

GLOBAL BALANCE IN ADULT SPINAL DEFORMITIES. A STUDY OF 60 CASES

ALINHAMENTO GLOBAL EM DEFORMIDADES DA COLUNA VERTEBRAL DO ADULTO.
UM ESTUDO DE 60 CASOS

BALANCE GLOBAL EN LAS DEFORMIDADES ESPINALES DEL ADULTO.
UN ESTUDIO DE 60 CASOS

VICTOR MISAEL GALICIA LUNA¹, JUAN ENRIQUE GUZMAN CARRANZA¹, AMADO GONZALEZ MOGA¹, GABRIEL HUERTA HERNANDEZ¹,
ABRAHAM ISAIS GOMEZ¹, VICTOR HUGO ANAYA CONTRERAS¹, LEONARDO ALVAREZ VAZQUEZ¹

1. Centro Médico ISSEMYM Ecatepec, Estado de México, México.

ABSTRACT

Objectives: Determine the most prevalent type of curve in our population, to quantify the radiographic parameters such as PT, IP, SS and compare the physical function according to ODI and SRS-22r. **Methods:** Retrospective, observational, longitudinal, single-center study, carried out from January 2010 to May 2015 at the Centro Médico ISSEMYM Ecatepec, Spine Surgery Service. **Results:** A total of 60 patients were obtained, 60% female, with curvatures according to SRS-Schwab, type T (28%), TL (46.6%), D (15%), N (10%), with a mean preoperative VAS of 7 for all curves and post-surgical 2 after 6 months. The SRS-22r preoperative test was 2.1 and postoperatively was 3.75, with $p < 0.001$. **Conclusions:** Deformities of the adult spine are a growing disease in our country. The surgical management of deformities requires proper clinical and radiographic planning. Patients undergoing surgical treatment in our study showed curvature type TL and demonstrated significant improvement in ODI and SRS-22r.

Keywords: Scoliosis; Classification SRS-schwab; Sagittal balance; Radiographic criteria.

RESUMO

Objetivos: Determinar o tipo de curva mais prevalente em nossa população, quantificar os parâmetros radiográficos, tais como PT, PI, SS e comparar a função física de acordo com ODI e SRS-22r. **Métodos:** Estudo retrospectivo, observacional, longitudinal, em centro único, realizado no período de janeiro de 2010 a maio de 2015 no Centro Médico ISSEMYM Ecatepec, Serviço de Cirurgia da Coluna. **Resultados:** Reuniu-se um total de 60 pacientes, 60% do sexo feminino, com curvaturas, de acordo com o SRS-Schwab, tipo T (28%), TL (46,6%), D (15%), N (10%), com EVA média pré-operatória de 7 para todas as curvas e pós-cirúrgica de 2 depois de 6 meses. O teste SRS-22r pré-operatório foi de 2,1 e o pós-operatório foi de 3,75, com $p < 0,001$. **Conclusões:** As deformidades da coluna vertebral do adulto são uma doença crescente em nosso país. O tratamento cirúrgico das deformidades requer planejamento clínico-radiográfico adequado. Os pacientes submetidos ao tratamento cirúrgico em nosso estudo mostraram curvatura tipo TL e apresentaram melhora significativa de ODI e SRS-22r.

Descritores: Escoliose; Classificação SRS-Schwab; Equilíbrio sagital; Critérios radiográficos.

RESUMEN

Objetivos: Determinar el tipo de curva más frecuente en nuestra población, cuantificar los parámetros radiográficos como PT, PI, SS y comparar la función física de acuerdo al test de ODI y SRS-22r. **Métodos:** Estudio retrospectivo, observacional, longitudinal y unicéntrico, realizado en el periodo entre Enero de 2010 y Mayo de 2015 en el Centro Médico ISSEMYM Ecatepec, Servicio de Cirugía de Columna. **Resultados:** Se obtuvieron un total de 60 pacientes, 60% mujeres, con curvaturas, de acuerdo a la clasificación SRS-Schwab, tipo T (28%), tipo TL (46,6%), tipo D (15%), tipo N (10%), con una EVA prequirúrgica promedio de 7 para todo tipo de curvas y posquirúrgica de 2 a los 6 meses. El test de SRS-22r prequirúrgico fue de 2,1 y el posquirúrgico de 3,75 con $p < 0,001$. **Conclusiones:** Las deformidades espinales del adulto son una patología creciente en nuestro país. El manejo quirúrgico de las deformidades requiere una adecuada planeación clínico-radiográfica. Los pacientes sometidos a tratamiento quirúrgico en nuestro estudio mostraron una curvatura tipo TL y presentaron mejoría significativa del ODI y del SRS-22r.

Descriptores: Escoliosis; Clasificación SRS-Schwab; Balance sagital; Criterios radiográficos.

INTRODUCTION

Adult scoliosis is defined as an abnormal curvature greater than 10° in a patient older than 18 years of age who has reached skeletal maturity of Risser grade 5.^{1,2} Sometimes this results from a curvature that was present in childhood and never treated, and which consequently progressed.^{3,4} If scoliosis is present in an adult without any precedent of curvature in childhood, it is classified as

degenerative (De Novo) adult scoliosis.^{5,6}

As we age, there are changes in the spine due to the failure of the discogenic cascade and changes produced at the level of the facet joints that produce antero-, retro-, or laterolisthesis and lead to radicular compression.⁷

Worldwide, adult scoliosis has been referred to as affecting a very wide range that goes from 2% to 32%.⁶ It is estimated that approximately 65% of the cases of scoliosis are idiopathic, 15% are congenital, and

Study conducted at the Centro Medico ISSEMYM Ecatepec, Department of Spine Surgery, State of Mexico, Mexico.

Correspondence: Centro Médico ISSEMYM ECATEPEC, Servicio de Cirugía de Columna, Avenida del trabajo s/n, Colonia el Carmen, Estado de México. omnipen@gmail.com

another 10% are secondary to neuromuscular diseases.⁸ In our country there are no statistics for this pathology, but we do know that it is a growing problem, as evidenced by the numbers from INEGI, since in the 50s there were only 554.000 patients over the age of 60, and in the 90s the number had practically tripled to 1.611,317 residents, and in 2010 to 3.116,466 with a rate of aging of 31%.⁹ Because of this, and because the traditional Lenke classification for idiopathic scoliosis was not sufficient to cover this pathology,⁵ there were multiple attempts to classify it, those by Aebi in 2005,⁷ Schwab in 2006, and the SRS in 2011,^{10,11} to name a few. Today, there is a great deal of interest in spinal pelvic balance as described by Roussouly and Gollogly¹² and Lafage et al.,^{13,14} such that three sagittal modifiers of spino-pelvic balance were included in the 2013 classification of the Scoliosis Research Society—Schwab Adult Spinal Deformity Classification. To determine the most prevalent curve in our population, to quantify radiographic parameters such as PT, PI, and SS, and to compare function according to the ODI and SRS 22r questionnaires.

MATERIAL AND METHODS

Retrospective, observational, longitudinal, single-center study. During the period between January 2010 and May 2015 in the Spine Surgery Service of the Centro Médico ISSEMYM Ecatepec. This includes a total of 60 patients, all of whom signed the term of consent. The approval of the Ethics Committee was not required for this retrospective study in our unit.

RESULTS

In this study, we obtained a sample made up of (n) 60 patients, 24 men, and 36 women. The average age was 68.5 ± 5.5 years. Spinal deformity was classified according to the SRS-SCHWAB classification and the most common diagnosis was thoracolumbar scoliosis at 47%, followed by simple thoracic scoliosis at 28.33%, and, in last place at 10%, by sagittal deformities. Radiographic measurements were taken as part of the pre-surgery planning protocol in order to classify the deformities and are displayed in Figure 1 below. In turn, we also classified the type of lordosis present in the patients according to the classification of Pierre Roussouly and found that type 4 was the most common at 36.66%, followed by types 1 and 3 with a total of 15 patients each, and finally by type 2 at only 8%. Patient disability was measured prior to surgery using the ODI and SRS 22r tests. The results are displayed below. (Figure 2) As we can see, the level of disability is high in both tests, which is the reason why patients accepted surgical treatment. In terms of post-surgical results, we find an improvement in almost all the radiographic measurement taken, as can be seen in Figure 3.

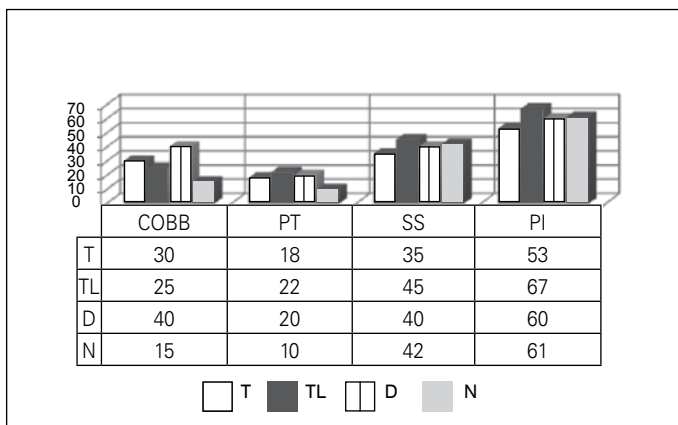


Figure 1. Relationship between type of curve and preoperative modifiers of sagittal balance.

An improvement in disability scores is observed, but the improvement was only greater than 15 points in the postoperative ODI for type L curves. The Student's *t* test for dependent variables yielded a *p* value < 0.001 (CI 95% of the difference -0.8 to -0.3). (Figure 4) Regarding the VAS, we can see in Figure 5 that the results decrease progressively to a VAS of between 2 and 3 for all types of curves. Next, the results of the SRS 22r test show improvement. The Student's *t* test for dependent variables yielded a *p* value < 0.001 (CI 95% of the difference -0.8 to -0.03). (Figure 6) Complications included the dehiscence of a wound and a seroma, both of which were resolved without further complications.

DISCUSSION

In our study we found a greater incidence of spinal deformities in the group of women, with a percentage of 60%, which is not an overwhelming difference like that reported by Daubs et al.⁹ in their case series with 38 women and 8 men. In this study we found that the most common type of curve was thoracolumbar with a total of 46.6%, which corresponds to that found by Bridwell et al.¹⁵ in their case series, and also corresponds to the changes found in the population pyramid with the increasing population older than 60 years of age, which agrees with the data reported by INEGI. We found an average preoperative VAS of 7 for all types of curves and a 6-month postoperative VAS of 3. Application of the SRS 22r test yielded a preoperative average of 2.1 for all curves and increased to 3.75 postoperatively, similar to the findings of Crawford et al.¹⁶ who reported a change in the SRS 22r from 2.93 to 3.65 points following surgery. It is clear that the patients scored better because of an improvement in body image, but also because of better global balance, pain reduction, and therefore, a return to increased patient activity.

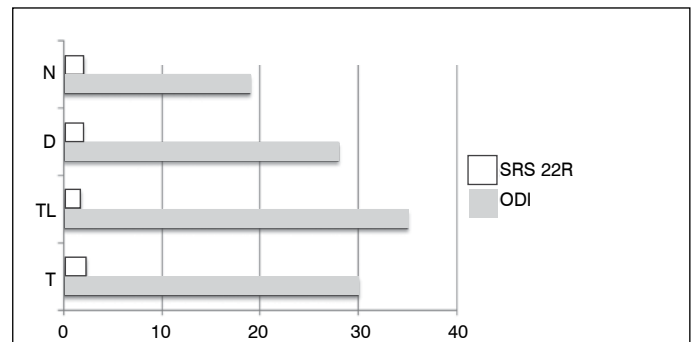


Figure 2. Relationship between type of curve and disability according to ODI and SRS 22R scores.

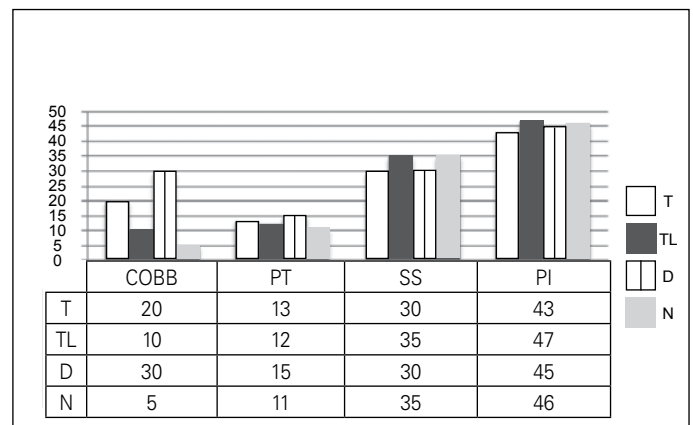


Figure 3. Relationship between type of curve and postoperative modifiers of sagittal balance.

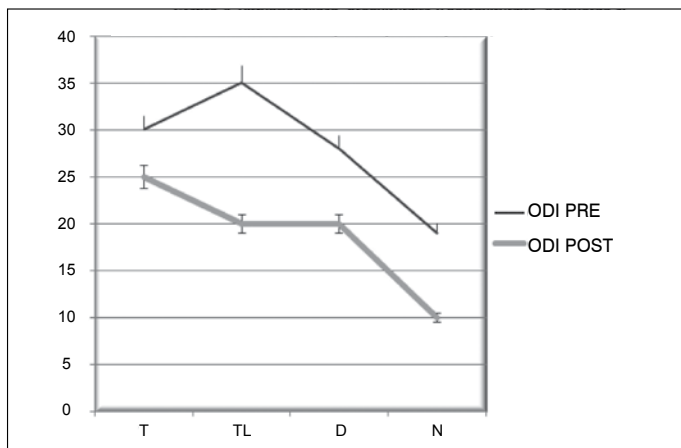


Figure 4. Pre- and postoperative disability according to ODI (Owsestry Disability Index).

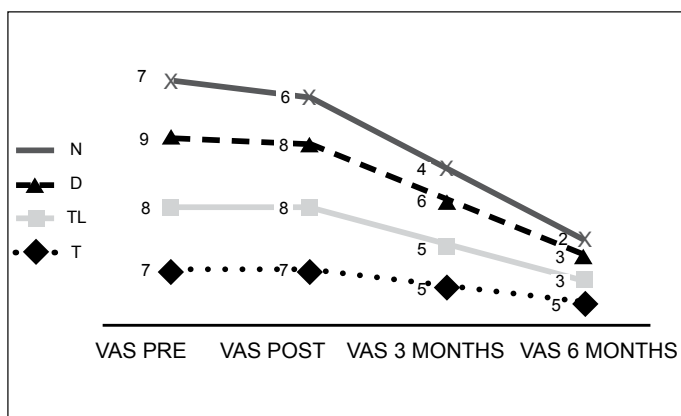


Figure 5. Follow-up of postoperative pain using VAS (Visual Analog Scale).

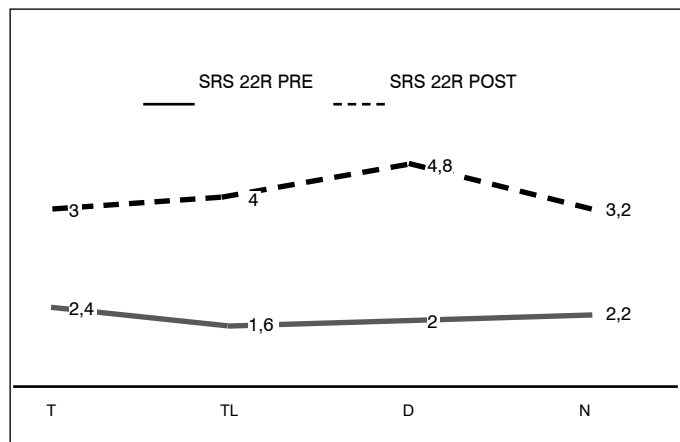


Figure 6. Measurement of disability according to SRS 22R, for all types of curves.

CONCLUSION

Adult spinal deformities are a growing disease in our country. Surgical management of these deformities requires proper clinical and radiographic planning. The patients in our study who underwent surgical treatment for type L curvature showed significant improvement in ODI and SRS 22r scores.

ACKNOWLEDGEMENTS

To the ISSEMYM medical center for allowing us to work properly and also to have given us the opportunity to count on their resources for our study. To our patients for their trust. To my wife and children for their approval and love.

All the authors declare that there are no potential conflicts of interest regarding this article.

AUTHORS' CONTRIBUTION: Each author made significant individual contributions to the preparation of the manuscript. VMGL and JEGC conception and design of the study. AGM and GHH critical review and design of the study. LAV, AIG Y VHAC critical review analysis and interpretation of the data.

REFERENCES

- Schwab FJ, Smith VA, Biserni M, Gamez L, Farcy JP, Pagala M. Adult scoliosis: a quantitative radiographic and clinical analysis. *Spine (Phila Pa 1976)*. 2002;27(4):387-92.
- Glassman SD, Berven S, Bridwell K, Horton W, Dimar JR. Correlation of radiographic parameters and clinical symptoms in adult scoliosis. *Spine (Phila Pa 1976)*. 2005;30(6):682-8.
- Maclure M, Willett WC. Misinterpretation and misuse of the kappa statistic. *Am J Epidemiol*. 1987;126(2):161-9.
- Cummings RJ, Loveless EA, Campbell J, Samelson S, Mazur JM. Interobserver reliability and intraobserver reproducibility of the system of King et al. For the classification of adolescent idiopathic scoliosis. *J Bone Joint Surg Am*. 1998;80(8):1107-11.
- Ogon M, Giesinger K, Behensky H, Wimmer C, Nogler M, Bach CM, et al. Interobserver and intraobserver reliability of Lenke's new scoliosis classification system. *Spine (Phila Pa 1976)*. 2002;27(8):858-62.
- Schwab F, Farcy JP, Berven S, Bridwell K, Ferguson M, Glassman S, et al. Importance of deformity apex in Adult Lumbar Scoliosis: a multicenterradiographic and health status analysis. In: Annual Meeting of the North American Spine Society, Chicago, IL; 2004.
- Aebi M. The adult scoliosis. *Eur Spine J*. 2005;14(10):925-48.
- Duval-Beaupère G, Lamireau T. Scoliosis at less than 30 degrees. Properties of the evolutive (risk of progression). *Spine (Phila Pa 1976)*. 1985;10(5):421-4.
- Daubs MD, Lenke LG, Cheh G, Stobbs G, Bridwell KH. Adult spinal deformity surgery: complications and outcomes in patients over age 60. *Spine (Phila Pa 1976)*. 2007;32(20):2238-44.
- Schwab F, Bess S, Blondel B, Hostin R, Shaffrey CI, Smith JS, et al. Combined Assessment of Pelvic Tilt, Pelvic Incidence/Lumbar Lordosis Mismatch and Sagittal Vertical Axis Predicts Disability in Adult Spinal Deformity: A Prospective Analysis. Louisville, KY: Scoliosis Research Society; 2011.
- Schwab F, Ungar B, Blondel B, Buchowski J, Coe J, Deinlein D, et al. Scoliosis Research Society-Schwab adult spinal deformity classification: a validation study. *Spine (Phila Pa 1976)*. 2012;37(12):1077-82.
- Roussouly P, Gollogly S, Berthonnaud E, Dimnet J. Classification of the normal variation in the sagittal alignment of the human lumbar spine and pelvis in the standing position. *Spine (Phila Pa 1976)*. 2005;30(3):346-53.
- Lafage V, Schwab F, Skalli W, Hawkinson N, Gagey PM, Ondra S, et al. Standing balance and sagittal plane spinal deformity: analysis of spinopelvic and gravity line parameters. *Spine (Phila Pa 1976)*. 2008;33(14):1572-8.
- Lafage V, Schwab F, Patel A, Hawkinson N, Farcy JP. Pelvic tilt and truncal inclination: two key radiographic parameters in the setting of adults with spinal deformity. *Spine (Phila Pa 1976)*. 2009;34(17):E599-606.
- Bridwell KH, Cats-Baril W, Harrast J, Berven S, Glassman S, Farcy JP, et al. The validity of the SRS-22 instrument in an adult spinal deformity population compared with the Oswestry and SF-12: a study of response distribution, concurrent validity, internal consistency, and reliability. *Spine (Phila Pa 1976)*. 2005;30(4):455-61.
- Crawford CH 3rd, Glassman SD, Bridwell KH, Berven SH, Carreon LY. The minimum clinically important difference in SRS-22R total score, appearance, activity and pain domains after surgical treatment of adult spinal deformity. *Spine (Phila Pa 1976)*. 2015;40(6):377-81.