

Image Quiz for Surgeons

Chirurgia (2016) 111: 422-427
No. 5, September - October
Copyright© Celsius

<http://dx.doi.org/10.21614/chirurgia.111.5.422>

Mature Teratoma Associated with Bilateral Ovarian Carcinosarcoma - Accidental Association or Etiopathogenetic Determinism? - Case Report

Rodica Birla, Elena-Roxana Catanescu, Andrei Caragui, Silviu Constantinoiu

Department of General and Esophageal Surgery, Excellence Center for Esophageal Surgery, Sf. Maria Hospital, Bucharest, Romania
"Carol Davila" University of Medicine and Pharmacy, Surgery Department, Bucharest, Romania

Rezumat

Teratom matur ovarian bilateral asociat cu carcinosarcom – asociere întâmplătoare sau determinism etiopatogenic? - prezentare de caz

Carcinosarcomul este o formă rară de cancer ovarian cu origine mixtă, iar asocierea sa cu teratomul matur este extrem de rară. Prezentăm cazul pacientei T.M. în vârstă de 67 ani, internată în clinică în 15.05.2016, F.O. 4877 pentru creșterea în volum a abdomenului. La internare, pacienta afebrilă, conștientă, cooperantă, echilibrată cardio-respirator, cu abdomen destins de volum, matitate accentuată pe flancuri, semnul valului pozitiv, bioumoral în limite normale cu excepția: acid uric seric = 6.64 mg/dl, glicemie serică = 113.7 mg/dl, proteine serice totale = 8.65 g/dl, raportul albumină/globulină subunitar, CRP 33.63 mg/l, sideremie 51 ug/dl, CA 125 = 588.4 UI. Ecografia abdominală: cantitate mare de lichid decliv și perihepatic și multiple formațiuni tumorale cu transformare chistică la nivelul abdomenului și pelvisului. Examen CT descrie multiple mase tisulare localizate intraperitoneal abdomino-pelvin, manșonate în epanșament lichidian, infiltrative, cu efect de masă pe lumenle digestive, fără obstrucție vizibilă CT. Tratamentul

chirurgical a constat în evacuarea lichidului de ascită, excizia formațiunilor tumorale din marele epiploon, a formațiunilor tumorale din ligamentul gastro-colic, epiploonectomie, anexectomie bilaterală și histerectomie totală. Evoluție postoperatorie simplă. Examenul histopatologic confirmă diagnosticul de carcinosarcom ovarian bilateral asociat cu teratom matur tridermic (prezența zonelor de țesut cerebral, asociat cu țesut cartilagos, epitelii de tip tranzițional, epitelii de tip tubar, stromă de tip endometrial, țesut adipos). IHC confirmă compatibilitatea cu diagnosticul de carcinosarcom ovarian (tumoră malignă mixtă mulleriană). Pacienta a urmat poli-chimioterapie adjuvantă. Asocierea teratomului cu elemente carcinosarcomatoase conferă cazului un prognostic infaust.

Cuvinte cheie: teratom matur, carcinosarcom ovarian

Abstract

Carcinosarcoma is a rare form of ovarian cancer with mixed origin, and its association with mature teratoma is extremely rare. We present the case of patient T. M. aged 67, admitted into our clinic on the 15/05/2016, F.O. 4877 for the increase of the abdominal volume. On admission, the patient was afebrile, conscious, cooperative, cardio-respiratory balanced, having the abdomen distended in volume, sharp dullness in the flanks, positive wave sign bioumoral within normal limits except: uric acid = 6.64 mg / dL, serum glucose = 113.7 mg / dl, serum total proteins = 8.65 g / dl, the albumin / globulin subunit, CRP 33.63 mg / l, sideremia 51 ug / dl, CA 125 = 588.4 IU. Abdominal ultrasound: high volume fluid and multiple perihepatic formations and multiple formations with cystic

Corresponding author:

Rodica Birla, MD
Department of General and Esophageal Surgery, Excellence Center for Esophageal Surgery, Sf. Maria Hospital, Bucharest
"Carol Davila" University of Medicine and Pharmacy, Bucharest, Romania
E-mail: birlarodica@yahoo.com

transformation in the abdomen and pelvis. CT exam describes multiple tissular masses localized intraperitoneal in the abdominal-pelvic region, sheath fluid effusion, infiltrative, with mass effect on the digestive lumens, without visible CT obstruction. Surgical treatment consisted in evacuation of the ascites fluid, excision of the tumoral lumps situated in the great omentum, omentectomy, excision of the lumps of the gastrocolic ligament, bilateral ovariectomy and hysterectomy. Post-operative simple evolution. Histopathology confirmed the diagnosis of bilateral ovarian carcinosarcoma associated with tridermic mature teratoma (presence of brain tissue areas associated with cartilage, transitional type epithelium, tubal type epithelium, endometrial stroma type and fatty tissue). IHC confirms the compatibility with the diagnosis of ovarian carcinosarcoma (mixed malignant Mullerian tumor). The patient followed adjuvant polichemotherapy. The association of teratoma with carcinosarcoma elements confers a poor prognosis case.

Key words: mature teratoma, ovarian carcinosarcoma

Introduction

Carcinosarcoma is a rare form of ovarian cancer with epithelial origin, has a poor prognosis compared with high grade serous papillary carcinoma, regardless of the FIGO staging and its association with mature teratoma (dermoid cyst) is extremely rare as its malignancy is - in less than 2% of cases. (1)

Case report

We present the case of a patient, T. M. aged 67 years, with associated cardiac pathologie (ischemic heart disease and essential hypertension stage II), dyslipidemia, colecistectomised and left neftectomy, admitted to the clinic for the sudden increase in abdominal volume. From the personal history of the patient's we retain one birth, menopause at 50 years without any suffering any gynecologic previously diagnosed before admission. On admission, the patient was afebrile, conscious, cooperative, cardio-respiratory balanced, with distended abdomen, sharp dullness on the flanks, positive wave sign.

Bioumoral within normal limits except: uric acid = 6.64 mg / dL, serum glucose = 113.7 mg / dl, serum total proteins = 8.65 g / dl, the albumin / globulin subunit, CRP 33.63 mg / l, sideremia 51 ug / dl, CA 125 = 588.4 IU.

Abdominal ultrasound shows a large amount of liquid both perihepatic and declive, 8 cm lateral from the umbilicus - hyperechoic conglomerate with areas of cystic transformation that stretches to the small basin (Fig. 1), where a right lateral-uterine complex formation is revealed with a similar aspect and a complex area with similar aspect in the left hemiabdomen, measuring 17 cm (Fig. 2).

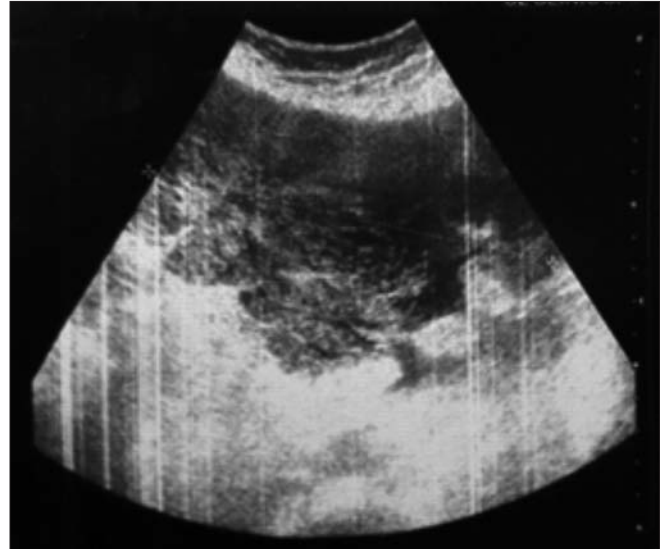

Figure 1. Conglomerate with areas of cystic transformation that stretches to the small basin

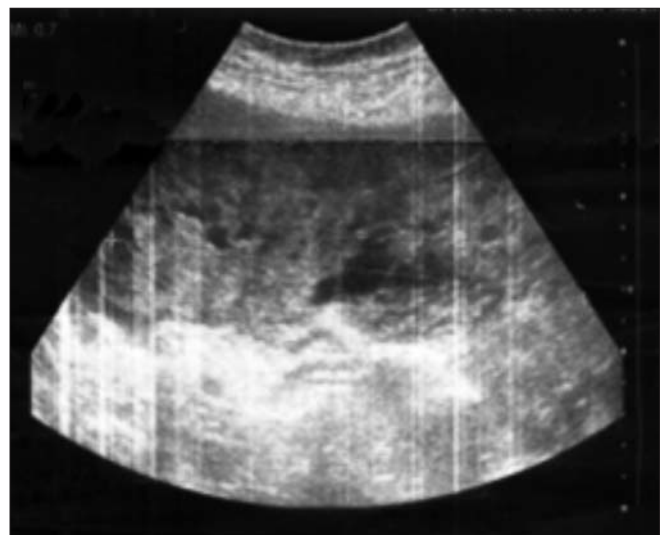


Figure 2. Ultrasound aspect—complex abdominal formation in the left hemiabdomen

Computed tomography describes an 8 mm nodular tissue located in the right pulmonary base, multiple confluent, intense Iodophors tissular masses, localized intraperitoneal in the abdominal-pelvic region belled in fluid effusion, with a possible starting point in the utero-axnaxal lodge, infiltrating the omentum, mesentery, with mass effect on the digestive lumens, without visible CT obstruction. (Fig. 3, 4, 5)

Following an appropriate preoperative preparation surgery is decided as the course of action. Supra and subumbilical median laparotomy is practiced and we found: peritoneal carcinomatosis having an ovarian starting point. Ascites fluid in large quantity from which samples are harvested for cytology and bacteriological exam, multiple tumor formations with cerebriform aspect over and infracentimetric in size, between 0.5-20 cm diameter at the level of the great omentum which

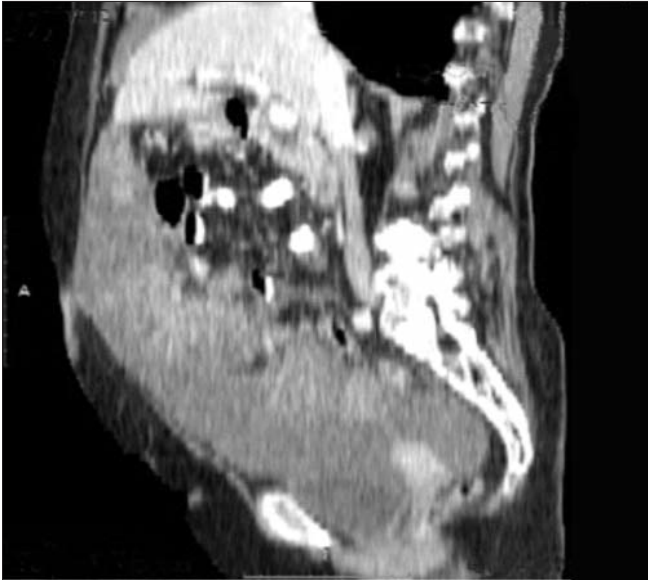

Figure 3. Confluent abdominal-pelvic tissular masses, intense Iodophors - sagittal section

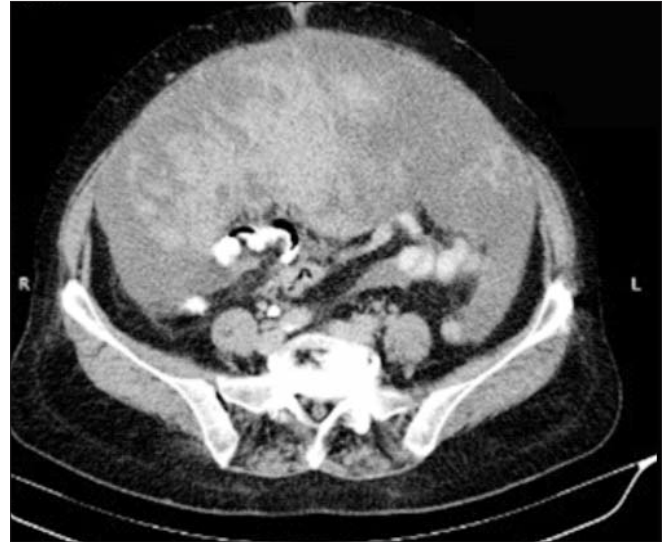

Figure 4. Tissular masses infiltrating the omentum and mesentery with mass effect on the digestive lumens, without visible obstruction tomographic aspect – transversal section

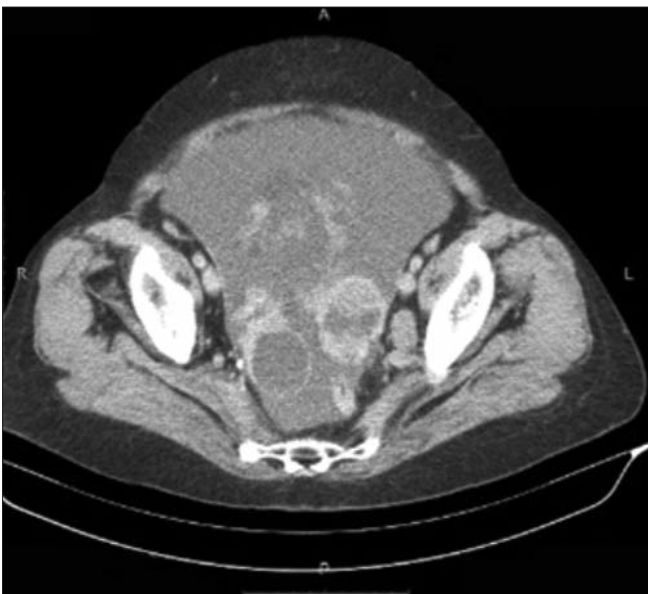

Figure 5. Pelvic tumoral formations belled by a large amount of ascites fluid - tomographic aspect, transversal section

occupies most of the peritoneal cavity, bilateral tumoral ovaries bilateral with 8 and 12 cm in size.

The surgical procedure consisted in the excision of the formations situated in the great omentum, omentectomy, of the two tumor formations with a diameter of 1 and 2 cm from the gastro-colic ligament, and total hysterectomy with bilateral ovariectomy, sending the specimens to histopathology. Peritoneal cavity lavage with saline solution, drainage of the Douglas cul de sac.

Macroscopic appearance of the surgically excised formations: 6 nodular abdominal formations with diameters between 20 and 7 cm, with whitish-gray and mucoid areas,

alternating with blackish areas, omentum with numerous nodular formations with sizes between 1 and 9 cm, right Fallopian tube with tumoral transformed ovary, 5/4/3 cm in size, presenting in the periphery a 4 cm cystic formation, metastatic nodules from the gastrocolic ligament - two nodules with a diameter of 1 or 2 cm, left Fallopian tube - multinodular elastic whitish-gray formation, piece of hysterectomy - 3/4/3 cm uterus, the uterus cavity with dimensions of 2 cm, endometrium - 0.1 cm. (Fig. 6, 7, 8)

Histopathological aspect of the excized peritoneal formations is highly suggestive for the diagnosis of carcinosarcoma associated with mature teratoma (presence of mature teratoma areas consisting of brain tissue associated with cartilage, transitional type epithelial tissue, tubal stroma endometrial-like tissue, adipose). Ovaries and fallopian tubes, lymph nodes with two massive carcinomatous infiltration. At the serous of the uterine body - large areas of mature brain tissue. (Fig. 9, 10, 11, 12)

Partial staging pT3cM1 – FIGO IV.

To confirm the sarcomatous component of the malignant tumor proliferation and differential diagnosis with high-grade serous carcinoma immunohistochemical tests were recommended.

They reveal: AE1 / AE3 strongly positive in the epithelial component, focal positive in very rare tumor cells from the stromal component. CA125 focal positive in the epithelial component, ER focal positive in very rare nuclei of the tumor cells of epithelial component,

WT1 focal positive in rare nuclei of tumor cells from the epithelial component, focal positive in the cytoplasm of numerous cells of the tumor stromal component.

S100 focal positive in tumor cells from the condrosarcoma areas.

Ki67 Ki67 positive many nuclei of the tumor cells, both in

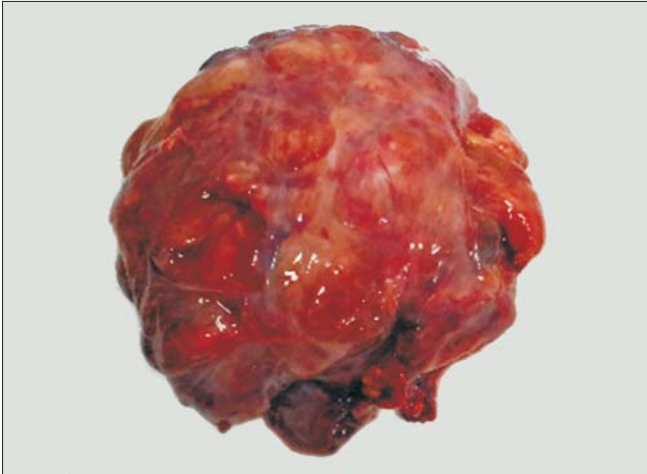

Figure 6. Macroscopic aspect—omentum formation, encapsulated, with mixed consistency, unhomogeneous

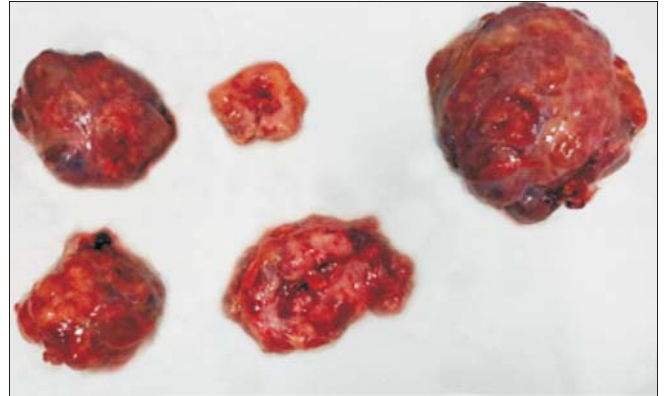


Figure 7. Macroscopic aspect – 5 tumoral formations separately resected from the great omentum with similar structure

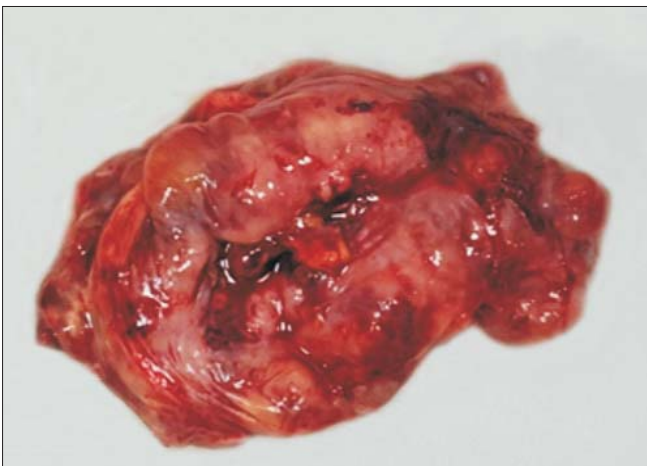


Figure 8. Macroscopic aspect – omentum formation with cerebriform aspect

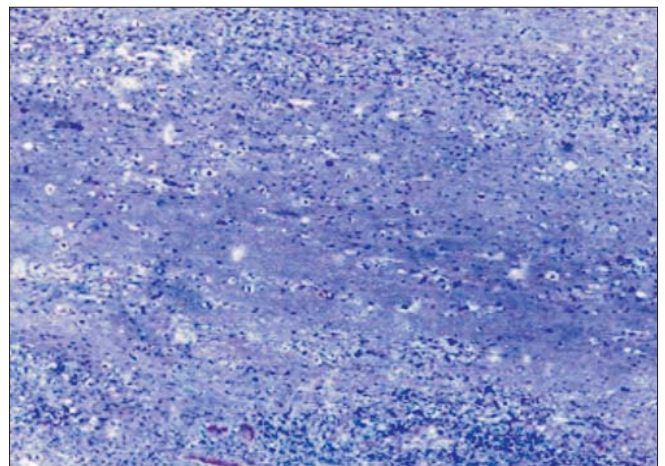


Figure 9. Mature teratoma composed of cerebriform tissue – HP, HE, 20X aspect

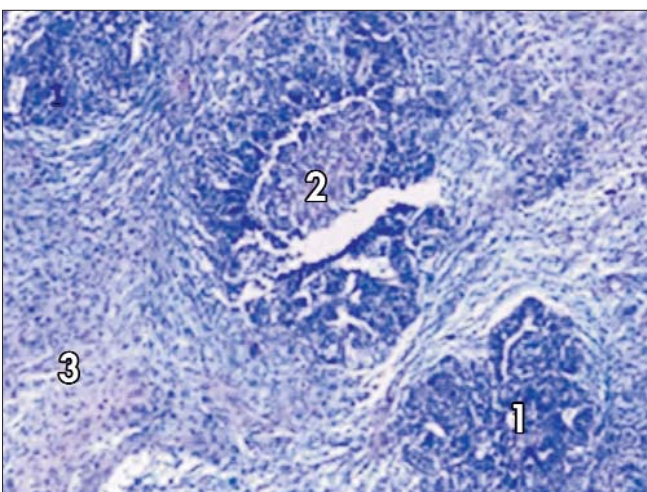


Figure 10. Carcinosarcoma - Carcinomatous poorly differentiated component (1), comedonecrosis (2) high grade sarcomatous component (3) - HP, HE 20 x aspect

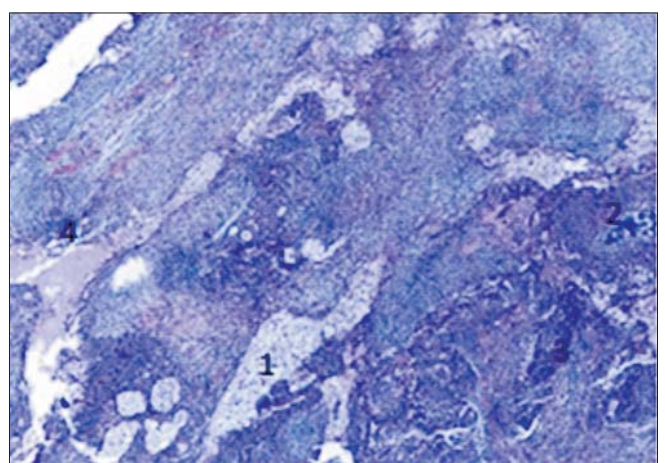


Figure 11. Mature teratoma (squamous component with clear cell (1), mature cartilaginous tissue (2)) associated with carcinosarcoma (poorly differentiated carcinomatous component (3), high grade sarcomatous component (4) - HP, HE, 20X aspect

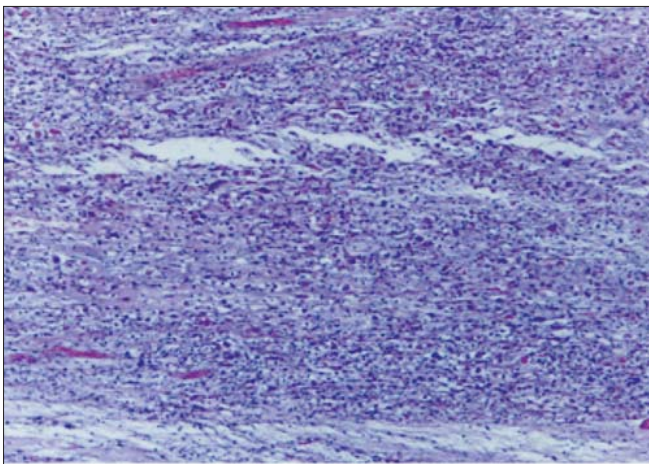


Figure 12. Sarcomatous rhabdoid-like component, HP, HE, 20X aspect

the stromal component, and in the epithelial component. Ki67 focal index 80%.

Histopathological and immunophenotype appearance is compatible with a diagnosis of ovarian carcinosarcoma (mixed Mullerian tumor).

Favorable postoperative evolution, encumbered by the appearance of a postoperative ileus treated conservatively with discharge in the 15th postoperative day. Postoperatively, the patient was taken over by an oncologist who established adjuvant chemotherapy.

Discussions

The term of teratoma derives from the greek term of "teratos" and it means monster (1).

Teratomas are the most common germ cell tumors consisting of 2 or 3 germ foils: ectoderm, mesoderm or mature endoderm. Mature teratomas are made up of differentiated components found in adult such as cartilage or glandular epithelium while immature teratomas contain tissue with incomplete somatic differentiation similar to the fetal tissues. (2)

Literature data report mature teratoma association with different types of ovarian malignancy in cases where injuries were identified strictly on the ovaries. (3)

The incidence of malignant transformation in mature teratoma of the ovary is less than 2% as reported in gynaecological and pathological literature. (1)

Currently, the malignant transformation of teratoma is most often postoperative diagnosed by histopathological examination of the resection specimens. (4)

Incriminated predictive factors for malignant transformation of ovarian mature teratoma include high values of CA-125, older age, larger tumor and postmenopausal status. (5,6).

Our patient was in menopause for 17 years, the abdominopelvic tumor formations were between 0.5-20 cm, and CA-125 level was increased about 20 times. Similar data we met in other studies showing that: ovarian malignant transformation of mature teratomas usually occurs in women after menopause; Tumor formation is characterized by large (greater than 10 cm

diameter) and presenting high level of serum CA-125. (7,8, 9, 10, 11, 12, 13)

Moreover, in the case presented, the presence of multiple masses of tissue located intraperitoneal belled in fluid effusion, infiltrative raised a high suspicion of a neoplastic process with adnexal starting point but the presence of mature teratoma aspects was a histopathological surprise.

Studies in the literature reveal that, most often degeneration is of squamous cell carcinoma type (88.3%), followed by adenocarcinoma, fibrosarcoma, carcinoid and mixed tumors. (14)

In our patient, the mature teratoma degenerations was of carcinosarcoma type. In the cases of tumors located strictly in the ovaries the therapeutic attitude is represented by anexectomy followed by complete resection after histopathological confirmation of malignant mature teratoma.(15)

Literature data show that patients with ovarian carcinosarcoma tumors seek medical attention in advanced stages of the disease in 90% of the cases, in most cases the tumors exceeds the ovary and is accompanied by the presence of ascites. (16)

If the studied case, the clinical and laboratory investigations have confirmed the presence of abdominopelvic mixed, bulky tumor formation, probably with ovarian starting point and a large amount of ascites.

In the case of ovarian carcinosarcoma diagnosed in advanced stages debulking is first intended, followed by adjuvant chemotherapy.

Our therapeutic strategy consisted in applying the surgical treatment as the first therapeutic sequence - due to biological conditions and absence of metastatic determinations, followed by adjuvant chemotherapy.

Currently, the literature and reported cases are in small numbers and because of this therapeutic strategy is not fully established. The literature suggests that the optimal treatment for carcinosarcoma consists of surgical debulking and chemotherapy. Given that on admission the patient had a good clinical and biological condition, the surgical treatment is first recommended followed by adjuvant chemotherapy. In patients with poor clinical and biological condition chemotherapy is first recommended, possibly with neoadjuvant character, given that the tumor is responsive to treatment. (17)

Because of the small number of cases there is no standard chemotherapy scheme. (18)

Many authors include platinum salts in their chemotherapy schemes. (19,20)

In our case, from the HP point of view, the elements of mature teratoma were supported by the presence in the excised tumor formations of brain tissue associated with cartilage, transitional type epithelium, tubal type epithelium, endometrial type stroma and fatty tissue. Literature data suggest that the presence of brain tissue in mature teratoma is rare. (21,22,23)

Although the HP appearance was highly suggestive for the diagnosis of carcinosarcoma associated with mature teratoma, we performed immunohistochemical testing for confirmation of the mixed character of the malignant proliferation (for the carcinomatous component AE1 / AE3, CA-125, ER, WT1,

and for the sarcomatous component S100). Other authors have noted the presence of estrogen and cytokeratin receptors and the absence of progesterone receptors as being characteristic for the carcinomatous component and the sarcomatous component is characterized by the presence of vimentin. (24)

Although we have no data to prove the existence of a previously asymptomatic ovarian mature teratoma we believe that the coexistence of mature teratoma elements with malignant ones in the peritoneal and ovarian tumor formations support the diagnosis of malignant mature teratoma.

Sarcomatous component association confers a poor prognosis case.

Conclusions

Carcinosarcoma developed on ovarian mature teratoma is rare and surprising.

Therefore, there is no standard of therapy, in most cases being executed the surgery followed by chemotherapy.

References

- Bal A, Mohan H, Sunitha BS, Sehgal A: Malignant transformation in mature cystic teratoma of the ovary: report of five cases and review of the literature. *Arch Gynecol Obstet.* 2007;275(3):179-82. Epub 2006 Sep 7.
- Newsom-Davis T, Poulter D, Gray R, Ameen M, Lindsay I, Papanikolaou K, et al. Case report: malignant teratoma of the uterine corpus. *BMC Cancer.* 200 Jun 18;9:195. doi: 10.1186/1471-2407-9-195.
- Togami S, Kawamura T, Kamio M, Douchi T. A rare case of microinvasive squamous cell carcinoma arising in mature cystic teratoma of the ovary. *Eur J Gynaecol Oncol.* 2016;37(3):420-2.
- Mori Y, Nishii H, Takabe K, Shinozaki H, Matsumoto N, Suzuki K, et al. Preoperative diagnosis of malignant transformation arising from mature cystic teratoma of the ovary. *Gynecol Oncol.* 2003;90(2):338-41.
- Park CH, Jung MH, Ji YI. Risk factors for malignant transformation of mature cystic teratoma. *Obstet Gynecol Sci.* 2015; 58(6):475-80. doi: 10.5468/ogs.2015.58.6.475. Epub 2015 Nov 16.
- Ariyoshi K, Kawauchi S, Kaku T, Nakano H, Tsuneyoshi M. Prognostic factors in ovarian carcinosarcoma: a clinicopathological and immunohistochemical analysis of 23 cases. *Histopathology.* 2000;37(5):427-36.
- Lee KH, Song MJ, Jung IC, Lee YS, Park EK. Autoamputation of an ovarian mature cystic teratoma: a case report and a review of the literature. *World J Surg Oncol.* 2016;14(1):217. doi: 10.1186/s12957-016-0981-7.
- Hackethal A, Brueggmann D, Bohlmann MK, Franke FE, Tinneberg HR, Münstedt K. Squamous-cell carcinoma in mature cystic teratoma of the ovary: systematic review and analysis of published data. *Lancet Oncol.* 2008;9(12):1173-80. doi: 10.1016/S1470-2045(08)70306-1.
- Doo DW, Erickson BK, Arend RC, Conner MG, Huh WK, Leath CA 3rd. Radical surgical cyto-reduction in the treatment of ovarian carcinosarcoma. *Gynecol Oncol.* 2014; 133(2):234-7. doi: 10.1016/j.ygyno.2014.03.002. Epub 2014 Mar 11.
- Brudie LA, Khan F, Radi MJ, Yates MM, Ahmad S. Malignant melanoma arising in a mature teratoma: a case report with review of the recent literature. *Gynecol Oncol Rep.* 2016;16: 47-50. doi: 10.1016/j.gore.2016.04.005. eCollection 2016.
- Koc S, Tapisiz OL, Turan T, Ocalan R, Ozfuttu A, Boran N, et al. Malignant transformation of mature cystic teratoma of the ovary: a case series. *J Exp Ther Oncol.* 2015;11(1):11-6.
- Hackethal A, Brueggmann D, Bohlmann MK, Franke FE, Tinneberg HR, Münstedt K. Squamous-cell carcinoma in mature cystic teratoma of the ovary: systematic review and analysis of published data. *Lancet Oncol.* 2008;9(12):1173-80. doi: 10.1016/S1470-2045(08)70306-1.
- Kearney MS. Synchronous benign teratomas of the greater omentum and ovary. Case report. *Br J Obstet Gynaecol.* 1983; 90(7):676-9.
- Brudie LA, Khan F, Radi MJ, Yates MM, Ahmad S. Malignant melanoma arising in a mature teratoma: a case report with review of the recent literature. *Gynecol Oncol Rep.* 2016;16:47-50. doi: 10.1016/j.gore.2016.04.005. eCollection 2016.
- Kalampokas E, Boutas I, Kairi-Vasilatou E, Salakos N, Panoulis K, Aravantinos L, et al. A rare case report of squamous-cell carcinoma arising from mature cystic teratoma of ovary. *G Chir.* 2014; 35(9-10):241-5.
- Brown E, Stewart M, Rye T, Al-Nafussi A, Williams AR, Bradburn M, et al. Carcinosarcoma of the ovary: 19 years of prospective data from a single center. *Cancer.* 2004;100(10): 2148-53.
- Menon S, Deodhar K, Rekhi B, Dhake R, Gupta S, Ghosh J, et al. Clinico-pathological spectrum of primary ovarian malignant mixed mullerian tumors (OMMMT) from a tertiary cancer institute: A series of 27 cases. *Indian J Pathol Microbiol.* 2013; 56(4):365-71. doi: 10.4103/0377-4929.125293.
- Otsuka I, Takaya H, Takagi K, Tanaka A, Kaseki H, Izuta C, et al. Carcinosarcoma of the ovary treated with paclitaxel and carboplatin chemotherapy-a report of 4 cases. *Gan To Kagaku Ryoho.* 2013;40(9):1249-53. Japanese
- Rauh-Hain JA, Birrer M, Del Carmen MG. Carcinosarcoma of the ovary, fallopian tube, and peritoneum: Prognostic factors and treatment modalities. *Gynecol Oncol.* 2016;142(2):248-54. doi: 10.1016/j.ygyno.2016.06.003. Epub 2016 Jun 16.
- Uçar MG, Çakir T, İlhan TT, Karabaglı P, Çelik Ç. Primary ovarian malignant mixed mullerian tumour: a case report and brief review of literature. *J Clin Diagn Res.* 2016;10(3):QD04-6. doi: 10.7860/JCDR/2016/18127.7457. Epub 2016 Mar 1.
- Hirschowitz L, Ansari A, Cahill DJ, Bamford DS, Love S. Central neurocytoma arising within a mature cystic teratoma of the ovary. *Int J Gynecol Pathol.* 1997;16(2):176-9.
- Friedrichs N, Vorreuther R, Fischer HP, Wiestler OD, Buettner R. Neurocytoma arising in the pelvis. *Virchows Arch.* 2003; 443(2):217-9. Epub 2003 Jul 3.
- Ersoz S, Kucuk H, Mungan S, Turgutalp H, Imamoglu M, Kosucu P. Neurocytoma arising in an adrenal gland mature teratoma. *Fetal Pediatr Pathol.* 2011;30(5):275-9. doi: 10.3109/15513815.2011.572955. Epub 2011 May 25.
- Dasgupta S, Bose D, Bhattacharyya NK, Biswas PK. Carcinosarcoma of ovary with its various immunohistochemical expression: Report of a rare case. *J Cancer Res Ther.* 2015;11(4):1022. doi: 10.4103/0973-1482.147390.