



Archivos Españoles de Urología

ISSN: 0004-0614

urologia@arch-espanoles-de-urologia.es

Editorial Iniestares S.A.

España

Fernández Pello, Sergio; Mosquera, Javier; Fernández, Isabel; Perez Carral, José
Ramón; Benito, Priscila; Díaz, Begoña; Cuervo, Javier; Quiñones, Luis
RIÑÓN DE PAGE: HEMATOMA SUBCAPSULAR RENAL E HIPERTENSIÓN ARTERIAL.
PRESENTACIÓN DE UN NUEVO CASO Y REVISIÓN DE LA LITERATURA
Archivos Españoles de Urología, vol. 66, núm. 6, julio-agosto, 2013, pp. 593-596
Editorial Iniestares S.A.
Madrid, España

Available in: <http://www.redalyc.org/articulo.oa?id=181043651008>

- How to cite
- Complete issue
- More information about this article
- Journal's homepage in redalyc.org

redalyc.org

Scientific Information System

Network of Scientific Journals from Latin America, the Caribbean, Spain and Portugal

Non-profit academic project, developed under the open access initiative

Case Reports

Arch. Esp. Urol. 2013; 66 (6): 593-596

PAGE KIDNEY: SUBCAPSULAR HAEMATOMA AND ARTERIAL HYPERTENSION. A NEW CASE REPORT AND REVIEW OF THE LITERATURE

Sergio Fernandez Pello, Javier Mosquera, Isabel Fernandez, Jose Ramon Perez Carral, Priscila Benito, Begoña Diaz, Javier Cuervo and Luis Quiñones¹.

Urology Department and Nephrology Department¹. Hospital de Cabueñes. Gijón. Asturias. Spain.

Summary.- **OBJECTIVE:** We present the case of a spontaneous subcapsular renal hematoma with increase of the levels of blood pressure in a patient previously normotensive.

METHODS: Patient with abdominal pain, spontaneous without previous trauma. CT showed a right subcapsular kidney hematoma. High levels of blood pressure were noticed at the admission in urology.

CONCLUSION: Page kidney is a cause of arterial hypertension due to external compression of renal parenchyma. It could be unnoticed as essential hypertension if high suspicion is not taken into account. Nowadays, the main cause of Page kidney is the renal biopsy in the context of kidney transplantation. The treatment is not recommended in the guidelines although the conservative management is proposed as first option.

Keywords: Page Kidney. Subcapsular haematoma. Secondary hypertension.

Resumen.- **OBJETIVO:** se presenta el caso de un hematoma subcapsular renal espontáneo con elevación de las cifras de tensión arterial en un paciente previamente normotenso.

MÉTODOS: paciente que acude por dolor abdominal, de aparición espontánea sin antecedente traumático. El TC demuestra la presencia de un hematoma subcapsular renal derecho. En la planta de hospitalización se registran cifras elevadas de tensión arterial.

CONCLUSIÓN: el riñón de Page es una causa de hipertensión arterial debida a una compresión extrínseca del parénquima renal. Sin una alta sospecha clínica podría interpretarse como hipertensión arterial esencial. Actualmente la causa más frecuente de este proceso ocurre en relación con la biopsia renal en pacientes trasplantados. El tratamiento no está consensuado en guías clínicas aunque el manejo médico conservador se propone como primera elección.

Palabras clave: Riñón de Page. Hematoma subcapsular. Hipertensión secundaria.

CORRESPONDENCE

Sergio Fernandez-Pello
Servicio de Urología
Hospital de Cabueñes
Gijón. Asturias. (Spain)

spello84@hotmail.com

Accepted for publication: February 17th, 2011

INTRODUCTION

Page kidney is an unfrequent medical profile of arterial hypertension caused by an external kidney compression due to a subcapsular or perirenal haematoma. The ischaemia produced involves interstitial nephritis and activation of yuxtaglomerular cells. Consequently, there are increasing of levels of serum renin and blood pressure.

These days, the complications of a kidney biopsy are the most frequent cause.

However, external trauma in the context of motor vehicle accident or the evidence of renal masses, are also common.

In our case, we present a patient with sudden pain over the right flank without trauma or anticoagulant antecedents. The imaging techniques showed the haematoma

and the hypertension were discovered previously to be discharged.

A few weeks later, a contrast enhanced CT describes the maintenance of subcapsular haematoma but in resolution phase.

CASE REPORT

A 52-year-old man presented to the hospital reporting pain located at right renal fossa 12 hours ago. As medical history he had diet-controlled arterial hypertension, alcoholic hepatopathy and an episode of right hemiparesis followed up by neurology department. From the urologic point of view, he had a right simple kidney cyst (4cm) discovered by incidental way. He used to take 100 mg acetil salicylic acid daily.

The patient referred a sudden and spontaneous pain, located at right lumbar region, without any previous traumatic antecedent. No fever, dysuria neither urinary symptoms.

On physical examination, blood pressure was 186/91 mm Hg and the temperature was 35°C. Abdominal examination was remarkable for right flank pain to palpation with negative bilateral kidney percussion.

Blood analysis with leukocytosis, other interesting parameters as hemoglobin (16.9 g/dl) or serum creatinine (1.18 mg/dl) were normal. Coagulation parameters were also normal: protrombin percentage 99% and INR 1.01. Urine analysis with pH of 7, one protein cross. Urine sediment with 6 eritocytes and 4 leukocytes.

He underwent urgent ultrasound and subsequently contrast enhanced CT, which revealed a contained right

subcapsular renal haematoma with a nodular image measured in 31 mm located at upper pole and no contrast enhancement. It also showed the previously known simple sinusoidal cyst (73 x 44 mm) and low contrast output by right kidney (Figure 1).

The patient was admitted to the urology department for pain and hemodynamic control, conservative observation was recommended. During the admission, no anemia was notice and pain was well-controlled. Only was remarkable the high levels of blood pressure registered with good response at ACEI. He underwent control ultrasound at 7 day with no changes respect to the previous. Levels of serum renine were not considered because the influence of fluids and drugs given at the hospitalisation. The patient was discharged at the 7th day.

Six weeks later the patient was cited at urology department. The control CECT describes the persistence of the subcapsular haematoma but in resolution phase. No nodular images in parenchyma neither additional contrast enhancement are described. In addition It is observed a right double incomplete excretory system (Figure 2).

Levels of blood pressure after 6 weeks were 180/90 mmhg, without any antihypertensive drug. The patient should continue with nephology controls.

DISCUSSION

In 1939, Page published an experiment based on a canine model. It proved the development of arterial hypertension as a result of wrapping the both kidneys in cellophane. This induced hypertension was explained

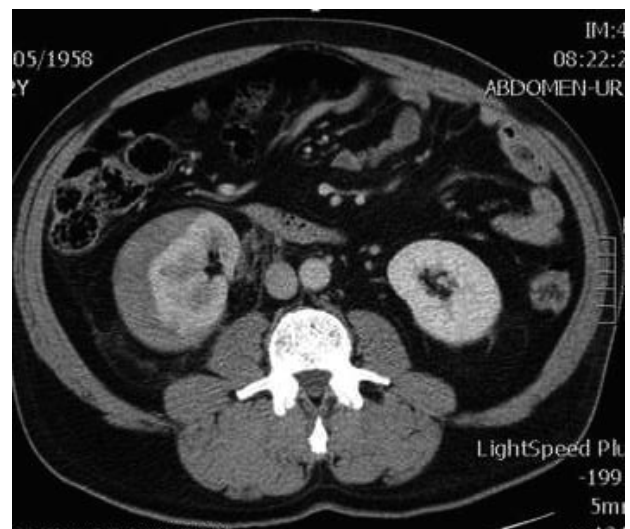
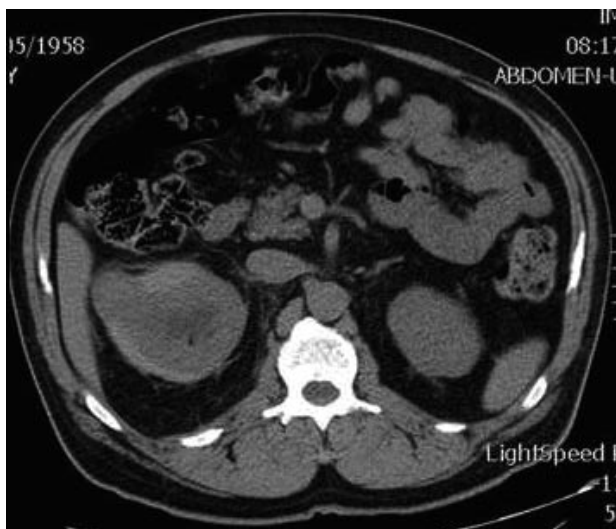


Figura 1. Hematoma subcapsular renal derecho comprimiendo parénquima renal. Lesión nodular sospechosa en polo superior.

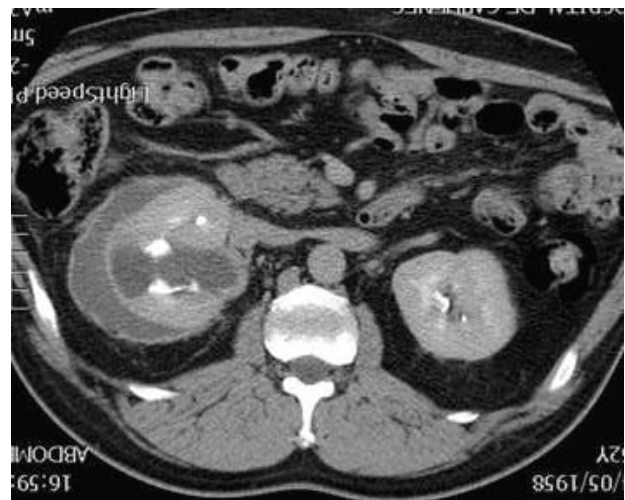
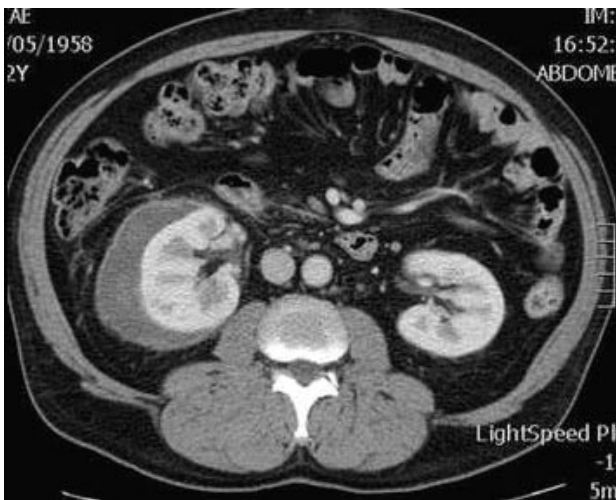


Figura 2. Persistencia del hematoma pero con menor densidad radiológica.

by the tissue ischaemia because of the external compression. The result was an acute perinephritis and activation of yuxtaglomerular cells, increasing the serum levels of renin (1).

This experiment was based on the papers published by Goldblatt in 1934. These showed an increased arterial pressure secondary to low blood input of the kidney after compression of the renal artery (2).

The first case in literature with hypertension due to an external kidney compression was described by Page in 1955. He reported a case of a young football player who suffered a blunt injury to the kidney producing a renal haematoma and renin-mediated hypertension. Both the patient and the arterial tension were controlled with angiotensin converter enzyme inhibitors (ACEI) (3).

Vanegas et al, in 2005, published a similar experiment to the Page one but with a murine model. They explained the development of hypertension because of interstitial nephritis secondary to low kidney blood input and displace the activation of renin as an accessory cause (4).

Page kidney has been recognized on clinical grounds for several decades. Page kidney is the result of an external kidney compression normally caused by subcapsular haematoma associated with arterial hypertension and occasionally kidney failure (5).

Kidney is a retroperitoneal organ that is surrounded by two anatomic envelopes. The external one, the Gerota's fascia, which is a large space and a large haematoma is needed to compress the kidney. The internal one, the kidney capsule, which has a potential space that allows only small amount of blood before compressing the kidneys and manifesting as hypertension or wor-

sening of the renal function (6). The causes of Page kidney may be divided in two groups. On the one hand the bleeding causes: due to trauma (motor vehicle accidents, contact sports, etc.), secondary to interventions (kidney biopsy, extracorporeal lithotripsy, surgery, etc.) and spontaneous bleeding (pancreatitis, anticoagulant therapy, tumors, etc). On the other hand there are non-bleeding causes as lymphoceles, large simple cysts, urinomas or retroperitoneal masses (6).

A recent review of the Page kidney cases reported in the literature showed that twothirds of the patients were men, average age was 38 years and average blood pressure at the time of diagnosis was 177/95 mm Hg. In the past, most cases of Page kidney were described secondary to an external trauma. Nowadays, the majority of the cases occurred in kidney allografts as a result of a complicated biopsy, with the consequent kidney worsening. In the cases of native-kidneys the most common preceding events were motor vehicle accidents and mass lesions (7).

Ultrasound is considered the gold standard as first diagnosis due to its accessibility, harmlessness and low cost. In addition it could be interesting in the identification of structural kidney disturbances, as well as the detection of perfusion abnormalities with the Doppler technique. The CT offers better images of the haematoma, blood input and urine elimination, and even the bleeding point. Radiation doses and use of intravenous contrast are the main disadvantages (8).

The objective of the treatment is the external compression releasing and the decreasing of the levels of arterial tension. When hemodynamically stable situation of the patient is achieved, the conservative management of the haematoma and the use of ACEI to control de arterial tension should be the best therapeutic option. If hypertension persists, the renal function deteriorates

or the haematoma is too large, the surgical management with haematoma exeresis must be considered. Percutaneous drainage is low invasive, however organized haematomas are not amenable to this mode of treatment and open exeresis or nephrectomy should be proposed. It is also described the exeresis by a laparoscopic way with positive results (9-11).

CONCLUSION

We present a patient who went to the emergency for right flank pain from hours of evolution, spontaneous and without a traumatic antecedent. Abdominal ultrasound was requested and subsequently an abdominal CECT. The CECT showed a right subcapsular haematoma which compressed the parenchyma, likewise there was also a lesion depending on the upper kidney pole unknown previously. Conservative management was decided, the patient was hemodynamically stable and the pain was well-controlled on admission in urology department. Only was remarkable the high levels of blood pressure registered in the following day with good response at ACEI. He was discharged at the 7th day and cited in six weeks in order of the blood pressure and the CT image control. CECT describes the persistence of the haematoma but in resolution phase, no nodular images in parenchyma are noticed.

Arterial hypertension is a sign of every Page kidney. It could be considered as essential hypertension in most of cases if there would not be a high grade of clinic suspicion or a traumatic antecedent. In this way, it is possible that Page kidneys were underdiagnosed in an important number of cases.

REFERENCES AND RECOMMENDED READINGS (*of special interest, **of outstanding interest)

1. Page IH. A method for producing persistent hypertension by cellophane. *Science* 1939; 89 (2308): 273-4.
2. Goldblatt H, Lynch J, Hanzal RF, Summerville WW. Studies on experimental hypertension: I. The production of persistent elevation of systolic blood pressure by means of renal ischemia. *J Exp Med* 1934; 59 (3): 347-79.
3. Engel WJ, Page IH. Hypertension due to renal compression resulting from subcapsular hematoma. *J Urol* 1955; 73(5):735-9.
- *4. Vanegas V, Ferrebuz A, Quiroz Y, Rodriguez-Iturbe B: Hypertension in Page (cellophane-wrapped) kidney is due to interstitial nephritis. *Kidney Int* 68:1161-1170, 2005
- **5. Haydar A, Rashed SB, Matthew P, David JA. Page kidney-A review of literature. *J Nephrol*. 2003; 16:329-33.
6. Mathew A, Brahmhatt B, Rajesh R, Kurian G, Unni VN. Page kidney. *Indian J Nephrol* 2009; 19(4):170-1.
- **7. Dopson SJ, Jayakumar S, Velez JCQ. Page kidney as a rare cause of hypertension: case report and review of the literature. *American Journal of Kidney Diseases* 2009; 54 (2): 334-39.
8. Montoya R, Lopez I, Guzman F, Llorente S et al. Riñón de Page: caso clínico posbiopsia en paciente trasplantado. Revisión etiología y terapéutica. *Nefroplus* 2010; 3 (2): 46-51.
9. Chung J, Caumartin Y, Warren J, Luke PP. Acute page kidney following renal allograft biopsy: A complication requiring early recognition and treatment. *Am J Transplant*. 2008; 8:1323-8.
10. Moriarty KP, Lipkowitz GS, Germain MJ. Capsulectomy: a cure for the page kidney. *Journal of Pediatric Surgery* 1997; 32 (6): 831-33.
11. Duchene DA, Williams RD, Winfield HN. Laparoscopic management of bilateral page kidneys. *Urology* 2007; 69(6):1208:e1-3.