

# Early Failure of Articular Surface Replacement XL Total Hip Arthroplasty

Garen D. Steele, MD,\* Thomas K. Fehring, MD,\* Susan M. Odum, MEd,†  
Anne C. Dennon, BS,† and Matthew C. Nadaud, MD‡

---

**Abstract:** The ASR (articular surface replacement) XL (DePuy, Warsaw, Ind) metal-on-metal hip arthroplasty offers the advantage of stability and increased motion. However, an alarming number of early failures prompted the evaluation of patients treated with this system. A prospective study of patients who underwent arthroplasty with the ASR XL system was performed. Patients with 2-year follow-up or any revision were included. Failure rates, Western Ontario and McMaster Universities Osteoarthritis Index (WOMAC) scores, and radiographs were evaluated. Ninety-five patients (105 hips) were included. There were 16 revisions. Thirteen (12%) were aseptic acetabular failures. Eight were revised for aseptic loosening; 4, for metallosis; 1, for malposition; 2, for infection; and 1, for periprosthetic fracture. Mean time to revision was 1.6 years (0.18-3.4 years). The ASR XL with a revision rate of 12% is the second reported 1 piece metal-on-metal system with a significant failure rate at early follow-up. This particular class of implants has inherent design flaws that lead to early failure.

---

Large diameter metal-on-metal articulations in total hip arthroplasty offers the theoretical advantage of improved stability and increased range of motion compared with smaller diameter bearings [1-4]. Another advantage of metal-on-metal articulations is the potential for lower wear rates and improved durability [5-8,10]. These proposed advantages have caused an increase in the use of large diameter metal-on-metal articulations worldwide. Many theoretical concerns still exist for metal-on-metal articulations. Metal ion levels, hypersensitivity, and pseudotumor reactions continue to be an area of ongoing research [11-18].

The ASR (articular surface replacement) XL total hip arthroplasty system by DePuy (Warsaw, Ind) was initially developed as an alternative to total hip arthroplasty. This total hip system offers a nonmodular metal-on-metal acetabular component, which was initially designed for hip surface replacements, paired with a large diameter femoral head.

The acetabular cup is less than a hemisphere, allowing for greater range of motion as well as a degree of bone conservation. The ASR XL head system was then developed, which allowed surgeons to use traditional femoral stems to be matched with larger femoral heads. Although the less-than-hemispherical acetabulum offers a greater theoretical range of motion, the preparation and insertion of a nonmodular cup introduce possible technical errors that may account for early failures.

Early failures of less than 2 years of large head metal-on-metal hip systems have been reported in another 1 piece metal-on-metal system [9]. Similarly, an alarming number of early failures were noted with this implant, prompting a review of patients implanted with the ASR XL system. The purpose of this study was to determine the clinical and radiographical outcomes for the ASR XL total hip arthroplasty.

## Methods

A retrospective review of a consecutive series of ASR implants was performed at 2 centers. Institutional review board approval was obtained by each institution. Cases were selected from institutional prospective total joint registries. All primary total hips performed with an ASR implant between 2006 and 2008 were included in the study. Patient age at the date of surgery and sex was recorded. Postoperative Western Ontario and McMaster Universities Osteoarthritis Index (WOMAC) scores were documented as well as surgical approach, cup size, and stem type. The primary outcome variable was success or

---

From the \*OrthoCarolina, PA, Charlotte, North Carolina; †OrthoCarolina Research Institute, Inc, Charlotte, North Carolina; and ‡Knoxville Orthopedic Clinic, Knoxville, Tennessee.

Submitted January 6, 2011; accepted March 13, 2011.

The Conflict of Interest statement associated with this article can be found at [doi:10.1016/j.arth.2011.03.027](https://doi.org/10.1016/j.arth.2011.03.027).

Reprint requests: Thomas K. Fehring, MD, OrthoCarolina, PA, 2001 Vail Avenue, Suite 200-A, Charlotte, NC 28207.

0883-5403/2606-0004\$36.00/0  
[doi:10.1016/j.arth.2011.03.027](https://doi.org/10.1016/j.arth.2011.03.027)

failure. *Failure* was defined as the need for revision surgery and the reason for revision was documented. Time to revision was calculated.

A radiographic analysis was performed on both the acetabular and femoral components. Because all of the femoral components were cementless, they were evaluated according to the fixation method of Engh et al [19]. Each implant was graded as solidly fixed, possibly loose, or loose. Because all acetabular components were cementless, the fixation classification system described by Moore et al [20] was used to grade the acetabular components as solidly fixed, possible loose, or loose. Abduction angles were evaluated from the anteroposterior (AP) pelvis radiographs. Those patients with abduction angles greater than 50° were separately evaluated for success or failure.

WOMAC scores were stratified to identify those patients with an unsatisfactory clinical outcome. A WOMAC score of less than 70 was arbitrarily chosen to identify such patients. Those unrevised patients with acetabular components radiographically graded as loose or those patients with a WOMAC score less than 70 were added to those patients already revised to give a total radiographic and clinical failure rate of the ASR XL system. Patients with documented femoral loosening were excluded from this calculation.

To minimize selection bias because of lost to follow-up, all patients with inadequate follow-up were contacted by mail and/or telephone for a clinical follow-up examination. When returning to the clinic was not possible, patient-reported outcomes including WOMAC scores and information about revision surgeries were obtained by telephone. Patients were contacted a minimum of 3 times before they were categorized as lost to follow-up.

Descriptive statistics, including median, mean, and frequency, were calculated. Independent *t* tests were performed to assess differences in normally distributed continuous variables between failures and successes. Mann Whitney *U* tests were used to determine differences between failures and successes for variables that were not normally distributed.  $\chi^2$  Tests were used for dichotomous data.

A total of 109 patients (120 hips) had a primary total hip with an ASR implant between January 2006 and August 2008. Of the 109 patients, there were 63 women and 46 men at an average age of 48 years (16-71 years). Of these 109, 14 patients (15 hips) were lost to follow-up. Therefore, the final data set includes 95 patients (105 hips) with a minimum of 2-year follow-up. There were 54 women and 41 men at an average age of 49 years (16-71 years), with an average follow-up of 37 months (22-50 months).

All total hip arthroplasties were performed by 5 fellowship-trained total joint surgeons at 2 institutions. Four of these surgeons, at the same institution, prescribe

the same postoperative analgesia and rehabilitation protocol. A standard posterior approach was used in 115 hips, and a direct anterior approach was used in the remaining 5 hips. All cups were pressfit, underreaming by 1 mm.

## Results

At an average of only 1.6 years (0.18-3.4 years), the overall revision rate in this consecutive series was 15% (16/105). Of these 16 revisions, 13 were aseptic acetabular component failures. Eight were revised for aseptic loosening, 4 were revised for metallosis, 2 were revised for infection, 1 was revised for a periprosthetic fracture, and 1 was revised due to acetabular implant malposition. Therefore, the aseptic acetabular component failure rate was 12% (13/105).

Of the 89 remaining unrevised hips (in 80 patients) with minimum 2-year follow-up (mean, 37 months), 11 (12%) had a postoperative WOMAC score below 70. Of the 11 with WOMAC scores below 70, 5 also had pain, stiffness, and function subscores below 70.

Of the 89 remaining unrevised hips, 3 had evidence of femoral loosening. Of the 86 remaining unrevised ASR XL patients, 6 had acetabular loosening and 11 had WOMAC scores below 70.

Therefore, if one combines the 12 hips that were revised for acetabular loosening or metallosis and those patients with a WOMAC score below 70 (11 hips) or patients with radiographic evidence of acetabular loosening (6 hips), the combined failure rate increases to 28% (29/105).

The average abduction in this series of patients was 41° (31°-57°). Four patients had abduction angles greater than 50° (52°, 52°, 55°, 57°, respectively). None of these patients has been revised or has a WOMAC score less than 70.

## Discussion

Metal-on-metal articulations have been heralded as a solution for wear and osteolysis inherent in metal-on-plastic articulations in young active patients [21]. An added benefit of this articulation is the ability to use large femoral heads, thus improving intrinsic hip stability [1-4]. The original ASR implant was designed as a surface replacement coupling a nonmodular cementless acetabular component, a resurfaced femoral head, and a metal-on-metal articulation.

Because both stability and wear properties of metal-on-metal articulations improve with increasing head size, a natural evolution of this design was applied to total hip arthroplasty. The ASR XL system with head sizes ranging from 39 to 63 was attractive to surgeons who wished to use extra large heads greater than 36 mm to both improve stability as well as improve wear characteristics. Unfortunately, the early results reported here suggest that this evolution may have been misguided.

Our study has some limitations. This was a retrospective multicenter study with multiple surgeons performing the surgery. Some variance in surgical technique



**Fig. 1.** Articular surface replacement acetabular component with insertion handle.

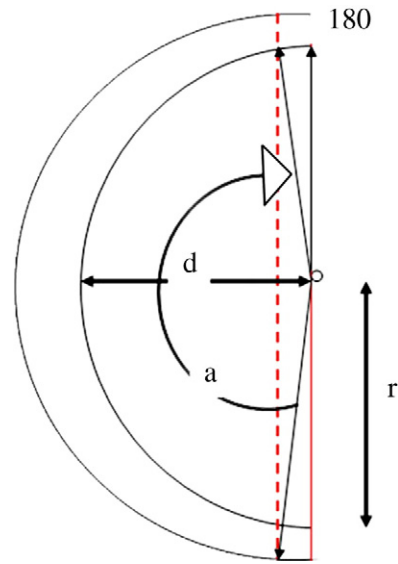
must be assumed. In addition, 15 patients were lost to follow-up. Because this was a retrospective study, no serum or urine ion measurements were prospectively made in this cohort of patients. Because we are reporting a consecutive series of patients, no learning curve period is accounted for. Possible technical errors with this system may have affected the results reported here. However, all surgeries were performed by high-volume fellowship-trained arthroplasty surgeons.

Design issues for insertion instrumentation as well as design issues of the acetabular component itself may have affected results. Because this is a 1-piece component, a central hole is not available to improve the tactile feel of insertion. Compared with a modular acetabular component, the ability to assess complete seating as well as adequate fit is compromised. Of course, no adjuvant screw fixation is possible in this nonmodular design (Fig. 1).

Design issues of the acetabular component itself may have compromised results. The ASR XL acetabular component has less than a 180° hemisphere ranging from 148° to 160° depending on size. Not only does this



**Fig. 2.** Insertion handle attaches to inner rim that decreases functional articular surface.



**Fig. 3.** In a hemispheric cup, the center of rotation is midpoint between the polar ends, therefore  $r = d$ . In a subhemispheric cup with a thickened dome and an inner rim cutout for the insertion device,  $r >> d$ , which forces the center of rotation outside the component and thus reduces the functional articular surface.

fact diminish the porous surface area available for fixation but also the porous coating did not extend all the way to the rim, further diminishing fixation potential in an area very critical for implant fixation (Fig. 2). Although hydroxyapatite was added to the porous coating to help improve osseous integration, the fact that extra large heads were used increased the frictional torque to initiate motion [22]. This may have been transferred to the bone prosthetic interface, further compromising osseous integration.

Because these implants were relatively thin at the rim (3.5-mm thickness in an ASR, 50-mm cup vs 5.25-mm thickness in a Pinnacle modular cup [DePuy]), the potential for elliptical deformation in a hard bone and equatorial seizing of the bearing may have inhibited bone ingrowth [23].

A final design issue that may have affected our 4 metallosis failures concerns what is termed the *functional articular surface*. A functional articular surface of 10 mm is felt to be necessary to optimize the wear characteristics of a metal-on-metal implant [24]. A component that is less than a hemisphere by definition has a diminished functional articular surface. Because the ASR XL insertion tool fits inside the acetabular component, this functional articular surface is diminished further. Therefore, a 48-mm ASR XL implant inserted at 45° of abduction functions like an implant placed at 59° of abduction. The resultant functional articular surface is significantly diminished (Fig. 3) [23]. Such relative positioning is below the functional articular surface limit that is necessary for the proper wear characteristics

of a metal-on-metal implant. This diminished functional articular surface can lead to edge loading, diminished lubrication, and subsequent metallosis. In addition, this implant has a variable thickness in the sagittal profile. It is thicker at the dome than at the rim in attempt to minimize deformation (Fig. 3). A disadvantage of the variable thickness of this design is that it moves the center of rotation of the femoral head out from the center of the acetabular component, further encouraging edge loading.

Our results are not dissimilar from those reported by Long et al [9], concerning the Durom acetabular component (Zimmer, Warsaw, Ind). In this study, there was a 15% revision rate within 2 years of implantation. It was postulated that similar design flaws lead to higher risks of early loosening with this system. Mechanically, the authors felt the preferential peripheral contact of the less-than-hemispheric cup caused micromotion and, hence, poor ingrowth. Combining the data Long et al reported as well as the results reported here raise concern for this class of similarly designed implants.

The ASR XL total hip results reported here should be compared with the ASR resurfacing results previously reported by Jameson et al [25,26]. In this study, they reported a 3.4% incidence of metallosis in ASR resurfacings that required revision to an alternate bearing. Aseptic loosening was not noted in this cohort at 3-year follow-up. The authors postulated that a subhemispheric design increased edge loading, which may have led to excessive metal wear. Why the investigators did not note similar loosening levels to those reported here is not understood.

## Conclusion

The purpose of our study was to determine the clinical and radiographic outcome of the ASR XL total hip system. Although the theoretical advantages of extra large heads are attractive, the 12% early aseptic revision rate and the 28% combined clinical and radiographic failure rates are clearly unacceptable. This implant is the second recently reported 1-piece metal-on-metal hip system with a significant failure rate at early follow-up. This particular class of implants, that is, 1-piece metal-on-metal acetabular components, may have inherent design characteristics that lead to early failure. Adequate preclinical trials may have identified some of the shortcomings of this class of implants before the marketing and widespread use of these implant ensued.

## References

- Berry DJ, von Knoch M, Schleck CD, et al. Effect of femoral head diameter and operative approach on risk of dislocation after primary total hip arthroplasty. *J Bone Joint Surg Am* 2005;87:2456.
- Cuckler JM, Moore KD, Lombardi Jr AV, et al. Large versus small femoral heads in metal-on-metal total hip arthroplasty. *J Arthroplasty* 2004;19(8 Suppl 3):41.
- Smith TM, Berend KR, Lombardi Jr AV, et al. Metal-on-metal total hip arthroplasty with large heads may prevent early dislocation. *Clin Orthop Relat Res* 2005;441:137.
- Hilton KR, Dorr LD, Wan Z, et al. Contemporary total hip replacement with metal on metal articulation. *Clin Orthop Relat Res* 1996(329 Suppl):S99.
- Dastane MR, Long WT, Wan Z, et al. Metal-on-metal hip arthroplasty does equally well in osteonecrosis and osteoarthritis. *Clin Orthop Relat Res* 2008;466:1148.
- Delaunay CP. Metal-on-metal bearings in cementless primary total hip arthroplasty. *J Arthroplasty* 2004;19(8 Suppl 3):35.
- Dorr LD, Hilton KR, Zhinian W, et al. Modern metal on metal articulation for total hip replacements. *Clin Orthop Relat Res* 1996;108.
- Dumbleton JH, Manle MT. Metal-on-metal total hip replacement: what does the literature say? *J Arthroplasty* 2005;20:174.
- Long WT, Dastane M, Harris MJ, et al. Failure of the Durom Metasul acetabular component. *Clin Orthop Relat Res* 2010;468:400.
- Long WT, Dorr LD, Gendelman V. An American experience with metal-on-metal total hip arthroplasties: a 7-year follow-up study. *J Arthroplasty* 2004;19(8 Suppl 3):29.
- Shahrdar C, Campbell P, Mirra J, et al. Painful metal-on-metal total hip arthroplasty. *J Arthroplasty* 2006;21:289.
- Langton DJ, Sprowson AP, Joyce TJ, et al. Blood metal ion concentrations after hip resurfacing arthroplasty: a comparative study of articular surface replacement and Birmingham Hip Resurfacing arthroplasties. *J Bone Joint Surg Br* 2009;91:1287.
- Jacobs JJ, Anastasia K, Doorn PF, et al. Cobalt and chromium concentrations in patients with metal on metal total hip replacements. *Clin Orthop Relat Res* 1996 (329 Suppl):S256.
- De Haan R, Pattyn C, Gill HS, et al. Correlation between inclination of the acetabular component and metal ion levels in metal-on-metal hip resurfacing replacement. *J Bone Joint Surg Br* 2008;90:1291.
- Savarino L, Granchi D, Ciapetti G, et al. Effects of metal ions on white blood cells of patients with failed total joint arthroplasties. *J Biomed Mater Res* 1999;47:543.
- De Smet K, De Haan R, Calistri A, et al. Metal ion measurement as a diagnostic tool to identify problems with metal-on-metal hip resurfacing. *J Bone Joint Surg Am* 2008;90(Suppl 4):202.
- Pandit H, Glynn-Jones S, McLardy-Smith P, et al. Pseudotumours associated with metal-on-metal hip resurfacing. *J Bone Joint Surg Br* 2008;90:847.
- Udomkiat P, Wan Z, Dorr LD. Comparison of preoperative radiographs and intraoperative findings of fixation of hemispheric porous-coated sockets. *J Bone Joint Surg Am* 2001;83-A:1865.
- Engh CA, Massin P, Suthers KE. Roentgenographic assessment of the biologic fixation of porous-surfaced femoral components. *Clin Orthop Relat Res* 1990;107.
- Moore MS, McAuley JP, Young AM, et al. Radiographic signs of osseointegration in porous-coated acetabular components. *Clin Orthop Relat Res* 2006;444:176.

21. MacDonald SJ, McAlden RW, Chess DG, et al. Metal-on-metal versus polyethylene in hip arthroplasty: a randomized clinical trial. *Clin Orthop Relat Res* 2003;282.
22. Schmidig G, Patel A, Liepins I, et al. The effects of acetabular shell deformation and liner thickness on frictional torque in ultrahigh-molecular-weight polyethylene acetabular bearings. *J Arthroplasty* 2010;25:644.
23. Griffin WL, Nanson CJ, Springer BD, et al. Reduced articular surface of one-piece cups: a cause of runaway wear and early failure. *Clin Orthop Relat Res* 2010;468:2328.
24. De Haan R, Campbell PA, Su EP, et al. Revision of metal-on-metal resurfacing arthroplasty of the hip: the influence of malpositioning of the components. *J Bone Joint Surg Br* 2008;90:1158.
25. Jameson SS, Langton DJ, Nargol AV. Articular surface replacement of the hip: a prospective single-surgeon series. *J Bone Joint Surg Br* 2010;92:28.
26. Langton DJ, Jameson SS, Joyce TJ, et al. Early failure of metal-on-metal bearings in hip resurfacing and large-diameter total hip replacement: a consequence of excess wear. *J Bone Joint Surg Br* 2010;92:38.