
◎原 著

Long-term administration of Clarithromycin for an asthmatic patient with mucosal abnormalities of sinonasal cavity

Takashi Mifune, Fumihiro Mitsunobu, Yasuhiro Hosaki, Kouzou Ashida, Hirofumi Tsugeno, Seishi Harada, Makoto Okamoto, Eiichirou Yumoto, Shingo Takada, Yoshiro Tanizaki

Division of Medicine, Misasa Medical Branch,
Okayama University Medical School

Abstract: We experienced a case of 59-year-old woman with intractable asthma, who had aspirin intolerance. Despite various treatments including systemic corticosteroid administration, she was often admitted due to severe asthma attacks. Furthermore, she had allergic rhinitis and sinusitis. Computed tomography (CT) scans of sinonasal cavity revealed marked thickness of nasal mucosa and air-fluid level in maxillary sinuses. Although her asthma symptoms such as wheezing and dyspnea were improved by administration of bronchodilator, systemic corticosteroids and beclomethasone disocyanate (BDI) accompanied with spa therapy, her peak expiratory flow (PEF) showed no improvement. After readmission due to asthma attacks, clarithromycin (CAM) administration for sinonasal disorders was started. The PEF value showed marked improvement after starting CAM administration, and pulmonary functions and bronchial hyperresponsiveness were also improved. It is suggested from her clinical course that CAM may have beneficial effects in asthmatic patients with sinonasal disorders.

Key word: bronchial asthma, allergic rhinitis, sinusitis, clarithromycin, peak expiratory flow (PEF)

Introduction

Bronchial asthma is often accompanied with allergic rhinitis or chronic sinusitis. It has been suggested that treatment of nasal allergy can help to reduce airway responses in some patients with asthma. Rachelefsky et al. examined the influence of medical therapy for sinusitis on airway response in 48 children with asthma. They showed that a marked improvement

in asthma symptoms, normalization of pulmonary function tests in 67% of patients, and discontinuation of bronchodilator use in 79% of patients were observed¹⁾. Similar results were reported by Friedman, et al.²⁾ and Slavin³⁾. However, the influence of sinonasal disease on pathogenesis of asthma is poorly understood. Two previous controlled studies have shown a reduction in asthma symptoms and improvement in bronchial hyperresponsiveness during pol-

len seasons with the use of intranasal corticosteroids^{4,5)} These data suggest that there may be a relationship in inflammatory events between the upper and lower airways, and that sinusitis may have influences on asthma exacerbation. In this article, we reported a case with aspirin-induced asthma whose pulmonary functions were improved by the treatment for sinusitis.

Case Report

A 59-year-old woman was admitted at the Misasa Medical Branch on October 28, 1997, because of asthma attacks. She had no dyspnea until the age of 39. At the age of 39, she was first aware of shortness of breath and wheeze. She had subsequently consulted a doctor, and was diagnosed as bronchial asthma. Since then, she had been admitted many times due to severe asthma attacks. Several years later, it was revealed that she had aspirin-intolerance and allergic rhinitis. For several days before this admission, she developed sore throat, cough and dyspnea, and on admission day, she had still severe asthma attacks.

Physical examination on admission revealed expiratory and inspiratory dry rales over the all lung fields and prolonged expiration on auscultation. The findings of blood chemistry and urinalysis were normal. The serum IgE level was 93.0 U/ml and specific antibodies for *Dermatophagoides pteronyssinus*, *Dermatophagoides farinae*, *Candida*, cat-skin and rice pollen were positive by radioallergosorbent test (RAST). Chest X-ray film showed normal findings. Systemic corticosteroids and bronchodilators were administered after admission. Improvement of asthma attacks was observed by the ninth hospital day. On the 18th hospital day she started to have complex spa therapy (swimming training at a hot spring, inhalation of iodine salt solution and fango therapy), with 7.5mg/day of systemic corticosteroid, inhaled glucocorticoid (beclomethasone) and bronchodilators administration. Results of pulmonary function test at the 30th hospital day were as follows; %VC 92.5%, FEV1.0% 57.5%, % \dot{V} 75 45.6%, % \dot{V} 50 16.0%, % \dot{V} 25

4.5% and %DLCO 158.7%. Despite gradual improvement of subjective symptoms, the peak expiratory flow (PEF) in the early morning did not improve (160-210L/min, average 194.5L/m). She was discharged on February 10,1998.

She was readmitted on March 11, 1998, because of severe asthma attacks. In the physical examinations, marked expiratory dry rales were heard over the lung fields on auscultation. Initial laboratory data on re-admission are shown in Table 1. The clinical course during readmission is illustrated in Fig.1. She was treated with systemic corticosteroid and bronchodilators were after admission. Although wheeze and dyspnea diminished by the ninth hospital day, prominent nasal and post-nasal discharge were not improved. Chest CT scans revealed neither signs of emphysema, chronic bronchitis nor middle lobe syndrome. Sinonasal CT scans revealed marked thickening of bilateral nasal mucosa and air-fluid level in bilateral maxillary sinuses (Fig.2). Results of pulmonary function test at the 16th hospital day were as follows; %VC 95.0%, FEV1.0% 67.8%, % \dot{V} 75 7.2%, % \dot{V} 50 26.7%, % \dot{V} 25 11.7% and %DLCO 123.5%. Bronchial responsiveness was measured using methacholine with an Astograph (Chest Corp., Tokyo, Japan), and she revealed bronchial hyperresponsiveness (Cmin 98 γ /ml, Dmin 0.0621 units). To control nasal and post-nasal discharge, clarithromycin (CAM) was administered on the 14th hospital day. After administration of CAM, nasal and post-nasal discharge gradually decreased, accompanied with improvement of the value of PEF metry. The pulmonary function test at the 77th hospital day improved as follows; %VC 100.4%, FEV1.0% 61.4%, % \dot{V} 75 63.3%, % \dot{V} 50 21.8%, % \dot{V} 25 12.0% and %DLCO 157.9%. Airway hyperresponsiveness also showed improvement after CAM administration (Cmin 390 γ /ml, Dmin 0.394 units)(Table 2).

Discussion

It has been noted since the time of Galen that an

Table 1. Laboratory Findings on Admission

Hematological findings		Blood urea nitrogen	9.1mg/dl
White blood cell	7600/mm ³	Creatinine	0.7mg/dl
Lymph	34.6%	Immunological findings	
Mono	5.5%	IgG	1215mg/dl
Neutro	59.9%	IgA	190mg/dl
Eosino	0.0%	IgM	166mg/dl
Red blood cell	421x10 ⁶ /mm ³	IgE(RIST)	93.0U/ml
Hemoglobin	12.9g/dl	IgE(RAST)	
Hematocrit	37.4%	D. pteromyssinus	class2
Platelet	22.9x10 ⁴ /mm ³	D. farinae	class2
Blood chemistry		HD1	class2
GOT	19U/l	HD2	class2
GPT	2U/l	Cat	class2
ALP	68U/l	Rice	class4
LDH	126U/l	Cortisol	1.1µg/dl
γ-GTP	26U/l	LTC4	10.5ng/5x10 ⁶ cells
Total cholesterol	188mg/dl	LTB4	119ng/5x10 ⁶ cells
Tnglycoide	59mg/dl		
Sodium	143.7mmol/l		
Potassium	3.98mmol/l		
Chloride	108.9mmol/l		

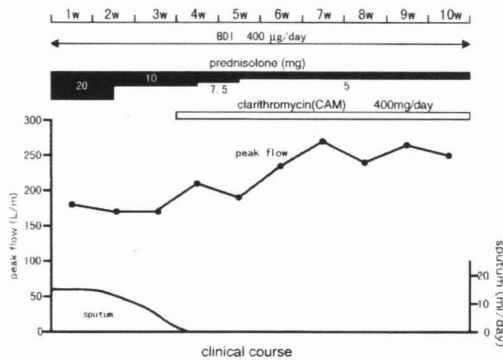


Fig. 1 clinical course of patient during readmission

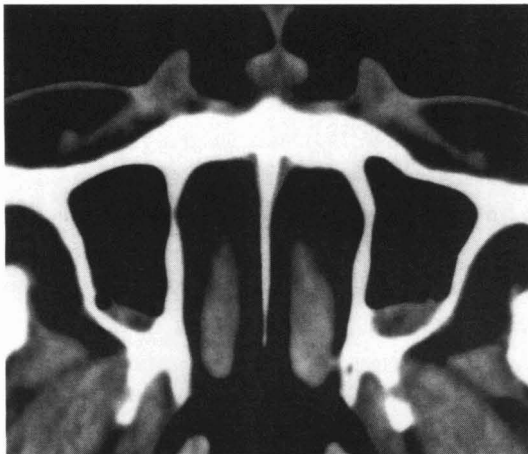


Fig. 2 CT scan of the sinus level. Marked thickness of nasal mucosa and air-fluid level in maxillary sinuses were observed.

Table 2. Changes of pulmonary functions and bronchial responsiveness before and after clarithromycin administration

	before	after
FVC	2210ml(92.5%)	2410ml(100.4%)
FEV1.0	1270ml(57.5%)	1480ml(61.4%)
MMF	0.74L/s(28.2%)	1.04L/s(39.5%)
PEFR	3.04L/s(55.1%)	3.25L/s(58.6%)
ṀV75	2.33L/s(45.6%)	3.24L/s(63.3%)
ṀV50	0.60L/s(16.0%)	0.82L/s(21.8%)
ṀV25	0.07L/s(4.5%)	0.19L/s(12.0%)
Cmin	98γ/ml	390γ/ml
Dmin	0.0621unit	0.394unit

association exists between nasal symptoms and chest disease⁶. More recently, Several studies have suggested that there is a link between upper respiratory tract disorders and bronchial asthma^{7,8,9,10,11}. Furthermore, many investigators have noted that treatment of upper airway disease often resulted in an improvement of asthma symptoms^{12,13}. In our case, administration of CAM for sinusitis and allergic rhinitis resulted in improvement of sinonasal discharge, pulmonary functions and bronchial hyperresponsiveness. The improvement of them may be due to the results of decrease of post-nasal discharge. Huxley et al. reported that pulmonary aspiration of nasopharyngeal secretions could be found in 50% of normal subjects and 70% of ill patients because of relaxation of the epiglottis during sleep¹⁴. In patients with chronic sinusitis, eosinophil infiltration in sinus mucosa has often been observed, and extracellular deposition of major basic protein (MBP) has also been shown to correlate with mucosal damage¹⁵. Eosinophils in post-nasal discharge aspirated into airways may induce the damage of bronchial mucosa and lead to asthma exacerbation. CAM has the effects that reduce naso-sinus secretion and increase mucociliary transportation¹⁶. Reduce of post-nasal discharge and aspiration into airway by CAM may lead to improvement of bronchial inflammation in our case. The improvement of asthma symptoms in our case may

also be due to the result of improved nasal filtering by administration of CAM¹⁷⁾.

Another proposed mechanism for the role of sinusitis as an aggravator of asthma is nasal-sinus-bronchial reflex. Kaufman and Wright showed an increase in lower airway resistance by blowing silica particles into the nasopharynx. In contrast, atropin injection inhibited lower airway response. Stimulation of neural receptors in the nose and sinuses activates trigeminal afferent pathways and produces bronchoconstriction through a vagal efferent neural arc¹⁸⁾. In our case, chronic inflammation in maxillary sinuses might be relieved by CAM administration, and stimulation of sinonasal receptors might decrease. Furthermore, CAM may inhibit cholinergic neuroeffector transmission in the human airway smooth muscle by reducing exocytotic release of acetylcholine from the nerve terminals¹⁹⁾.

CAM has also the effects of attenuation cytokine-induced endothelin-1 expression in human bronchial epithelial cells²⁰⁾, induction of eosinophil apoptosis²¹⁾ and protection of ciliated epithelium against oxidative damage inflicted by phospholipids-sensitized phagocytes²²⁾. Besides improvement of sinonasal symptoms, these effects for airway might result in improvement of pulmonary functions and bronchial hyperresponsiveness in our case.

From the course of this case, clarithromycin may have beneficial effects in asthmatic patients with chronic sinusitis or allergic rhinitis.

References

1. Rachelefsky GS, Kats RM and Siegel SC: Chronic sinus disease with associated reactive airway disease in children. *Pediatrics*, 73:526-529,1984.
2. Friedman R, Ackerman M and Wald E: asthma and bacterial sinusitis in children. *J Allergy Clin Immunol*, 74:185-189, 1984.
3. Slavin RG: Sinusitis in adults. *J Allergy Clin Immunol*, 81:1028-1032, 1988.
4. Reed CE, Marcoux JP and Welsh PW: Effects of topical nasal treatment on asthma symptoms. *J Allergy Clin Immunol*, 81:1042-1047, 1988.
5. Watson WT, Becker AB and Simons FER: Treatment of allergic rhinitis with intranasal corticosteroids in patients with mild asthma-Effect on lower airway responsiveness. *J Allergy Clin Immunol*, 91:97-101, 1993.
6. Daremberg C. *Oevres anatomique physiologiques et medicales de Galen*, Paris, vol 1. London:Bailliere Tindall, 1984.
7. Sotomayor H, Badier M, Vervloet D and Orehek J: Seasonal increase of carbachol airway responsiveness in patients allergic to grass pollen. *Am Rev Respir Dis*, 130:56-58,1984.
8. Aubier M, Levy J, Clirci C, Neukirch F and Hermann D: Different effects of nasal and bronchial glucocorticoid administration on bronchial hyperresponsiveness in patients with allergic rhinitis. *Am Rev Respir Dis*, 146:122-126,1992.
9. Juniper EF, Kline PA, Vanzielghem MA, Ramsdale EH, O'byrne PM and Hargreave FE: Effects of long-term treatment with an inhaled corticosteroid (budesonide) on airway hyperresponsiveness and clinical asthma in non-steroid-dependent asthmatics. *Am Rev Respir Dis*, 142:832-836, 1990.
10. Corren JC, Adinoff AD and Irvin CG: Changes in bronchial responsiveness following nasal provocation with allergen. *J Allergy Clin Immunol*, 89:611- 618,1992.
11. Annesi I, Oryszczyn MP, Neukirch F and Orvoen-Frija E: Relationship of upper airways disorders to FEV1 and bronchial hyperresponsiveness in an epidemiological study. *Eur Respir J*, 5: 1104-1110, 1992.
12. Welsh PW, Stricker WE, Chu-pin C, et al.: Efficacy of beclomethasone nasal solution, flunisolide, and cromolyn in relieving symptoms of ragweed allergy. *Mayo Clin Proc*, 62:125-134, 1987.
13. Slavin RG, Cannon RE, Friedman WH, Palitang E, Sundaram M: Sinusitis and bronchial asthma. *L*

- Allergy Clin Immunol, 66:250-257,1980.
14. Huxley EJ, Virodlov J, Gray WR and Pierce AK: Pharyngeal aspiration in normal adults and patients with depressed consciousness. *Am J Med*, 64: 564-568,1978.
 15. Pelikan Z: Role of intra nasal allergy in chronic maxillary sinusitis: diagnostic value of nasal challenge. *J Allergy Clin Immunol*, 86:484-491, 1990.
 16. Rubin BK, Druce H, Ramirez OE and Palmer R: Effects of clarithromycin on nasal mucous properties in healthy subjects and in patients with purulent rhinitis. *Am J Respir Crit Care Med*, 155:2018-2023, 1997.
 17. Wood RA and Eggleston PA: The effects of intranasal steroids on nasal and pulmonary responses to cat exposure. *Am Rev Respir Dis*, 151:315-320, 1995.
 18. Mcfadden ER: Nasal-sinus-pulmonary reflexes and bronchial asthma. *J Allergy Clin Immunol* 78:1-3, 1986.
 19. Tamaoki J, Tagaya E, Sakai A and Konno K: Effects of macrolide antibiotics on neurally mediated contraction of human isolated bronchus. *J Allergy Clin Immunol*, 95: 853-859,1995.
 20. Takizawa H, Desaki M, Ohtoshi T, et al. : Erythromycin and clarithromycin attenuate cytokine-induced endothelin-1 expression in human bronchial epithelial cells. *Eur Respir J*, 12:57-63, 1998.
 21. Adachi T, Mojima S, Hirata A et al. : Eosinophil apoptosis caused by theophylline, glucocorticoids and macrorides after stimulation with IL-5. *J Allergy Clin Immunol*, 98: S207-S215, 1996.
 22. Feldman C, Anderson R, Theron AJ, Ramafi G, Cole PJ, Wilson R: Roxithromycin, clarithromycin and azithromycin attenuate the injurious effects of bioactive phospholipids on human respiratory epithelium in vitro. *Inflammation*, 21: 655-665, 1997.

鼻腔・副鼻腔疾患を合併する気管支喘息症例に対するクラリスロマイシン投与の効果

御船尚志, 光延文裕, 保崎泰弘, 芦田耕三, 柘野浩史, 原田誠之, 岡本 誠, 湯本英一朗, 高田真吾, 谷崎勝朗

岡山大学医学部附属病院三朝分院内科

気管支喘息にアレルギー性鼻炎や副鼻腔炎を合併する症例は頻回に経験される。副鼻腔炎症状の増悪が喘息症状の増悪を引き起こす症例も存在し、鼻腔・副鼻腔における炎症が気管支喘息の病態と何らかの関係を持っていることが考えられる。今

回, 59 才の難治性アスピリン喘息症例を呈示する。副腎皮質ホルモンの全身投与を含めた様々な治療にも関わらず頻回に重篤な喘息発作を呈し、入退院を繰り返している症例である。アレルギー性鼻炎も合併し、CT では著明な鼻粘膜肥厚と上顎洞の鏡面形成が認められた。入院後の投薬や温泉療法によって呼吸困難は改善したが、ピークフロー値は上昇が認められないまま退院となった。再入院後、副鼻腔炎に対しクラリスロマイシン投与を開始したところ、ピークフロー値は著明に改善を示し、肺機能・気道過敏性も改善した。この症例のように、鼻腔・副鼻腔疾患を合併する気管支喘息症例に対しては、クラリスロマイシン投与が有効である可能性が考えられた。