

ESOPHAGEAL CATHETERIZATION STUDIES. I. THE MECHANISM OF SWALLOWING IN NORMAL SUBJECTS WITH PARTICULAR REFERENCE TO THE VESTIBULE (ESOPHAGO-GASTRIC SPHINCTER) \*

By JAMES H. PERT, MURRAY DAVIDSON, THOMAS P. ALMY AND MARVIN H. SLEISENGER

(From the Departments of Medicine and Pediatrics, The New York Hospital-Cornell Medical Center, New York, N. Y.)

(Submitted for publication October 29, 1957; accepted October 2, 1958)

Although studies of motility by means of an indwelling balloon have furthered understanding of the physiology of the esophagus, this method does not readily lend itself to the simultaneous measurements from multiple sites that are necessary for understanding the coordinate activities of deglutition (1-3). Several investigators were better able to study peristalsis in this organ by utilizing tandem systems with open-tipped catheters or transducers (4-10). Sanchez, Kramer and Ingelfinger first pointed out that the motor activity of the vestibule, or distal 2 to 5 cm. of esophagus, is different from that of the body (5). Since then there has been considerable discussion regarding the different motility patterns recorded from this area and how to interpret them (6, 9-11). A good method for the study of the vestibule should allow for sensitive, simultaneous recordings from closely approximated sites, be sufficiently comfortable to the subject to permit prolonged observations, and of course, yield reproducible results.

The purpose of this paper is to describe a technique which fulfills these criteria and to report on the results obtained in 15 observations of esophageal motility in 10 healthy adult subjects. The normal patterns described here will be compared (in subsequent communication) with those obtained in disease states and during drug administration.

METHODS AND MATERIALS

*Equipment.* The catheterization set consisted of six polyethylene tubes (Intramedic®, I.D. 0.055, O.D. 0.075,

\* This study was supported by a grant-in-aid of the G. D. Searle and Company, Chicago, Ill., the Ida and William Rosenthal Foundation, and Research Grant RG 4460 from the National Institutes of Health, United States Public Health Service.

P.E. 2000)<sup>1</sup> cut in three foot lengths and mounted side by side. The catheters were sealed at their distal ends to a metal gastric bucket so that in effect they represented a single tube with six separate lumina. Lateral openings, 2 mm. in diameter, were made at fixed intervals from the gastric tip and marked with radiopaque thread (Figure 1).

The catheters were filled with water and pressure changes were transmitted through these columns to three Sanborn electromanometers and a four-channel Sanborn polyviso recorder. Details of the operation of the de-

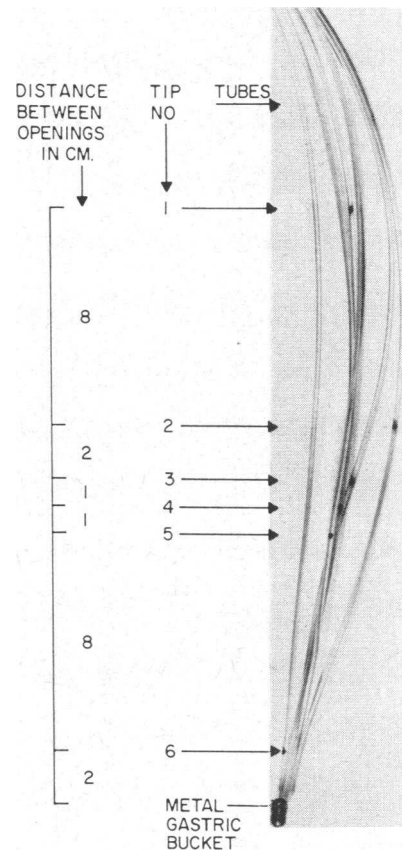


FIG. 1. ESOPHAGEAL CATHETER SET

<sup>1</sup> Obtained from Clay-Adams, Inc., New York, N. Y.

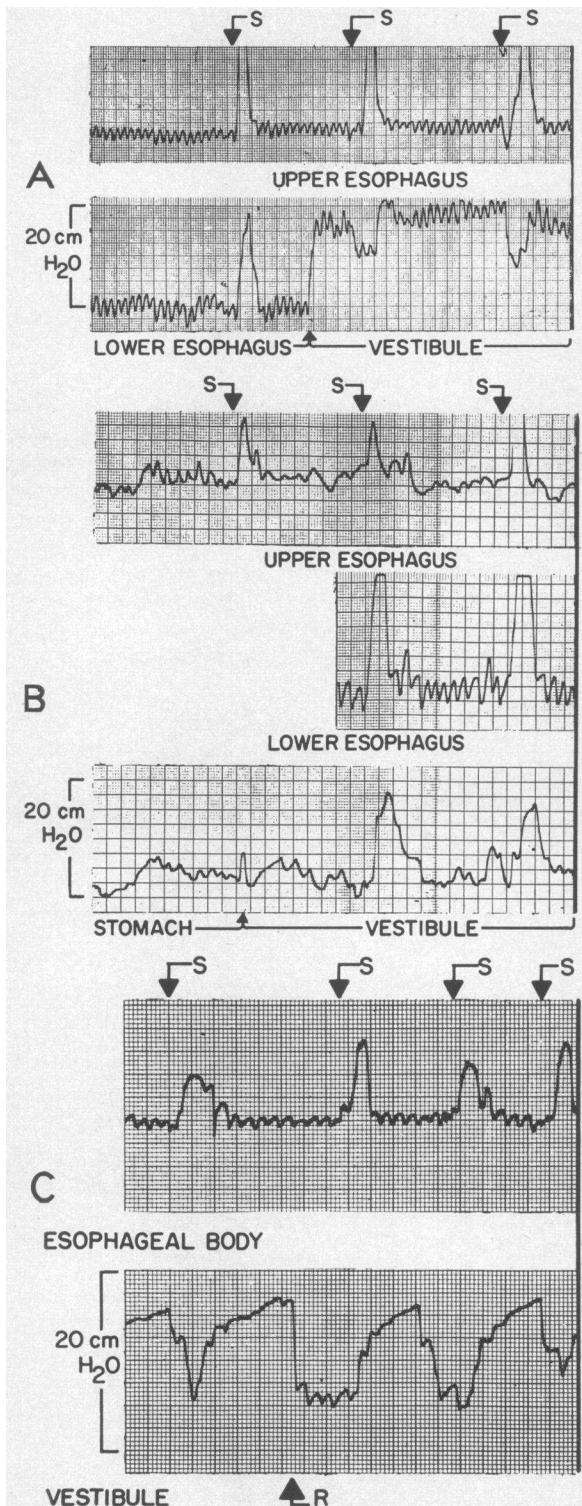


FIG. 2. EFFECT OF RESTING PRESSURE IN THE VESTIBULE ON MOTILITY DURING SWALLOWING

A. The initial portion of Record A shows a simultaneous recording from the upper and lower esophageal body.

detecting and recording apparatus and of the connections between catheters and these instruments were previously described (12). The records were standardized at 20 cm. H<sub>2</sub>O full scale with a paper speed of 1 mm. per second, or for higher pressures, at 40 cm. H<sub>2</sub>O and 0.5 mm. per second.

The scale on the figures indicates magnitude of pressure change without reference to a zero pressure. This permits full use of the scale and depicts accurately the pressure gradients between segments, which are the determining factors in the movement of the bolus. The method also eliminates the additional error introduced by comparing measurements to atmospheric pressure. This is sometimes inaccurately referred to as "absolute pressure," but is in fact another method of expressing relative pressure but in reference to an extraneous variable—atmospheric pressure.

An important feature of the apparatus was the interposition of three 3-way stopcocks between the six catheters and the connections to the electromanometers (Figure 3). To each of these, two catheters were attached. By switching the stopcock connections, it was possible to select the desired sites without moving the catheters. Such switching introduced no significant difference in the accuracy of interpretation of pressure changes when this maneuver was confined to tips Nos. 3, 4 and 5, which were positioned 1 to 2 cm. apart. In this manner, pressure in the vestibule relative to that in the stomach or in the body of the esophagus could be determined at any time by changing from the recording tip in the vestibule to one in the body above or one in the stomach below. Also, switching aided in locating the terminal segment. Vestibular pressure relative to gastric or body pressure was frequently ascertained before the effect of swallowing was studied (Figure 2).

To record the pressure exerted by the closed organ, a modification of the pump described by Lorber and Shay

By switching the stopcock from the lower esophageal tip to a catheter located 2 cm. below, a vestibular pattern is recorded with a resting pressure about 20 cm. over the pressure in the esophageal body. Note that with this elevated resting pressure the entire response of this segment to swallowing is a sustained fall in pressure lasting 8 to 10 seconds.

S↓, swallow; ↑, switching of recording catheter to vestibule.

B. In Record B, the bottom tracing shows gastric motility. By switching the stopcock to a tip 2 cm. higher, a vestibular pattern is recorded. In this instance there is virtually no difference in resting pressure between the stomach and the vestibule. Note that during swallowing the major component of the vestibular response consists of a positive pressure wave.

C. In Record C, the initial portion of the vestibular record shows an elevated resting pressure and relaxation during swallowing. There is a spontaneous relaxation of resting pressure indicated by R, and at this lower resting pressure the response to swallowing consists of a positive pressure wave.

(13) and Davidson, Sleisenger, Almy and Levine (12) was employed. This pump maintained a flow of water through the catheters at the rate of 3 ml. per hour (Figure 3). The effect of this flow upon the form of the pressure tracing recorded from the vestibule was tested in five experiments with four subjects, with two catheters placed at the same level. No significant differences were observed on comparison of records obtained with and without the pump except for more frequent loss of the usual phasic activity associated with respiration when the pump was not employed. This indicates that the replacement by the pump of the small amounts of fluid being lost at the dependent tip of the catheter diminishes the possibility of damping in the pressure transmission, because of air bubbles.

The relationship of the pump to the responsiveness of the pressure detecting system under conditions when the recording tip is occluded, as would exist when a sphincter is closed around the catheter, is seen in Figure 4. The figure illustrates the effect on the pressure record when the tip of a single catheter of the type used in the studies was manually occluded with the pump turned on and off, while the catheter was connected to the pump and electromanometer. During simultaneous recording at the same level, no change in the form of the record was produced in the second catheter when the pump was turned on or off in the first catheter. This indicates that these pressure fluctuations are probably not the result of pumping water into the small closed space of the vestibular lumen.

When the diameter of our recording catheter was increased and it was made more rigid by fastening the tubes together with an elastic band, pressure changes were diminished and fluctuations in the resting pressure of the sphincter were minimized.




FIG. 3A. PUMP ASSEMBLY WITH THREE 3-WAY STOPCOCKS FOR ATTACHMENT OF THE ESOPHAGEAL CATHETER SET

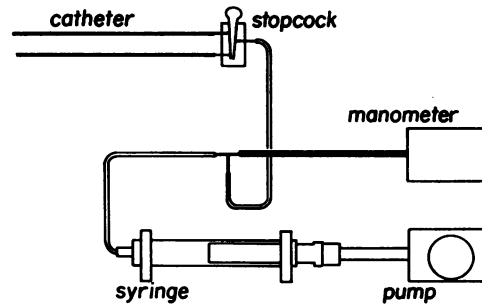


FIG. 3B. DIAGRAMMATIC REPRESENTATION OF FIGURE 3A

In an effort to determine if any component of the wave forms was caused by the flow of water past the tips during deglutition, a special set of catheters was prepared. Three polyethylene catheters were attached together, one with a lateral opening, one with an end opening directed caudad, and one with an end opening cephalad. All openings were at the same level. Motility tracings demonstrated that the flow was too slow to have any detectable influence on the pressure waves and that the recording from the lateral opening was identical to those from the catheters with end openings.

A pneumograph placed around the chest of the subject and connected to the fourth channel served as a check on the effect of respiration, coughing, talking and so forth upon the recording.

*Procedure.* In the fasting state and without anesthesia or premedication, the subject swallowed the catheters which were positioned fluoroscopically so that the gastric tip (No. 6) was in the body of the stomach and No. 5 opening was about 2 cm. below the diaphragm. Because the motility of this segment was found to be different from that of the stomach, it was considered to be

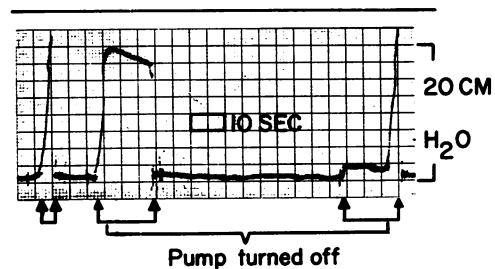


FIG. 4. EFFECT OF SUDDEN OCCLUSION OF CATHETER OPENING ON PRESSURE RECORD

Periods of catheter occlusion are marked by arrows. Note that when catheter is occluded with pump on, there is marked rise in pressure and prompt return to baseline with release of occlusion. During occlusion the pressure falls slowly when pump is turned off (second complex). Later, with pump still off, occlusion produced only slight rise in pressure; however, when the pump was again turned on, a sharp rise in pressure is recorded (final complex).

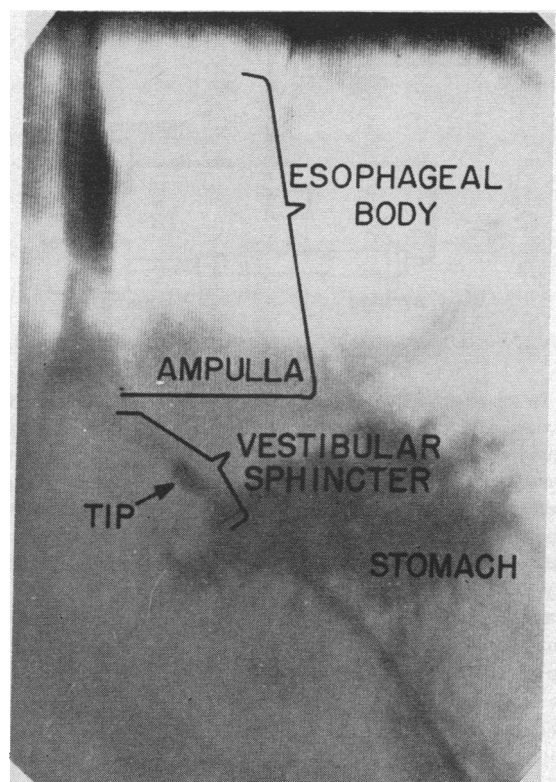


FIG. 5A. SPOT FILM ILLUSTRATING LOCALIZATION OF TIP INFRADIAPHRAGMATICALLY IN STUDIES OF THE TERMINAL SEGMENT OF ESOPHAGUS

esophagus. Miokon<sup>2</sup> was injected into the catheters and their positions demonstrated fluoroscopically and by spot films (Figure 5).

The respiratory tracing also aided in localizing the openings. Above the diaphragm, inspiration caused a decrease in intraesophageal pressure and was registered as a downward deflection of the recording needle. Conversely, normal inspiration caused the infradiaphragmatic catheter to record an upward deflection as did gentle manual pressure over the stomach. A recording tip at the level of the diaphragm, however, described a respiratory record of lower amplitude which was out of phase with both of these. In the infradiaphragmatic esophagus, a deep breath produced an immediate upward deflection followed by a rapid downward deflection as the diaphragm passed caudad to the catheter tip (Figure 6).

Although preliminary observations indicated that no appreciable differences could be observed when patients sat or when they reclined, the studies were performed with the patient in the sitting position because this is the usual body position during swallowing. Continuous aspiration of saliva with a catheter situated beyond the cricopharyngeus reduced involuntary swallowing, but during experimental observations this was not carried out since

<sup>2</sup> Miokon<sup>®</sup> was generously supplied by W. R. Armstrong. Mallinckrodt Chemical Works, St. Louis, Mo.

the effect of involuntary as well as of voluntary swallowing was of interest. The effects of coughing, retching, belching, swallowing saliva and deep inspiration were noted on the tracings.

To study deglutition, the subject was given 10 ml. of water to be held in the mouth and swallowed on command. Continuous pressure measurements were made over periods of one-half to three hours. In the analyses of all records, the presence or absence of each component was noted as were the duration and maximum amplitude of the complex.

## RESULTS

Both during swallowing and in the resting state there are characteristic wave forms of the upper eight-ninths (body) and lower one-ninth (vestibule) of the esophagus (Figure 7).

### *Resting state*

In the resting state only respiratory movements are discernible in the body. The vestibular segment may exhibit a relatively high resting pressure (Figures 2A and 8B) or a changing tone (Figures 2C and 8C). Pressure usually varies between 10 and 40 cm. H<sub>2</sub>O but may reach even 100 cm. H<sub>2</sub>O over resting gastric pressure. By noting the distance between the tips recording this characteristic pattern, usually Nos. 3, 4 and 5 (Figures 1 and 7), the length of this segment was found to vary from 2 to 5 cm. with an average in five normal subjects roughly estimated at 2.7 cm.

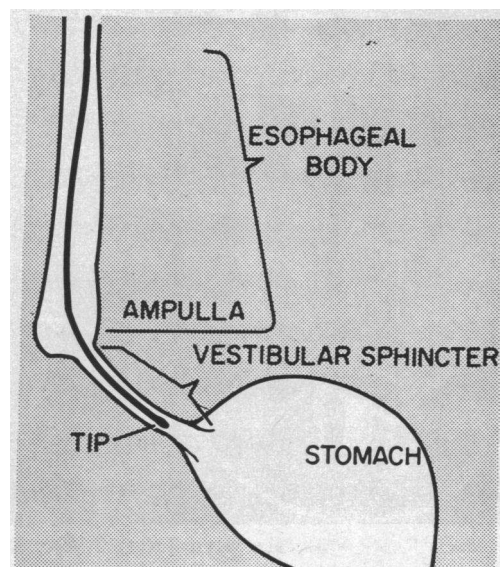


FIG. 5B. DIAGRAMMATIC REPRESENTATION OF FIGURE 5A

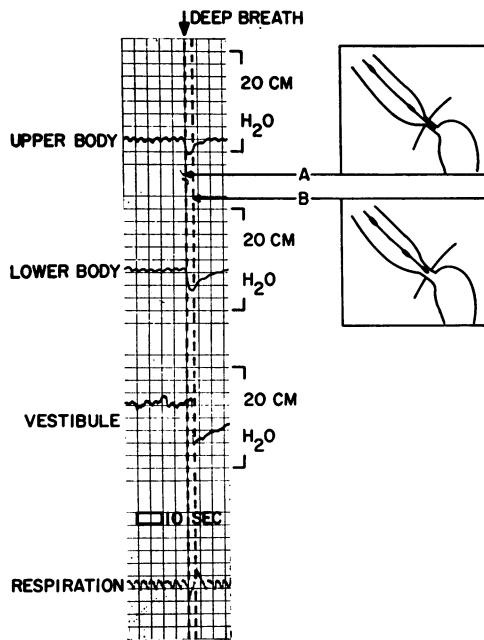


FIG. 6. EFFECT OF A DEEP BREATH

The respiratory record aids in localizing the recording tips. The vestibule does not register fall in pressure until the diaphragm has passed caudad to the recording tip during deep inspiration.

*Swallowing*

The usual wave form of the esophageal body during swallowing has five recognizable components (Figure 7). Component 1 occurs during the sipping of a mouthful of water; if, however, the subject retains liquid in his mouth prior to swallowing, this wave will not appear. Under the conditions used in these studies, it appears that this wave is caused by the involuntary inspiration which occurs with sipping. Our interpretation is in agreement with others that Wave 2 is related to the contraction of the pharyngeal muscles. It is transmitted to the esophageal body tracing via the bolus. It seems probable that Component 3 represents a summation of the decline in Wave 2 and the increase in pressure of Wave 4 and thus appears as a plateau. The major component, Wave 4, represents peristaltic contraction and usually has a smooth, bell-shaped contour. It travels at the average rate of 2.5 cm. per second (1.9 to 5.5 cm. per second) and, with the recording system used, attains a pressure of 15 to 20 cm. water. Its duration is 8 to 10 seconds. Occasionally it reaches a height of 25 cm. water and, rarely, 40

cm., and may last as long as 18 seconds. Deflection 5 represents the effect of respiration. This type of deflection, therefore, may occur in any part of the complex.

With the onset of deglutition, there is a brief relaxation of the vestibule, the degree of pressure drop being in part dependent upon the resting pressure (Figures 2 and 8). Thus, in some instances the relaxation was not apparent when the difference between resting pressure in the vestibule and stomach was relatively small even though the position of the recording tip in the vestibule was established by both manometric and radiologic criteria (Figures 2B and 8B). Fluoroscopic examination will show that some material may be passed into the stomach at this time. This probably represents a mechanism for emptying the esophagus before the bolus reaches the segment. As the peristaltic wave travels down the body,

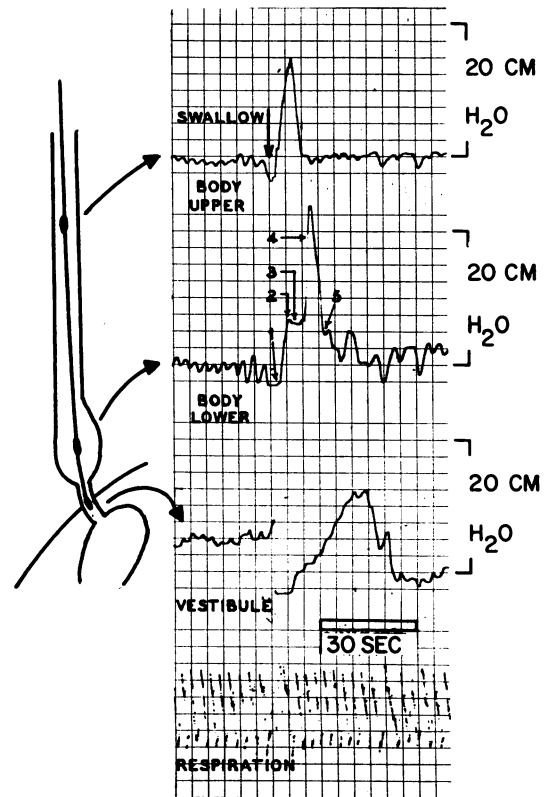


FIG. 7. PRESSURE CHANGES IN NORMAL SWALLOWING

This is a multiple tip recording demonstrating pressure changes in the body and vestibule during the swallowing of water. Components 1 through 5 of complex are described in text.

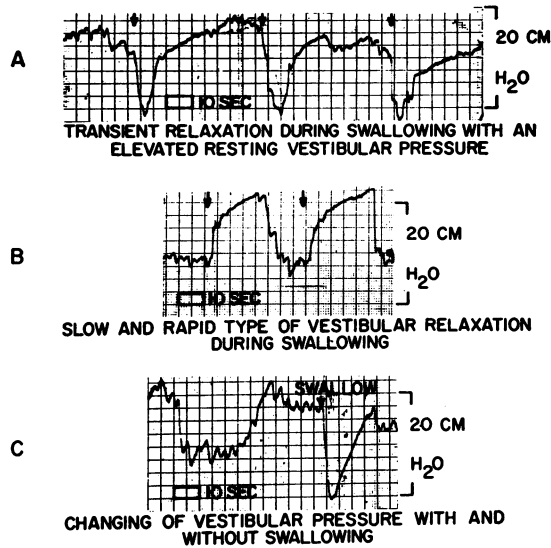


FIG. 8. DIFFERENT TYPES OF ACTIVITY OF THE VESTIBULAR SPHINCTER

These tracings were recorded from three different normal individuals, and illustrate the types of pattern which may be observed in any normal subject. Assessment of vestibular pressure before swallows as "high" or "low" is in reference to either pressure in the gastric fundus or esophageal body (Figure 2). Scale indicates magnitude of pressure change. Swallowing occurs at arrows only.

A. With a high resting vestibular pressure, swallowing frequently produces a single relaxation with a return to the elevated baseline.

B. Note that there is no initial relaxation with the onset of each of two swallows. This is observed when the resting pressure at the time is only slightly more than gastric pressure. The ensuing pressure rise may be terminated slowly (first swallow) or rapidly (second swallow).

C. Spontaneous changes in the resting vestibular pressure are illustrated. The relaxation which occurred with swallowing is indicated by the arrow.

the pressure in the vestibule gradually rises to 5 to 20 cm. water and lasts from 5 to 30 seconds. This rise is terminated with a sudden drop in pressure in 80 per cent of studies. In the remaining 20 per cent, especially when the vestibular tonus at the time of swallowing is high, the initial decline is of long duration and constitutes the entire complex (Figures 2A and 8A).

A comparison of the slopes of contraction and subsequent relaxation in the vestibule following a swallow showed that the rate of relaxation was 5 to 10 times as fast as that of contraction, a

pressure drop of 20 cm. water often occurring in one second. No relationship between the two slopes in any given complex is seen when the two slopes are plotted against each other and the gradient sum test applied.

Moreover, the rates of fall in pressure in the vestibule which followed periods of contraction varied among individuals and were different at various times in the same normal subject (Figure 8B). The rapid decline in pressure may be due not to sudden relaxation of the vestibular musculature, but to the rapidity of equilibration of pressures in the distal portion of vestibule and the stomach at the time the lumina of these organs are in continuity.

#### DISCUSSION

These studies confirm the previous work of others that there are two separate functional segments of the normal human esophagus: the body (upper eight-ninths) and the vestibule (lower one-ninth) (5, 6, 8, 10). Also, our observations and interpretations of the motility characteristics of the body associated with deglutition are for the most part in agreement with those of others (4, 5). While changes in vestibular pressure, particularly with swallowing, have been shown previously, our measurements demonstrate greater fluctuation of pressure in this segment, particularly during rest, than previously noted. Fluctuations in resting pressure do not appear to be caused by shifting of the recording tip out of the vestibule, because such pressure changes may be seen to occur simultaneously when recording with closely placed tips in this segment. Similarly when recording within 1 cm. above or below this segment, the baseline continues to show the resting pressure of the esophageal body or stomach while the vestibular tracing shows these changes. Further clarification of such problems will require simultaneous catheterization and cineradiographic investigations. Another difference has been our finding that the motility of the vestibule during deglutition is in part dependent upon its pressure relative to that in the stomach or lower esophagus at the time of the swallow. This gradient, readily noted in the same recording channel by switching from vestibule to these adjacent segments, varied greatly, but pressure was al-

ways equal or higher in the vestibule. This characteristic fluctuation in resting pressure and its influence upon pressure changes during deglutition certainly are consistent with sphincteric activity.

Fyke, Code and Schlegel, using a single transducer, demonstrated slightly higher resting pressure in the vestibular segment than in the stomach. With composite tracings recorded by withdrawing this catheter, and also from recordings made with open-tipped catheters in tandem, these authors demonstrated not only that relaxation occurred in this area with deglutition, but also that there was a rise in pressure above baseline for about 13 seconds thereafter. Analysis of their tandem record shows a fluctuation of 40 cm. H<sub>2</sub>O in the vestibule during deglutition. They concluded that this behavior warranted designation of this segment as the "esophago-gastric sphincter" (10). Creamer, Fyke, Code and Olsen have reported similar findings with an electromagnetic transducer or an open-tipped catheter connected to a manometer (9). As further evidence, Fyke and co-workers cited the fact that pressure in this area relative to fundic pressure became greater in the head-down position (10).

Sanchez and associates, using open-tipped, water-filled catheter and electromanometers, have reported that the vestibule demonstrated motor behavior different from the body of the organ. Later, Ingelfinger mentioned "receptive relaxation of the vestibule with swallowing" (14). More recently, Fleshler, Hendrix, Kramer and Ingelfinger working in the same laboratory, have reported that there is an elevated resting pressure which disappears with or immediately after onset of body peristalsis (15). In addition, this segment resisted hydrostatic force. From these findings the authors concluded that the vestibule behaves as a sphincter. Our studies also indicate that the vestibule operates as a sphincter capable of rapid, vigorous contraction and relaxation and warrants designation as the "esophago-gastric sphincter."

Rapid changes in pressure in any short segment of gut pose two problems in recording, particularly when the walls are in apposition to each other and the lumen is completely obliterated. One is maintenance of the recording tip in the

area for prolonged periods, and the other is the reliability of the recording, even if one is certain that the recording tip has not been dislodged. The first problem is largely solved by the catheter system employed in these studies which permits rapid localization of the sphincter without moving the catheter.

Since the vestibule may often be only 2 cm. in length, the generation of high pressures will tend to displace any catheter whose terminus is in the area, especially if there is a bulky tip at its end. As previously noted, bulkiness of catheters affects accuracy of pressure recording. It is also probable that a sudden increase in tone will dislodge any contents of the lumen, including a catheter tip, into the body of the esophagus above or into the stomach below. Frequent movement of the catheters by the observer to assure proper positioning may also cause retching or coughing which may displace the tips.

These difficulties are largely obviated by the six-tube system with closely approximated lateral openings, which makes possible a set of catheters of uniform diameter free of bulky recording tips, the terminus of the system residing in the stomach. Discomfort and retching are thus minimized. In addition, by means of switching the stopcock settings between the closely approximated lateral openings, small shifts in position can be adjusted for, and continuous recording for several hours is possible without moving the tubes. In this way one is better able to characterize and record continuously the motor behavior of the distal 2 to 5 cm. of the esophagus.

The sustained obliteration of the lumen which occurs at a sphincter interferes with reliable recording and is not easily obviated by changing the catheter design. Even assuming that one is recording constantly from the sphincteric region, the deficiencies of the measuring system have to be taken into account. In other hollow viscera the open-tipped catheters attached to the electromanometers always reside in a fluid-filled loop. Changes in pressure exerted on the fluid in the lumen are, therefore, transmitted through the catheters. In a sphincter, however, if all the gas or liquid is squeezed out when the lumen is obliterated, there is no medium on which pressure can be exerted. Instead, the opening of the catheter becomes

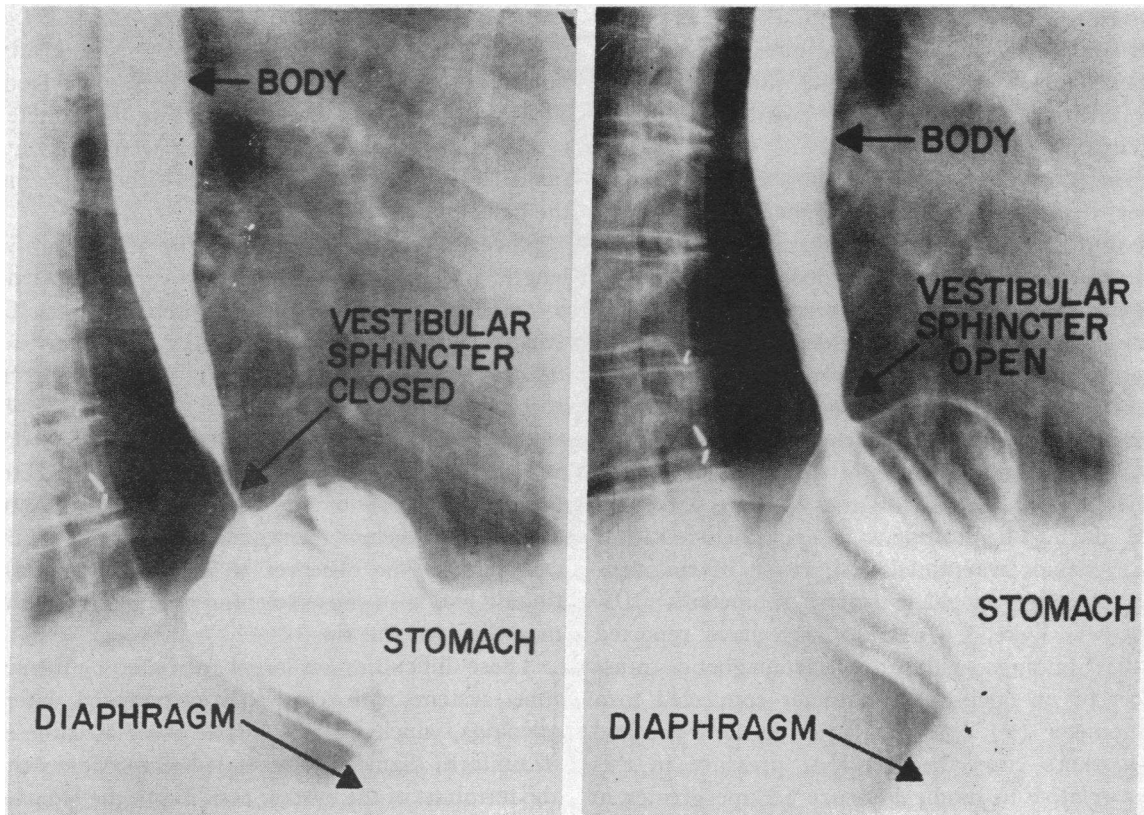


FIG. 9. A BARIUM FILLED SLIDING HIATUS HERNIA, ILLUSTRATING THAT THE SPHINCTERIC ACTION IS INDEPENDENT OF THE DIAPHRAGM

plugged at its distal end as the mucosa of the sphincter occludes it, or even protrudes into it.

The electromanometer is designed to register pressure changes induced at the end of a catheter to which it is attached by means of small volume displacements of the liquid in the system. Once the opening of a catheter becomes completely occluded by a "membrane" such as the mucosa of the obliterating wall, there may be failure of the electromanometer to register the exact height of the tonus change in the musculature, since there will be no displacement of liquid after the time of complete occlusion of the tip. However, if the system employs a constant infusion pump, a rise in pressure will be recorded since fluid is entering at the proximal end without any distal escape. This rise can only reach the level of that exerted at the distal opening by the sphincteric musculature. If it exceeds this level, it would force the mucosa away from the orifice, causing fluid to escape, and the pressure in the catheter could go

no higher. Thus, the pump makes possible a much closer approximation to the actual pressure being exerted by a segment contracting strongly enough to produce occlusion. Furthermore, even when the tip is not occluded, the pump tends to keep the system continuously free of the cushioning effect of air bubbles.

The ability to record pressures from this short segment over long periods makes it possible to study the area in greater detail and to observe the coordinate action of the proximal and distal esophagus during the resting state, swallowing and drug administration. It is also possible to differentiate the sphincter pattern from the effect of the diaphragm by recording above, at and below the diaphragm simultaneously.

Aside from its pattern of contraction and relaxation during deglutition, there is other evidence that the vestibule constitutes an intrinsic sphincter. A short, contractile segment at the junction of the esophagus and the stomach may be observed



fluoroscopically and has been clearly demonstrated by Wolf and co-workers with cineradiography (16). Figure 9 shows representative roentgenograms to illustrate that the action of this segment is independent of the diaphragm. In the case illustrated, pressure studies of the vestibule showed a normal resting tone and a coordinated response to deglutition.

This physiologic sphincter cannot be readily identified morphologically as a localized muscular ring. In his careful study, Lerche (17) succeeded in finding a small band of muscle, but this was microscopic in size. The ease of passage of a bolus through this segment is attributable to reflex relaxation and this behavior is more consistent with the behavior of an intrinsic sphincter than of a valve. The relationship of the sling action of the right crus of the diaphragm (18) to the function of the intrinsic sphincter has not been evaluated by the present method. However, this sling action is probably unnecessary for, and unrelated to, normal sphincteric activity. Under physiological conditions the respirations occur more frequently than do the openings and closings of the sphincter. In addition, breath holding has little influence on the measurements of sphincteric activity, which also continues in the presence of hiatus hernia (Figure 9).

#### SUMMARY

1. A technique of esophageal catheterization is described for measuring the motility of the esophagus. The method employs electromanometers, a constant infusion pump, and a specially prepared set of six catheters connected to three 3-way stopcocks. The advantages of this system for pressure measurements from a sphincter are detailed.

2. The pattern of pressure changes obtained from the vestibule is different from that of the body of the esophagus both at rest and during deglutition, indicating that each of these is a separate functioning segment.

3. At rest, there are changing tonus levels in the vestibule, often with sudden generation or release of high pressures. These patterns are independent of those seen in the body of the esophagus

and influence the type of response obtained in this segment during swallowing.

4. At the onset of swallowing, the vestibule briefly relaxes and, as peristalsis reaches this segment, a positive pressure wave is developed, following which relaxation again occurs. However, if vestibular resting pressure closely approximates that in the stomach, this initial relaxation does not occur. Conversely, when resting pressure is high, the drop in pressure is greater and so prolonged as to comprise the entire vestibular complex.

5. These motor patterns at rest and during swallowing indicate that the vestibule behaves as an intrinsic sphincter and should be referred to as the esophago-gastric sphincter.

#### REFERENCES

1. Kramer, P., and Ingelfinger, F. J. Motility of the human esophagus in control subjects and in patients with esophageal disorders. *Amer. J. Med.* 1949, 7, 168.
2. Kramer, P., and Ingelfinger, F. J. Esophageal sensitivity to mecholyl in cardiospasm. *Gastroenterology* 1951, 19, 242.
3. Sleisenger, M. H., Steinberg, H., and Almy, T. P. The disturbance of esophageal motility in cardiospasm: Studies on autonomic stimulation and autonomic blockade of the human esophagus, including the cardia. *Gastroenterology* 1953, 25, 333.
4. Butin, J. W., Olsen, A. M., Moersch, H. J., and Code, C. F. A study of esophageal pressures in normal persons and patients with cardiospasm. *Gastroenterology* 1953, 23, 278.
5. Sanchez, G. C., Kramer, P., and Ingelfinger, F. J. Motor mechanisms of the esophagus, particularly of its distal portion. *Gastroenterology* 1953, 25, 321.
6. Ingelfinger, F. J., Kramer, P., and Sanchez, G. C. The gastroesophageal vestibule, its normal function and its role in cardiospasm and gastroesophageal reflux. *Amer. J. med. Sci.* 1954, 228, 417.
7. Hightower, N. C., Jr., Olsen, A. M., and Moersch, H. J. A comparison of the effects of acetyl-beta-methyl-choline chloride (mecholy) on esophageal intraluminal pressure in normal persons and patients with cardiospasm. *Gastroenterology* 1954, 26, 592.
8. Sleisenger, M. H., Davidson, M., Pert, J. H., and Almy, T. P. Recent advances in physiology of the esophagus. *N. Y. St. J. Med.* 1955, 55, 2747.
9. Creamer, B., Fyke, F. E., Jr., Code, C. F., and Olsen, A. M. Intraluminal pressures at the esophago-gastric junction in healthy persons and in patients with cardiospasm (achalasia of the cardia). *Clin. Res. Proc.* 1956, 4, 130.

10. Fyke, F. E., Jr., Code, C. F., and Schlegel, J. F. The gastroesophageal sphincter in healthy human beings. *Gastroenterologia (Basel)* 1956, **86**, 135.
11. Proceedings of the meeting of the Gastroenterology Research Group, May 16, 1957, Colorado Springs, Colo. *Amer. J. dig. Dis.* 1957, **2**, 743.
12. Davidson, M., Sleisenger, M. H., Almy, T. P., and Levine, S. Z. Studies of distal colonic motility in children. I. Non-propulsive patterns in normal children. *Pediatrics* 1956, **17**, 807.
13. Lorber, S. H., and Shay, H. Technical and physiological considerations in measuring gastrointestinal pressures in man. *Gastroenterology* 1954, **27**, 478.
14. Ingelfinger, F. J. Disorders of esophageal motor functions. *Advanc. intern. Med.* 1956, **8**, 11.
15. Fleshler, B., Hendrix, T. R., Kramer, P., and Ingelfinger, F. J. Resistance and reflex function of the lower esophageal sphincter. *Clin. Res. Proc.* 1957, **5**, 199.
16. Wolf, S. B., Marshak, R. H., Som, M. L., Brahm, S. A., and Greenberg, E. I. The gastroesophageal vestibule on roentgen examination; differentiation from phrenic ampulla and minimal hiatal herniation. *J. Mt Sinai Hosp.* 1958, **25**, 167.
17. Lerche, W. *The Esophagus and Pharynx in Action.* Springfield, Ill., Charles C Thomas, 1950.
18. Allison, P. R. Reflux esophagitis, sliding hiatal hernia, and anatomy of repair. *Surg. Gynec. Obstet.* 1951, **92**, 419.