

Case Report

Uveal Hematocysts in a Golden Retriever Dog

Kyle L. Tofflemire, R. David Whitley, Gil Ben-Shlomo, and Rachel A. Allbaugh

Department of Veterinary Clinical Sciences, Iowa State University, 1600 South 16th Street, Ames, IA 50011, USA

Correspondence should be addressed to R. David Whitley; dwhitley@iastate.edu

Received 7 October 2013; Accepted 13 November 2013

Academic Editors: M. T. Mandara and N.-Y. Park

Copyright © 2013 Kyle L. Tofflemire et al. This is an open access article distributed under the Creative Commons Attribution License, which permits unrestricted use, distribution, and reproduction in any medium, provided the original work is properly cited.

Case Description. A 7-year-old neutered male golden retriever presented for examination 1 month following the observation of multifocal round brown structures in the anterior chamber of the left eye and similar, but blood-filled, structures in the right eye. *Clinical Findings.* Ophthalmic examination revealed bilateral iris hyperpigmentation, pigment deposition on the anterior lens capsule, and uveal cysts. The uveal cysts in the right eye were partially blood filled. Clinical findings were consistent with pigmentary uveitis of golden retrievers. *Treatment and Outcome.* The patient has been maintained on topical anti-inflammatories and no progression of the disease has occurred in eight months. *Clinical Relevance.* This paper emphasizes the importance of recognizing the unique clinical signs of pigmentary uveitis and highlights uveal hematocysts, a rare manifestation of the disease.

1. Case Description

A 7-year-old neutered male golden retriever dog presented to the Iowa State University Lloyd Veterinary Medical Center for ophthalmic examination 1 month following identification of multifocal brown structures in the anterior chamber of the left eye and similar, but blood-filled, structures in the right eye. The primary care veterinarian discovered these structures during annual wellness examination.

Ophthalmic examination revealed normal palpebral, dazzle, and pupillary light reflexes in both eyes. Vision was considered normal based on positive menace responses and appropriate navigation in the hospital environment. On careful inspection, both eyes had mild conjunctival hyperemia, diffuse iris hyperpigmentation, pigment deposition on the anterior lens capsule, and numerous uveal cysts in the anterior chamber. The uveal cysts in the right eye were blood filled (Figure 1). Focal posterior synechia and an incipient anterior cortical cataract were also present in the right eye. Tonometry, with a TonoVet (Tiolat Oy, Helsinki, Finland), indicated an intraocular pressure of 8 mmHg in both eyes. Schirmer tear test I values were 16 and 15 mm/min in the right and left eyes, respectively. Fluorescein staining was negative in both eyes.

Dilation of the left pupil occurred within 20 minutes of tropicamide 1% application; however, dilation of the

right pupil was limited by the posterior synechia. Indirect ophthalmoscopy revealed no abnormalities of the fundus in either eye.

Complete physical examination was unremarkable, with the exception of a body condition score of 6/9. Notably, cardiovascular parameters were normal and no petechiation, ecchymosis, or bruising was identified. Complete blood count, serum biochemistry panel, and thyroid panel were within normal limits.

The patient's clinical signs were considered consistent with pigmentary uveitis of golden retrievers, and prednisolone acetate 1% and tropicamide 1% were each prescribed for use in both eyes once daily.

Reevaluation of the eyes 2 weeks later revealed resolution of the conjunctival hyperemia in both eyes and rupture of one blood-filled cyst in the right eye, resulting in a 2 mm corneal endothelial opacity. Intraocular pressures were 6 and 9 mmHg in the left and right eye, respectively. Ophthalmic examination was otherwise unchanged and no adjustments to the medication regimen were made.

At the time of publication, treatment has successfully controlled clinical progression of the disease for the preceding eight months. Reevaluations are recommended every 3–6 months to monitor for progression of pigmentary uveitis and development of sequelae.

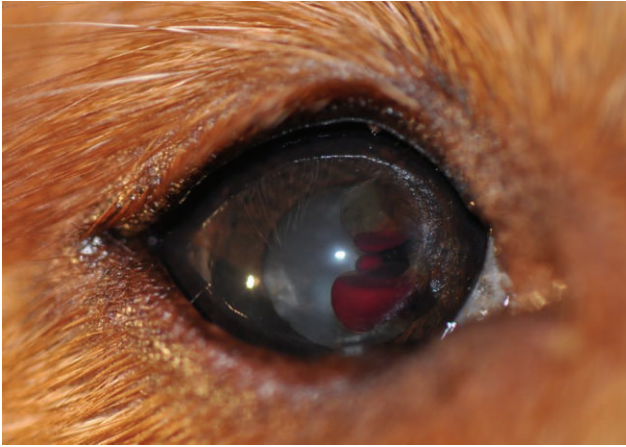

FIGURE 1: Photograph of the right eye with multiple uveal hematocysts. Iris hyperpigmentation, pigment deposits on the anterior lens capsule, medial posterior synechia, and an incipient cataract are also present. Upper and lower distichia are an incidental finding.

2. Discussion

Pigmentary uveitis, also known as golden retriever uveitis and multiple iridociliary cysts in golden retrievers, is a bilateral, chronic, low-grade, and progressive disease that may be immune-mediated [1–5]. The breed predilection of golden retrievers may reflect a genetic influence [1, 6]. Clinical signs of the disorder include iris hyperpigmentation and thickening, pigment dispersion in the anterior chamber, and pigment deposition on the anterior lens capsule and corneal endothelium [1, 7]. Aqueous flare, sometimes with cellular debris, may also occur [1, 4, 5, 7]. Because of their location at the level of the ciliary body, uveal cysts are not often recognized clinically in affected dogs; however, they are a common finding on histopathology [1, 2, 4, 8, 9]. For this reason, identification of uveal cysts in a golden retriever should prompt careful investigation for other lines of evidence of pigmentary uveitis.

Although they are a defining characteristic of pigmentary uveitis [1, 2, 4, 10], uveal cysts may be an incidental clinical finding in many dog breeds [3, 4, 7, 9, 11]. However, the uveal hematocysts in this report are a unique feature as, to the authors' knowledge, there has been only one other report of similar cysts in peer-reviewed literature [1]. Limited details on that case are available, but the patient was a golden retriever with pigmentary uveitis and resorption of the blood within the cyst that occurred within 5 months of diagnosis. In contrast, the hematocysts in our report were unchanged over the course of 8 months, with the exception of one rupturing shortly after starting therapy.

The authors can only speculate about the origin of the blood within the uveal cysts: preiridal fibrovascular membrane formation, which may be prone to vascular fragility, has been associated with intraocular disease, including pigmentary uveitis [2, 4, 12]; vascular anomalies of the uveal tract may be present given the possible congenital origin of uveal cysts [7]; disruption of the blood aqueous barrier

is also a possibility, although the inflammatory nature of pigmentary uveitis is debated [4]. In the present case, systemic bleeding disorders were considered unlikely based on normal physical examination and clinicopathologic findings. Ocular ultrasonography and histopathology of eyes with uveal hematocysts, although not typically necessary for diagnosis, may help characterize the pathophysiology.

Uveal cysts have been proposed to be directly related to pathogenesis of pigmentary uveitis and the subsequent development of glaucoma, which occurs in approximately 50% of the affected dogs [1, 2, 4, 8]. The exact relationship between uveal cysts and glaucoma is unclear; however, uveal cysts may contribute to glaucoma development by displacing the iris anteriorly and narrowing the iridocorneal angle, liberating viscous material into the anterior chamber, and contributing to formation of a preiridal fibrovascular membrane and/or posterior synechia [2, 4, 5, 7, 8]. If glaucoma develops, medical and surgical therapy is warranted but often unrewarding [1, 3].

In summary, the patient in this report was diagnosed with pigmentary uveitis based on subtle, but suggestive, clinical signs. The uveal hematocysts described here likely represent a rare manifestation of the disease. Anti-inflammatory treatment was provided in an attempt to control the disease process. Because affected dogs are at high risk for vision-threatening sequelae such as glaucoma, the patient is being reevaluated every 3–6 months to monitor intraocular pressure and for progression of the disease.




Conflict of Interests

The authors declare no conflict of interests.

References

- [1] J. S. Sapienza, F. J. S. Domenech, and A. Prades-Sapienza, "Golden retriever uveitis: 75 cases (1994–1999)," *Veterinary Ophthalmology*, vol. 3, no. 4, pp. 241–246, 2000.
- [2] D. Esson, M. Armour, P. Mundy, C. S. Schobert, and R. R. Dubielzig, "The histopathological and immunohistochemical characteristics of pigmentary and cystic glaucoma in the golden retriever," *Veterinary Ophthalmology*, vol. 12, no. 6, pp. 361–368, 2009.
- [3] D. V. H. Hendrix, "Disease and surgery of the canine anterior uvea," in *Veterinary Ophthalmology*, K. N. Gelatt, Ed., pp. 816–831, Blackwell Publishing, Oxford, UK, 4th edition, 2007.
- [4] "The uvea," in *Veterinary Ocular Pathology: A Comparative Review*, R. R. Dubielzig, K. L. Ketring, G. J. McLellan, and D. M. Albert, Eds., pp. 250–255, WB Saunders, Edinburgh, UK, 2010.
- [5] "Anterior uvea and anterior chamber," in *Ophthalmic Disease in Veterinary Medicine*, C. L. Martin, Ed., pp. 305–316, Manson Publishing, 2010.
- [6] W. M. Townsend, A. Mankey, and J. A. Gerlach, "Association between dog leukocyte antigen haplotype and golden retriever pigmentary uveitis," in *Proceedings of the Annual Meeting ACVO*, 2009.
- [7] P. E. Miller, "Uvea," in *Slatter's Fundamentals of Veterinary Ophthalmology*, D. J. Maggs, P. E. Miller, and R. Ofri, Eds., pp. 217–225, Elsevier Saunders, Philadelphia, Pa, USA, 4th edition, 2008.

- [8] A. J. Deehr and R. R. Dubielzig, "A histopathological study of iridociliary cysts and glaucoma in golden retrievers," *Veterinary Ophthalmology*, vol. 1, no. 2-3, pp. 153–158, 1998.
- [9] B. P. Wilcock, "The eye and ear," in *Jubb, Kennedy, and Palmer's Pathology of Domestic Animals*, M. G. Maxie, Ed., pp. 497–518, Elsevier, New York, NY, USA, 5th edition, 2007.
- [10] K. N. Gelatt, "Surgical procedures of the anterior chamber and anterior uvea," in *Veterinary Ophthalmic Surgery*, K. N. Gelatt and J. P. Gelatt, Eds., pp. 238–258, Elsevier Saunders, Oxford, UK, 2011.
- [11] K. A. Corcoran and S. A. Koch, "Uveal cysts in dogs: 28 cases (1989–1991)," *Journal of the American Veterinary Medical Association*, vol. 203, no. 4, pp. 545–546, 1993.
- [12] R. L. Peiffer Jr., B. P. Wilcock, and H. Yin, "The pathogenesis and significance of pre-iridal fibrovascular membrane in domestic animals," *Veterinary Pathology*, vol. 27, no. 1, pp. 41–45, 1990.



Hindawi

Submit your manuscripts at
<http://www.hindawi.com>

