



Diagnostic value of perfusion cardiovascular magnetic resonance in patients with angina pectoris but normal coronary angiograms assessed by intracoronary acetylcholine testing

Ali Yilmaz, Anastasios Athanasiadis, Heiko Mahrholdt, et al.

Heart 2010 96: 372-379 originally published online November 23, 2009
doi: 10.1136/hrt.2009.174367

Updated information and services can be found at:

<http://heart.bmj.com/content/96/5/372.full.html>

These include:

References

This article cites 37 articles, 30 of which can be accessed free at:

<http://heart.bmj.com/content/96/5/372.full.html#ref-list-1>

Email alerting service

Receive free email alerts when new articles cite this article. Sign up in the box at the top right corner of the online article.

Notes

To order reprints of this article go to:

<http://heart.bmj.com/cgi/reprintform>

To subscribe to *Heart* go to:

<http://heart.bmj.com/subscriptions>

Diagnostic value of perfusion cardiovascular magnetic resonance in patients with angina pectoris but normal coronary angiograms assessed by intracoronary acetylcholine testing

Ali Yilmaz, Anastasios Athanasiadis, Heiko Mahrholdt, Matthias Voehringer, Peter Ong, Stefan Hill, Eva-Maria Kispert, Melanie Seebo, Udo Sechtem

Division of Cardiology,
Robert-Bosch-Krankenhaus,
Stuttgart, Germany

Correspondence to

Ali Yilmaz,
Robert-Bosch-Krankenhaus,
Auerbachstrasse 110,
Stuttgart 70376, Germany;
ali.yilmaz@rbk.de

Accepted 27 October 2009
Published Online First
23 November 2009

ABSTRACT

Background Perfusion cardiovascular magnetic resonance (CMR) has a high sensitivity for the detection of significant coronary artery disease (CAD). However, the specificity of this method is lower than its sensitivity. The reason for this observation is hitherto unclear and has been either explained by 'false-positive' results or by microvascular dysfunction in patients without CAD.

Objective To evaluate whether pathological myocardial perfusion-CMR imaging in symptomatic patients without significant CAD is associated with coronary epicardial or microvascular dysfunction.

Methods In this retrospective study, 42 patients who presented with unstable angina pectoris underwent (a) an adenosine-stress perfusion-CMR study; (b) coronary angiography; (c) intracoronary acetylcholine (ACh) testing following coronary angiography with exclusion of significant CAD. The CMR protocol comprised cine imaging followed by adenosine first-pass perfusion imaging and late gadolinium enhancement-CMR. Diagnostic left ventriculography and multiplane coronary angiography were performed before intracoronary ACh testing.

Results An adenosine-induced, reversible subendocardial perfusion defect was detected in 22/42 patients (52%) without significant CAD. Coronary epicardial vasospasm was detected in 10/42 patients (24%) while microvascular dysfunction was found in 20/42 patients (48%). Patients with a reversible stress-induced perfusion defect had significantly more often a pathological coronary epicardial or microvascular vasoreaction (20/22; 91%) during intracoronary ACh testing than those without a perfusion defect (10/20; 50%; $p < 0.01$). Univariate correlation analyses revealed a substantial association between a pathological ACh-testing result and a perfusion defect in the antecedent CMR study ($r = +0.45$; $p < 0.01$).

Conclusions Reversible perfusion defects depicted by perfusion-CMR in patients without significant CAD are mostly due to coronary epicardial or microvascular dysfunction, and correct interpretation of such perfusion-CMR results may enable targeted treatment.

Coronary artery disease (CAD) is clinically suspected when patients present with symptoms of chest pain or dyspnoea on exertion (typical angina pectoris (AP) or AP equivalent). However, these symptoms are neither sensitive nor specific and may also be associated with other cardiac (eg, coronary vasospasm, myocarditis) and non-

cardiac diseases (eg, pleuritis, gastro-oesophageal reflux).^{1–3} In order to verify the presence of the disease, non-invasive stress testing is usually applied before patients are referred for coronary angiography.⁴

Cardiovascular magnetic resonance (CMR) imaging with adenosine-stress first-pass perfusion (perfusion-CMR) has been shown to be a sensitive non-invasive method for the detection of myocardial ischaemia caused by significant coronary stenosis in patients with CAD.^{5,6} However, despite a high sensitivity of perfusion-CMR for the detection of significant CAD, the specificity of this method was mostly lower and up to 40% of patients with typical AP and a perfusion defect in their perfusion-CMR study were found to have normal or near-normal coronary arteries.^{6,7} Moreover, not only perfusion-CMR but most available imaging modalities (apart from stress echocardiography) that assess the haemodynamic significance of CAD have a moderate to low specificity for detection of significant CAD.^{8,9} Only in the case of stress echocardiography has a satisfactory diagnostic specificity (80–91%) for the detection of significant CAD been demonstrated and attributed to the absence of wall motion abnormalities in patients with myocardial ischaemia not caused by epicardial stenosis.¹⁰ The cause of 'false-positive' results in perfusion-CMR and nuclear imaging modalities remains unclear: might the patients' chest discomfort be due to angiographically invisible cardiac disease? Previously, coronary vasomotility or microvascular disorders have been discussed as possible causes for such 'false-positive results'.^{11–14} However, no data on the results of coronary vasomotion testing in patients with pathological perfusion-CMR imaging but normal coronary arteries have been published.

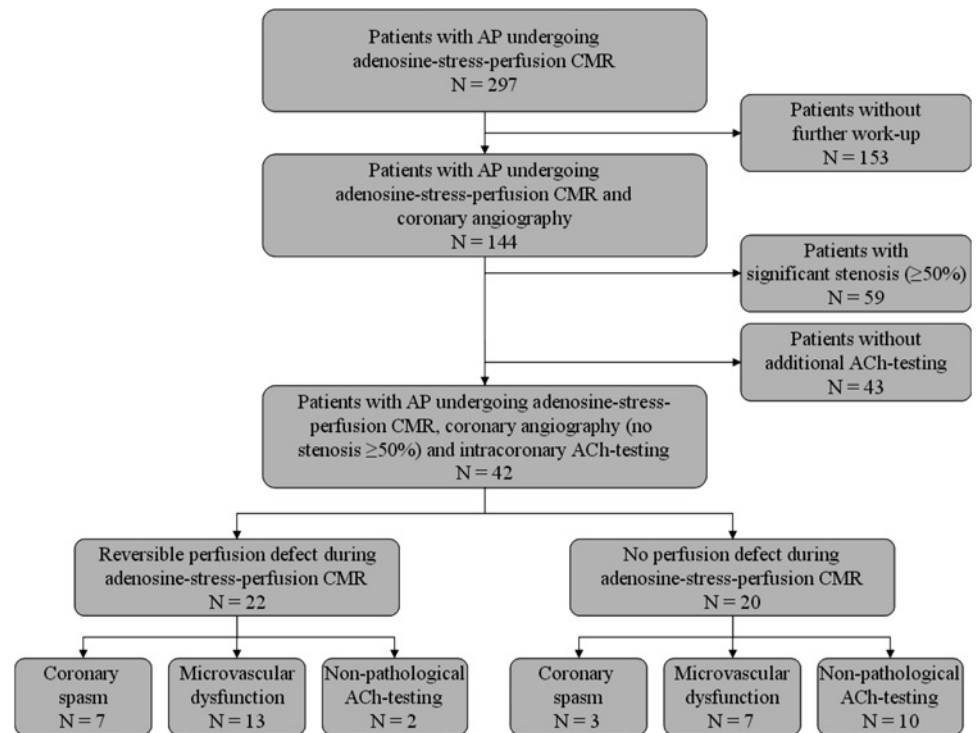
With this study, we aimed at evaluating whether a pathological perfusion-CMR study in patients without significant CAD is attributable to coronary epicardial or microvascular dysfunction by performing coronary functional testing using acetylcholine (ACh) as the provocative agent.

PATIENTS AND METHODS

Patient population

Between April 2005 and November 2008, we retrospectively identified 297 patients who fulfilled both of the following criteria (figure 1): (a) they

Figure 1 Flow-chart demonstrating patient selection for the study and the distribution of perfusion cardiovascular magnetic resonance (perfusion-CMR) and intracoronary acetylcholine (ACh) testing results in those 42 patients who were finally included in this study. AP, angina pectoris.



presented with unstable AP (leading complaints of chest pain and/or dyspnoea suggesting AP or an AP equivalent clinically indicative of significant CAD); (b) underwent a CMR study including adenosine-stress perfusion either for suspected CAD or to evaluate a possible recurrence of a haemodynamically significant stenosis in patients with previously known but repaired flow-limiting CAD. Out of this patient cohort, 153 patients did not undergo further investigation (by cardiac catheterisation) owing to the lack of myocardial ischaemia during perfusion-CMR. The remaining 144 patients underwent coronary angiography either owing to their pathological perfusion-CMR study ($n=88$) or owing to clinically suspected significant CAD in spite of a normal or non-conclusive perfusion-CMR study ($n=56$); significant CAD (defined as one or more coronary stenosis $\geq 50\%$) was found in 59 patients while it was ruled out in 85. Additional intracoronary ACh testing for evaluation of coronary epicardial or microvascular dysfunction as a possible causative reason for their symptoms was performed in 42 (of these 85) patients without significant CAD. The remaining 43 patients without significant CAD did not undergo ACh testing because of (a) missing patient consent in 30/43; (b) coronary anomalies in 4/43; (c) severely impaired left ventricular (LV) systolic function in 3/43; (d) impaired renal function in 3/43; (e) pulmonary hypertension in 2/43; (f) myocardial bridging in 1/43 patient(s).

Those 42 patients who underwent first a perfusion-CMR study, then coronary angiography and finally, intracoronary ACh testing were included in this analysis. The patient characteristics can be seen in tables 1 and 2. Written informed consent was obtained from all included patients for both perfusion-CMR and intracoronary ACh testing before each study.

CMR imaging

Electrocardiographic-gated CMR imaging was performed in breath-hold using a 1.5 T system (Magnetom Sonata, Siemens Medical Solutions, Erlangen, Germany). As described elsewhere,^{15 16} our CMR protocol comprised cine imaging at rest for assessment of LV function followed by adenosine gadolinium first-pass imaging for assessment of stress perfusion. After

waiting for 15 min to allow equilibration of the contrast agent first-pass perfusion imaging was repeated without adenosine for assessment of rest perfusion. Finally, late gadolinium enhancement (LGE)-CMR was performed for assessment of myocardial damage. After cine imaging in short- and long-axis views, adenosine (140 $\mu\text{g}/\text{kg}/\text{min}$) was infused under continuous electrocardiography and blood pressure monitoring for 3 min. Perfusion-CMR images were acquired using gadolinium contrast (0.075 mmol/kg Magnevist; Bayer Schering Pharma, Bayer Vital GmbH, Leverkusen, Germany; 3.5 ml/s) followed by a saline flush (45 ml with 3.5 ml/s) via an antecubital vein. Three to four short-axis slices were obtained for each heartbeat using a saturation-recovery gradient-echo sequence with a 90° prepulse for T1-weighting (echo time 1.1 ms; delay time 85–100 ms; temporal resolution 110–125 ms; voxel size $3.1 \times 1.8\text{--}2.5 \times 8$ mm). The gap between images was set to 2 mm to have the exact same slice locations (centre and plane) as cine-CMR. Five minutes after rest perfusion (with an additional 0.075 mmol/kg Magnevist), LGE-CMR was performed with a segmented inversion-recovery gradient-echo technique with constant adjustment of inversion time in the identical views as cine-CMR.¹⁷ Both cine-CMR and LGE-CMR images were prescribed in the short axis every 10 mm (slice thickness 6 mm) from base to apex. In-plane resolution was typically 1.2×1.8 mm.

CMR analysis

CMR images were evaluated by two observers as described elsewhere¹⁸ blinded to the intracoronary ACh testing results. In brief, endocardial and epicardial borders were outlined on the short-axis cine images. Volumes and ejection fraction were derived by summation of epicardial and endocardial contours using Argus software (Siemens, Erlangen, Germany). A perfusion defect in the perfusion-CMR images was defined as a regional dark area that (a) persisted for more than two beats while other regions enhanced during the first-pass of contrast through the LV myocardium; (b) involved the subendocardium.^{15 19} Stress and rest images were first assessed visually by reaching a consensus between both observers as to whether a subendocardial,

Cardiac imaging and non-invasive testing

Table 1 Patient characteristics based on cardiovascular magnetic resonance results

	All patients (n=42)	Patients with perfusion defect (n=22)	Patients without perfusion defect (n=20)	p Value
Age (years; (min to max))	66 (36–81)	68 (38–81)	65 (36–80)	0.91
Gender: female sex (n (%))	39 (93)	22 (100)	17 (85)	0.10
Hypertension (n (%))	35 (83)	19 (86)	16 (80)	0.69
Diabetes mellitus (n (%))	7 (17)	6 (27)	1 (5)	0.10
History of smoking (n (%))	8 (19)	6 (27)	2 (10)	0.24
Body-mass-index (kg/m ² ; (min to max))	25 (21–44)	25 (21–38)	26 (21–44)	0.86
Family history for CAD (n (%))	6 (14)	3 (14)	3 (15)	1
Hypercholesterolaemia (n (%))	24 (57)	14 (64)	10 (50)	0.53
LVEF (%; (min to max))	70 (43–86)	70 (43–82)	71 (45–86)	0.82
Previously diagnosed CAD (n (%))	4 (10)	3 (14)	1 (5)	0.61
Clinical symptoms:				
Resting symptoms	4 (10)	1 (5)	3 (15)	0.33
Symptoms on exertion	19 (45)	11 (50)	8 (40)	0.55
Resting symptoms + on exertion	19 (45)	10 (45)	9 (45)	1

CAD, coronary artery disease; LVEF, left ventricular ejection fraction.

reversible perfusion defect was absent in all segments or present at least in one segment considering the mid-ventricular six segments of the 16-segment model. A dark subendocardially limited rim at rest and during adenosine stress was classified as a non-pathological artefact. Contrast images were evaluated for LGE using a 16-segment model and assessing the presence or absence of LGE visually by reaching a consensus between both observers.

As described elsewhere,^{5 20} semiquantitative analysis was performed in a blinded fashion using QMASS software (Medis, Leiden, The Netherlands). Endocardial and epicardial borders were outlined automatically on the mid-ventricular short-axis perfusion images. Manual adjustments were made for any cardiac or respiratory movement. The short-axis slices were divided into six equiangular segments (1=anterior, 2=anterolateral, 3=inferolateral, 4=inferior, 5=inferoseptal and 6=anteroseptal). In addition, these segments were divided into subendocardial (10–50% of transmural extent) and subepicardial (51–90% of transmural extent) regions. The maximal upslope of the signal intensity curves was calculated for each segment. The maximal upslope value of the blood-pool signal intensity curve was used for indexing, thereby minimising possible differences in the arterial input function. A myocardial perfusion index was calculated for each segment by dividing the maximal segmental

signal intensity upslope with the maximal upslope of the blood pool. A myocardial perfusion reserve index (MPRI) was calculated by dividing the myocardial perfusion index value during maximal vasodilatation (during adenosine stress) with the respective value during resting conditions. A subendocardial: subepicardial MPRI ratio of <0.72 was used as cut-off value to define a substantial hypoperfusion in the subendocardium in relation to the subepicardium.¹³

Coronary angiography and ACh testing

After pausing all vasoactive drugs for at least 24 h, diagnostic left ventriculography and multiplane coronary angiography were performed, followed by intracoronary ACh testing (Miochol E, Novartis Pharma, Germany). As described elsewhere,³ following baseline angiography the left coronary artery was tested in the best projection, showing large portions of the vessel. Graded doses of ACh (2 µg, 20 µg and 108 µg) were given over 3 min each, using the catheter employed for diagnostic coronary angiography. The test was stopped if symptoms occurred and coronary vasospasm was seen in at least one of the tested major coronaries (left anterior descending or left circumflex artery). Nitroglycerin was applied immediately dependent on the patient's symptoms. If no vasospasm requiring the immediate application of nitroglycerin i.c. occurred in the left anterior descending or the left circumflex artery, the catheter was repositioned in the right coronary artery, and just a single dose of ACh (80 µg) was applied. Finally, nitroglycerin (0.2 mg) was injected into both left and right coronary arteries, and additional coronary angiograms were obtained 60 s after nitroglycerin injection.

Angiographic analysis

Coronary angiograms were analysed by a blinded observer using quantitative coronary angiography software (QCA-CMS 6.0, Medis, Netherlands), applying an automatic edge detection algorithm, according to the segment classification model of the American Heart Association. Only main segments of the main coronary arteries were included in the analysis. Average lumen diameters were determined in identical, at least 10 mm long segments in the angiograms, first after ACh infusion, and then after nitroglycerin application. Percentage vasoconstriction was determined by dividing the mean segment diameter after ACh by the diameter after nitroglycerin and subtracting the result from 1.²¹ Coronary vasospasm was defined as a lumen narrowing of a coronary artery segment $\geq 75\%$ in diameter after ACh

Table 2 Bivariate correlations between baseline characteristics and pathological intracoronary acetylcholine testing

	r	p Value
Age	+ 0.05	0.77
Gender: female sex	+ 0.03	1
Hypertension	+ 0.14	0.65
Diabetes mellitus	+ 0.28	0.16
History of smoking	+ 0.17	0.40
Body mass index	– 0.11	0.50
Family history for CAD	+ 0.11	0.66
Hypercholesterolaemia	+ 0.20	0.30
LVEF	– 0.11	0.49
Clinical symptoms		
Resting symptoms	– 0.33	0.06
Symptoms on exertion	+ 0.36	0.04
Resting symptoms + on exercise	– 0.17	0.32
CMR-perfusion defect	+ 0.45	<0.01

CAD, coronary artery disease; CMR, cardiovascular magnetic resonance; LVEF, left ventricular ejection fraction.

infusion as compared with the relaxed state after intracoronary application of nitroglycerin, associated with ischaemic ST-segment changes and reproduction of clinical symptoms. Accordingly, microvascular dysfunction was defined as a coronary lumen narrowing <75% in addition to ischaemic ST-segment changes and reproduction of clinical symptoms.^{22 23} All other possible constellations were classified as non-pathological results (eg, if the patient felt a hitherto unknown chest pain symptom in response to ACh or if no or only minor, non-significant ST-segment changes occurred).

Statistical analysis

Data for continuous variables are expressed as median values in addition to minimal and maximal values, whereas data for categorical variables are expressed as the number and percentage of patients. Comparisons between groups were made using a two-sided unpaired Student *t* test for normally distributed, and Mann–Whitney *U* test for non-normally distributed continuous variables. For categorical variables we used the χ^2 test and Fisher's exact test, where appropriate. Bivariate correlation analysis was performed with ϕ coefficients of association between two dichotomous variables and point bi-serial coefficients in cases where one variable was dichotomous and the other non-dichotomous. The difference between two groups was defined as statistically significant for a two-sided *p* value of <0.05.

RESULTS

Patient characteristics

Based on our inclusion and selection criteria, 42 patients who underwent (a) a perfusion-CMR study; (b) coronary angiography; (c) intracoronary ACh testing following coronary angiography were included in this study. The median time interval between the perfusion-CMR study and cardiac catheterisation was 4 days. The median coronary heart disease risk based on the Framingham risk score was only 8% (over 10 years; range 1–22%) in these patients. Resting ECG abnormalities were present in 10 patients: An ST-segment depression was registered in five, a bundle-branch block in four and an AV block in another patient. As demonstrated in table 1, the median age of the patient group was 66 years with a maximum of 81 years and a minimum of 36 years. Ninety per cent of these patients had exertional AP (\pm resting symptoms) while only a minority (10%) had exclusively resting complaints.

The most common cardiovascular risk factors were hypertension (83%) and hypercholesterolaemia (57%) while all other risk factors were present in <20% of these patients. Comparison of baseline characteristics between these patients (n=42) and those without additional ACh testing (n=43) showed no significant differences with respect to age, gender or hypertension. However, those patients without additional ACh testing presented less frequently with both resting clinical symptoms (chest pain and/or dyspnoea) and symptoms on exertion (21% vs 45%; *p*=0.02).

Comparison of baseline characteristics between patients with (n=22) and without a perfusion defect (n=20) among those included in this analysis (table 1) did not show any significant differences. However, when baseline characteristics were compared between patients with pathological ACh testing results (n=30) and those with non-pathological results (n=12), symptoms exclusively on exertion were more frequently present in the former group (57% vs 17%; *p*=0.04). Interestingly, the proportion of patients with diabetes was higher in those patients with a perfusion defect or a pathological ACh testing result; however,

owing to the small number of patients with diabetes (n=7), this distribution difference was not statistically significant.

CMR results

The great majority of this patient cohort had a normal LV function (left ventricular ejection fraction \geq 60%), only six patients demonstrated a reduced left ventricular ejection fraction <60% by CMR. The median LV end-diastolic volume was 120 ml (range 79–184) without a significant difference between patients with and without a perfusion defect (*p*=0.44). The diameter of the septal wall was measured at end diastole in long-axis views and found to be 9 mm in the median (range 6–16), with four patients demonstrating left ventricular hypertrophy with values >11 mm. Again, there was no significant difference in the septal wall diameter between patients with and without a perfusion defect (*p*=0.36).

An adenosine-induced, reversible subendocardial perfusion defect was detected in 22/42 patients (52%) after visual perfusion-CMR analyses. In those patients with a reversible subendocardial perfusion defect, chest pain during adenosine stress occurred in 18/22 (82%) while only in 8/20 patients (40%) without a perfusion defect (*p*=0.01). In all patients with chest pain during adenosine stress, the chest discomfort disappeared quickly after stopping the adenosine infusion. Thus, in this non-randomly selected patient cohort there were 22 'false-positive' (perfusion defect in the absence of significant CAD) and 20 'true-negative' results (no perfusion defect and no CAD), resulting in a specificity of perfusion-CMR to detect patients with significant CAD of 48%.

Based on semiquantitative perfusion analyses, the increase in transmural myocardial perfusion index (stress compared with rest) was similar between patients with (MPRI 2.48 ± 0.49) and those without a perfusion defect (MPRI 2.54 ± 0.70 ; *p*=0.76). In addition, there was no significant difference in the mean MPRI in both subendocardial and subepicardial segments between patients with and those without a perfusion defect (subendocardial: 2.23 ± 0.53 vs 2.35 ± 0.65 , *p*=0.52; subepicardial: 2.65 ± 0.69 vs 2.55 ± 0.65 , *p*=0.64). However, the mean subendocardial:subepicardial MPRI ratio was significantly lower in patients with (0.85 \pm 0.10) than in those without (0.92 \pm 0.06) a perfusion defect (*p*=0.02). Previously, a subendocardial:subepicardial MPRI ratio of <0.72 was suggested as the optimal ratio for distinguishing patients with microvascular dysfunction from healthy controls. In our study, none of the patients without a visually detected perfusion defect demonstrated a subendocardial:subepicardial MPRI ratio of <0.72 while all of the patients with a perfusion defect had at least one segment with a subendocardial:subepicardial MPRI ratio of <0.72 (mean no of segments = 1.6 \pm 0.8).

LGE-CMR for evaluation of myocardial damage was performed following resting perfusion in all patients. Only two patients were LGE positive, both showed a non-ischaemic type of enhancement: one patient demonstrated a mid-wall pattern of LGE in the septum while in the other, a focal intramural pattern was found in the inferolateral wall.

ACh testing results

Epicardial coronary vasospasm associated with ischaemic ST-segment changes and reproduction of clinical symptoms was detected during intracoronary ACh testing in 10/42 patients (24%), including six patients with a multivessel spasm, while microvascular spasm (defined as a coronary lumen narrowing <75% in addition to ischaemic ST-segment changes and reproduction of clinical symptoms) was found in another 20/42 patients (48%).

Cardiac imaging and non-invasive testing

Epicardial coronary vasospasm was detected in 7/22 patients with and only 3/20 without a perfusion defect (figure 2). Microvascular spasm was found in 13/22 patients with but in only 7/20 without a perfusion defect. Thus, altogether 30 patients (71%) were found to have some form of coronary epicardial or microvascular dysfunction in response to intracoronary ACh. Patients with a perfusion defect demonstrated a significantly higher incidence of an impaired coronary epicardial or microvascular vasoreaction (20/22 (91%)) than those without a perfusion defect (10/20 (50%); $p < 0.01$) during intracoronary ACh testing (figure 3). Based on these results, the sensitivity and specificity of perfusion-CMR to detect those patients having an abnormal coronary epicardial or microvascular vasoreaction to ACh in the absence of significant CAD was 73% and 83%, respectively. Moreover, compared with ACh testing, the positive predictive value of perfusion-CMR for the presence of a coronary vasoreactivity disorder was 91%, but the negative predictive value was only 50% in our study.

Interestingly, all four patients with left ventricular hypertrophy had an impaired vasoreaction, with two demonstrating coronary vasospasm and two microvascular dysfunction, respectively.

Moreover, there were four patients with previously diagnosed significant CAD who had all undergone previous percutaneous coronary intervention with stenting. While ACh testing was suggestive of microvascular dysfunction in all four patients, only three of them demonstrated a perfusion defect during adenosine perfusion-CMR. In two out of those three patients with a perfusion defect, quantitative perfusion-CMR analyses

disclosed a subendocardial:subepicardial MPRI ratio of < 0.72 in those myocardial segments that were supplied by the stented coronary artery.

Correlation analyses

The associations between baseline parameters and ACh testing results are shown in table 2: Bivariate correlation analyses showed a substantial correlation between a pathological ACh testing result and symptoms on exertion ($r = +0.36$; $p = 0.04$) as well as between a pathological ACh testing result and a perfusion defect in the antecedent CMR study ($r = +0.45$; $p < 0.01$). Owing to the limited study size, a comprehensive multivariate regression analysis could not be performed.

Accordingly, we evaluated the association between baseline parameters and perfusion-CMR results (table 3): A significant association was found between the presence of a perfusion defect and hypertension ($r = +0.61$; $p < 0.01$) as well as symptoms on exertion ($r = +0.68$; $p < 0.01$) based on bivariate correlation analyses.

DISCUSSION

To the best of our knowledge, this is the first study that comparatively evaluates perfusion-CMR (for the detection of myocardial ischaemia) and intracoronary ACh testing (for the evaluation of coronary epicardial and microvascular vasoreaction) in the same patients with symptoms of AP in the absence of significant CAD. Our study results emphasise the limited specificity of perfusion-CMR for the detection of significant CAD and simultaneously explain that this observation is not primarily due to 'false-positive' results but rather

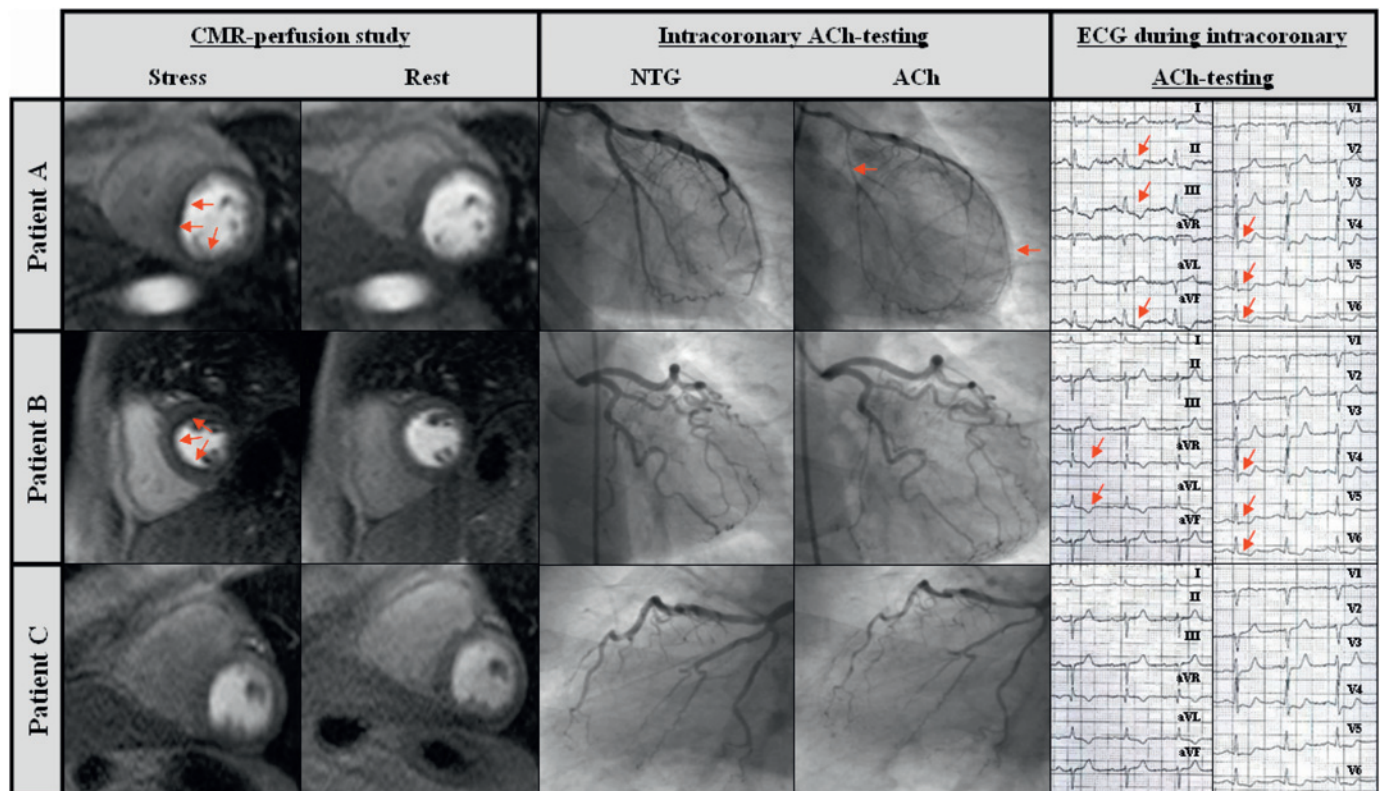


Figure 2 Panels of three different patients comprising stress- and rest-perfusion cardiovascular magnetic resonance (rest-perfusion CMR) images, coronary angiograms of the left coronary artery during acetylcholine (ACh) and nitroglycerin (NTG) infusion and ECG recordings during ACh testing. Patient A: Patient with coronary vasospasm showing a subendocardial perfusion defect in the septal wall, coronary vasospasm in both the left anterior descending coronary artery and right circumflex artery and ischaemic ECG changes during ACh testing. Patient B: Patient with microvascular dysfunction showing a more circumferential subendocardial perfusion defect, no significant vasoconstriction during ACh testing in spite of significant ischaemic ECG changes. Patient C: Patient with completely normal study results.

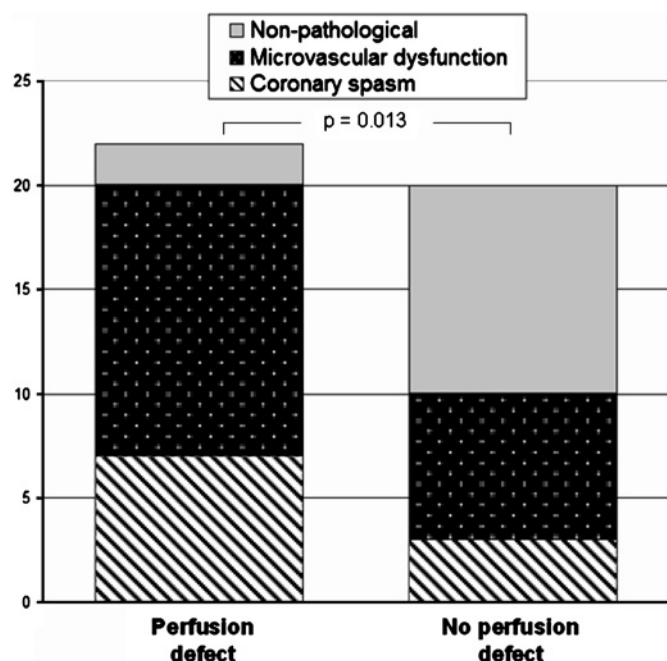


Figure 3 Significantly different distribution of acetylcholine (ACh) testing results in patients with and without a perfusion defect during perfusion cardiovascular magnetic resonance.

associated with an impaired coronary vasoreaction. Reversible subendocardial myocardial ischaemia as demonstrated by perfusion-CMR is particularly prevalent in patients with exertional symptoms and pre-existing hypertension and is significantly correlated with an underlying coronary epicardial or microvascular dysfunction.

Indication and diagnostic performance of perfusion-CMR

Imaging-based evaluation of suspected CAD has been traditionally performed by single-photon emission tomography or stress echocardiography.^{24 25} However, in the past few years perfusion-CMR and dobutamine stress-CMR have gained acceptance owing to their high spatial and temporal resolution without the burden of ionising radiation.^{5 7 16 26} A recent meta-analysis on the diagnostic performance of both perfusion-CMR and dobutamine stress-CMR in the detection of significant CAD (defined as coronary stenosis $\geq 50\%$) included data from 24

Table 3 Bivariate correlations between baseline characteristics and an adenosine-induced cardiovascular magnetic resonance perfusion defect

	r	p Value
Age	- 0.02	0.92
Gender: female sex	+ 0.29	0.10
Hypertension	+ 0.61	<0.01
Diabetes mellitus	+ 0.30	0.10
History of smoking	+ 0.22	0.24
Body mass index	- 0.02	0.91
Family history for CAD	- 0.02	1
Hypercholesterolaemia	+ 0.14	0.53
LVEF	- 0.07	0.68
Clinical symptoms		
Resting symptoms	- 0.18	0.33
Symptoms on exertion	+ 0.68	<0.01
Resting symptoms + on exercise	+ 0.20	0.23

CAD, Coronary artery disease; LVEF, Left ventricular ejection fraction.

studies and 1516 patients undergoing perfusion-CMR.⁶ This technique had an excellent overall sensitivity of 91%, but a clearly lower specificity of 81%. Moreover, the specificity of perfusion-CMR (for the detection of significant CAD with a stenosis $\geq 50\%$) was only 62% in one of the studies analysed.⁷ In that study conducted in a highly selected patient population, the specificity of perfusion-CMR was only 48%. We selected this group of patients with the aim of answering the question: why is the specificity lower than its sensitivity for the detection of CAD in most studies published until now?⁶ Are those 'false-positive' perfusion-CMR results which could lead the clinician to classify the patients' symptoms as non-cardiac truly false? The correct answer to these questions has potentially far-reaching clinical consequences for the implementation of appropriate treatment.

Significance of an abnormal perfusion-CMR in patients without CAD

In our selected study cohort, perfusion-CMR disclosed a reversible myocardial perfusion defect in 52% of our 42 patients without significant CAD. By performing intracoronary ACh testing, we were able to reproduce the patients' clinical symptoms in 71% (30/42). Those patients who simultaneously demonstrated epicardial coronary vasoconstriction of $\geq 75\%$ in response to intracoronary ACh were classified as having a coronary vasospasm (n=10; 24%), whereas a simultaneous vasoconstriction of <75% in addition to ischaemic ECG changes was defined as microvascular spasm (n=20; 48%) and the patient was diagnosed as having microvascular angina. Such a classification is in line with the results of Sun *et al* who demonstrated that myocardial ischaemia (proven by ischaemic ECG changes and myocardial lactate production) may occur without or before epicardial coronary vasospasm in patients with anginal pain.²³ Interestingly, those patients with a perfusion defect in our study demonstrated an impaired coronary epicardial or microvascular vasoreaction in up to 91%. Therefore, we argue that in patients without significant CAD, a pathological perfusion-CMR study may not be 'false-positive' but is often indicative of an impaired coronary vasoreaction (with a sensitivity of 73% and a specificity of 83% as compared with ACh testing). Moreover, the positive predictive value and negative predictive value suggest a strong diagnostic value of a pathological perfusion study result (in the absence of significant stenosis) but only a limited diagnostic value in case of a negative perfusion study result.

In this study, we looked at a different group of patients than in the two previous studies, which reported on the results of perfusion-CMR in patients with cardiac syndrome X.^{13 20} The term cardiac syndrome X is used for those patients who have typical exertional angina and demonstrate ST-segment depression during exercise ECG in addition to a completely normal coronary angiogram, but who do not have cardiovascular risk factors for CAD such as hypertension or hypercholesterolaemia (both of which were highly prevalent in our study cohort).^{27 28} While in the study of Panting *et al* a subendocardial hypoperfusion was demonstrated in patients with cardiac syndrome X, Vermeltfoort *et al* could not reproduce these findings. The pathomechanism of chest pain in patients with cardiac syndrome X is still unclear²⁹ and apart from subendocardial ischaemia due to a limited coronary flow reserve other causes such as an abnormally enhanced sensitivity of myocardial pain receptors or even non-cardiac causes are discussed.³⁰ By contrast, 83% of our patients had hypertension (in addition to other risk factors) and univariate correlation analysis showed a significant association between the presence of hypertension and an impaired coronary vasoreaction. Therefore, it is theoretically

possible that some of our patients had hypertensive heart disease with impaired coronary flow reserve causing their symptoms, although the great majority (38/42) did not demonstrate LV hypertrophy.

Underlying pathophysiology for perfusion defects in the absence of CAD

The association between arterial hypertension and an impaired microvascular dysfunction resulting in a reduced coronary flow reserve is well established^{9 10 31 32}. Previous studies have revealed structural changes of the microvasculature (such as an increased media wall thickness of myocardial arterioles due to perivascular fibrosis and reduced coronary capillary density due to interstitial fibrosis) as well as functional abnormalities such as endothelial dysfunction with decreased nitric oxide production. Furthermore, previous nuclear imaging based studies showed a low specificity (as low as 36%) for the detection of CAD in hypertensive patients owing to scintigraphic defects caused by microvascular dysfunction in the absence of significant epicardial stenosis.^{9 10} Therefore, we believe that those aforementioned structural and functional alterations in hypertensive patients cause a coronary vasomotor dysfunction, which in turn may cause perfusion defects in the absence of significant CAD not only in single-photon emission tomography images but also when perfusion-CMR is performed. Since clinical studies have suggested a potential improvement of these structural and functional alterations as well as a relief in clinical symptoms following treatment with ACE inhibitors or calcium antagonists, the appropriate diagnosis in these patients is of paramount importance.^{33–35}

Moreover, the prognosis of patients with normal or near-normal coronary angiograms and inducible myocardial ischaemia due to endothelial dysfunction is worse than for those without myocardial ischaemia and endothelial dysfunction, respectively.^{36 37} Thus, a pathological perfusion-CMR study may have valuable prognostic implications even in the absence of epicardial CAD. This needs to be evaluated in appropriately designed prospective studies. However, since perfusion-CMR has a significantly higher resolution capacity than nuclear imaging modalities, it should be more appropriate for a non-invasive identification of patients with abnormal coronary function in the absence of significant CAD.

Clinical and practical consequences

The results of this study may have important consequences for the diagnostic approach in patients with possible cardiac symptoms: According to the current guidelines, a perfusion-CMR study for evaluation of suspected CAD is appropriate in patients with an intermediate pre-test probability of CAD. If perfusion-CMR is performed in such a patient and shows no pathological finding, then there is only a very low likelihood of a 'false-negative' result with respect to the presence of significant CAD. Thus, additional coronary angiography for evaluation of CAD is not recommended. However, a patient with the appropriate constellation of symptoms (exercise-induced angina/dyspnoea with or without symptoms at rest) and a normal perfusion-CMR study might still have a coronary vasomotility disorder. Therefore, ACh testing may constitute an additional diagnostic possibility in a patient with a high clinical suspicion of ischaemia despite a normal perfusion-CMR study.

If on the other hand, CMR shows a perfusion defect, then primarily two possibilities have to be considered: the patient either has significant epicardial stenosis or a coronary vasomotility disorder (or both). According to the results of this

study, the third option of this finding—that is, that it is a 'false-positive' result—is quite unlikely, in particular in patients with exercise symptoms and hypertension. Since pathological perfusion-CMR results do not allow to discriminate a perfusion defect due to significant epicardial stenosis from one due to a coronary vasomotility disorder, patients with hypertension were even excluded from studies that assessed the diagnostic accuracy of perfusion-CMR in suspected CAD.⁵ As such a discrimination is not possible based on perfusion-CMR, coronary angiography has to be performed in order to definitely rule out potentially hazardous severe CAD. The coronary angiogram will permit appropriate decision-making about interventional or medical treatment for CAD. However, the exclusion of significant CAD during coronary angiography should force the clinician to think of and consider a coronary vasomotility disorder: This can (a) either be further evaluated (and mostly confirmed) by intra-coronary ACh testing as demonstrated in this study or (b) even be diagnosed based on the clinical symptoms and the initial pathological perfusion-CMR result without further testing. The latter is reasonable as this study demonstrated a sensitivity of 73% for perfusion-CMR (compared with ACh testing) to detect vasomotility disorders in the absence of CAD. In both scenarios, the tentative application of calcium antagonists and/or vasodilatory drugs such as nitroglycerin (with a timely follow-up and evaluation of treatment success) should be considered as appropriate.

Study limitations

Obviously, our study size was small and precluded any multivariate analyses for determinants of an impaired coronary vasomotion. However, the size of this study was larger than that of comparable studies published previously^{12 20} and therefore our analyses should at least allow careful hypothesis generation. Furthermore, this was a retrospective study and we cannot definitely exclude bias in patient selection that might have influenced our study results, although this seems to be unlikely. In addition, we could only assess the mid-ventricular six segments of the 16-segment model by semiquantitative analysis.

CONCLUSIONS

The data of this retrospective study suggest that reversible perfusion defects depicted by perfusion-CMR in patients without significant CAD are mostly due to coronary epicardial or microvascular dysfunction, and correct interpretation of such perfusion-CMR results may enable a targeted treatment and be of prognostic importance.

Competing interests None.

Patient consent Obtained.

Provenance and peer review Not commissioned; externally peer reviewed.

REFERENCES

1. **Korff S**, Katus HA, Giannitsis E. Differential diagnosis of elevated troponins. *Heart* 2006;**92**:987–93.
2. **Ong P**, Athanasiadis A, Hill S, *et al.* Coronary artery spasm as a frequent cause of acute coronary syndrome: the CASPAR (Coronary Artery Spasm in Patients with Acute Coronary Syndrome) study. *J Am Coll Cardiol* 2008;**52**:523–7.
3. **Yilmaz A**, Mahrholdt H, Athanasiadis A, *et al.* Coronary vasospasm as the underlying cause for chest pain in patients with PVB19 myocarditis. *Heart* 2008;**94**:1456–63.
4. **Fox K**, Garcia MA, Ardissino D, *et al.* Guidelines on the management of stable angina pectoris: executive summary: the task force on the management of stable angina pectoris of the European society of cardiology. *Eur Heart J* 2006;**27**:1341–81.
5. **Nagel E**, Klein C, Paetsch I, *et al.* Magnetic resonance perfusion measurements for the noninvasive detection of coronary artery disease. *Circulation* 2003;**108**:432–7.
6. **Nandalur KR**, Dwamena BA, Choudhri AF, *et al.* Diagnostic performance of stress cardiac magnetic resonance imaging in the detection of coronary artery disease: a meta-analysis. *J Am Coll Cardiol* 2007;**50**:1343–53.

7. **Paetsch I**, Jahnke C, Wahl A, *et al.* Comparison of dobutamine stress magnetic resonance, adenosine stress magnetic resonance, and adenosine stress magnetic resonance perfusion. *Circulation* 2004;**110**:835–42.
8. **Gibbons RJ**, Abrams J, Chatterjee K, *et al.* ACC/AHA 2002 guideline update for the management of patients with chronic stable angina—summary article: a report of the American College of Cardiology/American Heart Association Task Force on Practice Guidelines (Committee on the Management of Patients with Chronic Stable Angina). *Circulation* 2003;**107**:149–58.
9. **Houghton JL**, Frank MJ, Carr AA, *et al.* Relations among impaired coronary flow reserve, left ventricular hypertrophy and thallium perfusion defects in hypertensive patients without obstructive coronary artery disease. *J Am Coll Cardiol* 1990;**15**:43–51.
10. **Fragasso G**, Lu C, Dabrowski P, *et al.* Comparison of stress/rest myocardial perfusion tomography, dipyridamole and dobutamine stress echocardiography for the detection of coronary disease in hypertensive patients with chest pain and positive exercise test. *J Am Coll Cardiol* 1999;**34**:441–7.
11. **Costa MA**, Shoemaker S, Futamatsu H, *et al.* Quantitative magnetic resonance perfusion imaging detects anatomic and physiologic coronary artery disease as measured by coronary angiography and fractional flow reserve. *J Am Coll Cardiol* 2007;**50**:514–22.
12. **Lanza GA**, Buffon A, Sestito A, *et al.* Relation between stress-induced myocardial perfusion defects on cardiovascular magnetic resonance and coronary microvascular dysfunction in patients with cardiac syndrome X. *J Am Coll Cardiol* 2008;**51**:466–72.
13. **Panting JR**, Gatehouse PD, Yang GZ, *et al.* Abnormal subendocardial perfusion in cardiac syndrome X detected by cardiovascular magnetic resonance imaging. *N Engl J Med* 2002;**346**:1948–53.
14. **Di MA**, Bruno I, Sestito A, *et al.* Cardiac adrenergic nerve function and microvascular dysfunction in patients with cardiac syndrome X. *Heart* 2009;**95**:550–4.
15. **Klem I**, Heitner JF, Shah DJ, *et al.* Improved detection of coronary artery disease by stress perfusion cardiovascular magnetic resonance with the use of delayed enhancement infarction imaging. *J Am Coll Cardiol* 2006;**47**:1630–8.
16. **Mahrholdt H**, Klem I, Sechtem U. Cardiovascular MRI for detection of myocardial viability and ischaemia. *Heart* 2007;**93**:122–9.
17. **Simonetti OP**, Kim RJ, Fieno DS, *et al.* An improved MR imaging technique for the visualization of myocardial infarction. *Radiology* 2001;**218**:215–23.
18. **Mahrholdt H**, Goedecke C, Wagner A, *et al.* Cardiovascular magnetic resonance assessment of human myocarditis: a comparison to histology and molecular pathology. *Circulation* 2004;**109**:1250–8.
19. **Klem I**, Greulich S, Heitner JF, *et al.* Value of cardiovascular magnetic resonance stress perfusion testing for the detection of coronary artery disease in women. *JACC Cardiovasc Imaging* 2008;**1**:436–45.
20. **Vermeltoort IA**, Bondarenko O, Raijmakers PG, *et al.* Is subendocardial ischaemia present in patients with chest pain and normal coronary angiograms? A cardiovascular MR study. *Eur Heart J* 2007;**28**:1554–8.
21. **Mohri M**, Koyanagi M, Egashira K, *et al.* Angina pectoris caused by coronary microvascular spasm. *Lancet* 1998;**351**:1165–9.
22. **Gould KL**, Lipscomb K, Hamilton GW. Physiologic basis for assessing critical coronary stenosis. Instantaneous flow response and regional distribution during coronary hyperemia as measures of coronary flow reserve. *Am J Cardiol* 1974;**33**:87–94.
23. **Sun H**, Mohri M, Shimokawa H, *et al.* Coronary microvascular spasm causes myocardial ischemia in patients with vasospastic angina. *J Am Coll Cardiol* 2002;**39**:847–51.
24. **Cheitlin MD**, Armstrong WF, Aurigemma GP, *et al.* ACC/AHA/ASE 2003 guideline update for the clinical application of echocardiography: summary article: a report of the American College of Cardiology/American Heart Association Task Force on Practice Guidelines (ACC/AHA/ASE Committee to Update the 1997 Guidelines for the Clinical Application of Echocardiography). *Circulation* 2003;**108**:1146–62.
25. **Hendel RC**, Verani MS, Miller DD, *et al.* Diagnostic utility of tomographic myocardial perfusion imaging with technetium 99m furifosmin (Q12) compared with thallium 201: results of a phase III multicenter trial. *J Nucl Cardiol* 1996;**3**:291–300.
26. **Hendel RC**, Budoff MJ, Cardella JF, *et al.* ACC/AHA/ACR/ASE/ASNC/HRS/NASCI/RSNA/SAIP/SCAI/SCCT/SCMR/SIR 2008 Key Data Elements and Definitions for Cardiac Imaging. A Report of the American College of Cardiology/American Heart Association Task Force on Clinical Data Standards (Writing Committee to Develop Clinical Data Standards for Cardiac Imaging). *Circulation* 2009;**119**:154–86.
27. **Arbogast R**, Bourassa MG. Myocardial function during atrial pacing in patients with angina pectoris and normal coronary arteriograms. Comparison with patients having significant coronary artery disease. *Am J Cardiol* 1973;**32**:257–63.
28. **Camici PG**. Is the chest pain in cardiac syndrome X due to subendocardial ischaemia? *Eur Heart J* 2007;**28**:1539–40.
29. **Wu EB**. Microvascular dysfunction in patients with cardiac syndrome X. *Heart* 2009;**95**:521.
30. **Panza JA**. Myocardial ischemia and the pains of the heart. *N Engl J Med* 2002;**346**:1934–5.
31. **Motz W**, Vogt M, Rabenau O, *et al.* Evidence of endothelial dysfunction in coronary resistance vessels in patients with angina pectoris and normal coronary angiograms. *Am J Cardiol* 1991;**68**:996–1003.
32. **Motz W**, Scheler S, Strauer BE. [Coronary microangiopathy in hypertensive heart disease: pathogenesis, diagnosis and therapy]. *Herz* 1995;**20**:355–64.
33. **Just H**, Frey M, Zehender M. Calcium antagonist drugs in hypertensive patients with angina pectoris. *Eur Heart J* 1996;**17**(Suppl G):20–4.
34. **Motz W**, Strauer BE. Improvement of coronary flow reserve after long-term therapy with enalapril. *Hypertension* 1996;**27**:1031–8.
35. **Schwartzkopff B**, Brehm M, Mundhenke M, *et al.* Repair of coronary arterioles after treatment with perindopril in hypertensive heart disease. *Hypertension* 2000;**36**:220–5.
36. **Bugiardini R**, Manfrini O, Pizzi C, *et al.* Endothelial function predicts future development of coronary artery disease: a study of women with chest pain and normal coronary angiograms. *Circulation* 2004;**109**:2518–23.
37. **Bugiardini R**, Bairey Merz CN. Angina with "normal" coronary arteries: a changing philosophy. *JAMA* 2005;**293**:477–84.