



Acta Scientiae Veterinariae

ISSN: 1678-0345

ActaSciVet@ufrgs.br

Universidade Federal do Rio Grande do
Sul
Brasil

Baqir, Senan; Al Azri, Horiya; Al Rasbi, Khalid; Mastromonaco, Gabriela; Gartley, Cathy
Skin Lipoma in an Arabian Leopard (*Panthera pardus nimr*)

Acta Scientiae Veterinariae, vol. 42, 2014, pp. 1-6

Universidade Federal do Rio Grande do Sul

Porto Alegre, Brasil

Available in: <http://www.redalyc.org/articulo.oa?id=289039188017>

- How to cite
- Complete issue
- More information about this article
- Journal's homepage in redalyc.org

redalyc.org

Scientific Information System

Network of Scientific Journals from Latin America, the Caribbean, Spain and Portugal

Non-profit academic project, developed under the open access initiative

Skin Lipoma in an Arabian Leopard (*Panthera pardus nimr*)

Senan Baqir¹, Horiya Al Azri², Khalid Al Rasbi³, Gabriela Mastromonaco⁴ & Cathy Gartley⁵

ABSTRACT

Background: The Arabian leopard (*Panthera pardus nimr*) is the largest living felid in the arid Arabian Peninsula and classified on the IUCN red list as critically endangered. Unlike felids, neoplasia prevalence in canids such as benign lipoma and malignant liposarcoma has been long and well documented. Only until recently a plethora of reports emerged demonstrating that neoplasia occurrence in wild exotic felids is prevailed more than expected. Soft tissue tumors arise from fatty cells form either a benign lipoma or a dangerously malignant liposarcoma. Alarming though, such cellular transformation might endanger the life of an already endangered animal.

Case: An intact Arabian male leopard living in captivity at the Oman wildlife animal breeding center (N23.70 E58.09 A5.80 m) aged approximately 18 years and weight 31 kg was admitted to the veterinary clinic for semen collection and routine physical examination. The animal was identified with two large adjacent subcutaneous masses on the upper rear left limb, clinically resembling that of a lipomatosis. Only one large tissue mass was surgically excised from the base with no incident of bleeding. Gross examination revealed a soft, smooth, rubbery, homogeneous, lack of internal fluid and whitish color lobule. Morphometry measurement of the mass shows that the weight, diameter, circumference, thickness and surface area were 3.6 gm, 2.6 cm, 10.2 cm, 3 cm and 17.8 cm³ respectively. On visual examination, neither mucin fluid nor mucosal ulcerations were detected. Microscopically, dark discrete spots were observed on the anterior central and periphery of the mass surface outgrowth. Moreover, histopathological diagnoses with haematoxylin and eosin (HE), masson fontana (MF) and elastic verrohof van giesson (EVG) revealed normal nuclear and non-granular cytoplasm resembling that of a fatty cell originating from a fat adipose tissue. Adipocytes had reasonable amounts of cytoplasm and well defined borders. The nuclei were round to oval shape and no cells were found to be multinucleated. No evidence of high nuclear cytoplasmic ratio was observed. Few lymphocytes and plasma cells were present with no visible lymphatic vessels. Taken together, the lesion was diagnosed as a lobulated soft mass resembling that of an adipose tissue, specifically a benign neoplastic lipoma.

Discussion: To date not a single report describes maladies in big cats from arid regions. This is the first study to demonstrate the occurrence of neoplasia in a wild felid namely; the Arabian leopard. Additionally, while recent reports have shown neoplasia occurrence in the *Panthera* subspecies in tropical, polar and temperate zones, this is the first report to manifest the disease in an arid region. The increase in neoplasm frequency in exotic felids is a concerning fact as numerous members of the *Panthera* family including the Arabian leopard are classified by the IUCN as endangered or critically endangered species. With less than 200 animals in the wild, only 14 founder individuals in captivity and an aged female population the occurrence of lipoma tumors in the Arabian leopard is a worrisome sign. Taken together, the data suggests the rise of uncommon diseases in carnivores and ubiquitously around different climate zones of the world. Thus highlights the importance of routine physical examinations, investing substantially in diagnostic equipment and healthcare endowment in captive exotic felids.

Keywords: neoplasia, Arabian leopard, critically endangered species, lipoma, *Panthera pardus nimr*.

INTRODUCTION

The Arabian leopard (*Panthera pardus nimr*) [21] is the largest living felid in the Arabian Peninsula and the smallest leopard subspecies [20]. The Arabian leopard is native to the arid mountainous region of the Arabian Peninsula [5,18] and classified on the IUCN red list as critically endangered with an estimated population of less than 200 animals in the wild [23] and only 82 reared in captivity [6]. Besides being one of the rarest big cats, it is the least studied in the *Panthera* genus [10]. To date not a single case report describes maladies in the captive Arabian leopard including neoplasms. In canids, the prevalence of tumors such as benign lipoma [40,13] and malignant myxoid liposarcoma [31,12] has been long and well documented. Similarly, with less frequency however, much of the neoplasm cases in felids have been reported in the domestic cat, this include basal cell tumor, mast cell tumor, squamous cell carcinoma, fibrosarcoma [33], angiofibrolipoma [28] and urinary bladder lipoma [26].

Only until recently, a plethora of neoplasm cases are being reported in captive big cats such as benign gastric tumors in the snow leopard [11], mast cell tumors in the Sumatran tiger [15], meningioma in the Bengal tiger [1], and in the case of African lion; dermal melanoma [39], squamous carcinoma [35], ocular melanoma and mammary carcinoma [9], mesothelioma [4], malignant lymphoma [17], lung cholangiocellular carcinoma [19] and oligodendroglioma [42].

This report describes for the first time the occurrence of a benign lipoma neoplasm in a *Panthera* subspecies reared in captivity in an arid region, namely the critically endangered Arabian leopard.

CASE

An intact Arabian male leopard living in captivity at the Oman wildlife animal breeding center (N23.70 E58.09 A5.80 m) aged approximately 18 years and weight 31 kg was admitted to the veterinary clinic for semen collection and routine physical examination. The maximum and minimum day temperatures at the time of investigation were 26°C and 19°C respectively. The male leopard was reared in captivity from a very early age and housed individually in a large indoor/outdoor enclosure and occasionally paired with a female for mating. The leopard was in good physical condition and no symptoms of limping were observed.

The daily diet consisted of frozen/thawed chicken and extra lean goat or sheep meat.

On physical examination two large well circumscribed subcutaneous annular structures adjacent to each other were found on the upper rear left limb, clinically resembling that of a lipomatosis. Surgical excision of only one of the large masses from the base was performed with no incident of bleeding. Surgical intervention lasted 2 h only and the male was returned to the enclosure in a semi-conscious condition.

Histopathological examination was conducted at the department of pathology, Sultan Qaboos University Hospital (SQUH) by tissue fixation with 10% neutral buffered formalin then dehydrated in a series of increasing alcohol concentrations (70%, 95% and 100%), placed into a clearing agent Xylene¹ then transferred to paraffin wax. All the steps were carried out with the use of an automated tissue processing unit². Samples were then embedded in paraffin wax and sectioned at 3-4 µm with a rotary microtome³. Three stains namely; Haematoxylin and Eosin (HE), Masson Fontana (MF) and Elastic Verrhof Van Giesson (EVG) were used on different sections with the use of an automated slide stainer⁴ for HE and manually in the case of MF and EVG. Slides were then visualized with a light microscope⁵ and images were captured with a digital camera⁶ and processed with DP Manager Software⁷. Gross examination revealed a soft, smooth, rubbery, homogeneous, lack of internal fluid and whitish color lobule (Figure 1).




Figure 1. Photographic image of gross pathology depicting a large lobulated tissue mass. Morphometry analysis of the length, width, diameter, circumference, weight, thickness and surface area. Inset: reverse view showing dark pigment on the central and periphery of the mass (*).

Morphometry measurement of the mass shows that the weight, diameter, circumference, thickness and surface area were 3.6 gm, 2.6 cm, 10.2 cm, 3 cm and 17.8 cm³ respectively (Figure 1). Visually, neither mucin fluid nor mucosal ulcerations were detected in the outgrowth. Dark discrete spots were observed on the anterior central and periphery of the mass surface (Figure 1 inset). Therefore was suspected to be a malignant neoplastic mass. Histopathological examination revealed normal rounded nuclei with a non-granular cytoplasm resembling that of a fatty cell originating from a fat adipose tissue. Few lymphocytes and plasma cells were present with no visible lymphatic vessels. Adipocytes had reasonable amounts of cytoplasm and well defined borders. The nuclei were round to oval shape and no cells were found to be multinucleated (Figure 2).

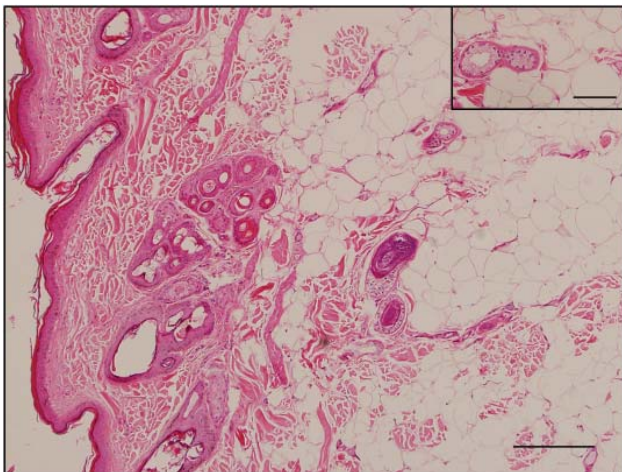


Figure 2. Photomicrograph of a Haematoxylin and Eosin (HE) stained section. Fat cells displaying typical adipose tissue characteristics. Increase in the size and number of adipocyte cells in the hypodermis layer [Bar = 100 µm]. Inset: Normal cellular appearance with round shaped nuclei and absence of multinucleation [Bar = 50 µm].

No evidence of high nuclear cytoplasmic ratio were observed with HE staining. However, a slight increase in the size and number of infiltrative fatty tissue (adipocytes cells) was observed in the hypodermis (Figure 2). Signs of a malignant lipoma such as primitive lipoblasts and frank malignant features were absent. The elastoid degeneration found in some connective tissue regions was of an insignificant degree.

Tissue pattern examination with EVG dye demonstrate the presence of mild to dense areas of collagenous stroma and multiple layers of elastic fibers

(Figure 3). MF stain, which is commonly used for the identification of melanin in routine histopathology, has shown normal melanin deposition and distribution (Figure 4). Moreover, no inflammation signs were present in the mass evidently by the fact that inflammatory component composed of neutrophils and macrophages were absent in all sections.

Five months after surgery no evidence of recurrence were observed. Taken together, gross and histopathological data suggest that the lesion was diagnosed as a benign fatty lipoma tumor rather than a malignant liposarcoma outgrowth. Electron microscopy examination was not undertaken as the data from three types of histological staining failed to show any sign of malignancy.

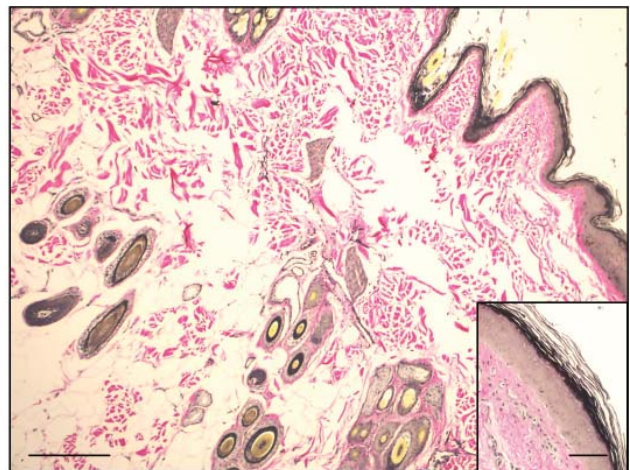


Figure 3. Photomicrograph of an Elastic Verrhof Van Giesson (EVG) stained section. Mild to dense areas of red collagenous stroma and multiple layers of elastic fiber arrangements [Bar = 100 µm]. Inset: Elastic fibers in epidermis layer [Bar = 75 µm].

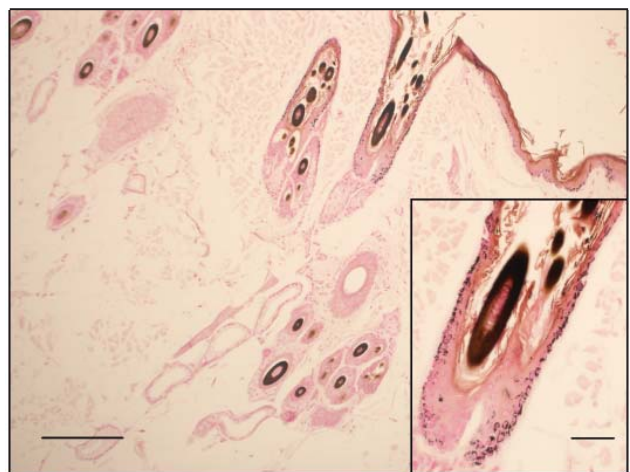

Figure 4. Photomicrograph of a Masson Fontana (MF) stained section. Reasonable melanin deposition and distribution in epidermal layer. Presence of a hair follicle with the absence of inflammatory components [Bar = 100 µm]. Inset: Melanocytes surrounding the hair follicle [Bar = 60 µm].

DISCUSSION

The current reported case had identical morphological and clinical characteristics of an enlarged neoplasm outgrowth. While lipoma/liposarcoma incidence has been reported in canine species [22,37] the occurrence in wild felids is rare and neither reported nor fully understood. Recently however, a spike in neoplasia cases from various climate zones in the *Panthera* subspecies has been witnessed, including this report and others [1,4,9,12,16]. Similarly, lipomatosis, a neoplasm state where multiple lipomas are present on the body is not usually reported in exotic felids. In fact, while we report the occurrence in the Arabian leopard, only two other retrospective studies have shown the prevalence of lipomatosis in the spotted leopard [8] and in the form of myelolipomas in the cheetah and Siberian tiger [29].

The increase in neoplasm frequency in felids is a concerning fact as numerous members of this family are classified by the IUCN as endangered or critically endangered species. With less than 200 animals in the wild, only 14 founder individuals in captivity [27] and an aged female population [7] the occurrence of lipoma tumors in the Arabian leopard is a worrisome sign. While the long term pathological impact of fatty tumor depositions remains unclear in leopards, recurrence rate in other species following excision remains very high especially in infiltrative lipomas that tend to clinically reappear after several years. Although the causes for soft tissue tumor formation in wild felid species remain obscure, the majority of the studies points to the fact that prevalence arise at late adulthood and in captive populations. In fact, it has been shown that neoplasia in bears is encountered solely in captive and aged animals [34]. While most of the reports in the *Panthera* subspecies are based on captive populations it has yet to be proven that neoplasm occurs in wild individuals as well.

Malignant transformation of lipomas into liposarcomas is a rare incidence with only a few cases of transformation have been described in bone and kidney lipomas. Diagnostically, distinguishing between a fatty mass tumor, such as a benign lipoma, and malignant liposarcoma is a challenging task [2,38]. The diagnosis requires the use of one or more costly and labour-intensive technical methods such as ultrasonography [38,43], computed tomography (CT Scan) [36], magnetic resonance imaging (MRI)

[14,24], electron microscopy (EM) [32], biopsy and immunohistochemistry [36].

While much of the clinical diagnostic methodology is readily provided to humans, applying the same techniques to wild carnivores is extremely difficult as it requires multiple rounds of anaesthetics that endanger the life of an already endangered animal.

Equally dangerous, melanoma and lipoma malignancies have been successfully treated in the canine species with the use of human tyrosinase vaccine that coincided with extended survival [3,25]. However, the use of human tyrosinase vaccine or other analogs has yet to prove efficacy and longevity in wild felid species [39].

In summary, according to gross and histopathological examination, this is the first report to reveal neoplasia occurrence in an arid zone of a subcutaneous benign skin lipoma in the critically endangered captive Arabian leopard. This report is in agreement with earlier studies that demonstrate the rise of emerging diseases in wildlife animals [16,41] and more specifically in carnivores [30]. This in turn highlights the importance of routine physical examinations, investing substantially in diagnostic equipment and healthcare endowment in captive exotic felids.

SOURCES AND MANUFACTURERS

¹Xylene, Fisher Scientific UK Ltd, Loughborough, UK.

²Sakura Tissue Tek VIP3000, RBC, Japan.

³RM2135, Leica, Wetzlar, Germany.

⁴Automat Sakura DRS601, Japan.

⁵BX51, Olympus, Japan.

⁶DP70, Olympus, Japan.

⁷Olympus Optical, Japan.

Funding. The research was funded by a Sultan Qaboos University internal grant (IG/SCI/BIOL/11/02) and funds from the veterinary services of the royal court affairs.

Acknowledgments. The authors would like to thank the keepers Hamood AL-Salti and Awadh AL-Shakaili at the Oman Wildlife breeding center for handling the animals, Asma Bani Orabah and Noura Al Zeheimi for technical assistance, Dr. Andrzej Golachowski and Dr. Barbara Golachowski for anesthetising the animals.

Ethical approval. Restraining and anesthetizing the animal was made according to well defined international protocols and approved by the bioethics committee at Sultan Qaboos University.

Declaration of interest. The authors report no conflicts of interest. The authors alone are responsible for the content and writing of the paper.

REFERENCES

- 1 Akin E.Y., Baumgartner W.A., Lee J.K. & Beasley M.J. 2013. Meningioma in a Bengal tiger (*Panthera tigris tigris*). *Journal of Zoo and Wildlife Medicine*. 44(3): 761-764.
- 2 Alaggio R., Coffin C.M., Weiss S.W., Bridge J.A., Issakov J., Oliveira A.M. & Folpe A.L. 2009. Liposarcomas in young patients: a study of 82 cases occurring in patients younger than 22 years of age. *American Journal of Surgical Pathology*. 33(5): 645-658.
- 3 Bergman P.J., McKnight J., Novosad A., Charney S., Farrelly J., Craft D., Wulderk M., Jeffers Y., Sadelain M., Hohenhaus A.E., Segal N., Gregor P., Engelhorn M., Riviere I., Houghton A.N. & Wolchok J.D. 2003. Long-Term Survival of Dogs with Advanced Malignant Melanoma after DNA Vaccination with Xenogeneic Human Tyrosinase A Phase I Trial. *Clinical Cancer Research*. 9(4): 1284-1290.
- 4 Bollo E., Scaglione F.E., Tursi M., Schröder C., Degiorgi G., Belluso E., Capella S. & Bellis D. 2011. Malignant pleural mesothelioma in a female Lion (*Panthera leo*). *Research in Veterinary Science*. 91: 116-118.
- 5 Breitenmoser U., Breitenmoser C., Mallon D. & Edmonds J.A. 2006. Status and Conservation of the Leopard on the Arabian Peninsula. *Cat Specialist Group, IUCN [Cat Newsletter]*. pp.1-48.
- 6 Budd J. 2011. Arabian leopard (*Panthera pardus nimr*) *International Studbook*. 7, p. 48.
- 7 Budd J. & Leus K. 2011. The Arabian Leopard (*Panthera pardus nimr*) conservation breeding program. *Zoology in the Middle East*. 54(3): 141-150.
- 8 Burke T.J. 1969. Multiple lipomas in a spotted leopard (*Panthera pardus*). *Journal of the American Veterinary Medical Association*. 155(7): 1099-1100.
- 9 Cagnini D.Q., Salgado B.S, Linardi J.L., Grandi F., Rocha R.M., Rocha N.S., Teixeira C.R., Del Piero F. & Sequeira J.L. 2012. Ocular melanoma and mammary mucinous carcinoma in an African lion. *BMC Veterinary Research*. 8(176): 1-5.
- 10 Cunningham P. & Gross C. 2000. Reproduction and development of the Arabian leopard, *Panthera pardus nimr*, in captivity. *Zoology in the Middle East*. 20(1): 9-14.
- 11 Dobson E.C., Naydan D.K., Raphael B.L. & McAloose D. 2013. Benign gastric neuroendocrine tumors in three snow leopards (*Panthera unica*). *Journal of Zoo and Wildlife Medicine*. 44(2): 441-446.
- 12 Doster A.R., Tomlinson M.J., Mahaffey E.A. & Jordan C.W. 1986. Canine liposarcoma. *Veterinary Pathology*. 23(1): 84-87.
- 13 Gleiser C.A., Jardine J.H., Raulston G.L. & Gray K.N. 1979. Infiltrating lipomas in the dog. *Veterinary Pathology*. 16(5): 623-624.
- 14 Goodnight A.L., Traslavina R.P., Emanuelson K., Affolter V.K., Gaffney P.M., Vernau W., Williams C., Wu C.I., Sturges B.K. & Lowenstine L.J. 2013. Squamous cell carcinoma of the anal sac in a spotted hyena (*Crocuta crocuta*). *Journal of Zoo and Wildlife Medicine*. 44(4): 1068-1074.
- 15 Graille M., Huyghe F.P. & Nicolier A. 2013. Mastocytemia associated with a visceral mast cell tumor in a Sumatran tiger (*Panthera tigris*). *Journal of Zoo and Wildlife Medicine*. 44(1): 189-192.
- 16 Gummow B. 2010. Challenges posed by new and re-emerging infectious diseases in livestock production, wildlife and humans. *Livestock Science*. 130(1): 41-46.
- 17 Harrison T.M., McKnight C.A., Sikarskie J.G., Kitchell B.E., Garner M.M., Raymond J.T., Fitzgerald S.D., Valli V.E., Agnew D. & Kiupel M. 2010. Malignant lymphoma in African lions (*Panthera leo*). *Veterinary Pathology*. 47(5): 952-957.
- 18 Harrison D. & Bates P. 1991. *The mammals of Arabia*. 2nd edn. Kent: Harrison Zoological Museum, 354p.
- 19 Hedau M., Raut S.S., Bhandarkar A.G., Ganorkar A.G. & Ingle K.S. 2008. Cholangiocellular carcinoma in a leopard (*Panthera pardus*). *Indian Journal of Veterinary Pathology*. 32(1): 84-85.
- 20 Hellyer P. & Aspinnall S. 2005. *The emirates - A natural history*. London: Trident Press Ltd., pp.307-344
- 21 Hemprich F.W. & Ehrenberg C.G. 1833. Symbolae physicae seu icones et descriptiones corporum naturalium novorum aut minus cognitorum, quae ex itineribus per Arabiam. *Pars zoological*. 1, 257p.
- 22 Horta R.S., Lavalle G.E., Rodrigues A.A.M., Costa P.M, Tavares S.E.M & Carneiro R.A. 2013. Total resection of the lower urinary tract without the need of pelvic osteotomy in the treatment of urethral neoplasia in a dog. *Acta Scientiae Veterinariae*. 41(1): 14.

- 23 IUCN - Mallon D. & Budd K. 2011. IUCN Red list; Regional red list status of carnivores in the Arabian Peninsula. IUCN, Gland, Switzerland and Cambridge, UK and environment and protected areas authority, Sharjah, UAE. Sharjah: IUCN, 49p.
- 24 Jaovisidha S., Suvikapakornkul Y., Woratanarat P., Subhadrabandhu T., Nartthanarung A & Siritwongpairat P. 2010. MR imaging of fat-containing tumours: the distinction between lipoma and liposarcoma. *Singapore Medical Journal*. 51(5): 418-423.
- 25 Liao J.C., Gregor P., Wolchok J.D., Orlandi F., Craft D., Leung C., Houghton A.N. & Bergman P.J. 2006. Vaccination with human tyrosinase DNA induces antibody responses in dogs with advanced melanoma. *Cancer Immunology*. 6: 8-18
- 26 Khodakaram-Tafti A., S. Shirian N. Vesal & Hadadi S. 2011. Lipoma of the Urinary Bladder in a Cat. *Journal of Comparative Pathology*. 144(2-3): 212-213.
- 27 Leus K. 2011. Captive breeding and conservation. *Zoology in the Middle East*. 54(3): 151-158.
- 28 Liggett A.D., K.S. Frazier & Styer E.L. 2002. Angiolipomatous tumors in dogs and a cat. *Veterinary Pathology*. 39: 286-289.
- 29 Lombar L.S., Fortna H.M., Garner F.M. & Brynjolfsson G. 1968. Myelolipomas of the liver in captive wild Felidae. *Pathology Veterinary*. 5: 127-134.
- 30 McCarthy A.J., Shaw M.A. & Goodman S.J. 2007. Pathogen evolution and disease emergence in carnivores. *Proceeding of the Royal Society, Biological Sciences*. 274 (1629): 3165-3174.
- 31 Messick J.B. & Radin M.J. 1989. Cytologic, histologic, and ultrastructural characteristics of a canine myxoid liposarcoma. *Veterinary Pathology*. 26: 520-522.
- 32 Mete A., Woods L., Famini D. & Anderson M. 2012. Disseminated Pleomorphic Myofibrosarcoma in a Grizzly Bear (*Ursus arctos horribilis*). *Journal of Comparative Pathology*. 147(2-3): 376-380.
- 33 Miller M.A., Nelson S.L., Turk J.R., Pace L.W., Brown T.P., Shaw D.P., Fischer J.R. & Gosser H.S. 1991. Cutaneous neoplasia in 340 cats. *Veterinary Pathology*. 28: 389-395.
- 34 Mörner T., Eriksson H., Bröjer C., Nilsson K., Uhlhorn H., Agren E., af Segerstad C.H., Jansson D.S. & Gavier-Widén D. 2005. Diseases and mortality in free-ranging brown bear (*Ursus arctos*), gray wolf (*Canis lupus*), and wolverine (*Gulo gulo*) in Sweden. *Journal of Wildlife Diseases*. 41(2): 298-303.
- 35 Mwase M., Mumba C., Square D., Kawarai S. & Madarame H. 2013. Cutaneous Squamous Cell Carcinoma presenting as a Wound with Discharging Sinus Tracts in a Wild African Lion (*Panthera leo*). *Journal of Comparative Pathology*. 149(4): 520-523.
- 36 Nikolaidis P., Silverman S.G., Cibas E.S., Vansonnenberg E., Rybicki F.J., Manola J.B., Tuncali K., Karshbaum S.H., Singer S., Fletcher C.D.M. & Demetri G.D. 2005. Liposarcoma subtypes: identification with computed tomography and ultrasound-guided percutaneous needle biopsy. *European Journal of Radiology*. 15(2): 383-389.
- 37 Pinho S.S., Carvalho S., Cabral J., Reis C.A. & Gärtner F. 2012. Canine tumors: a spontaneous animal model of human carcinogenesis. *Journal of Laboratory Clinical Medicine*. 159(3): 165-172.
- 38 Righi A., Pantalone O. & Tagliaferri G. 2012. Giant lipoma of the thigh: A case report. *Journal of Ultrasound*. 15(2): 124-126.
- 39 Steeil J.C., Schumacher J., Baine K., Ramsay E.C., Sura P., Hodshon R., Donnell R.L. & Lee N.D. 2013. Diagnosis and treatment of a dermal malignant melanoma in an African lion (*Panthera leo*). *Journal of Zoo and Wildlife Medicine*. 44(3): 721-727.
- 40 Strafuss A., Smith J., Kennedy G.A. & Dennis S. 1973. Lipomas in dogs. *Journal of the American Animal Hospital Association*. 9(6): 555-561.
- 41 Thompson R.C.A., Lymbery A.J. & Smith A. 2010. Parasites, emerging disease and wildlife conservation. *International Journal of Parasitology*. 40(10): 1163-1170.
- 42 Tucker A.R., Ramsay E.C. & Donnell R.L. 2008. Oligodendroglioma in an African lion (*Panthera leo*). *Journal of Zoo and Wildlife Medicine*. 39(4): 650-654.
- 43 Wu S., Tu R., Liu G. & Shi Y. 2013. Role of ultrasound in the diagnosis of common soft tissue lesions of the limbs. *Ultrasound quarterly*. 29(1): 67-71.

