
Chapter 8

Progressive Neurodegeneration of Retina in Alzheimer's Disease — Are β -Amyloid Peptide and Tau New Pathological Factors in Glaucoma?

Kin Chiu, Kwok-Fai So and
Raymond Chuen-Chung Chang

Additional information is available at the end of the chapter

<http://dx.doi.org/10.5772/53428>

1. Introduction

Alzheimer's disease (AD) is a neurodegenerative disease affecting 5.4 million people globally and is predicated to affect over 100 million people worldwide by 2050 [1]. It is the most common form of progressive cognitive decline. As originally described by Alois Alzheimer in 1907, AD is associated with extracellular amyloid plaque formation and intracellular neurofibrillary tangles in the brain regions involved in learning and memory processes [2]. A major problem of the disease is, perhaps, altered proteolytic processing of the amyloid precursor protein (APP) resulting in the production and aggregation of neurotoxic forms of $A\beta$. Amyloid plaques are extracellular deposits of fibrils and amorphous aggregates of β -amyloid ($A\beta$). Compact plaques have been considered to be associated with neuronal and synaptic loss, dystrophic neurites, hypertrophic astrocytes, activated microglia cells, and various features of inflammatory processes. The intracellular neurofibrillary tangles consist of paired helical filaments formed by the microtubule-associated protein tau that exhibits hyperphosphorylation and oxidative modifications. Increasing lines of evidence have shown that visual impairment is associated with the prevalence of AD [3]-[5].

Glaucoma is recognized as an age-related neurodegenerative disorder – optic neuropathy. Being the second leading cause of blindness, it is estimated that glaucoma will affect more than 80 million people worldwide with at least 6 - 8 million individuals becoming bilaterally blind by the year 2020 [6]. Comparing to normal population, the prevalence of glaucoma is about 2.5 times higher in AD patients [7]. In 2011, Nucci and co-workers reported that glaucoma progression was associated with altered levels of $A\beta$ and tau proteins in cerebral spinal fluid

[8]. The intravitreal levels of $A\beta_{1-42}$ are significantly decreased and that of tau are markedly increased in glaucoma patients [9]. We propose that accumulation of $A\beta$ and hyperphosphorylated tau protein should be considered to be new pathological factors to propagate neurodegeneration in glaucoma.

1.1. Amyloid precursor protein and functions

APP is a type I transmembrane protein with a single transmembrane domain, a large extracellular ectodomain, and a short cytoplasmic tail [10]. The processing of APP to $A\beta$ is an important event in the pathogenesis of AD [11]. The processing is initiated by cleavage of APP by α -secretase within the $A\beta$ region, and by cleavage by β -secretase (BACE) at the amino terminus of $A\beta$, leading to the secretion of large soluble ectodomains. In pathological situation, if the carboxyl-terminal fragments is processed by γ -secretase resulting in the production of $A\beta$, p3, and the APP intracellular domain (AICD). In humans, the *APP* gene is located on chromosome 21 with three major isoforms (APP695, APP751 and APP770) arising from alternative splicing [12]. APP is highly expressed in neurons where the protein is rapidly transported down the axons to nerve terminus in the brain and retina [13].

As the processing of APP to $A\beta$ is an important event in the pathogenesis of AD, great effort has been devoted to understand biological functions of APP since its cloning in 1988 [10]. *In vitro* and *in vivo* studies have shown important activities of APP in modulating neurite outgrowth [14], synaptic activity [15]-[17], metal homeostasis [18], [19], synaptic transmission [20] and synaptic adhesion at the neuromuscular junction [21]. In retina, APP plays a role in retinogenesis. In APP knockout (KO) mice, differentiation of some inner retinal neurons, specifically horizontal and amacrine cells are hampered in APP-KO mice during early postnatal development [22]. However, normal numbers of horizontal cells and most types of amacrine cells are found in adult APP-KO mice. The number is similar to adult C57/B6JxSV129 wild type control mice. APP is expressed in inner retina including horizontal, cone bipolar, amacrine and ganglion cells in the APP-KO mice. Although APP is not required for gross retinal structure or visual acuity in adult retina, it is required for the inner retinal function of the rod and cone pathway [23].

1.2. Tau protein and functions

1.2.1. Tau protein

Tau protein is microtubule-associated protein that stabilizes microtubules and able to form aggregation in pathological conditions. Tau is expressed from the gene known as microtubule-associated protein tau (MAPT) on chromosome 17 at position 17q21. Tau is highly expressed in neurons and is abundant in axons [24]. Hyperphosphorylated, insoluble, and filamentous tau proteins were shown to be the main component of neurofibrillary tangles (NFTs), a pathological hallmark of AD [24].

Tau binding to microtubules enables them to play a fundamental role in promoting microtubule assembly and stability; and in turn, affecting intra-neuronal transport of cargos. Detach-

ment of tau from microtubules leads to dysfunction of axonal transport and even retraction of spines[25]. Apart from stabilizing microtubules, tau has a more versatile role in the central nervous system (CNS). Tau regulates the process of neurite extension via its ability to stop microtubule-severing proteins and its facilitative role on nerve growth factor signaling [26]. Tau interacts via its amino-terminal projection domain with the kinase Fyn (a proto-oncogene tyrosine-protein kinase). Fyn phosphorylates the N-methyl-D-aspartate receptor (NMDAR) to link NMDAR to synaptic excitotoxic downstream signaling [27]. Recent findings also reported that Tau can modulate phospholipase C gamma [28], histone deacetylase-6 [29], and heat shock proteins [30]. Tau also interacts with actin via acidic N-terminals, projecting from microtubules for neurite outgrowth and stabilization during the brain development [31]. In tau knockout mice, neurogenesis is severely reduced [32].

1.2.2. Multiple functions of tau in the retina

In the retina, tau not only regulates the cytoskeleton and axonal transport in retinal neurons, but also affects accumulation of $A\beta$ and cell survival signaling. The pivotal roles of tau in retinal functions are summarized in Figure 1.

It has been found that tau is expressed in a gradient manner in retinal ganglion cells (RGC), with higher levels in the terminal parts of axons of developing RGCs. Its localization at the axon plays a role in proper axon development and survival of RGCs [33]. Exposure to okadaic acid resulted in accumulation of phosphorylated tau, followed by distortion of the cytoskeleton leading to growth cone collapse. Hence, tau has been implicated in the process of establishing neuronal axon polarity [34]. Interruption in these transport mechanisms would cause the accumulation of $A\beta$, which can propagate secondary degeneration. Studies based on Tg2576 transgenic mice showed that immunoreactivity of hyperphosphorylated tau was found to be very close to that of $A\beta$ in mouse retina [35].

Tau can be phosphorylated by cyclin-dependent kinase 5 (Cdk5), a proline-directed serine/threonine kinase. Phosphorylation leads tau to dissociate from microtubules and affects its stability. Cdk5 is highly expressed in neuronal axons and growth cones serving to promote neurite outgrowth and migration[36]. To initiate its activation, Cdk5 requires interaction with its activator subunit p35. Cdk5 has been implicated to phosphorylate various substrates to regulate a diverse range of cellular processes in the CNS. Studies have shown that ephrin-A signaling pathway can also lead to the activation of Cdk5. Ephrin-A regulates retinotectal projection via receptor-mediated axon growth repulsion through a complex signaling cascade. Fyn can activate Cdk5 to phosphorylate collapsin response mediator protein (CRMP2) to reduce microtubule assembly[37]. Immunofluorescence studies have shown that activation of Cdk5 occurs downstream of ephrin-A5 signaling to phosphorylate tau in the growth cones and axons of RGCs. These findings suggest that phosphorylation of tau serves as another means to which ephrin-A signaling can induce microtubule reorganization in RGC growth cones[38].

Apart from Cdk5, tau has also been found to interact with calcium/calmodulin-dependent protein kinase II (CaMKII) in the CaMKII- α -associated protein complex in chick retina. Endogenous association of tau with CaMKII- α suggests that it is important in regulating

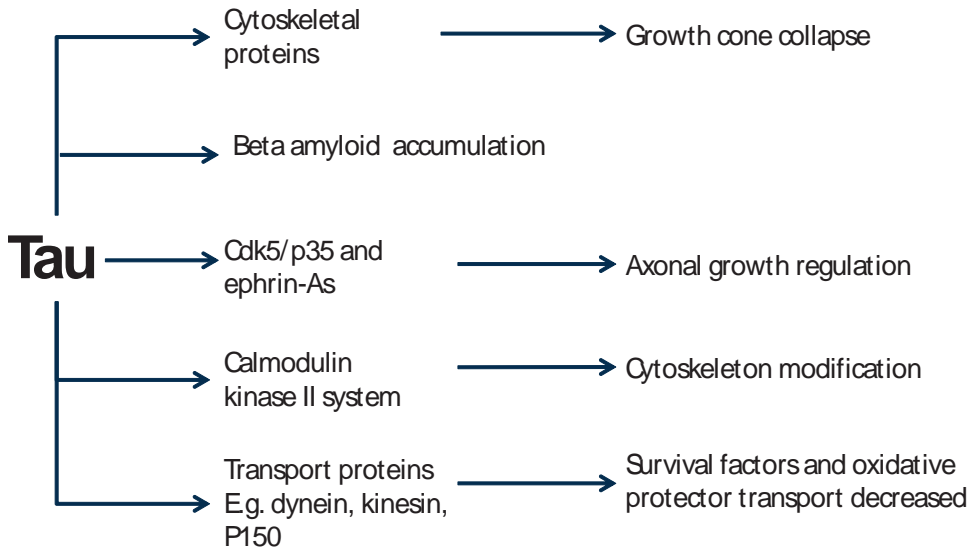


Figure 1. Schematic diagram summarizing the roles of tau in retinal functions. Tau stabilizes microtubules. Dislocation of Tau from microtubules can result in growth cone collapse. Accumulation of β -amyloid ($A\beta$) is an example to trigger phosphorylation of tau and hence detaches from microtubule. Apart from $A\beta$ as a triggering factor, any stimulation of signaling cascade of cdk5, ephrin-A receptor or calmodulin-dependent protein kinase II affecting phosphorylation of tau can also modulate microtubules. Once tau leaves microtubules after phosphorylation, they can easily form aggregation, which can further impair axonal transport mediated by kinesin or dynein. Consequently, mitochondria in the distal part of nerve, nerve terminus or spines cannot obtain protection from the cell body (soma) so that they are collapse and cannot produce energy. Neurodegeneration can unavoidably occur.

cytoskeletal assembly in neurons. Through the phosphorylation of tau, microtubule assembly may be inhibited; and hence, the cellular architecture is disrupted[39].

Abnormally aggregated tau inhibits the transportation of mitochondria by kinesin-like motors towards the cell periphery of rat RGCs. Consequently, neurons with perturbation of mitochondria and peroxisomes suffer from loss of energy production and accumulation of reactive oxygen species (ROS). The anterograde transport of vesicles required for growth cones and synaptic function is retarded. In addition, these neurons may be more vulnerable to oxidative stress[40]. In the RGCs axons of P301S mutant mice, the projection domain of tau interacts with the C-terminus of p150, the major component of the dynein-activator. The co-localization of tau and p150 suggests that tau dysfunction can result in the mislocalization of dynactin in axons, which can result in neurodegeneration[41].

2. Clinical manifestation of visual deficits in Alzheimer's patients

Various visual deficits in AD have been reported since 1987 [42]. Cognitive visual changes have been reported in patients in the early stages of AD [43], including difficulties in reading

and finding objects [44]-[46], depth perception [43] perceiving structure from motion [44], [46]-[48], color recognition [44], [49], and impairment in spatial contrast sensitivity [47], [50]. Previously, these changes have been attributed to neuronal damage to the visual pathways in the brain rather than the retina [51]. However, there are increasing lines of evidence showing that specific AD like pathology (amyloid plaques and NFT) in the brain can be found in the retina. In 2011, Koronyn-Hamaoui and co-workers [52] identified amyloid plaques in the retinas from AD patients as well as patients in mild cognitive impairment.

Cross-sectional imaging of the retina using optical coherence tomography (OCT) has demonstrated a significant reduction of thickness in peripapillary retinal fiber layer (RFL) of patients with early AD when compared with age-matched controls[53]-[57]. The thinning of RFL was observed predominantly in the inferior and superior quadrants, which was consistent with the inferior and superior visual field loss in AD patients[44], [54]. Reduction of the macular thickness has also been reported in AD; and the total volume of the macula is inversely correlated with the severity of the disease[55]. Changes in the optic nerve head have been observed using confocal scanning laser ophthalmoscopy (cSLO). The observed changes include reduced RFL thickness, neuroretinal rim volume and area, and increased cup-disc ratio; suggesting an overall reduction in the number of optic nerve fibers passing through the optic nerve head [58]. These *in vivo* findings are corroborated by the histopathological findings of axonal degeneration in optic nerves, reduced thickness of RFL and a significant reduction in the number of large diameter RGCs in the post-mortem AD retinas [59], [60].

According to the definitions of glaucoma published in 2002 by an international consensus panel [61], glaucoma is thought to be present when at least one eye has typical defects both in structural and functional aspects (optic disc damage and visual field loss, respectively) [62]. Characteristically, the damage indicates the death of RGC in the inner retina and loss of axons in the optic nerve. This structural loss of the axons can be recognized clinically by ophthalmoscope or can be detected by imaging devices such as OCT and scanning laser polarimetry. Besides NFL thinning, the similarities between the ocular effects of AD and glaucoma can be observed in pattern electroretinogram (PERG) responses [63], [64], the type of cell loss (large magnocellular RGC) and possibly the mechanisms for loss of RGC (apoptosis) [65], [66]. This may explain the high incidence of glaucoma in AD patients [7], [67]. The involvement of A β accumulation and hyperphosphorylated tau protein might be important causes of neurodegeneration of RGCs in glaucoma.

3. Retinal degeneration in AD transgenic mice

Since there is a lack of postmortem human retinal samples from AD patients, progress of investigating pathogenesis of retinal neurodegeneration in the AD eyes is slow. Much of the insights have gained from specific gene mutations that account for the familial AD (FAD). The majority (30-40%) of FAD is resulted from autosomal dominant inheritance with mutated genes encoding presenilin 1 (PS1) on the long arm of chromosome 14, presenilin 2 (PS2) on chromosome 1 and amyloid precursor protein (APP) on chromosome 21 [68].

Depending on the number of genes they express, transgenic mice come in three varieties: single (APP, PS1, or Tau), double (APP/PS1, APP/Tau), or triple transgenic (APP/PS1/Tau) [69]. Behavioral studies on AD transgenic mice showed that the mice were suffered from visual dysfunction [70].

Multiple lines of AD transgenic mice have elicited AD-like pathological hallmarks in the retina as disease progresses [69]. The over-expression of APP, the production of soluble A β , and A β deposition will lead to formation of amyloid plaques that can induce cell death via the apoptotic pathway [71]. Even before formation of plaques, oligomeric A β can induce synaptic degeneration. Furthermore, A β plays a role in inducing hyperphosphorylation of tau, which in turn affects the integrity of retinal cells and their synapses in inner nuclear layer (INL) [72]. It has been reported that over-expression of APP, A β and/or tau deposition, neuronal cell loss, changes of retinal glial cell, and vascular changes occur in the retina of AD transgenic mice. The changes of retinal histopathology documented in the AD transgenic mouse models are summarized in Table 1.

3.1. Loss of retinal neurons in AD transgenic mice

In consistent with the findings in the retina of AD patient, reduced retinal thickness between RGCL and ONL was detected in Tg2576 mice [73]. This indicates that there was a loss of either the photoreceptor cells in the ONL (rod and cone cells) or neuronal cells in the inner retinal layers (RGC, horizontal cells, bipolar cells or amacrine cells). In double transgenic mice strain (APP_{swe}/PS1_{M146L}), a significant increase in the number of apoptotic cells in the RGCL was detected by TUNEL staining as the animal grew from 7.8 months to 27 months [11]. By using a different double transgenic mice strain (APP_{swe}/PS1 _{Δ E9}), there was significant increase of TUNEL-positive cells in the RGCL when comparing with age-matched controls. Most recently, direct visualization of apoptotic RGCs in the retina was reported in triple transgenic mouse model of AD [74]. Using a fluorophore-labeled annexin V protein as a marker of apoptosis and cSLO to detect the fluorescence, the triple transgenic mice displayed increased number of RGC apoptosis compared with wild-type controls.

3.2. Over-expression of APP in the AD retina

Compared to the wild-type mice, a significant increase in immunoreactivity of APP in the cytoplasm was detected in RGCL and INL of various transgenic mice [11], [73], [74]. In single transgenic Tg2576 mice, over expressed APP was detected in the RGCL and INL of 14-month-old mice [73], [75]. In double transgenic mice strain APP_{swe}/PS1_{M146L}, over-expression of APP was age-dependent. In 27 months old mice, immunoreactivity of APP was detected not only in the different layers of retina such as NFL, RGCL, inner plexiform layer (IPL), INL, outer plexiform layer (OPL), outer segment (OS) and retinal pigment epithelium (RPE) but also in the retinal vasculature [11]. By using different double transgenic strain- APP_{swe}/PS1 _{Δ E9}, APP immunoreactivity was exhibited in the RGCL only at an intermediate age of 10.5 months. In earlier time point (9 month-old animals), moderate immunoreactivity of APP was detected only in the IPL and OPL not in the RGCL [11], [73], [76], [77].

3.3. Deposition of $A\beta$ in the retina and retinal vasculature

The deposition of $A\beta$, derived from abnormal processing of APP was found in the retinas of AD transgenic mice. In single transgenic Tg2576 mice, $A\beta$ was found to deposit from RGCL to INL or even at ONL. $A\beta$ deposits and plaque like formation were detected by four different monoclonal antibodies such as BAM01, 6E10, $A\beta$ -40 and $A\beta$ -42 as well as Congo red staining [73], [76]. Retinal $A\beta$ deposit has also been found in double transgenic mouse models expressing APP/PS1.

Mutant genes	Type/ Age	Neuronal cell loss [^]	APP over- expression	$A\beta$ deposits	$A\beta$ -deposited vasculature	P-tau deposits	Ref.
APP _{SWE} (HuAPP695, K670N, M671L)	Single/ 14- months	Yes	+++ (GCL, INL)	+++ (GCL, IPL, INL, OPL, ONL, RV) + (OS)	Yes	\pm (GCL, IPL, INL, OPL, ONL)	[73]
APP _{SWE} (HuAPP695, K595N, M596L)	Single/ 2-to18-months	n/a	+++ (GCL, INL)	\pm (GCL, RV)	Yes	n/a	[75]
APP _{SWE} PS1 Δ E9	Double/ 6-to 12-months	n/a	++ (IPL, OPL)	\pm (GCL, INL, RV)	Yes	n/a	[75]
APP _{SWE} PS1 Δ E9	Double/ 10.5-months	Yes	+++ (GCL)	\pm (NFL, CV)	Yes	n/a	[11]
APP _{SWE} PS1 Δ E9	Double/ 12-to 19-months	No	n/a	*(IPL, OPL)	n/a	n/a	[77]
APP _{SWE} PS1 _{M146L}	Double/ 7.8 months	Yes	+ (GCL, INL)		Yes	n/a	[11]
APP _{SWE} PS1 _{M146L}	Double/ 27-months	Yes	+++ (NFL, GCL, IPL, INL, OPL, + OS, RPE, RV)	+++ (NFL, GCL) (RV, CV)	Yes	n/a	[11]
TauP301S	Single/ 1- to 6-months	No	n/a	n/a	n/a	\pm (IPL), with paired helical filament formation	[78]
PS1 _{M146V} , APP _{SWE} and TauP301L	Triple/ 10-to 22- months	Yes	n/a	*Yes (layers not specified)	n/a	n/a	[79]

n/a: not applicable; swe: Swedish mutation; P-tau: hyperphosphorylated tau; [^] neuronal cells in the inner retinal regions, including INL and GCL; * plaques formation; NFL: nerve fiber layer; GCL: ganglion cell layer; IPL: inner plexiform layer; INL: inner nuclear layer; OPL: outer plexiform layer; ONL: outer nuclear layer; OS: outer segment; RPE: retinal pigment epithelium; RV: retinal vasculature; CV: choroidal vasculature; +++ strong level; ++ moderate level; + weak level; +/- present.

Table 1. Retinal changes in documented AD transgenic mouse models

In double transgenic mice strain APP_{swe}/PS1_{M146L}, A β was found to deposit predominantly in NFL and RGCL in aged mice of 27 months but not at young mice of 7.8 months. In another double transgenic strain APP_{swe}/PS1 Δ E9, similar A β deposition was detected in intermediate age of 10.5 months[11]. In another subsequent study using transgenic mice APP_{swe}/PS1 Δ E9, A β plaques were found by thioflavin-S staining in plexiform layers; the size and the number of plaques significantly increased with age from 12 months[77]. The transparent nature of the eyes allows direct tracking and visualization of the A β signal has also been detected in the retinal and choroidal vasculature. In single transgenic Tg2576 mice, A β was detected around microvessels in RGCL[73], [76]. Both retinal and choroidal vascular A β deposits were reported in aged (27 months) APP_{swe}/PS1_{M146L} transgenic mice and intermediate-aged (10.5 months) APP_{swe}/PS1 Δ E9 mice [11].

3.4. Deposition of hyperphosphorylated tau in the retina

Hyperphosphorylation of tau protein and subsequent deposition as neurofilibrillary tangles is associated with AD. Tau inclusions have been observed in the brains as well as in the retinas of Tg2576 and triple transgenic mice [79]. In single transgenic Tg2576 mice, hyperphosphorylated tau was detected by antibody AT8 in various retinal layers from RGCL through to the ONL. The hyperphosphorylated tau was found to be associated with A β depositions [73]. Another single transgenic expresses human P301S tau transgene, hyperphosphorylated tau was found to deposit in the RNFL and aggregated into filamentous inclusions in RGCs starting from 2-month-old mice [78]. Hyperphosphorylation and aggregation of tau were associated *in vivo* with reduced axonal transport, both anterograde and retrograde, in the optic nerve of this transgenic mice line [80].

3.5. Glial reaction in AD retina

Glial reactions, activated microglia and astrocytes, in the retina were detected in different kinds of AD transgenic mice at various ages. In Tg2576 transgenic mice, significant infiltration of microglial cells detected by iba-1 and the increased astrocytes activation detected by GFAP in the inner retina were detected as early as 4-month-old mice [73]. In double transgenic APP_{swe}/PS1_{M146L} mice, microglia was increased in an age-dependent manner, which was in parallel with A β deposits and TUNEL positive RGC in the GCL. The average percentage of cells in the GCL surrounded by microglial cells increased significantly from 10% in 7.8-month-old to 50% in 27-month-old APP_{swe}/PS1_{M146L} transgenic mice [11]. In another double transgenic APP_{swe}/PS1 Δ E9 mice, qualitative evaluation revealed greater immunoreactivity of microglia in 12 to 19 months old transgenic mice when compared to age-matched non-transgenic control[77].

4. β -Amyloid peptide and glaucoma

4.1. A β in animal models mimic glaucoma

In a rat model mimicking chronic ocular hypertension (COH) [81], A β has been reported to be implicated in the development of RGC apoptosis in glaucoma. Increased intracellular A β in

RGC detected by using $A\beta$ antibody was co-localized with apoptotic RGC cells. Targeting $A\beta$ pathway in this experimental model, three different approaches were applied including: (i) β -secretase inhibitor to reduce formation of $A\beta$; (ii) an anti- $A\beta$ antibody to clear $A\beta$ deposition; and (iii) Congo red to inhibit aggregation of $A\beta$ and neurotoxic effects of $A\beta$. Manipulating production of $A\beta$ pathway, apoptosis of RGC was successfully reduced by suppressing further $A\beta$ aggregation and inhibiting the enzymatic activity of amyloidogenesis. The combined treatment (triple therapy) was more effective than either single- or dual-agent therapy in protecting RGC survival under COH. Increased expression of $A\beta$ in the RGCL and optic nerve was related to abnormal APP-splicing in the presence of elevated IOP in DBA/2J glaucomatous mouse retinas [82] and mouse experimental COH model [83]. Increase of $A\beta$ in the retinal in COH has been found to be associated with activation of caspase-8 and caspase-3, and caspase-3-mediated APP cleavage product (DeltaC-APP) in the RGCs under COH [65]. Application of exogenous $A\beta$ peptide into the vitreous also induced significant RGC apoptosis in rat retina [81].

4.2. $A\beta$ -mediated mitochondrial dysfunction and glaucoma

There are some suggestions that $A\beta$ peptides modulate Ca^{2+} level in mitochondria that may alter the mitochondrial morphology and physiology [84]. For examples, elevated cytosolic Ca^{2+} levels may enhance fragmentation of mitochondria. This can lead to the perturbation of fission and fusion balance, which may eventually cause mitochondrial dysfunction [85]. Dysregulation of Ca^{2+} homeostasis may also disrupt downstream pathways of Ca^{2+} -dependent regulators monitoring mitochondrial dynamics [84], [86]. Consequently, synaptic dysfunction may occur due to the failure of meeting the energy demand in neurons, particularly in axonal and dendritic terminals [86]-[88].

Our eyes are energy demanding organs in which high density of mitochondria exist at the optic nerve heads [89]. If one applies $A\beta$ to the eyes, it may trigger mitochondrial dysfunctions resulting in retinal degeneration. Intriguingly, in a glaucomatous model where cultured RGCs were subjected to elevated hydrostatic pressure, fission of mitochondria was found to be enhanced, together with morphological changes and bioenergetics dysfunction [90]. A clinical study showed that mean mitochondrial respiratory activity was decreased by 21% in patients with primary open-angle glaucoma compared with age-matched control subjects ($p < 0.001$) [91]. In rabbit model of COH, daily topical application of 5 μ M mitochondria targeted cationic plastoquinone derivative SkQ1 (10-(6'-plastoquinonyl) decyltriphenylphosphonium) showed reduction in glaucomatous changes [92]. This hypothesis may be extended to one of the causes in $A\beta$ -induced RGC apoptosis in glaucoma.

5. TAU and glaucoma

5.1. Tau in the retina of glaucoma patient

In aged retina (49-87 year-old human), there is a positive correlation between age and number of tau-positive RGCs. Diffuse immunoreactivity of tau was found in the INL, while aggregated

tau was found within the cytoplasm of photoreceptor cells in patients older than 63-years-old [93]. Total tau is present in the INL and IPL but much reduced in glaucomatous retina. On the other hand, phosphorylated Tau (pTau) recognized by monoclonal antibody-AT8 is detected in glaucomatous retina at the outer border of the INL and occasionally in the IPL. It has also been found that pTau was localized in horizontal cells labeled by cell marker-parvalbumin [94]. The distribution of tau in the normal aged (Fig. 2A) and glaucomatous retina (Fig. 2B) is summarized in Figure 2. The decrease of total Tau and accumulation of pTau in the glaucomatous retina support the hypothesis showing that glaucoma shares pathways with AD. This is consistent with previous reports showing an increased incidence of primary open-angle glaucoma among AD patients. Recent evidence also indicates that altered cerebrospinal fluid (CSF) circulatory dynamics can reduce the clearance of both A β and tau. Altered CSF circulatory dynamics can reduce clearance of neurotoxin along the optic nerve in the subarachnoid space; leading to deposition of tau and other toxic molecules which ultimately result in glaucoma progression[94].

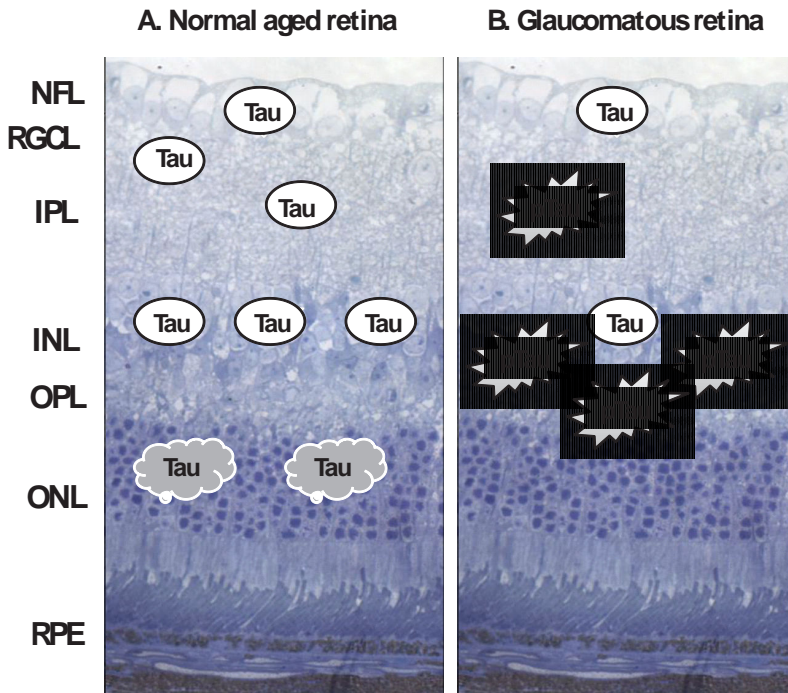


Figure 2. Diagram summarizing the literature reporting on the distribution of tau in the retina of normal people (A) and glaucomatous patient (B). The background is a cross semi-thin section showing the layered structure of the retina. *Ovals labelled 'Tau'* represent expression of total tau. *Cloudy labelled 'Tau'* represent tau aggregates. *Sparckle labelled 'pTau'* represent expression of abnormal phosphorylated tau. NFL: nerve fiber layer, RGCL: retinal ganglion cell layer, IPL: inner plexiform layer, INL: inner nuclear layer, OPL: outer plexiform layer, ONL: outer nuclear layer, RPE: retinal pigment epithelium.

5.2. Tau in animal models mimic glaucoma

In human glaucoma (chronic ocular hypertension), decreased total Tau and increased phosphorylated tau (pTau) are reported when compared to the age control group [94]. In animal models mimicking acute ocular hypertension, the loss of tau is evident even at earlier stages when the outer layer of the retina is mostly intact [95]. Acute ocular hypertension was induced for 1 hour by elevation of IOP to 120 mm Hg. The loss of tau proteins in the retina has been shown to occur from as early as 4 hours to over 7 days after induction of acute ocular hypertension. Proteolysis of tau has been suggested contributing to the pathogenesis of neuronal cell death, correlating with an increase in calcium, followed by activation of calpain. Calpain-induced conversion of p35 to p25 and activation of cdk5 are also involved in the RGC loss. There is no direct evidence about increase of pTau. However, it is indirectly evident by the up-regulation of the relevant kinase, cdk5, and the regulatory protein, p35/p25. One justification for the failure to detect pTau is that tau protein is cleaved by calpain before detection is possible [95]. Another justification is that this acute elevation of ocular hypertension actually blocks the retinal blood supply at 120 mmHg IOP. This is an ischemia/reperfusion model which may cause neuronal cell hypoxia. Under hypoxic conditions, similar changes have also been reported. In rat retinas treated with hypoxic conditions, it has been found that immunoreactivity of tau is almost completely lost in retinas within 5 hours; however, the proteolytic products of tau remain detectable [96]. The changes of Tau proteins in the chronic ocular hypertension model which mimic glaucoma over a relative long and slow degenerative period deserves further evaluation.

6. Future therapy

Increasing lines of evidence have demonstrated common pathological findings in both AD and glaucomatous retinal degeneration. Neuronal losses, inflammatory responses, accumulation of A β and pTau deposition are important pathological factors found in the brain and the retina [94], [97]. However, the correlation among A β deposits, pTau formation and the retinal degeneration is limited to histological level. The pathological mechanisms have not been comprehensively investigated. Questions like what are the mechanisms triggered by A β and tau to cause retinal degeneration are still waiting for answers.

As part of the CNS, the similarity between the brain and the retina allows the exchange of knowledge in terms of pathological mechanisms and therapeutic intervention. Mitochondrial dysfunction discussed above is one of the pathophysiological changes in both AD and retinal degeneration [3], [98]. The discovery of significant involvement of double-stranded RNA-dependent protein kinase (PKR) in the apoptosis of neurons in postmortem AD brain and in experimental studies is another good example [99]-[101]. Years after our report of the PKR in AD, PKR has also been proved to play important roles in neuronal apoptosis of RGCs in endoplasmic reticulum (ER) stress-induced retinal neuronal loss [102]. Neuroprotective agents found from *in vitro* AD research can also be applied to eye research. Our Studies on wolfberry, *Lycium barbarum*, an anti-aging herb, can be a good example. In primary neuronal culture,

wolfberry can alleviate the A β induced degenerative process by promoting survival signals, suppressing ER stress, reducing glutamate excitotoxicity [103]-[107]. In rat glaucoma model, wolfberry shows its beneficial effects on the retina based on suppressing neurodestructive factors, modulating the inflammatory responses [108], and up regulating the expression of protective chaperone – crystallin [109]. The neuroprotective effects of wolfberry shared between AD and glaucoma further strengthen our hypothesis that knowledge obtained from the brain can be transferred to the study of the retina.

On the other hand, retina can be a promising platform to investigate the efficacy of any potential drugs on different neuronal cells. In the study of rat chronic glaucomatous model, immunotherapy with a potential agent such as β -secretase inhibitor, Congo Red or A β antibody successfully reduced A β -induced RGC apoptosis by suppressing further A β aggregation and inhibiting the enzymatic activity of amyloidogenesis [81]. In APP^{swe}/PS1 Δ E9 mice, following MOG45D-loaded dendritic cells immunization, A β -plaque burden in the retinas was reduced as effective as that in the brain [52].

In a recent study using APP^{swe}/PS1 Δ E9 mice with five days of systemic administration of curcumin, the results showed that there is a age-dependent correlation between plaque deposition in the retina and the brain, and increased accumulations over the course of disease progression [52]. This is the very first prove that A β plaques in the retina precede the existence of brain plaques. The A β plaques can be detected as early as 2.5 months of age in the retina but A β plaques in the brain exists at the age of 5 months, which is about 2 months later [110]. Curcumin is a natural and safe fluorochrome that binds and labels A β plaques [111], [112]. In a six-month randomized, placebo-controlled, double-blind, pilot clinical trial in AD patients, there was no significant side effects even when patients took curcumin at the dose of 4 g/day [113].

Early sign of AD symptoms in the brain can hardly be detected. With the use of curcumin, retinal degeneration may be the most important site to be studied in early AD pathology. Future development of high-resolution optical imaging for early AD diagnosis, prognosis assessment and response to therapies can be achieved non-invasively through direct imaging of the retina. Progression of therapy is possible to be visualized qualitatively in a sense that one can monitor the changes of a particular neuronal cell [114], [115]. Quantitative examination of the disease stages have been performed by assessing the ratio of apoptosis to necrosis using fluorescence counts of respective dyes [74]. Even more, a high spatial resolution of images with a high signal-to-noise ratio ranging from 3:1 to 10:1 can be achieved with the imaging of the retina [114], [115]. The merits of non-invasive retinal imaging can provide investigators a solid support for assessing pathological status as well as developing and refining therapeutic strategies. Considering the potential of direct optical imaging of the retina, especially the A β plaques deposition in the retina labeled by curcumin, retinal degeneration in early AD is the window of monitoring disease progression as well as effectiveness of treatment.

With all the findings we pointed out in this review, we can formulate our working hypothesis for researchers: increase in the level of A β or hyperphosphorylated tau protein may be the co-pathological factors of glaucoma leading to progressive neurodegeneration in the retina.

Acknowledgements

Research in this laboratory is partly supported by HKU Alzheimer's Disease Research Network under Strategic Research Theme on Healthy Aging. The authors declare that we do not have competing interest in this review.

Author details

Kin Chiu¹, Kwok-Fai So^{1,2,3} and Raymond Chuen-Chung Chang^{1,2,3}

1 Laboratory of Neurodegenerative Diseases, Department of Anatomy, LKS Faculty of Medicine, China

2 Research Centre of Heart, Brain, Hormone and Healthy Aging, LKS Faculty of Medicine, China

3 State Key Laboratory of Brain and Cognitive Sciences, The University of Hong Kong, Pokfulam, Hong Kong SAR, China

References

- [1] Brookmeyer R, Johnson E, Ziegler-Graham K, HM A. Forecasting the global burden of Alzheimer's disease. *Alzheimers Dement* 2007;3:186-191.
- [2] Mattson MP. Pathways towards and away from Alzheimer's disease. *Nature* 2004;430:631-639.
- [3] Valenti DA. Alzheimer's disease: visual system review. *Optometry* 2010;81:12-21.
- [4] Berisha F, Fekete GT, Trempe CL, McMeel JW, Schepens CL. Retinal abnormalities in early Alzheimer's disease. *Invest Ophthalmol Vis Sci* 2007;48:2285-2289.
- [5] Rizzo M, Anderson SW, Dawson J, Nawrot M. Vision and cognition in Alzheimer's disease. *Neuropsychologia* 2000;38:1157-1169.
- [6] Quigley HA, Broman AT. The number of people with glaucoma worldwide in 2010 and 2020. *British J Ophthalmol* 2006;90:262-267.
- [7] Tamura H, Kawakami H, Kanamoto T, et al. High frequency of open-angle glaucoma in Japanese patients with Alzheimer's disease. *J Neurol Sci* 2006;246:79-83.
- [8] Nucci C, Martucci A, Martorana A, Sancesario GM, Cerulli L. Glaucoma progression associated with altered cerebral spinal fluid levels of amyloid beta and tau proteins. *Clin Exp Ophthalmol* 2011;39:279-281.

- [9] Yoneda S, Hara H, Hirata A, Fukushima M, Inomata Y, Tanihara H. Vitreous fluid levels of beta-amyloid((1-42)) and tau in patients with retinal diseases. *Jpn J Ophthalmol* 2005;49:106-108.
- [10] Muller UC, Zheng H. Physiological Functions of APP Family Proteins. *Cold Spring Harb Perspect Med* 2012;2:a006288.
- [11] Ning A, Cui J, To E, Ashe KH, Matsubara J. Amyloid-beta deposits lead to retinal degeneration in a mouse model of Alzheimer disease. *Invest Ophthalmol Vis Sci* 2008;49:5136-5143.
- [12] Goate A, Chartier-Harlin MC, Mullan M, et al. Segregation of a missense mutation in the amyloid precursor protein gene with familial Alzheimer's disease. *Nature* 1991;349:704-706.
- [13] Chow VW, Mattson MP, Wong PC, Gleichmann M. An overview of APP processing enzymes and products. *Neuromolecular Med* 2010;12:1-12.
- [14] Hoe H-S, Lee KJ, Carney RSE, et al. Interaction of Reelin with Amyloid Precursor Protein Promotes Neurite Outgrowth. *J Neurosci* 2009;29:7459-7473.
- [15] Priller C, Bauer T, Mitteregger G, Krebs B, Kretschmar HA, Herms J. Synapse formation and function is modulated by the amyloid precursor protein. *J Neurosci* 2006;26:7212-7221.
- [16] Moya KL, Benowitz LI, Schneider GE, Allinquant B. The amyloid precursor protein is developmentally regulated and correlated with synaptogenesis. *Dev Biol* 1994;161:597-603.
- [17] Herard AS, Besret L, Dubois A, et al. siRNA targeted against amyloid precursor protein impairs synaptic activity in vivo. *Neurobiol Aging* 2006;27:1740-1750.
- [18] White AR, Reyes R, Mercer JF, et al. Copper levels are increased in the cerebral cortex and liver of APP and APLP2 knockout mice. *Brain Res* 1999;842:439-444.
- [19] Duce JA, Tsatsanis A, Cater MA, et al. Iron-export ferroxidase activity of beta-amyloid precursor protein is inhibited by zinc in Alzheimer's disease. *Cell* 2010;142:857-867.
- [20] Wang Z, Wang B, Yang L, et al. Presynaptic and postsynaptic interaction of the amyloid precursor protein promotes peripheral and central synaptogenesis. *J Neurosci* 2009;29:10788-10801.
- [21] Yang L, Wang B, Long C, Wu G, Zheng H. Increased asynchronous release and aberrant calcium channel activation in amyloid precursor protein deficient neuromuscular synapses. *Neurosci* 2007;149:768-778.
- [22] Dinet V, An N, Ciccotosto GD, et al. APP involvement in retinogenesis of mice. *Acta Neuropathol* 2011;121:351-363.

- [23] Ho T, Vessey KA, Cappai R, et al. Amyloid Precursor Protein Is Required for Normal Function of the Rod and Cone Pathways in the Mouse Retina. *PLoS One* 2012;7.
- [24] Lee VM-Y, Goedert M, Trojanowski JQ. Neurodegenerative tauopathies. *Annual Review of Neuroscience* 2001;24:1121-1159.
- [25] Spires-Jones TL, Stoothoff WH, de Calignon A, Jones PB, Hyman BT. Tau pathophysiology in neurodegeneration: a tangled issue. *Trends Neurosci* 2009;32:150-159.
- [26] Dawson HN, Ferreira A, Eyster MV, Ghoshal N, Binder LI, Vitek MP. Inhibition of neuronal maturation in primary hippocampal neurons from tau deficient mice. *J Cell Sci* 2001;114:1179-1187.
- [27] Ittner LM, Ke YD, Delerue F, et al. Dendritic function of tau mediates amyloid-beta toxicity in Alzheimer's disease mouse models. *Cell* 2010;142:387-397.
- [28] Hwang SC, Jhon DY, Bae YS, Kim JH, Rhee SG. Activation of phospholipase C-gamma by the concerted action of tau proteins and arachidonic acid. *J Biol Chem* 1996;271:18342-18349.
- [29] Perez M, Santa-Maria I, Gomez de Barreda E, et al. Tau—an inhibitor of deacetylase HDAC6 function. *J Neurochem* 2009;109:1756-1766.
- [30] Miao Y, Chen J, Zhang Q, Sun A. Deletion of tau attenuates heat shock-induced injury in cultured cortical neurons. *J Neurosci Res* 2010;88:102-110.
- [31] Shahani N, Brandt R. Functions and malfunctions of the tau proteins. *Cell Mol Life Sci* 2002;59:1668-1680.
- [32] Hong M, Zhukareva V, Vogelsberg-Ragaglia V, et al. Mutation-specific functional impairments in distinct tau isoforms of hereditary FTDP-17. *Science* 1998;282:1914-1917.
- [33] Lieven CJ, Millet LE, Hoegger MJ, Levin LA. Induction of axon and dendrite formation during early RGC-5 cell differentiation. *Exp Eye Res* 2007;85:678-683.
- [34] Nakayama T, Goshima Y, Misu Y, Kato T. Role of cdk5 and tau phosphorylation in heterotrimeric G protein-mediated retinal growth cone collapse. *J Neurobiol* 1999;41:326-339.
- [35] Liu B, Rasool S, Yang Z, et al. Amyloid-peptide vaccinations reduce β -amyloid plaques but exacerbate vascular deposition and inflammation in the retina of Alzheimer's transgenic mice. *The American journal of pathology* 2009;175:2099-2110.
- [36] Nikolic M, Dudek H, Kwon YT, Ramos YF, Tsai LH. The cdk5/p35 kinase is essential for neurite outgrowth during neuronal differentiation. *Genes Dev* 1996;10:816-825.
- [37] Arimura N, Inagaki N, Chihara K, et al. Phosphorylation of collapsin response mediator protein-2 by Rho-kinase. Evidence for two separate signaling pathways for growth cone collapse. *J Bio Chem* 2000;275:23973-23980.

- [38] Cheng Q, Sasaki Y, Shoji M, et al. Cdk5/p35 and Rho-kinase mediate ephrin-A5-induced signaling in retinal ganglion cells. *Mol Cell Neurosci* 2003;24:632-645.
- [39] Liu N, Cooper NG. The Ca²⁺/calmodulin-dependent protein kinase II-associated protein complex isolated from chicken retina. *J Mol Neurosci* 1996;7:1-12.
- [40] Stamer K, Vogel R, Thies E, Mandelkow E, Mandelkow EM. Tau blocks traffic of organelles, neurofilaments, and APP vesicles in neurons and enhances oxidative stress. *J Cell Bio* 2002;156:1051-1063.
- [41] Magnani E, Fan J, Gasparini L, et al. Interaction of tau protein with the dynactin complex. *Embo J* 2007;26:4546-4554.
- [42] Cogan DG. Alzheimer syndromes. *Am J Ophthalmol* 1987;104:183-184.
- [43] Katz B, Rimmer S, Iragui V, Katzman R. Abnormal pattern electroretinogram in Alzheimer's disease - evidence for retinal ganglion-cell degeneration. *Ann Neurol* 1989;26:221-225.
- [44] Katz B, Rimmer S, Iragui V, Katzman R. Abnormal pattern electroretinogram in Alzheimer's disease: evidence for retinal ganglion cell degeneration? *Ann Neurol* 1989;26:221-225.
- [45] Jackson GR, Owsley C. Visual dysfunction, neurodegenerative diseases, and aging. *Neurol Clin* 2003;21:709-728.
- [46] Lee AG, Martin CO. Neuro-ophthalmic findings in the visual variant of Alzheimer's disease. *Ophthalmol* 2004;111:376-380.
- [47] Cronin-Golomb A, Corkin S, Rizzo JF, Cohen J, Growdon JH, Banks KS. Visual dysfunction in Alzheimer's disease: relation to normal aging. *Ann Neurol* 1991;29:41-52.
- [48] Mendez MF, Cherrier MM, Meadows RS. Depth perception in Alzheimer's disease. *Percept Mot Skills* 1996;83:987-995.
- [49] Cronin-Golomb A. Vision in Alzheimer's disease. *Gerontologist* 1995;35:370-376.
- [50] Gilmore GC, Whitehouse PJ. Contrast sensitivity in Alzheimer's disease: a 1-year longitudinal analysis. *Optom Vis Sci* 1995;72:83-91.
- [51] Leuba G, Saini K. Pathology of subcortical visual centers in relation to cortical degeneration in Alzheimer's disease. *Neuropath Applied Neurobiol* 1995;21:410-422.
- [52] Koronyo-Hamaoui M, Koronyo Y, Ljubimov AV, et al. Identification of amyloid plaques in retinas from Alzheimer's patients and noninvasive in vivo optical imaging of retinal plaques in a mouse model. *Neuroimage* 2011;54S1:S204-S217.
- [53] Paquet C, Boissonnot M, Roger F, Dighiero P, Gil R, Hugon J. Abnormal retinal thickness in patients with mild cognitive impairment and Alzheimer's disease. *Neurosci Lett* 2007;420:97-99.

- [54] Berisha F, Fekete GT, Trempe CL, McMeel JW, Schepens CL. Retinal abnormalities in early Alzheimer's disease. *Investigative ophthalmology & visual science* 2007;48:2285-2289.
- [55] Iseri PK, Altinas O, Tokay T, Yuksel N. Relationship between cognitive impairment and retinal morphological and visual functional abnormalities in Alzheimer disease. *J Neuroophthalmol* 2006;26:18-24.
- [56] Parisi V. Correlation between morphological and functional retinal impairment in patients affected by ocular hypertension, glaucoma, demyelinating optic neuritis and Alzheimer's disease. *Semin Ophthalmol* 2003;18:50-57.
- [57] Valenti DA. Neuroimaging of retinal nerve fiber layer in AD using optical coherence tomography. *Neurology* 2007;69:1060.
- [58] Danesh-Meyer HV, Birch H, Ku JY, Carroll S, Gamble G. Reduction of optic nerve fibers in patients with Alzheimer disease identified by laser imaging. *Neurol* 2006;67:1852-1854.
- [59] Hinton DR, Sadun AA, Blanks JC, Miller CA. Optic-nerve degeneration in Alzheimer's disease. *N Engl J Med* 1986;315:485-487.
- [60] Sadun AA, Bassi CJ. Optic nerve damage in Alzheimer's disease. *Ophthalmology* 1990;97:9-17.
- [61] Foster PJ, Buhrmann R, Quigley HA, Johnson GJ. The definition and classification of glaucoma in prevalence surveys. *Bri J Ophthalmol* 2002;86:238-242.
- [62] Quigley HA. Glaucoma. *Lancet* 2011;377:1367-1377.
- [63] Parisi V, Restuccia R, Fattapposta F, Mina C, Bucci MG, Pierelli F. Morphological and functional retinal impairment in Alzheimer's disease patients. *Clin Neurophysiol* 2001;112:1860-1867.
- [64] Neshet R, Trick GL. The pattern electroretinogram in retinal and optic-nerve disease - a quantitative comparison of the pattern of visual dysfunction. *Doc Ophthalmol* 1991;77:225-235.
- [65] McKinnon SJ, Lehman DM, Kerrigan-Baumrind LA, et al. Caspase activation and amyloid precursor protein cleavage in rat ocular hypertension. *Invest Ophthalmol Vis Sci* 2002;43:1077-1087.
- [66] Yin H, Chen L, Chen X, Liu X. Soluble amyloid beta oligomers may contribute to apoptosis of retinal ganglion cells in glaucoma. *Med Hypotheses* 2008;71:77-80.
- [67] Bayer AU, Ferrari F, Erb C. High occurrence rate of glaucoma among patients with Alzheimer's disease. *Eur Neurol* 2002;47:165-168.
- [68] Price DL, Tanzi RE, Borchelt DR, Sisodia SS. Alzheimer's disease: genetic studies and transgenic models. *Annu Rev Genet* 1998;32:461-493.

- [69] Chiu K, Chan TF, Wu A, Leung IYP, So KF, Chang RCC. Neurodegeneration of the retina in mouse models of Alzheimer's disease: what can we learn from the retina? *Age* 2012;34:633-649.
- [70] Arendash GW, Lewis J, Leighty RE, et al. Multi-metric behavioral comparison of APPsw and P301L models for Alzheimer's disease: linkage of poorer cognitive performance to tau pathology in forebrain. *Brain Res* 2004;1012:29-41.
- [71] Wostyn P, Audenaert K, De Deyn PP. Alzheimer's disease-related changes in diseases characterized by elevation of intracranial or intraocular pressure. *Clin Neurol Neurosurg* 2008;110:101-109.
- [72] Muyliaert D, Kremer A, Jaworski T, et al. Glycogen synthase kinase-3beta, or a link between amyloid and tau pathology? *Genes Brain Behav* 2008;7 Suppl 1:57-66.
- [73] Liu B, Rasool S, Yang Z, et al. Amyloid-peptide vaccinations reduce {beta}-amyloid plaques but exacerbate vascular deposition and inflammation in the retina of Alzheimer's transgenic mice. *Am J Pathol* 2009;175:2099-2110.
- [74] Cordeiro MF, Guo L, Coxon KM, et al. Imaging multiple phases of neurodegeneration: a novel approach to assessing cell death *n vivo*. *Cell Death and Dis* 2010;1:e3.
- [75] Dutescu RM, Li QX, Crowston J, Masters CL, Baird PN, Culvenor JG. Amyloid precursor protein processing and retinal pathology in mouse models of Alzheimer's disease. *Graefes Archive for Clinical and Experimental Ophthalmology* 2009;247:1213-1221.
- [76] Dutescu RM, Li QX, Crowston J, Masters CL, Baird PN, Culvenor JG. Amyloid precursor protein processing and retinal pathology in mouse models of Alzheimer's disease. *Graefes Arch Clin Exp Ophthalmol* 2009;247:1213-1221.
- [77] Perez SE, Lumayag S, Kovacs B, Mufson EJ, Xu S. Beta-amyloid deposition and functional impairment in the retina of the APPsw/PS1DeltaE9 transgenic mouse model of Alzheimer's disease. *Invest Ophthalmol Vis Sci* 2009;50:793-800.
- [78] Gasparini L, Crowther RA, Martin KR, et al. Tau inclusions in retinal ganglion cells of human P301S tau transgenic mice: effects on axonal viability. *Neurobio aging* 2011;32:419-433.
- [79] Oddo S, Caccamo A, Shepherd JD, et al. Triple-transgenic model of Alzheimer's disease with plaques and tangles: intracellular Abeta and synaptic dysfunction. *Neuron* 2003;39:409-421.
- [80] Bull ND, Guidi A, Goedert M, Martin KR, Spillantini MG. Reduced Axonal Transport and Increased Excitotoxic Retinal Ganglion Cell Degeneration in Mice Transgenic for Human Mutant P301S Tau. *PLoS One* 2012;7.
- [81] Guo L, Salt TE, Luong V, et al. Targeting amyloid-beta in glaucoma treatment. *Proc Natl Acad Sci U S A* 2007;104:13444-13449.

- [82] Goldblum D, Kipfer-Kauer A, Sarra GM, Wolf S, Frueh BE. Distribution of amyloid precursor protein and amyloid-beta immunoreactivity in DBA/2J glaucomatous mouse retinas. *Invest Ophthalmol Vis Sci* 2007;48:5085-5090.
- [83] Kipfer-Kauer A, McKinnon SJ, Frueh BE, Goldblum D. Distribution of Amyloid Precursor Protein and Amyloid-beta in Ocular Hypertensive C57BL/6 Mouse Eyes. *Cur Eye Res* 2010;35:828-834.
- [84] Hung CH, Ho YS, Chang RCC. Modulation of mitochondrial calcium as a pharmacological target for Alzheimer's disease. *Ageing Res Rev* 2010;9:447-456.
- [85] Saotome M, Safiulina D, Szabadkai G, et al. Bidirectional Ca^{2+} -dependent control of mitochondrial dynamics by the Miro GTPase. *Proc Natl Acad Sci U S A* 2008;105:20728-20733.
- [86] Liu X, Hajnoczky G. Ca^{2+} -dependent regulation of mitochondrial dynamics by the Miro-Milton complex. *Int J Biochem Cell Biol* 2009;41:1972-1976.
- [87] Allen B, Ingram E, Takao M, et al. Abundant tau filaments and nonapoptotic neurodegeneration in transgenic mice expressing human P301S tau protein. *J Neurosci* 2002;22:9340-9351.
- [88] Wang X, Su B, Lee HG, et al. Impaired balance of mitochondrial fission and fusion in Alzheimer's disease. *J Neurosci* 2009;29:9090-9103.
- [89] Carelli V, Ross-Cisneros FN, Sadun AA. Mitochondrial dysfunction as a cause of optic neuropathies. *Prog Retin Eye Res* 2004;23:53-89.
- [90] Ju WK, Liu Q, Kim KY, et al. Elevated hydrostatic pressure triggers mitochondrial fission and decreases cellular ATP in differentiated RGC-5 cells. *Invest Ophthalmol Vis Sci* 2007;48:2145-2151.
- [91] Abu-Amero KK, Morales J, Bosley TM. Mitochondrial Abnormalities in Patients with Primary Open-Angle Glaucoma. *Investigative Ophthalmology & Visual Science* 2006;47:2533-2541.
- [92] Neroev VV, Archipova MM, Bakeeva LE, et al. Mitochondria-targeted plastoquinone derivatives as tools to interrupt execution of the aging program. 4. Age-related eye disease. SkQ1 returns vision to blind animals. *Biochemistry (Mosc)* 2008.
- [93] Leger F, Fernagut PO, Canron MH, et al. Protein aggregation in the aging retina. *J Neuropath Exp Neurol* 2011;70:63-68.
- [94] Gupta N, Fong J, Ang LC, Yucel YH. Retinal tau pathology in human glaucomas. *Can J Ophthalmol* 2008;43:53-60.
- [95] Oka T, Tamada Y, Nakajima E, Shearer TR, Azuma M. Presence of calpain-induced proteolysis in retinal degeneration and dysfunction in a rat model of acute ocular hypertension. *J Neurosci Res* 2006;83:1342-1351.

- [96] Tamada Y, Nakajima E, Nakajima T, Shearer TR, Azuma M. Proteolysis of neuronal cytoskeletal proteins by calpain contributes to rat retinal cell death induced by hypoxia. *Brain Res* 2005;1050:148-155.
- [97] Guo L, Duggan J, Cordeiro MF. Alzheimer's disease and retinal neurodegeneration. *Curr Alzheimer Res* 2010;7:3-14.
- [98] Kong GY, Van Bergen NJ, Trounce IA, Crowston JG. Mitochondrial dysfunction and glaucoma. *J Glaucoma* 2009;18:93-100.
- [99] Chang RCC, Suen KC, Ma CH, Elyaman W, Ng HK, Hugon J. Involvement of double-stranded RNA-dependent protein kinase and phosphorylation of eukaryotic initiation factor-2 alpha in neuronal degeneration. *Journal of Neurochemistry* 2002a; 83:1215-1225.
- [100] Chang RCC, Wong AKY, Ng HK, Hugon J. Phosphorylation of eukaryotic initiation factor-2 alpha (eIF2 alpha) is associated with neuronal degeneration in Alzheimer's disease. *Neuroreport* 2002b;13:2429-2432.
- [101] Suen KC, Yu MS, So KF, Chang RCC, Hugon J. Upstream signaling pathways leading to the activation of double-stranded RNA-dependent serine/threonine protein kinase in {beta}-amyloid peptide neurotoxicity. *J Bio Chem* 2003;278:49819-49827.
- [102] Shimazawa M, Ito Y, Inokuchi Y, Hara H. Involvement of Double-Stranded RNA-Dependent Protein Kinase in ER Stress-Induced Retinal Neuron Damage. *Invest Ophthalmol Vis Sci* 2007;48:3729-3736.
- [103] Chan HC, Chang RCC, Koon-Ching Ip A, et al. Neuroprotective effects of *Lycium barbarum* Lynn on protecting retinal ganglion cells in an ocular hypertension model of glaucoma. *Exp Neurol* 2007;203:269-273.
- [104] Yu MS, Lai CS, Ho YS, et al. Characterization of the effects of anti-aging medicine *Fructus lycii* on beta-amyloid peptide neurotoxicity. *Int J Mol Med* 2007;20:261-268.
- [105] Ho YS, Yu MS, Yang XF, So KF, Yuen WH, Chang RCC. Neuroprotective Effects of Polysaccharides from Wolfberry, the Fruits of *Lycium barbarum*, Against Homocysteine-induced Toxicity in Rat Cortical Neurons. *J Alzheimers Dis* 2009.
- [106] Ho YS, Yu MS, Yik SY, So KF, Yuen WH, Chang RCC. Polysaccharides from wolfberry antagonizes glutamate excitotoxicity in rat cortical neurons. *Cell Mol Neurobiol* 2009;29:1233-1244.
- [107] Yu MS, Ho YS, So KF, Yuen WH, Chang RCC. Cytoprotective effects of *Lycium barbarum* against reducing stress on endoplasmic reticulum. *Int J Mol Med* 2006;17:1157-1161.
- [108] Chiu K, Chan HC, Yeung SC, et al. Erratum: Modulation of microglia by Wolfberry on the survival of retinal ganglion cells in a rat ocular hypertension model. *J Ocul Biol Dis Infor* 2009;2:127-136.

- [109] Chiu K, Zhou Y, Yeung SC, et al. Up-regulation of crystallins is involved in the neuroprotective effect of wolfberry on survival of retinal ganglion cells in rat ocular hypertension model. *J Cell Biochem* 2010;110:311-320.
- [110] Garcia-Alloza M, Robbins EM, Zhang-Nunes SX, et al. Characterization of amyloid deposition in the APPswe/PS1dE9 mouse model of Alzheimer disease. *Neurobiol Dis* 2006;24:516-524.
- [111] Garcia-Alloza M, Borrelli LA, Rozkalne A, Hyman BT, Bacskai BJ. Curcumin labels amyloid pathology in vivo, disrupts existing plaques, and partially restores distorted neurites in an Alzheimer mouse model. *J Neurochem* 2007;102:1095-1104.
- [112] Yang F, Lim GP, Begum AN, et al. Curcumin Inhibits Formation of Amyloid β Oligomers and Fibrils, Binds Plaques, and Reduces Amyloid in Vivo. *J Biol Chem* 2005;280:5892-5901.
- [113] Baum L, Lam CWK, Cheung SK-K, et al. Six-Month Randomized, Placebo-Controlled, Double-Blind, Pilot Clinical Trial of Curcumin in Patients With Alzheimer Disease. *J Clin Psych* 2008;28:110-113
- [114] Hintersteiner M, Enz A, Frey P, et al. In vivo detection of amyloid-beta deposits by near-infrared imaging using an oxazine-derivative probe. *Nat Biotechnol* 2005;23:577-583.
- [115] Nakada T, Matsuzawa H, Igarashi H, Fujii Y, Kwee IL. In vivo visualization of senile-plaque-like pathology in Alzheimer's disease patients by MR microscopy on a 7T system. *J Neuroimaging* 2008;18:125-129.

