

## Air Bubble Growth in Water

*To the Editor:*—I read with considerable interest the article by Benavides *et al.*<sup>1</sup> describing experiments of air bubble growth in water during exposure to 100% nitrous oxide, 100% xenon, or 50% xenon-50% oxygen. Although the experiments were nicely conducted, they explore a physics of gas flux in an unconstrained bubble permitted to grow spherically. Importantly, this geometry has limited biologic relevance for bubbles occluding vessels in the size range they have studied. The authors have referenced our previous work on xenon transport,<sup>2</sup> but they have mistakenly interpreted the findings presented therein to indicate the growth of bubbles as spheres. Rather, that study presents some simulations for bubbles that are initially spherical and just fill the vessel lumen. Such bubbles cannot grow radially because they are constrained by the vessel wall and therefore elongate during growth while maintaining a fixed curvature on the interface. This results in a much different force balance across the gas-liquid interface and, hence, a different pressure condition on the interior of the bubble from that which occurs in the case of a time-varying interfacial shape, which the authors have studied. We have described these differences in our previous theoretical and experimental studies of intravascular gas embolism.<sup>2-5</sup>

In addition, the initial internal gas content they have studied includes nitrogen, equilibrated with test solution A, but test solution B is nitrogen free. Hence, there are large gradients for nitrogen flux when the solutions are switched. We purposely avoided nitrogen as a component of either the bubble or perfusate in our predictions and considered only oxygen and xenon as the transportable species.<sup>2</sup> Whereas others have studied growth of similarly unconstrained air bubbles during cardiopulmonary bypass,<sup>6</sup> our work has not provided any data for direct comparisons such as the authors have made, based on the different gas constituents and the governing physics dictated by the shape constraint.

I find it fascinating, however, that they have couched their results in

terms of bubble diameter growth. When transferred to the volume domain, one readily sees that the spherical bubbles exposed to 100% xenon or 100% nitrous oxide had grown to more than twice their initial volume in 25 min (figs. 2 and 3) and continued growing when the solutions were switched (downward arrow). The time required for this is surprisingly similar to the volume doubling times we reported for many of the cases we explored, despite the differences in our model and these experiments.

The curve fitting by a double exponential suggests that there will be continuous exponential growth of bubble diameter. So although the physics and gas transport are different from what we studied, the indication of the studies are the same.

**David M. Eckmann, Ph.D., M.D.,** University of Pennsylvania, Philadelphia, Pennsylvania. eckmandm@uphs.upenn.edu

## References

1. Benavides RMD, Maze MFRC, Franks NPP: Expansion of gas bubbles by nitrous oxide and xenon. *ANESTHESIOLOGY* 2006; 104:299-302
2. Sta. Maria N, Eckmann DM: Model predictions of gas embolism growth and reabsorption during xenon anesthesia. *ANESTHESIOLOGY* 2003; 99:638-45
3. Branger AB, Eckmann DM: Accelerated arteriolar gas embolism reabsorption by an exogenous surfactant. *ANESTHESIOLOGY* 2002; 96:971-9
4. Branger AB, Lambertsen CJ, Eckmann DM: Cerebral gas embolism absorption during hyperbaric therapy: Theory. *J Appl Physiol* 2001; 90:593-600
5. Branger AB, Eckmann DM: Theoretical and experimental intravascular gas embolism absorption dynamics. *J Appl Physiol* 1999; 87:1287-95
6. Grocott HP, Sato Y, Homi HM, Smith BE: The influence of xenon, nitrous oxide and nitrogen on gas bubble expansion during cardiopulmonary bypass. *Eur J Anaesthesiol* 2005; 22:353-8

(Accepted for publication June 19, 2006.)

*In Reply:*—Our article<sup>1</sup> on the expansion of gas bubbles by xenon and nitrous oxide investigated how air bubbles of various dimensions in aqueous solution would expand when suddenly exposed to solutions containing certain gas mixtures (particularly mixtures containing xenon). The motivation behind this work was simple: Would air bubbles that were entrained while on cardiopulmonary bypass during cardiac surgery expand to a worrying extent if xenon were used during the procedure, hence potentially exacerbating damage caused by air emboli? Xenon has been proposed for use as a neuroprotectant,<sup>2</sup> and it might be beneficial in reducing the cognitive deficits that are known to occur during cardiopulmonary bypass.<sup>3</sup> However, if entrained gas bubbles expanded greatly, xenon may do more harm than good.

Indeed, Dr. Eckmann and his colleagues have suggested exactly that,<sup>4</sup> based on theoretical calculations that concluded that small gas bubbles would expand rapidly and indefinitely if they were trapped in fine blood vessels. (We fully understand that the model assumes that the bubbles are

constrained by the size of the capillaries.) For example, their calculations suggest that a 50-nl bubble of oxygen exposed to 70% xenon-30% oxygen would grow to 250 nl in approximately 20 min with an ever-increasing rate of growth. Because we thought that these predictions were implausible, and because there were a large number of variables that had to be estimated, we conducted our experiments, which were designed to measure bubble growth directly under a well-defined set of conditions. We studied the expansion of both air and oxygen bubbles, and the results were similar; our data show bubble expansions of the order of 10% in diameter and 30% in volume under conditions likely to be encountered during cardiopulmonary bypass. We concluded that this is unlikely to represent a significant clinical problem.

We disagree with Dr. Eckmann's claim that his calculations predict similar expansions to those we observed. Apart from the extent of the volume expansions that were predicted,<sup>4</sup> their most striking aspect was the ever-increasing rates of expansion that seemed to predict unlimited bubble growth. In contrast, we observed limited bubble growth with volumes tending toward finite equilibrium values. Even making allowances for the differences between the model and the gas compositions, we believe our experimental observations probably better reflects reality than the theoretical calculations that Dr. Eckmann has published. Furthermore, in our recently published feasibility and tolerability clinical study involving exposure of cardiac surgical patients to xenon while on cardiopulmonary bypass, there was no

Drs. Franks and Maze have a financial interest in an Imperial College spin-out company (Protexone Ltd., London, United Kingdom) that is interested in developing clinical applications for medical gases, particularly xenon, and both are paid consultants for this activity. Drs. Franks and Maze also sit on a Strategic Advisory Board that advises Air Products, Allentown, Pennsylvania, on possible medical applications for gases, including anesthetic gases. The funding for the current study was provided by Carburios Metálicos, a wholly owned subsidiary of Air Products.

increase in the number of observed emboli, which would have occurred had the bubble size of gas emboli increased significantly.<sup>5</sup>

**Nicholas P. Franks, Ph.D., F.Med.Sci.,\* Rodrigo Benavides, M.D., Mervyn Maze, F.R.C.P., F.R.C.A., F.Med.Sci.** \*Imperial College London, London, United Kingdom. n.franks@ic.ac.uk

## References

1. Benavides R, Maze M, Franks NP: Expansion of gas bubbles by nitrous oxide and xenon. *ANESTHESIOLOGY* 2006; 104:299-302

2. Ma D, Wilhelm S, Maze M, Franks NP: Neuroprotective and neurotoxic properties of the "inert" gas, xenon. *Br J Anaesth* 2002; 89:739-46

3. Ma D, Yang H, Lynch J, Franks NP, Maze M, Grocott HP: Xenon attenuates cardiopulmonary bypass-induced neurologic and neurocognitive dysfunction in the rat. *ANESTHESIOLOGY* 2003; 98:690-8

4. Sta Maria N, Eckmann DM: Model predictions of gas embolism growth and reabsorption during xenon anesthesia. *ANESTHESIOLOGY* 2003; 99:638-45

5. Lockwood GG, Franks NP, Downie NA, Taylor KM, Maze M: Feasibility and safety of delivering xenon to patients undergoing coronary artery bypass graft surgery while on cardiopulmonary bypass: Phase I study. *ANESTHESIOLOGY* 2006; 105:458-65

(Accepted for publication June 19, 2006.)

Anesthesiology 2006; 105:1060

Copyright © 2006, the American Society of Anesthesiologists, Inc. Lippincott Williams & Wilkins, Inc.

## One-lung Ventilation Provided by Anesthesiologists Having Minimal Experience with Thoracic Anesthesia

*To the Editor:*—I read with interest the report by Campos *et al.*<sup>1</sup> This article reported 39% and 36% incidences of failure of proper placement of lung isolation devices by faculty and senior residents, respectively. All participating anesthesiologists did not regularly practice thoracic anesthesia. The authors stated that one-lung ventilation is primarily provided by either a double-lumen tube, the Univent<sup>®</sup> torque control blocker (Vitaid Ltd., Lewiston, NY), or the Arndt<sup>®</sup> blocker (Cook Critical Care, Bloomington, IN). However, an additional blocker that was not mentioned is the Cohen blocker (Cook Critical Care). This commonly used blocker has a wheel at the operator end that, when turned, flexes the tip and gives the anesthesiologist the ability to direct the blocker to the appropriate bronchus.

This is an important article that highlights the difficulties for anesthesiologists who need to provide one-lung ventilation on an occasional basis. There is a learning curve with all of these techniques. I agree with the authors that the successful practice of thoracic anesthesia requires familiarity with the devices, skill in fiberoptic bronchoscopy, and knowledge of the tracheobronchial anatomy. Residents learning thoracic anesthesia should learn all three of these types of skills before graduation, and these should be specific goals in residency programs.

The authors stated that the preoperative instruction included the fiberoptic views that constituted correct positioning of the device. When checking the position of the lung isolating device, it is also important to identify the right upper lobe, the characteristic D-shaped opening to the middle lobe, and the basilar and superior segments of the lower lobe. The left mainstem bronchus is identified, as well as the left upper and left lower lobes. The views of just the double-lumen tube or blocker balloon are not adequate for establishing correct positioning, which could account for some of the malpositions reported in the study. If a simplified instruction is given, it is most important to identify the right upper lobe. It would be helpful to know exactly which views were included in the tutorial.

It would be interesting to repeat the study, with more training, to

achieve a higher success rate. Anesthesiologists who may have to provide one-lung ventilation on occasion should become familiar with the devices, learn the tracheobronchial anatomy, and practice fiberoptic bronchoscopy. There are hands-on workshops that are given at the annual meetings of the American Society of Anesthesiologists and the International Anesthesia Research Society and at the PostGraduate Assembly in Anesthesiology.

When choosing a lung isolation technique, there are other issues to consider besides the initial placement. Blockers, especially when used on the right side, are more easily dislodged than double-lumen tubes. It is also easier to suction and apply oxygen *via* a double-lumen tube, compared with a blocker. The main advantage of the blocker is in the patient with the difficult airway, which was excluded in the study. It is essential to be knowledgeable of possible complications. For example, a blocker may become dislocated into the trachea and block ventilation completely. Techniques for prevention and treatment of hypoxemia must be understood.

There is more to practicing thoracic anesthesia than just the initial placement of the lung isolation device.

The most important teaching message from this study is that practitioners who may have to provide one-lung ventilation on an occasional basis need to do continuing medical education. Development of a tutorial and/or attending a hands-on workshop might be beneficial.

**Steven M. Neustein, M.D.,** The Mount Sinai Medical Center, New York, New York. steve.neustein@msnyuhealth.org

## Reference

1. Campos JH, Hallam EA, Van Natta T, Kernstine KH: Devices for lung isolation used by anesthesiologists with limited thoracic experience: Comparison of double-lumen endotracheal tube, Univent<sup>®</sup> torque control blocker, and Arndt wire-guided endobronchial blocker<sup>®</sup>. *ANESTHESIOLOGY* 2006; 104:261-6

(Accepted for publication June 22, 2006.)

Anesthesiology 2006; 105:1060-1

Copyright © 2006, the American Society of Anesthesiologists, Inc. Lippincott Williams & Wilkins, Inc.

## Results of the Study Comparing Devices Used for Lung Isolation Are Rather Concerning

*To the Editor:*—The study by Campos *et al.*<sup>1</sup> presented some interesting findings. It was surprising that the lung isolation device used to achieve one-lung isolation did not provide an advantage to the anesthesiologist with limited experience. There was no difference in frequency of failure or time to

successful tube positioning among the three devices. A difference might have been anticipated, especially between the Arndt<sup>®</sup> blocker and the left-sided double-lumen endotracheal tube (DLT), because the DLT is the most commonly used device for lung isolation,<sup>2</sup> and bronchial blocking devices gener-

ally require longer time for placement compared with the left-sided DLT.<sup>3,4</sup> The results of the study<sup>1</sup> are rather concerning, because training and exposure for residents largely consist of the use of the DLT, which is used more often and has been in clinical practice for a longer period of time. Because a combination of unfamiliarity with tracheobronchial anatomy and skill in fiberoptic bronchoscopy was responsible for most of the malpositions,<sup>1</sup> perhaps training for residents should concentrate on building a stronger foundation in basic knowledge and skill. Personal experience with the routine use of video-bronchoscopy for confirmation of DLT position has shown that it greatly facilitates the learning process. Anatomy can be demonstrated clearly, and due to simultaneous viewing by the attending and resident, there is better appreciation of the steps involved in the identification and correction of any malposition problems. The use of a virtual bronchoscopy simulator may also be useful in skill acquisition in flexible bronchoscopy.<sup>5</sup>

**Ju-Mei Ng, F.A.N.Z.C.A.,** Singapore General Hospital, Singapore. ng.ju.mei@sgh.com.sg

Anesthesiology 2006; 105:1061-2

Copyright © 2006, the American Society of Anesthesiologists, Inc. Lippincott Williams & Wilkins, Inc.

*In Reply:*—We thank Drs. Ng and Neustein for their interest in our research.<sup>1</sup> Addressing Dr. Ng's letter, we fully agree with his comments that more attention should be given while training residents or staff anesthesiologists in lung isolation techniques, with particular emphasis on tracheobronchial anatomy and skills in fiberoptic bronchoscopy. In fact, after we published our study,<sup>1</sup> we designed a second study based on the lessons that we learned previously. Because the previous study did not demonstrate any advantage between the left-sided double-lumen endotracheal tubes and bronchial blockers (Univent<sup>®</sup> [Vitaid Ltd., Lewiston, NY] and Arndt<sup>®</sup> [Cook Critical Care, Bloomington, IN] blocker) and because the most common device used for lung isolation is the left-sided double-lumen endotracheal tube, we are currently conducting a new study, involving the use of left-sided double-lumen endotracheal tubes among anesthesiologists with limited experience in thoracic anesthesia (*i.e.*, less than two lung isolation device cases per month). In this randomized study, one group of anesthesiologists has been assigned to a tutorial in the simulator facility at The University of Iowa (Iowa City, Iowa), providing a tutorial demonstration and hands-on practice in proper placement of a double-lumen endotracheal tube with the aid of flexible fiberoptic bronchoscopy techniques on a mannequin model. The second group has been assigned to self-training using a DVD that was made by one of the authors (J.H.C.) that includes placement of left-sided double-lumen endotracheal tubes along with a detailed description of fiberoptic bronchoscopy techniques. It is our hope to have a definitive answer to determine which method (simulator training *vs.* DVD self-training) facilitates placement of double-lumen endotracheal tubes for anesthesiologists with limited thoracic anesthesia experience.

Our study has shown that one of the limitations of anesthesiologists with limited experience in thoracic anesthesia is unfamiliarity with bronchial anatomy.<sup>1</sup> In principle, every anesthesiologist resident or staff member should know the anatomical distances pertaining to the airway; for example, in an average subject, the distance from the incisors to the vocal cords is 15 cm, and the distance from the vocal cords to the tracheal carina is approximately 12 cm. The distance from the tracheal carina to the takeoff of the right upper lobe bronchus is an average of 1.5 cm in females and 2 cm in males. The distances from the carina to the takeoff of the left upper and left lower bronchus are an average of 4.5 and 5.0 cm, respectively.

Furthermore, when looking through the fiberoptic bronchoscope, the only early structure in the right mainstem bronchus that has three orifices is the right upper lobe bronchus: These are the apical, the anterior and the posterior bronchi. If every anesthesiologist recognized this anatomical structure, fewer problems would be encountered when inserting lung isolation devices. Adding a shared demonstration

## References

1. Campos JH, Hallam EA, Van Natta T, Kernstine KH: Device for lung isolation used by anesthesiologists with limited thoracic experience: Comparison of double-lumen endotracheal tube, Univent<sup>®</sup> torque control blocker, and Arndt wire-guided endobronchial blocker<sup>®</sup>. *ANESTHESIOLOGY* 2006; 104:261-6
2. Lewis JW, Serwin JP, Gabriel FS, Bastanfar M, Jacobson G: The utility of a double-lumen tube for one-lung ventilation in a variety of noncardiac thoracic procedures. *J Cardiothorac Vasc Anesth* 1992; 6:705-10
3. Bauer C, Winter C, Henzt JG, Ducrocq X, Steib A, Dupeyron JP: Bronchial blocker compared to double-lumen tube for one-lung ventilation during thoracoscopy. *Acta Anaesthesiol Scand* 2001; 45:250-4
4. Campos JH, Kernstine KH: A comparison of a left-sided Broncho-Cath with the torque control blocker Univent and the wire-guided blocker. *Anesth Analg* 2003; 96:283-9
5. Rowe R, Cohen RA: An evaluation of a virtual reality airway simulator. *Anesth Analg* 2002; 95:62-6

(Accepted for publication June 22, 2006.)

through a video-bronchoscopy might enhance training. Unfortunately, it has not been scientifically tested.

In response to Dr. Neustein's comments regarding the Cohen endobronchial blocker,<sup>2</sup> when the original manuscript was submitted, this blocker was mentioned as one of the lung isolation devices. However, one of the reviewers stated that this blocker should be deleted from the manuscript because this device was not tested in our study, and we complied. We have used the Cohen endobronchial blocker when lung isolation is required for either a left- or a right-sided surgical procedure with excellent results but have not identified an advantage over the Arndt<sup>®</sup> wire-guided endobronchial blocker.

As we previously stated, every trainee must be familiar with (1) the devices for lung isolation, (2) fiberoptic bronchoscopy techniques, and (3) the complete knowledge of tracheobronchial anatomy to be able to properly position and use these devices. This should be a high priority in resident training during thoracic anesthesia rotations and should be the case with every anesthesiologist who is involved on an occasional basis with lung isolation cases.

Regarding the question of which views were included in the tutorial, a graphic display of fiberoptic bronchoscopy images was shown in color in real time, showing step-by-step the correct fiberoptic bronchoscopy findings of the right or left bronchus and its secondary bronchus with special attention to the takeoff of the right upper bronchus, including a view of the apical, anterior, and posterior bronchus. Also, as we stated in our study, a pictorial review of the fiberoptic views that constituted proper positioning of the three devices was shown to each participant before the study.

Regarding the workshops given in major meetings, there is no study available to demonstrate the efficacy of this method. Personally, we do not believe it is the solution to the problem. Perhaps a simulator or self-teaching instruction with a professional DVD made by an expert in the field could make a difference. Our next study should provide an answer to this question.

Regarding the choice of lung isolation techniques, Dr. Neustein stated in his letter that bronchial blockers placed on the right side are more easily dislodged than a double-lumen endotracheal tube. We absolutely disagree with his statement. In a previous report by our group,<sup>3</sup> when we compared right-sided double-lumen endotracheal tubes with bronchial blockers (Univent<sup>®</sup> bronchial blocker), there were three malpositions in the right-sided double-lumen endotracheal tube group *versus* five malpositions in the right-sided Univent<sup>®</sup> bronchial blocker group. In both groups, there was only one instance in which a right-sided double-lumen endotracheal tube and a bronchial blocker dislodged; the other malpositions were related to the cuff needing more air or the tube being too far in. Overall in that study, the

number of malpositions was quite low for both tube types and did not differ between the groups. Therefore, the choice of device for lung isolation in the right mainstem bronchus does not matter when a cardiothoracic anesthesiologist places these devices. This concept might not apply to anesthesiologists with limited experience in thoracic anesthesia, but to our knowledge, this has not been tested scientifically.

**Javier H. Campos, M.D.,\* Ezra A. Hallam, B.A., Timothy Van Natta, M.D., Kemp H. Kernstine, M.D., Ph.D.** \*The University of Iowa Roy J. and Lucille A. Carver College of Medicine, Iowa City, Iowa. javier-campos@uiowa.edu

## References

1. Campos JH, Hallam EA, Van Natta T, Kernstine KH: Devices for lung isolation used by anesthesiologists with limited thoracic experience: Comparison of double-lumen endotracheal tube, Univent<sup>®</sup> torque control blocker, and Arndt wire-guided endobronchial blocker. *ANESTHESIOLOGY* 2006; 104:261-6
2. Campos JH: Progress in lung separation. *Thorac Surg Clin* 2005; 15:71-83
3. Campos JH, Massa CF: Is there a better right-sided tube for one-lung ventilation? A comparison of the right-sided double-lumen tube with the single-lumen tube with right-sided enclosed bronchial blocker. *Anesth Analg* 1998; 86:696-700

(Accepted for publication June 22, 2006.)

Anesthesiology 2006; 105:1062-3

Copyright © 2006, the American Society of Anesthesiologists, Inc. Lippincott Williams & Wilkins, Inc.

## Ambesh Maneuver during Subclavian Vein Catheterization Successfully Prevents and Detects Misplacement of the Catheter into Ipsilateral Internal Jugular Vein

*To the Editor:*—During subclavian vein catheterization, one of the most common misplacements of the catheter is into the ipsilateral internal jugular vein (IJV). Chest radiography is performed to identify the exact location of the catheter and procedure-related complications.<sup>1</sup> Misplaced catheters have increased risks of thrombophlebitis in addition to impairment of the central venous pressure (CVP) measurement.<sup>2</sup> Recently, Ambesh *et al.*<sup>3,4</sup> showed that manual occlusion of the ipsilateral IJV in the supraclavicular fossa during and after insertion of subclavian vein catheter is successful in preventing and diagnosing the misplacement of the subclavian vein catheter into the IJV, respectively. Since Ambesh *et al.* developed this maneuver and reported excellent results, no other study has validated these results. Therefore, in a randomized and controlled study, we tested whether the Ambesh maneuver is successful in preventing and diagnosing the misplacement of a subclavian vein catheter into the IJV.

After approval by the Ethics Committee (King George's Medical University, Lucknow, India), 300 adult patients of either sex scheduled to undergo central venous cannulation through the subclavian approach were randomly allocated into two groups of 150 each. Informed verbal consent was obtained from all patients before the procedure. In a patient lying supine with a 15°-20° Trendelenburg position and the head turned to the left, the junction of the medial one third and lateral two thirds of the clavicle in the right infraclavicular area was chosen as the puncture point. An 18-gauge introducer needle was inserted at this point and directed toward the sternoclavicular joint. After free flow of venous blood, the J-tip guide wire was threaded through the cannula into the subclavian vein. In the Ambesh maneuver group of patients, the ipsilateral IJV was occluded, as described by Ambesh *et al.*,<sup>3</sup> during threading of the J guide wire, whereas in control group, no such maneuver was performed. The subclavian vein catheter was then railroaded over the guide wire. The catheter was then connected with a transducer, and the CVP value and waveform pattern were observed. Next, the Ambesh maneuver<sup>4</sup> was reapplied for approximately 10 s, and changes in CVP value and waveform pattern were noted. If there was an increase in CVP value by more than 3 cm H<sub>2</sub>O along with flattening of the waveform, it was presumed that the catheter tip was misplaced into the ipsilateral IJV. At the end of the procedure, chest radiography was performed, and position of the catheter was identified in all patients. The characteristics of the patients were analyzed using the Student *t* test and Fisher exact test. *P* values were two-tailed, and *P* > 0.05 was considered significant.

The age, sex, and body weight of the patients were comparable in

two groups. Five patients in the control group and 7 patients in the Ambesh maneuver group could not be cannulated; therefore, 145 patients in the control group and 143 patients in the Ambesh maneuver group were analyzed. Chest x-ray films showed that in control group, there were 10 (6.9%) misplaced catheters, 9 (6.2%) in ipsilateral IJV and 1 (0.7%) in opposite subclavian vein, whereas in the Ambesh maneuver group, there were 2 (1.4%) (95% confidence interval, 1.4-6.9%; *P* < 0.05) misplaced catheters, both in the opposite subclavian vein and none in the IJV. The operator experienced difficulty in inserting the guide wire in 3 patients of control group and 9 patients of Ambesh maneuver group. The withdrawal and reinsertion of the guide wire and catheter were easy.

The correct placement of the central venous catheter is an essential prerequisite for accurate monitoring of CVP and long-term use of the catheter. Misplacement of the tip may enhance the risk of clot formation, thrombophlebitis, and catheter erosion in addition to impaired CVP measurement.<sup>2,5</sup> Recently, Domino *et al.*<sup>6</sup> reported that the proportion of malpractice claims related to central catheters and vascular access injury has increased significantly. The incidence of malpositioning of CVP catheters through the infraclavicular technique of the subclavian vein varies between 4% and 8%.<sup>3-5</sup> Our study shows a 6.9% incidence of misplacement of subclavian vein catheter through the right infraclavicular approach, and most of the misplacements were in the ipsilateral IJV (6.2%). The operator encountered difficulty in insertion of the guide wire in only 3 patients without IJV occlusion and in 9 patients with IJV occlusion. It becomes obvious that the guide wire in some of these 9 patients of the IJV occlusion group was intending to go into the ipsilateral IJV, but the IJV was occluded manually. The occlusion of ipsilateral IJV in the supraclavicular area may have prevented the cephalad insertion of the guide wire and therefore the subclavian vein catheter into the IJV.

We conclude that the Ambesh maneuver is a simple, inexpensive, and handy bedside technique that helps in preventing and diagnosing the misplacement of a subclavian vein catheter into the IJV. We strongly believe that the Ambesh maneuver should be used in all patients undergoing subclavian vein catheterization.

**Dinesh K. Singh, M.D.,\* Monica K. Kohli, M.D., Vasudha Singhal, M.D., Vineeta Singh, M.D., Alka Rani, M.D.** \*King George's Medical University, Lucknow, India. dksingh\_kgmu@rediffmail.com

## References

1. Boardman P, Hughes JP: Pictorial review: Radiological evaluation and management of malfunctioning central venous catheters. *Clin Radiol* 1998; 53:10-6

Support was provided solely from institutional and/or departmental sources.

2. Conces DJ, Holden RW: Aberrant locations and complications in initial placement of subclavian vein catheters. *Arch Surg* 1984; 119:293-5

3. Ambesh SP, Dubey PK, Matreja P, Singh S: Manual occlusion of internal jugular vein during subclavian vein cannulation: A maneuver to prevent misplacement of catheter into internal jugular vein. *ANESTHESIOLOGY* 2002; 96:215-6

4. Ambesh SP, Pandey JC, Dubey PK: Internal jugular vein occlusion test for rapid diagnosis of misplaced subclavian vein catheter into the internal jugular vein. *ANESTHESIOLOGY* 2001; 95:1377-9

5. Malatinsky J, Kadlic T, Majek M, Samel M: Misplacement and loop formation of central venous catheters. *Acta Anaesthesiol Scand* 1976; 20:237-47

6. Domino KB, Bowdle TA, Posner KL, Spittellie PH, Lee LA, Cheney FW: Injuries and liability related to central vascular catheters: A closed claims analysis. *ANESTHESIOLOGY* 2004; 100:1411-8

(Accepted for publication June 16, 2006.)

Anesthesiology 2006; 105:1063

Copyright © 2006, the American Society of Anesthesiologists, Inc. Lippincott Williams & Wilkins, Inc.

## Edison's Anesthetic

*To the Editor:*—American inventor and businessman Thomas Alva Edison is legendary for his contributions to such technologies as the lightbulb, the telephone, the phonograph, and motion pictures, among many others.<sup>1</sup> In his lifetime, Edison obtained 1,093 US patents and some 1,239 patents in other countries. Little known among these efforts was his “improved anesthetic compound.”

In the summer of 1882, George F. Shrady (Founder and Editor, *Medical Record* 1866-1904) (1837-1907), reported that Thomas Edison invented a new anesthetic made of chloroform, ether, alcohol, and camphor and had applied for British and German patents.<sup>2</sup> The witty but misinformed editor added, “Edison may wish to use it on his stockholders until electric light was in successful operation.”

In fact, the “anesthetic” actually was an analgesic liniment that Edison had prepared in early 1878. He named it Polyform and advertised it for “neurologic pain.” Polyform was a mixture of chloroform, ether, camphor gum, alcohol, chloral hydrate, morphine, and oils of peppermint and clove. Edison believed that his compound's various analgesics would potentiate each other and that the mixture would attack pain in a “shotgun manner.”<sup>3</sup>

In 1879, Edison applied for a US patent but, for unknown reasons, withdrew his application shortly thereafter. In February 1880, the British patent No. 599 was granted to his London agents for a slightly modified compound.<sup>5</sup> The editor of the *Medical Record* was misinformed: Edison did not apply for a German patent<sup>3</sup> (written personal communication, Hubert Rothe, Director, Information Department, German Patent and Trademark Office, Munich, Germany, May 2004).

Topical ether and, especially, chloroform had been widely used for musculoskeletal and neurologic pains since their discovery.<sup>4</sup> At the time of Edison's invention, not only were liniments of chloroform and of camphor used in the United States,<sup>5</sup> but there also existed lotions made of chloroform, camphor, ether, alcohol, morphine, and chloral hydrate.<sup>6</sup> One, Sankt Jakob Oel, had been popular in Germany since the mid-1870s. It was marketed in the United States during the 1880s

under the name of St. Jacob's Oil by the firms of C.A. Voegeler in Baltimore and Kroeger Ltd. of Cincinnati. Its formula is given in several US formularies.<sup>6-8</sup>

Whether Edison knew of St. Jacob's Oil when he invented his Polyform or whether he learned of its existence later on is unknown. The latter may explain why he did not apply for a German patent and withdrew his US application.

**Ray J. Defalque, M.D., M.S., Amos J. Wright, M.L.S.\*** \*School of Medicine, University of Alabama at Birmingham, Birmingham, Alabama. ajwright@uab.edu

The authors thank Gregory J. Higby, Ph.D. (Professor and Director of the American Institute of the History of Pharmacy, Madison, Wisconsin), Michael A. Flannery, Ph.D. (Associate Professor and Associate Director for Historical Collections, University of Alabama at Birmingham, Birmingham, Alabama), and Hubert Rothe (Director, Information Department, German Patent and Trademark Office, Munich, Germany) for their valuable information.

## References

1. Josephson M: Edison: A Biography. New York, Wiley, 1992
2. Edison's anaesthetic. Edited by Shrady GF. *Medical Record* 1882; 22:374
3. The Papers of Thomas A. Edison. Vol 4. Edited by Israel PB, Nier AP, Carlat P. Baltimore, London, Johns Hopkins University Press, 1989, pp 228-9
4. Kent DF: The Medical Uses of Ether and Chloroform in the 19th Century: How Medical Uses Contrasted with Surgical Uses [dissertation]. Madison, New Jersey, Drew University, 1995
5. The Dispensary of the United States of America, 13th ed. Edited by Wood GB, Bache F. Philadelphia, JB Lippincott, 1871, pp 1234-5
6. Rice C: Hospital Formulary of the Department of Public Charities and Correction of the City of New York, 4th edition. New York, Printing Bureau, Ward's Island, 1889, p 231
7. Fenner B: Fenner's Twentieth Century Formulary and International Dispensary, 12th edition. Westfield, New York, B. Fennel Publisher, 1903, p 1347
8. Street JP: The Composition of Certain Patent and Proprietary Medicines. Chicago, AMA Publications, 1917, p 233

(Accepted for publication June 19, 2006.)

Anesthesiology 2006; 105:1063-4

Copyright © 2006, the American Society of Anesthesiologists, Inc. Lippincott Williams & Wilkins, Inc.

## A Rare Iatrogenic Cause of Upper Gastrointestinal Bleeding

*To the Editor:*—An 85-yr-old man was transferred to our institution for evacuation of a subdural hematoma. His course was complicated by deep venous thromboembolism necessitating intravenous heparin. He ultimately required intubation and was ventilated for several minutes before the recognition of an inadvertent esophageal intubation. The endotracheal tube was correctly repositioned, and a nasogastric tube was inserted with the return of approximately 500 ml of fresh blood.

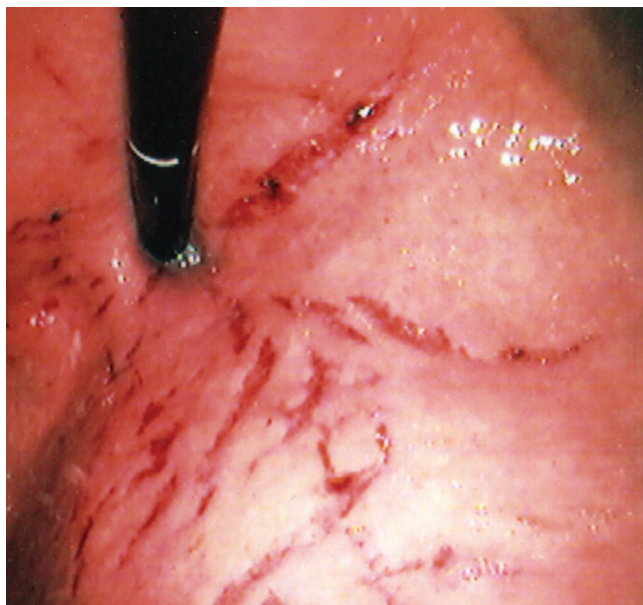
After the heparin was discontinued, his partial thromboplastin time normalized, and the platelet count and international normalized ratio were also normal. On upper endoscopy, the esophagus and duodenum were completely normal. In the gastric fundus, there were linear mucosal tears (fig. 1). There was no surrounding inflammation, and the appearance was not consistent with trauma from the nasogastric tube. There was minimal oozing of blood and small adherent clots, but there was nothing necessitating endoscopic treatment.

Tears in the gastric mucosa from overdistension during endoscopy for percutaneous endoscopic gastrostomy tube placement in the set-

Support was provided solely from institutional and/or departmental sources.

Anesthesiology, V 105, No 5, Nov 2006

Copyright © by the American Society of Anesthesiologists. Unauthorized reproduction of this article is prohibited.



**Fig. 1. Retroflexed view revealing mucosal tears along the lesser curvature of the stomach caused by overdistention after inadvertent esophageal intubation.**

ting of malnutrition, advanced age, and gastric atrophy have been described.<sup>1</sup> Gastric perforation from overdistention has been reported in patients undergoing cardiopulmonary resuscitation<sup>2,3</sup> and inadvertent esophageal intubation.<sup>4-8</sup> In these cases of iatrogenic gastric rupture, rapid accumulation of air leads to mucosal tears and ultimately to rupture of the stomach. At laparotomy or autopsy, the defect is typically identified in the lesser curvature of the stomach (the area of least elastance).<sup>8</sup> Rapid gastric distention may cause compression of the cardia by the right hemidiaphragm and also alter the angle of the antrum.<sup>9</sup> These changes allow air entry through the gastroesophageal junction but prevent escape of air through the gastroesophageal junction or the pylorus.<sup>8,9</sup>

We report a case of acute upper gastrointestinal bleeding from mucosal tears resulting from gastric overdistention after inadvertent esophageal intubation. To our knowledge, this complication has not been previously described and should be included in the differential diagnosis of upper gastrointestinal bleeding in critically ill patients who have had inadvertent esophageal intubation or cardiopulmonary resuscitation. The combination of history of esophageal intubation, involvement of the lesser curvature, and similarity to the mucosal tears seen by Green and Tendler<sup>1</sup> during percutaneous endoscopic gastrostomy tube placement support this diagnosis. In addition, in cases of upper gastrointestinal bleeding when a history of inadvertent esophageal intubation is obtained, gastric perforation should be ruled out with abdominal imaging before performing upper endoscopy.

**Daniel K. Mullady, M.D.,\* James B. McGee, M.D.** \*University of Pittsburgh School of Medicine, Pittsburgh, Pennsylvania. mulladydk@upmc.edu

## References

1. Green BT, Tendler DA: Diffuse mucosal hemorrhage after air insufflation during endoscopy for PEG tube placement. *Am J Gastroenterol* 2003; 98:502-4
2. Offerman SR, Holmes JF, Wisner DH: Gastric rupture and massive pneumoperitoneum after bystander cardiopulmonary resuscitation. *J Emerg Med* 2001; 21:137-9
3. Mills SA, Paulson D, Scott SM, Sethi G: Tension pneumoperitoneum and gastric rupture following cardiopulmonary resuscitation. *Ann Emerg Med* 1983; 12:94-5
4. Gilbert TB: Gastric rupture after inadvertent esophageal intubation with a jet ventilation catheter. *ANESTHESIOLOGY* 1998; 88:537-8
5. Bilotta JJ, Floyd JL: Bilateral pneumothoraces and pneumoperitoneum following esophageal intubation. *Crit Care Med* 1987; 15:281-3
6. Adler J, Dykan M: Gastric rupture: An unusual complication of the esophageal obturator airway. *Ann Emerg Med* 1983; 12:224-5
7. Crippen D, Olvey S, Graffis R: Gastric rupture: An esophageal obturator airway complication. *Ann Emerg Med* 1981; 10:370-3
8. Hershey MD, Hannenberg AA: Gastric distention and rupture from oxygen insufflation during fiberoptic intubation. *ANESTHESIOLOGY* 1996; 85:1479-80
9. Albo R, de Lorimier AA, Silen W: Spontaneous rupture of the stomach in the adult. *Surgery* 1963; 53:797-805

(Accepted for publication June 21, 2006.)

Anesthesiology 2006; 105:1064-5

Copyright © 2006, the American Society of Anesthesiologists, Inc. Lippincott Williams & Wilkins, Inc.

## Anesthesia in a Patient with Gitelman Syndrome

*To the Editor:*—We would like to report our recent experience with a patient with a rare disorder known as Gitelman syndrome.

*Gitelman syndrome*, a variant of Bartter syndrome, is a congenital autosomal recessive disorder characterized by hypokalemia, hypomagnesemia, and hypocalcemia associated with metabolic alkalosis.<sup>1,2</sup> Unlike Bartter syndrome, which presents in the neonatal period and childhood up to 5 yr of age, Gitelman syndrome presents in early adulthood. The two syndromes may also be distinguished from each other because Gitelman syndrome presents with hypomagnesemia and hypocalcemia, whereas Bartter syndrome presents with normal serum magnesium and high urinary calcium.<sup>1,2</sup> Patients with Gitelman syndrome usually present with cramps, fatigue, muscle weakness, and carpopedal spasms.

A 47-yr-old woman recently presented to us for repair of nasolacrimal duct stenosis during general anesthesia. Her medical history was significant for diabetes, gastroesophageal reflux disease, and thyroid disease. Her surgical history included a hysterectomy, an appendectomy, a thyroidectomy, a breast biopsy, and an explor-

atory laparotomy for ovarian cancer. She described her symptoms as cramps in her legs. She related that 2 yr ago during the surgery for her thyroid, she had a cardiac arrest. The patient stated that her cardiac arrest had occurred because of unrecognized hypokalemia and hypomagnesium.

Her medications included potassium chloride, magnesium, spiro-lactone, levothyroxine, glyburide, and lansoprazole. Her vital signs included a blood pressure of 111/77 mmHg, pulse of 98 beats/min, respiration of 18 breaths/min, and temperature of 97.9°F. Her laboratory studies showed the following: white blood cells, 10.6 (4.1-11.2); hemoglobin, 15.3 g/dl (11.5-15.1); hematocrit, 45.0% (35-46); platelets, 503 × 10<sup>3</sup> (140-400); Na, 137 mEq/l (136-145); K, 4.2 mEq/l (3.5-5.1); Cl, 96 mEq/l (98-107); HCO<sub>2</sub>, 27 (20-27); blood urea nitrogen, 20 mg/dl (6-20); creatinine, 0.8 (0.5-1.2); glucose, 68 mg/dl (65-115); Ca, 10.9 mEq/l (8.8-10.5); Mg, 1.9 mEq/l (1.3-2.1); and urine creatinine, 181 mEq/l. She was 4 ft 11 in tall and weighed 70 kg.

In the operating room after placement of an electrocardiograph, noninvasive blood pressure cuff, and pulse oximetry, general anesthesia was induced using propofol and fentanyl with rocuronium for muscle relaxation and for tracheal intubation. Desflurane was used

Support was provided solely from institutional and/or departmental sources.

for maintenance of anesthesia. At the end of the case, the muscle relaxant was reversed using glycopyrrolate and neostigmine. When the patient was awake and responding to commands, her trachea was extubated in the operating room without any complications.

Although the patient's current magnesium level was only slightly decreased, we decided not to replace it. Her current potassium level was also normal. She was aware of her diagnosis of Gitelman syndrome and was taking potassium and magnesium replacement. Review of the literature reveals that ventricular tachycardia has occurred in patients with Gitelman syndrome when potassium and magnesium levels are low. This potentially fatal arrhythmia must be recognized and treated early.

**Jack Bolton, M.D., James F. Mayhew, M.D.\*** \*Texas Tech University Health Sciences Center, Lubbock Texas. jmayhew@ttusc.edu

## References

1. Shaer AJ: Inherited primary renal tubular hypokalemic alkalosis: A review of the Gitelman and Bartter syndromes. *Am J Med Sciences* 2001; 322:316-332
2. Naesens M, Steels P, Verberckmoes R, Vanrenterghem Y, Kuypers D: Bartter's and Gitelman's syndromes: From gene to clinic. *Nephron Physiol* 2004; 96:65-78

*(Accepted for publication June 28, 2006.)*