

Effect of Methimazole Intake on Post-Natal Development of Hippocampus in Albino Rats Offspring (Histological Study)

HAZEM A.S. EL SHAAR, M.D.*; SAYED M. EL SAYED, M.D.** and SAMI ALGAIDI, M.D.***

The Department of Anatomy and Embryology, Faculty of Medicine, Assiut*, AM Shams** and Taibah*** Universities

Abstract

Introduction: Hypothyroidism during neonatal life markedly affects development of the hippocampus. Methimazole is an antithyroid drug that may induce hypothyroidism during the postnatal period and markedly retard both maturation and development of the hippocampus.

Aim of the Work: The present study aimed to detect the post-natal structural changes of the hippocampus resulting from hypothyroidism induced by methimazole intake.

Material and Methods: Twenty pregnant female rats were separated into 2 groups (10 animals each): Group I (control animals) and Group II (animals taking methimazole from day 1 of pregnancy till day 21 after delivery). Paraffin sections of the hippocampus were prepared and stained with Gallocyanine chrom-alum. Measurements of the mean thickness of stratum pyramidale of CA1 of the hippocampus were done and statistically analyzed.

Results: There was delayed maturation of the hippocampus CA1 subfield with markedly thin stratum pyramidale and appearance of degenerating and immature neurons in the treated group (Group II). The mean thickness and volume proportion (Vv) of stratum pyramidale of CA1 subfield of the hippocampus among the studied groups showed significant decrease in the treated group (Group II) as compared to the control group (Group I).

Conclusion: Hypothyroidism induced by methimazole intake during the developmental period of the brain markedly affects the post-natal development of the hippocampus through altering proliferation and migration of nerve cells. Although some authors stated that the drug can be used safely by the mothers during lactation, it should be used with precautions.

Key Words: Hippocampus — Methimazole — Development — Rats offspring.

Introduction

THE hippocampus proper or (cornu ammonis) is a c-shaped neural structure in the temporal lobe at the floor of the lateral ventricle. It is composed of

multiple subfields that are defined along the curve, from CA4 (hilar layer) through CAL. The CA regions are structured in layers (or strata). The most clearly defined are 3 strata; stratum pyramidale (contains the cell bodies of the pyramidal neurons which are the principal excitatory neurons of the hippocampus), stratum oriens (contains the basal dendrites of pyramidal neurons and other cells) and Stratum radiatum (contains septal and commissural fibers, interneurons and other cells). **Hi.** The hippocampal region occupies most of the ventroposterior and ventrolateral walls of the cerebral cortex. This region includes six distinct structures: Entorhinal cortex, parasubiculum, pre-subiculum, subiculum proper, fields' cornu ammonis (CA) 1-CA3 in Ammon's horn, and dentate gyms. Among the structures in the hippocampal region, the hippocampus (Ammon's horn and the dentate gyms) extends anteriorly beneath the corpus callosum to the posterior level of the septal nuclei [2].

Uematsu observed a significant non-linear age-related volume change, especially during the first few years of life, in the hippocampus. The robust growth of the hippocampus during infancy clarified the importance of this period for neural and functional development [3].

The hippocampus plays an important role in memory formation/retrieval and the dentate gyms (DG) subfield exhibits continued neurogenesis into adulthood. Therefore, this region contains both mature old granule cells and immature recently born GCs that are generated throughout adult life [4]. Production of new neurons in the post-natal life was identified in increasing regions of the adult brain, including the olfactory bulb and dentate gyms (DG) of the hippocampus. Neural stem cells (NSCs) are widely distributed in the central nervous system. One of the major sources of adult

Correspondence to: Dr. Hazem A. Sayed El Shaar,
[E-mail: Hzmshaar@hotmail.com](mailto:Hzmshaar@hotmail.com)

NSCs is the subventricular zone (SVZ) of the lateral ventricle. Hippocampal NSCs are localized in the subgranular zone (SGZ) of the DG apart from ventricles. A subset of NSCs migrates and forms a secondary germinal zone in the hippocampus during embryonic development. The formation of DG occurs mainly during postnatal development, and NSCs in the secondary germinal zone appear to remain in the SGZ, supply-ing neurons to the existing hippocampal network throughout adulthood [5].

The structural integrity of the hippocampus is dependent upon adequate supplies of thyroid hormone during development [6]. Thyroid hormones (THs) have a strictly regulated action in the brain, since these hormones play a crucial role in the development and physiological functioning of the central nervous system (CNS). They regulate the neuronal cytoarchitecture, neuronal growth and synaptogenesis, and they have widely distributed receptors in the CNS [7]. Also, the oligodendrocyte is a well-recognized target of thyroid hormones in the developing brain and these hormones regulate oligodendrocyte production of myelin [8].

Hypothyroidism during neonatal life (a critical phase of brain development) reduces cell number, synaptogenesis and dendritic arborization; alters cell migration patterns; and decreases axonal myelination. Abnormal development after severe hypothyroidism has been well documented in the cerebellum, neocortex and hippocampus [9].

Zhang found that abnormal iodine intake by rats could affect the neurological development of offspring by reducing the expression of brain derived neurotrophic factor (BDNF) during hippocampal development of the offspring and that might be related with the impaired cognitive functions [10].

Methimazole is an anti-thyroid drug that can inhibit the synthesis of thyroid hormones through interference with the conversion of iodide to iodine and consequently the iodination of tyrosyl groups. The tyrosyl groups are also inhibited from joining to form T3 and T4. Hypothyroidism during the postnatal period, induced by the administration of methimazole is known to markedly retard both maturation and development of the nervous system [11].

Although, Mookadam reported that neonatal rats receiving methimazole in their mothers' milk are rendered hypothyroid [12]. However, Azizi and Amouzegar considered that the drug doesn't produce hypothyroidism in breast-fed infants [13].

Due to lack of previous histological researches dealing with the effect of Methimazole on the development of rat hippocampus, the present study was designed to detect the post-natal developmental changes of rat hippocampus induced by Methimazole intake.

Material and Methods

Chemicals:

2-Mercapto-1-methylimidazole 99% (SIGMA-ALDRICH, ST. LOUIS, MO, USA), imported by the Egyptian International Center for import, Cairo, Egypt.

CAS Number: 60-56-0.

Formula: C₄H₆N₂S.

Molecular Weight: 114.17.

Packaging 25g in glass bottle.

Form: Crystalline.

Colour: Beige.

Animals:

Forty adult albino rats (20 male and 20 female), weighing about 180gm, were housed in the animal house of the Faculty of Medicine, Assiut University at ambient temperature 22±3°C with a 12-h light/dark cycle and a minimum relative humidity of 40%. Standard diet and tap water were given.

Experimental design:

After a one week acclimatization in the laboratory conditions, pairs of male and female rats will be kept overnight in each cage. Pregnant female rats will be inspected daily for the presence of the vaginal plug which will indicate day 0 of pregnancy.

Twenty pregnant female rats will be randomly divided into two groups.

The first group was served as a control group.

The second group received 0.025% methimazole (Sigma, France) in drinking water [14]. Treatments will be started from the first day of pregnancy till day 21 after delivery.

Pregnant female rats were allowed to deliver spontaneously. At days 1,7,14&21, the offspring from each group were anaesthetized with diethyl ether then sacrificed. The brain of each rat will be removed carefully and specimens were fixed in Bouin's solution then prepared for light microscopic examination according to Drury and Wallington [15]. Gallocyanine chrom-alum staining method was used to demonstrate Nissl's granules, nuclei and nucleoli. This staining method was performed

to examine the structural differences between brains of the different animal groups.

Stereological design:

I- Estimation of the thickness of CA1 subfield of hippocampus:

A number of non-overlapping fields at a magnification of X1000 times, exposing a complete scene of CA1 of hippocampus were measured for its thickness using a computed image analysing tool program specially prepared for Leica DMD 108 microscope. The previously measured parameter was calculated for each animal group. The mean value \pm SD were calculated. Unpaired student t-test was used to compare between mean values of different groups. The level of significance (*p*-value) was considered as follows: $p < 0.05$ is non-significant, $p < 0.05^*$ is significant and $p < 0.01^{**}$ is highly significant.

II- Estimation of volume proportion (Vv) of stratum pyramidale of CA1 of hippocampus:

This was done by using the point counting technique. A measuring area (about 9cm X 9cm) on a paper was divided into 100 points (10 points X 10 points). This diagram was placed against Lucida lens, and the slide was placed against object piece X 40. The numbers of points fallen on stratum pyramidale of CA1 of hippocampus. The volume proportion of stratum pyramidale was calculated as follows; $V_v = PL/PT$, where PL: The number of the points fell on the measured layer and PT: The total number of the points drawn in the area that equals to 100 points [16].

Results

Histological analysis:

1- Control group:

Light microscopic examination of galloxyanine chrom-alum stained sections of control albino rats' hippocampus showed the following; in one day old rats, the hippocampus proper displayed its characteristic arc shape with CA1, CA2, CA3 and CA4 subfields arranged subsequently. Each subfield consisted of three distinct layers, upper layer (stratum oriens), middle layer (stratum pyramidale) and lower layer (stratum radiatum) (Fig. 1). Stratum pyramidale of CA 1 subfield showed numerous neurons with round pale vesicular nuclei and underlying numerous immature darkly stained neurons (migrating neurons). Numerous astrocytes with their pale cytoplasm and branching pattern were observed in the neuropil of stratum oriens and stratum radiatum (Figs. 2,3).

In seven days old rats, stratum pyramidale of CA1 subfield showed compact layers of newly added mature neurons with round pale vesicular nuclei in addition to overlying widely spaced mature neurons with their peripheral processes. Few immature darkly stained neurons were observed. Some astrocytes were seen in the neuropil of stratum oriens and stratum radiatum (Figs. 4,5).

In fifteen days old rats, stratum pyramidale of CA1 subfield showed compactly arranged layers of mature neurons with some underlying darkly stained immature neurons. Numerous astrocytes were observed in stratum oriens and stratum radiatum (Figs. 6,7).

In twenty one days old rats, stratum pyramidale of CA1 subfield consisted of 4-5 layers of dispersed mature neurons with round vesicular nuclei and peripheral processes with some compactly arranged darkly stained immature neurons with irregular or oval nuclei. Numerous astrocytes were dispersed in stratum oriens and stratum radiatum (Figs. 8,9).

2- Treated group:

Light microscopic examination of galloxyanine chrom-alum stained sections of treated albino rats' hippocampus showed stratum pyramidale of CA1 subfield consisting of few mature neurons with round vesicular nuclei, with underlying numerous degenerating cells with pale disintegrating cytoplasm and irregular nuclei. Multiple dark stained astrocytes were seen in stratum radiatum and stratum oriens (Figs. 10,11).

In seven days old rats, stratum pyramidale of CA1 subfield showed few mature neurons with round vesicular nuclei and peripheral processes with many darkly stained immature neurons in-between and underlying them. Few astrocytes were observed in stratum oriens and stratum radiatum (Figs. 12,13).

In fifteen days old rats, stratum pyramidale of CA1 subfield showed few mature neurons with round vesicular nuclei with underlying numerous compactly arranged immature darkly stained neurons with irregular nuclei. Few astrocytes were observed in both stratum oriens and stratum radiatum (Figs. 14,15).

In twenty one days old rats, stratum pyramidale of CA1 subfield appeared markedly thin (2-3 layers) with few mature neurons with round vesicular nuclei and pale cytoplasm and some darkly stained immature neurons with irregular nuclei were compactly arranged. Few astrocytes with round vesic-

ular nuclei and light cytoplasm were dispersed in stratum oriens and stratum radiatum (Figs. 16,17).

Statistical analysis:

I- Estimation of the thickness of CA1 subfield of hippocampus:

In one day albino rats, the mean thickness of stratum pyramidale of CA1 of the hippocampus in group (II) treated rats significantly decreased (p0.00) by —0.4 times less than group (I) control rats. In seven days old rats, the mean thickness of stratum pyramidale of CA1 of the hippocampus in group (II) treated rats significantly decreased by —0.7 times less than group (I) control rats (p0.00). Also, in fifteen days old rats, there was a significant reduction in the mean thickness of stratum pyramidale of CA1 of the hippocampus of group (II) by — 0.9 as compared to group (I) (p0.00). Lastly,

in twenty one days old rats, the mean thickness of stratum pyramidale of CA1 of the hippocampus in group (II) significantly decreased by —0.7 in comparison to group (I) (p=0.00).

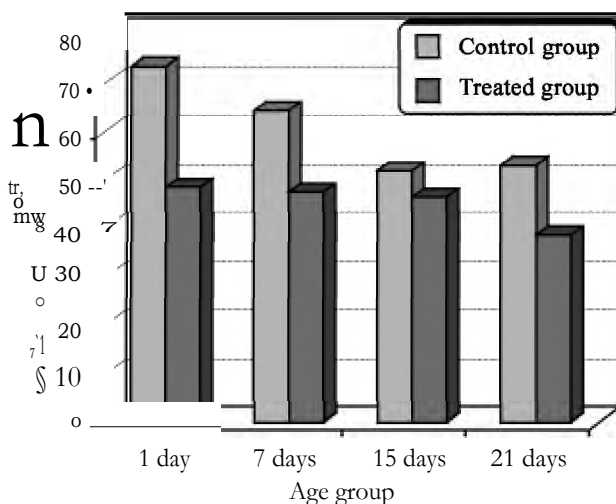
II- Estimation of volume proportion (Vv) of stratum pyramidale of CA1 of the hippocampus:

The estimated volume proportion (Vv) of stratum pyramidale of CA1 of the hippocampus showed significant decrease in group (II) treated rats (p0.000) by — 0.7 times less than group (I) control one day & seven days old rats. In fifteen days old rats, it decreased significantly in group (II) treated rats by — 0.9 times less than group (I) control rats (p=0.000). Lastly, in twenty one days old rats, it decreased significantly in group (II) treated rats by —0.7 times less than group (I) control rats (p=0.000).

Table (1): Measurement of the mean thickness of stratum pyramidale of CA1 of the hippocampus among the studied groups according to their age.

Age	Mean thickness of stratum pyramidale of CA1 of the hippocampus		
	Group I (control rats)	Group II (treated rats)	p value
1 day	73.28±8.1 SD	48.63±3.07 SD	0.000**
7 days	64.3±5.2 SD	47.4±6.3 SD	0.000**
15 days	51.6±8.3 SD	46±4.6 SD	0.000**
21 days	52.9±4.7 SD	38.05±5.6 SD	0.000**

p-value is highly significant if p<0.01.

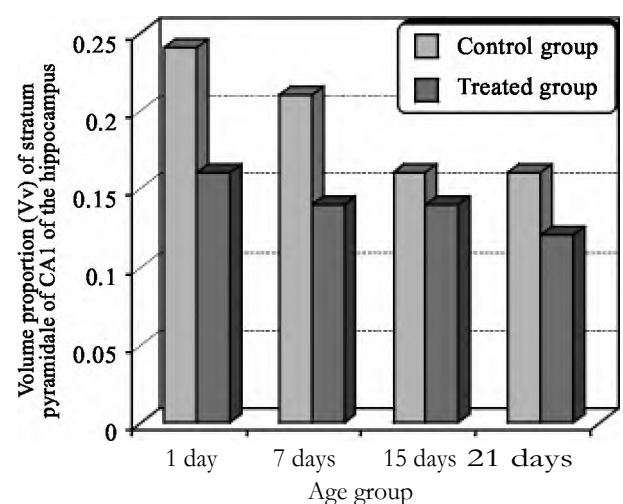


Graph (1): Comparison between the mean thickness of stratum pyramidale of CA1 in the hippocampus of studied age groups.

Table (2): Measurement of the volume proportion (Vv) of stratum pyramidale of CA1 of the hippocampus among the studied groups according to their age.

Age	Volume proportion (Vv) of stratum pyramidale of CA1 of the hippocampus		
	Group I (control rats)	Group II (treated rats)	value
1 day	0.24±0.01 SD	0.16±0.02 SD	0.000**
7 days	0.21±0.02 SD	0.14±0.02 SD	0.000**
15 days	0.16±0.01 SD	0.14±0.01 SD	0.000**
21 days	0.16±0.01 SD	0.12±0.01 SD	0.000**

p-value is highly significant if p<0.01.



Graph (2): Comparison between the volume proportions (Vv) of stratum pyramidale of CA1 in the hippocampus of studied age groups.

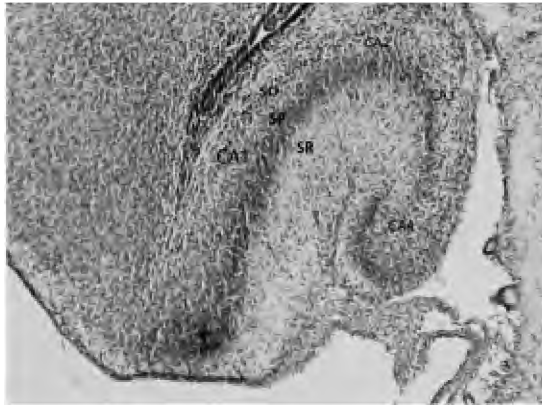


Fig. (1): A photomicrograph of a section in the hippocampus of one day old control rats showing its CA1, CA2, CA3 and CA4 subfields. Each subfield is formed of 3 distinct layers; stratum oriens (SO), stratum pyramidale (SP) and stratum radiatum (SR).
(Gallocyanine chrom-alum x100).

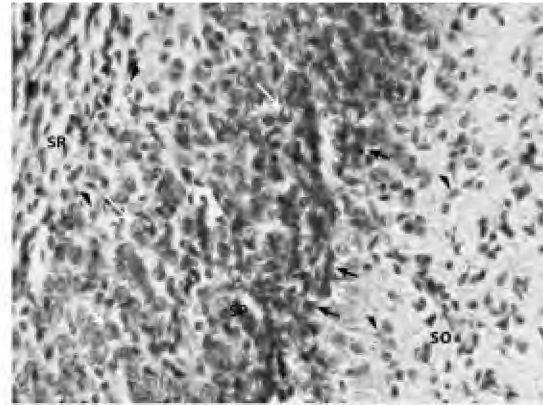


Fig. (2): A photomicrograph of a section in the hippocampus of one day old control rats showing stratum pyramidale (SP) of CA1 subfield containing neurons with round vesicular nuclei (white arrows), and numerous immature darkly stained migrating cells (black arrows). Astrocytes (arrow heads) are observed in the neuropil of stratum oriens (SO) and stratum radiatum (SR).
(Gallocyanine chrom-alum x400).

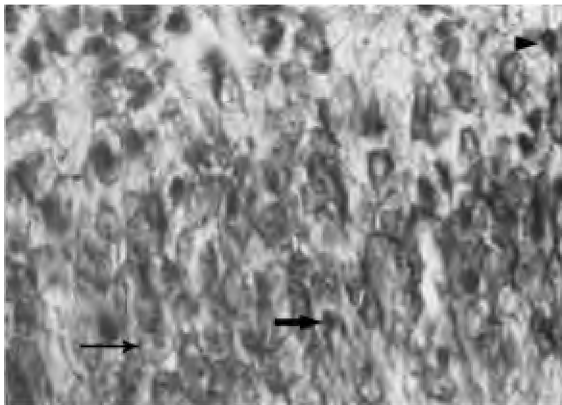


Fig. (3): A photomicrograph of a section in the hippocampus of one day old control rats showing stratum pyramidale of CA1 subfield containing mature neurons with round vesicular nuclei (thick arrows), and numerous immature darkly stained migrating cells (thick arrow). Astrocytes with branching pattern (arrow head) are observed in between.
(Gallocyanine chrom-alum x1000).

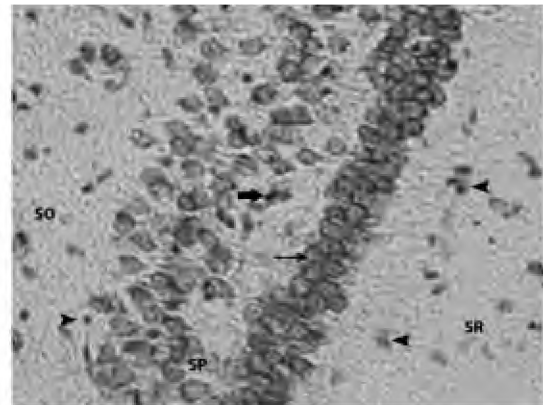


Fig. (4): A photomicrograph of a section in the hippocampus of seven days old control rats showing stratum pyramidale (SP) of CA1 subfield containing compactly arranged mature neurons with round vesicular nuclei (thin arrow), and some immature darkly stained migrating cells with irregular nuclei (thick arrow). Astrocytes (arrow heads) are observed in stratum oriens (SO) and stratum radiatum (SR).
(Gallocyanine chrom-alum x400).

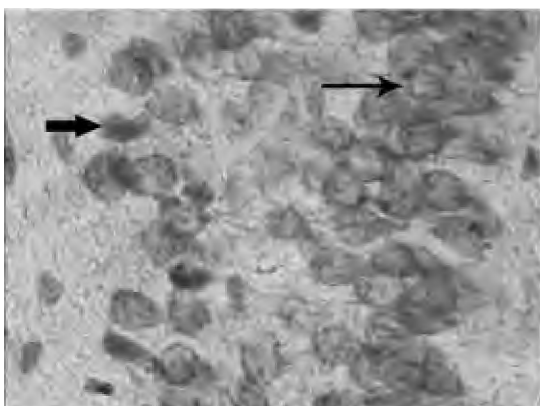


Fig. (5): A photomicrograph of a section in the hippocampus of seven days old control rats showing stratum pyramidale of CA1 subfield containing mature neurons with round vesicular nuclei compactly arranged in rows (thin arrow), and some immature darkly stained cells with oval nuclei (thick arrow).
(Gallocyanine chrom-alum x1000).

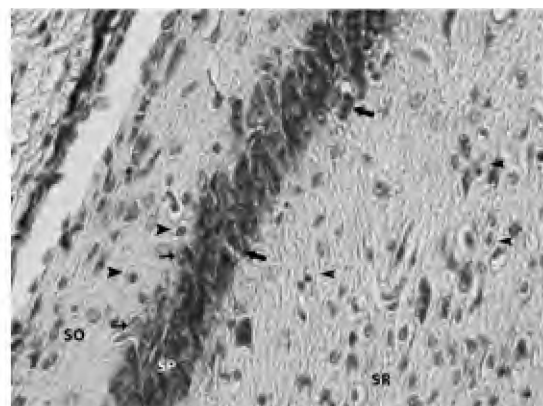


Fig. (6): A photomicrograph of a section in the hippocampus of fifteen days old control rats showing stratum pyramidale (SP) of CA1 subfield containing compactly arranged mature neurons with round vesicular nuclei (thin arrows) and some darkly stained immature neurons with irregular nuclei (thick arrows). Numerous astrocytes (arrow heads) are observed in stratum oriens (SO) and stratum radiatum (SR).
(Gallocyanine chrom-alum x400).

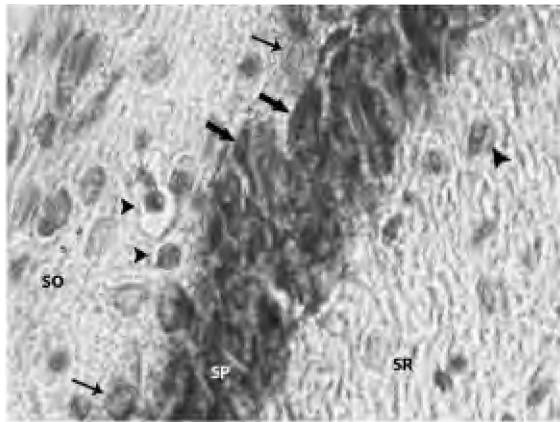


Fig. (7): A photomicrograph of a section in the hippocampus of fifteen days old control rats showing stratum pyramidale (SP) of CA1 subfield containing some mature neurons with round vesicular nuclei (thin arrows), and compactly arranged layers of immature darkly stained cells with irregular nuclei (thick arrows). Some astrocytes (arrow heads) are observed in stratum oriens (SO) and stratum radiens (SR). (Gallocyanine chrom-alum x1000).

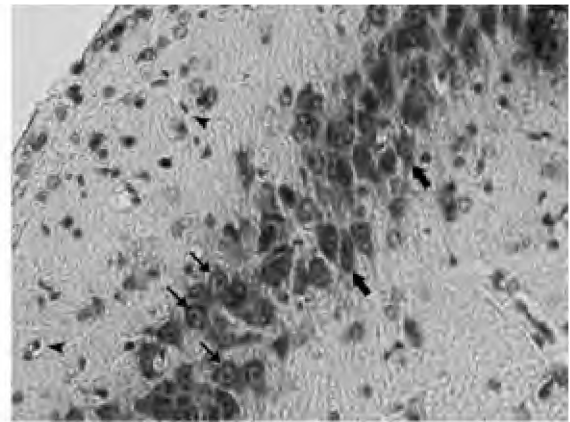


Fig. (8): A photomicrograph of a section in the hippocampus of twenty one days old control rats showing stratum pyramidale of CA1 subfield containing some mature neurons with round vesicular nuclei and compactly arranged darkly stained immature neurons with irregular nuclei (thick arrows), and some mature neurons with round nuclei (thin arrows). Astrocytes (arrow heads) are observed. (Gallocyanine chrom-alum x400)

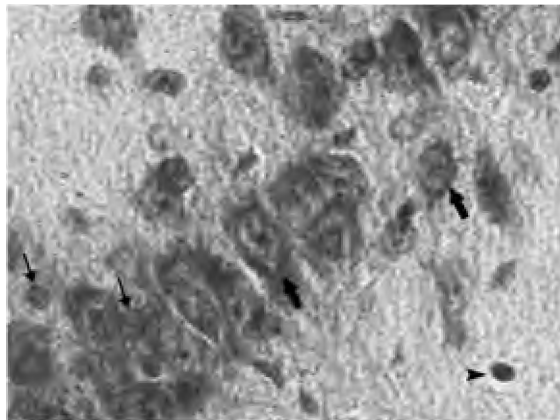


Fig. (9): A photomicrograph of a section in the hippocampus of twenty one days old control rats showing stratum pyramidale of CA1 subfield containing some mature neurons with round vesicular nuclei (thin arrows) and some immature darkly stained cells with irregular nuclei (thick arrows). Astrocytes with pale cytoplasm and round nuclei are observed (arrow heads). (Gallocyanine chrom-alum x1000)

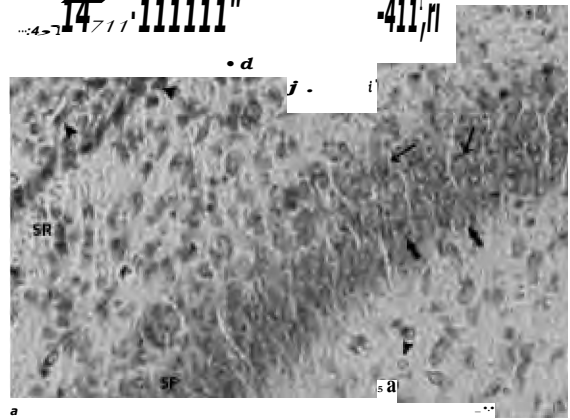


Fig. (10): A photomicrograph of a section in the hippocampus of one day old treated rats showing stratum pyramidale of CA1 subfield containing few mature neurons with round vesicular nuclei (thin arrows), and numerous degenerated pale stained irregularly shaped cells (thick arrows). Many astrocytes (arrow heads) are observed in the neuropil of stratum oriens and stratum radiatum. (Gallocyanine chrom-alum x400).

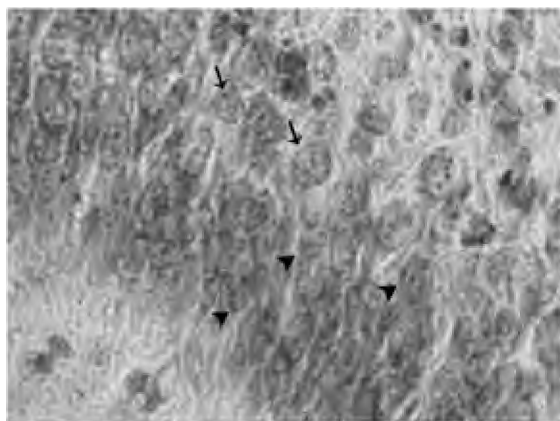


Fig. (11): A photomicrograph of a section in the hippocampus of one day old treated rats showing stratum pyramidale of CA1 subfield containing some mature neurons with round vesicular nuclei (arrows), and numerous degenerated pale stained irregularly shaped cells (arrow heads). (Gallocyanine chrom-alum x1000).

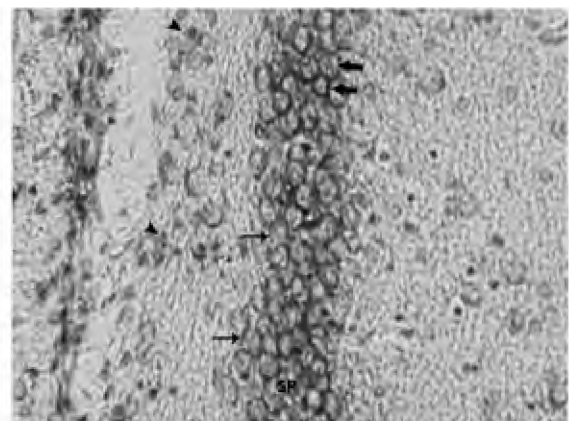


Fig. (12): A photomicrograph of a section in the hippocampus of seven days old treated rats showing stratum pyramidale (SP) of CA1 subfield containing few mature neurons with round vesicular nuclei (thin arrows), and numerous darkly staining immature neurons (thick arrows). Few astrocytes are observed (arrow heads). (Gallocyanine chrom-alum x400).

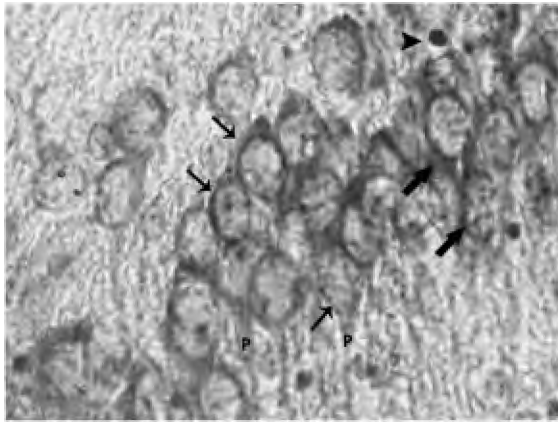


Fig. (13): A photomicrograph of a section in the hippocampus of seven days old treated rats showing stratum pyramidale (SP) of CA1 subfield containing few mature neurons with round vesicular nuclei (thin arrows) and long processes (P), and some darkly staining immature neurons (thick arrows). Few astrocytes are observed (arrow heads). (Galloyanine chrom-alum x400).

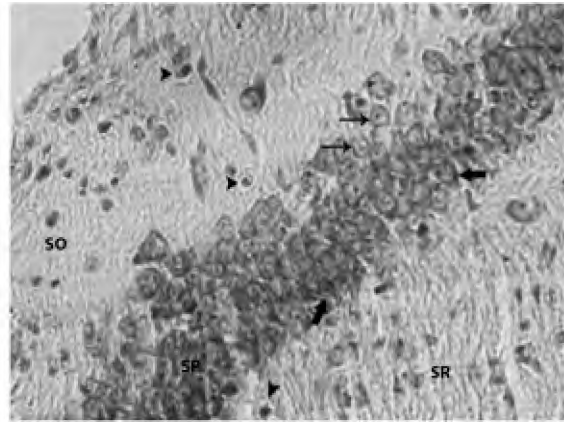


Fig. (14): A photomicrograph of a section in the hippocampus of fifteen days old treated rats showing stratum pyramidale (SP) of CA1 subfield containing few mature neurons with round vesicular nuclei (thin arrows) and numerous darkly stained immature neurons with irregular nuclei (thick arrows). Few astrocytes (arrow heads) are observed in stratum oriens (SO) and stratum radiatum (SR). (Galloyanine chrom-alum x400).

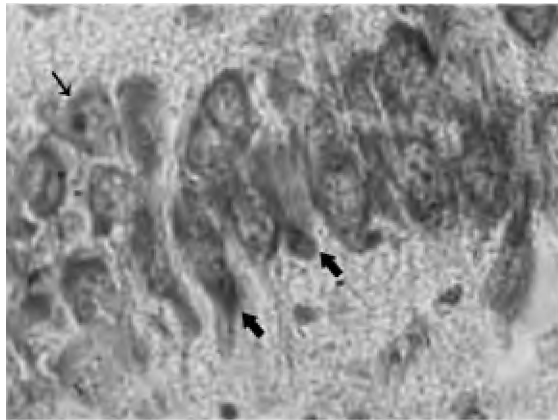


Fig. (15): A photomicrograph of a section in the hippocampus of fifteen days old treated rats showing stratum pyramidale of CA1 subfield containing few mature neurons with round vesicular nuclei (thin arrows) and numerous darkly stained immature neurons with irregular nuclei (thick arrows). (Galloyanine chrom-alum x1000).

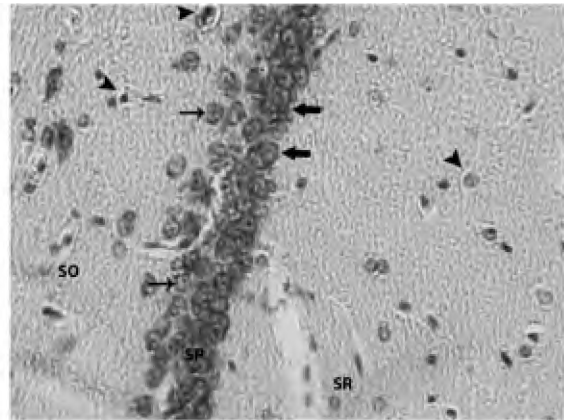


Fig. (16): A photomicrograph of a section in the hippocampus of twenty one days old treated rats showing stratum pyramidale (SP) of CA1 subfield containing some mature neurons with round vesicular nuclei (thin arrows) and some darkly stained immature neurons with irregular nuclei (thick arrows). Few astrocytes (arrow heads) are observed in stratum oriens (SO) and stratum radiatum (SR). (Galloyanine chrom-alum x400).

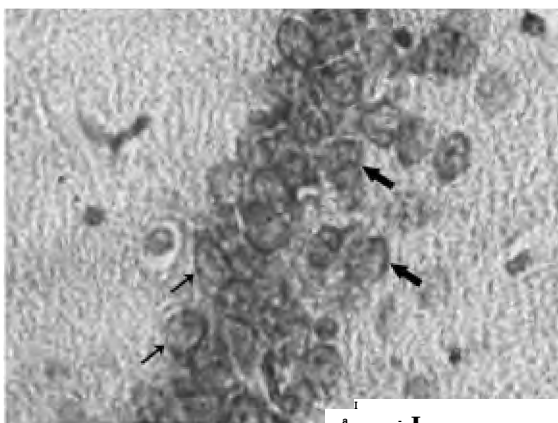


Fig. (17): A photomicrograph of a section in the hippocampus of twenty one days old treated rats showing stratum pyramidale of CA1 subfield containing some mature neurons with round vesicular nuclei (thin arrows) and multiple darkly stained immature neurons with irregular nuclei (thick arrows). (Galloyanine chrom-alum x1000).

Discussion

Thyroid hormones exert a critical action on brain development in man and other mammals by regulation of the concentration of the active hormone, T3, and the control of gene expression. Most brain T3 is formed locally from its precursor, T4, by the action of type II deiodinase which is expressed in glial cells, tanycytes, and astrocytes. These hormones accelerate changes of gene expression that take place during development [17]. This action is necessary for normal cytoskeletal system and consequently is essential for migration and neuronal outgrowth. So, normal levels of thyroid hormones are essential for normal human brain development during a critical period beginning in utero and extending through the first 2

years postpartum [18]. And any decrease in thyroid hormones level may lead to the migration defects associated with neurological deficits in the human brain [19].

The rat brain was considered as the best animal model of thyroid hormone dependent brain development [14], especially the hippocampus as being a highly sensitive neural structure to the actions of thyroid hormones due to its high content of thyroid receptors as described by Marti-Carbonell [20].

Methimazole was used in the present study as it was stated that this drug is secreted in breast milk and its level was the same as in the serum [21], rendering neonatal rats hypothyroid [12].

In the present study, the hippocampus appeared with its three-layered structure similar to the same arrangement of the hippocampus seen in humans [22]. In one day old control rats, stratum pyramidale of CA1 of the hippocampus showed numerous mature neurons with underlying numerous migrating immature neurons. In seven days old control rats, stratum pyramidale of CA1 subfield showed compact layers of newly added mature neurons with overlying dispersed mature neurons. In fifteen days old control rats, stratum pyramidale of CA1 subfield showed compact layers of mature neurons with some underlying immature neurons. In twenty one days old control rats, stratum pyramidale of CA1 subfield showed multiple layers (4-5) of dispersed mature neurons with peripheral processes in addition to some immature neurons. This is in agreement with developmental description stated by Toni and Song [23,24].

In the treated group; stratum pyramidale of CA1 of the hippocampus of one day old rats displayed delayed maturation with numerous degenerating neurons. This finding is supported with Madeira who stated that hypothyroidism induced neuronal death in the hippocampal CA1 region [25]. Also, Gong have reported a decrease in cell survival in the dentate gyms, CA1 and CA3 after developmental hypothyroidism [26]. In the remaining age groups, there was delayed maturation with many immature neurons in stratum pyramidale and few astrocytes in stratum oriens and stratum radiatum. These findings were obvious in the last age group (21 days), stratum pyramidale appeared markedly thin (2-3 layers). All the previous structural changes were confirmed by statistical measurements that revealed significant reduction of the mean thickness of stratum pyramidale of CA1

subfield of the hippocampus in the treated group as compared to the control group in all the studied age groups. Also, there was a significant decrease of the volume proportion (Vv) of stratum pyramidale of CA1 subfield of the hippocampus in treated groups as compared with control groups. These results are in agreement with Alva-Sanchez who stated that, the cells of dentate gyms project upon the dendrites of CA3 pyramidal cells. These cells contribute a major input system to CAL The author added that hypothyroidism reduces the density of pyramidal cells in the CA3 region and leads to a decrease in the total number of pyramidal cells in the CA1 region [27].

CA1 neurons are known to be particularly vulnerable to aggressive agents [28]. So, early thyroid hormone deficiency leads to impaired maturation of radial glial cells in the CA1 region of the hippocampus [29]. Thyroid gland disorders are one of the most common endocrine diseases. Any deficiency or increase of these hormones (hypo- or hyperthyroidism) during the developmental periods may result in an irreversible impairment, morphological and cytoarchitecture abnormalities. This includes abnormal neuronal proliferation, migration, decreased dendritic densities and dendritic arborizations. The sensitivity to the thyroid hormones is not only remarkable during the neonatal period but also prior to birth. These changes may lead to brain damage if not corrected shortly after birth [7].

On the contrary, Azizi and Amouzegar stated that methimazole doesn't cause any alterations in thyroid function and physical and mental development of infants breast-fed by lactating thyrotoxic mothers [13]. Histological changes detected in the present study could be attributed to the high sensitivity of the hippocampus to minimal decrease in thyroid hormones due to its high content of thyroid receptors as described by Marti-Carbonell [20].

Conclusion:

Hypothyroidism induced by methimazole intake during the developmental period of the brain markedly affects the post-natal development of the hippocampus through altering proliferation and migration of nerve cells. Although some authors stated that the drug can be used safely by the mothers during lactation, it should be used with precautions.

Conflicts of interest:

There is no conflict of interest to declare.

References

- 1- ANDERSEN P., SOLENG A.F. and RAASTAD M.: "The hippocampal lamella hypothesis revisited". *Brain Res.*, 886 (1-2): 165-171, 2000.
- 2- PYEON H.J. and LEE Y.I.: Differential expression levels of synaptophysin through developmental stages in hippocampal region of mouse brain. *Anat. Cell. Biol. Jun.*, 45 (2): 97-102, 2012.
- 3- UEMATSU A., MATSUI M., TANAKA C., TAKAHASHI T., NOGUCHI K., SUZUKI M. and NISHIJO H.: Developmental Trajectories of Amygdala and Hippocampus from Infancy to Early Adulthood in Healthy Individuals. *PLoS One*, 7 (10): e46970, 2012.
- 4- CARLA M.L., KENNETH A.P., RAMESH C., TOSHIKI N., KATALIN T., SUSUMU T. and CHRIS J.M.: Competition from newborn granule cells does not drive axonal retraction from silenced old granule cells in the adult hippocampus. *Frontiers in Neural Circuits*. November, Volume 6, Article, 85, 2012.
- 5- HYUN J.K. and WOONG S.: Adult Neurogenesis in the Central and Peripheral Nervous Systems. *Int. Neurology J.*, 16: 57-61, 2012.
- 6- AUSO E., LAVADO-AUTRIC R., CUEVAS E., DEL REY F.E., MORREALE DE ESCOBAR G. and BERBEL P.: A moderate and transient deficiency of maternal thyroid function at the beginning of fetal neocortico-genesis alters neuronal migration. *Endocrinology*, 145: 4037-4047, 2004.
- 7- OSAMA M.A., EL-GAREIB A.W., EL-BAKRY A.M., ABD EL-TAWAB S.M. and AHMED R.G.: Thyroid hormones states and brain development interactions. Review, *Int. J. Devl. Neuroscience*, 26: 147-209, 2008.
- 8- ANDERSON G.W.: Thyroid hormones and the brain. *Front. Neuroendocrinol.*, 22: 1-17, 2001.
- 9- GILBERT M.E., ROVET J., CHEN Z. and KOIBUCHI N.: Developmental thyroid hormone disruption: Prevalence, environmental contaminants and neurodevelopmental consequences. *Neurotoxicology*. Aug., 33 (4): 842-52, 2012.
- 10- ZHANG L., TENG W., LIU Y., LI J., MAO J., FAN C., WANG H., ZHANG H. and SHAN Z.: Effect of maternal excessive iodine intake on neurodevelopment and cognitive function in rat offspring. *BMC Neurosci.*, 13: 121, 2012.
- 11- DARBRA S., GARAU A., BALADA F., SALA J. and MARTI-CARBONELL M.A.: Perinatal hypothyroidism effects on neuromotor competence, novelty-directed exploratory and anxiety-related behaviour and learning in rats. *Behav. Brain Res.*, 143: 209-215, 2003.
- 12- MOOKADAM M., LESKE D.A., FAUTSCH M.P., LAMER W.L. and HOLMES J.M.: The anti-thyroid drug methimazole induces neovascularization in the neonatal rat analogous to ROP. *Invest. Ophthalmol. Vis. Sci.*, 45: 4145-4150, 2004.
- 13- AZIZI F. and AMOUZEGAR A.: Management of hyperthyroidism during pregnancy and lactation. *Eur. J. Endocrinol.* June, 1 (164): 871-876, 2011.
- 14- SCHWARTZ H.L., ROSS M. and OPPENHEIMER J.H.: Lack of effects of thyroid hormone on late fetal rat brain development. *Endocrinology*, 138: 3119-3124, 1997.
- 15- DRURY A.A. and WALLINGTON E.A.: Carleton's histological technique. 5th Ed., Oxford University press, New York, Toronto, 1980.
- 16- WEIBEL E.R.: Stereological principles for morphometry in electron microscopic cytology. *Int. Rev. Cytol.*, 26: 235-302, 1969.
- 17- BERNAL J.: Action of thyroid hormone in brain. *J. Endocrinol. Invest. Mar.*, 25 (3): 268-88, 2002.
- 18- PORTERFIELD S.P.: Thyroidal dysfunction and environmental chemicals potential impact on brain development. *Environ. Health Perspect*, 108 (Suppl. 3), 433-438, 2000.
- 19- SUN X.Z., TAKAHASHI S., CUI C., ZHANG R., SAKATA-HAGA H., SAWADA K. and FUKUI Y.: Normal and abnormal neuronal migration in the developing cerebral cortex. *J. Med. Invest.*, 49: 97-110, 2002.
- 20- MARTI-CARBONELL M.A., GARAU A., SALA-ROCA J. and BALADA F.: Effects of adult dysthyroidism on the morphology of hippocampal granular cells in rats. *Acta, Neurobiol. Exp. (Wars)*, 72 (3): 230-9, 2012.
- 21- JOHANSEN K., ANDERSEN A.N., KAMPMANN J.P., MOLHOLM HANSEN J.M. and MORTENSEN H.B.: Excretion of methimazole in human milk. *Eur. J. Clin. Pharmacol.* Oct., 23 (4): 339-41, 1982.
- 22- STANDRING S., ELLIS H., HEALY J.C., JOHNSON D. and WILLIAMS A.: The anatomical basis of clinical practice. 39th ed. Elsevier Churchill Livingstone, Toronto, 2005.
- 23- TOM N' LAPLAGNE D.A., ZHAO C., LOMBARDI G., RIBAK C.E., GAGE F.H., et al., Neurons born in the adult dentate gyrus form functional synapses with target cells. *Nat. Neurosci.*, 11: 901-7, 2008.
- 24- SONG HJ' STEVENS C.F. and GAGE F.H.: Neural stem cells from adult hippocampus develop essential properties of functional CNS neurons. *Nat. Neurosci.*, 5: 438-45, 2002.
- 25- MADEIRA M.D., SOUSA N. and PAULA-BARBOSA M.M.: Sexual dimorphism in the mossy fiber synapses of the rat hippocampus. *Exp. Brain Res.*, 87: 537-545, 1991a.
- 26- GONG J., DONG J., WANG Y., XU H., WEI W., ZHONG J., LIU W., XI Q. and CHEN J.: Developmental iodine deficiency and hypothyroidism impair neural development, up-regulate caveolin-1 and down-regulate synaptophysin in rat hippocampus. *J. Neuroendocrinol.*, 22: 129-139, 2010.
- 27- ALVA-SANCHEZ C., ORTIZ-BUTRON R. and PACHECO-ROSADO J.: Kainic acid does not affect CA3 hippocampal region pyramidal cells in hypothyroid rats. *Brain Res. Bull.*, 63: 167-171, 2004.
- 28- MADEIRA M.D., SOUSA N., LIMA-ANDRADE M.T., CALHEIROS F., CADETE-LEITE A. and PAULA-BARBOSA M.M.: Selective vulnerability of the hippocampal pyramidal neurons to hypothyroidism in male and female rats. *J. Comp. Neurol.*, 322: 501-518, 1992.
- 29- MARTINEZ-GALAN J., PEDRAZA P., SANTACANA M., ESCOBAR DEL REY F., MORREALE DE ESCOBAR G. and RUIZ-MARCOS A.: Early effects of iodine deficiency on radial glial cells of the hippocampus of the rat fetus; A model of neurological cretinism. *J. Clin. Invest.*, 99: 2701-2709, 1997.