
STRUCTURE AND FUNCTIONAL SIGNIFICANCE OF BRANCHED ANASTOMOSING MUCOSAL FOLDS IN THE PROXIMAL INTESTINE OF THE FARMED AFRICAN CATFISH (*Clarias gariepinus* BURCHELL 1822)

IKPEGBU, Ekele, NLEBEDUM, Uchenna Calistus, NNADOZIE, Okechukwu and AGBAKWURU, Isaiah Okezie

Department of Veterinary Anatomy, Michael Okpara University of Agriculture, Umudike, Abia State, Nigeria.

Corresponding Author: Ikpegbu, E. Department of Veterinary Anatomy, Michael Okpara University of Agriculture, Umudike, Abia State, Nigeria. **Email:** fikpegbu@yahoo.com **Phone:** +234 8060775754

ABSTRACT

Histology has provided morphologist a powerful tool that enhances the nature, form and detailed structure of organs. The proximal intestine though a more muscular tube than the rest of the intestine presented a complex anastomosing mucosal fold resembling a honey comb-like structure. This specialization was not seen in the other intestinal segments. This specialization increases the surface area for nutrient absorption. This probably compensates for shortness of intestine and absence of pyloric caeca in this species. The glycoconjugates in the goblet cell of proximal intestine mucosal fold were subjected to mucin histochemical study. The study revealed the presence of neutral and acid mucin but acid mucin was predominant. The neutral mucin can be associated to buffering the effect of gastric acid, transport of small disaccharide molecules. The predominating acid mucin suggest air-breathing function since the acid will always make the epithelium moist for gaseous exchange between dissolved air in swallowed water and abundant blood vessels present in the tunica mucosa.

Keywords: Nutrient absorption, Proximal intestine, Anastomosing mucosal folds, Histology, Histochemistry, *Clarias gariepinus*

INTRODUCTION

Structure and functional morphology of the alimentary tract has been of interest in the adaptation of teleosts to food and feeding habits. A correlation between the structure of the alimentary canal and relative intestinal length with the feeding habits of teleosts has been studied (Al-Hussaini, 1949; Kramer and Bryant, 1995). They stated that herbivorous fishes have the longest relative intestinal length (RIL), while carnivores have the least. Omnivores have values in between the two. The herbivorous high RIL is adaptations to enable the fish sift through the high content of

indigestible cellulose materials therein. Also studies have been done on several teleostean fish alimentary canal like the *Sparus aurata* (Catladi *et al.*, 1987); the stratum compactum of rainbow trout (*Salmo gairdneri*, Rich) gut (Ezeasor, 1986), but there is dearth of information on the functional morphology of the domesticated African catfish (*Clarias gariepinus*) alimentary canal. The histology of several teleosts digestive tracts have been documented and their functional morphology indicated that they were principally involved in food absorption and digestion (Chan *et al.*, 2004; Kozaric *et al.*, 2006; Monsefi *et al.*, 2010). Some authors have reported adaptation to air breathing in the

digestive tract of some teleost (Huebner and Chee, 1978; McMahon and Burggren, 1987; Moitra *et al.*, 1989; Park and Kim, 2001; Podkowa and Goniakowska-Witanlinska, 2002) and correlated the cellular composition, architecture of the mucosa with the digestive and respiratory functions, especially the presence of high vascularization of the mucosal fold. The result of this study will provide more understanding on the adaptation of *Clarias gariepinus* to concreted pond environment where dissolved oxygen is usually limited due to overstocking. The knowledge obtained will fill the gap, as there is dearth of information on the adaptation of the African catfish to intensive domestication in the tropics. This knowledge is important to explain their survival in stagnant water resource with a reduction in dissolved oxygen, making the gills inefficient to perform aquatic respiration (Park *et al.*, 2003). Hence, the aim of this study is to histologically and histochemically examine the proximal intestine and mucin of *C. gariepinus*, which grossly in some teleost is the site of pyloric caeca attachment (Hamlin *et al.*, 2000; Mazlan and Grove, 2002; Sanz *et al.*, 2011).

MATERIALS AND METHODS

Fifteen adult African catfish (mean weighed of 900 ± 20.25 g, mean standard body length of 45.00 ± 1.20 cm and mean intestinal length of 35.4 ± 1.35 cm) sourced from a commercial aquaculture farm in Umuahia, Abia State, Nigeria were used for the study. The fish were immobilized in MS 222 and the body cavity cut open through the ventral surface to expose the viscera and the alimentary tract dissected out. The proximal segment of the intestine from the pyloric sphincter to about 5 cm caudally was histologically studied (Figure 1). It was excised and immediately fixed in 10% neutral buffered formalin. The tissue was dehydrated in graded ethanol, cleared in xylene, impregnated and embedded in paraffin wax and mounted for sectioning. Sections of $6\mu\text{m}$ thick were obtained with Leitz microtome model 1512. Sections were differentially stained with Haematoxylin and Eosin for light microscopy examination (Bancroft and Stevens, 1977). Mucins were demonstrated

using Alcian blue (AB) at pH 2.5 (Lev and Spicer, 1964) and Periodic Acid Schiff (PAS) with and without prior digestion with diastase (Lillie and Greco, 1947; Ikpegbu *et al.*, 2011). In addition, combined AB and PAS procedure was employed for neutral and acid mucin (Bancroft and Stevens, 1977). Photomicrographs were taken using Motican 2001 camera (Motican UK) attached to Olympus microscope.

RESULTS

Grossly, the dissected proximal intestine was seen to have a mesh like or honey comb appearance (Figure 2). The histology under low magnification (x40), presented reticulated mucosal folds which formed labyrinths lined by villi (Figures 3 and 4). The reticulation involved primary, secondary and tertiary folds which branched and anastomosed, thus accounting for the gross honey-comb appearance of this region (Figures 3 and 4), thus reducing the size of the central lumen (Figure 5). All the folds were lined by a simple columnar absorptive epithelium that contained goblet cells and migratory leucocytes. The core of lamina propria contained loose collagen fibres, lymphocytes and numerous profiles of capillaries (Figures 6 and 7). Collagen fibres were contained in the submucosa. The tunica muscularis contained smooth muscle fibres arranged in inner circular and outer longitudinal layers. Tunica serosa was observed with subserosal vascularization.

Mucin histochemistry revealed that the goblet cells were PAS positive but their magenta colour was not intense (Figure 8). After diastase pretreatment the goblet cells were PAS positive also. On subjecting the sections to AB stain the goblets were AB positive (Figure 9). The sections were subjected to combined AB and PAS procedure after diastase pre-treatment, the goblet cells were mostly bluish indicating AB dominance (Figure 10).

DISCUSSION

The branched anastomosing mucosal fold seen in this region of the intestine is an adaptation to short relative intestinal length.

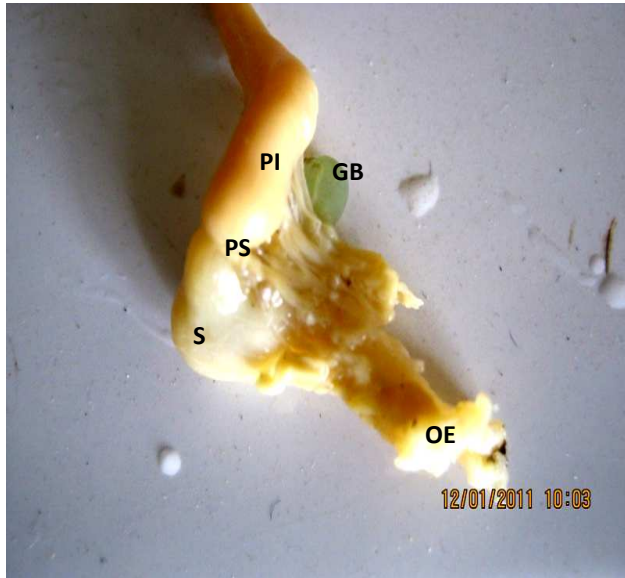


Figure 1: Topographic dissected section of adult digestive tract showing oesophagus (OE), stomach (s), pyloric shincter (PS), proximal intestine (PI), and gall bladder (GB). x10

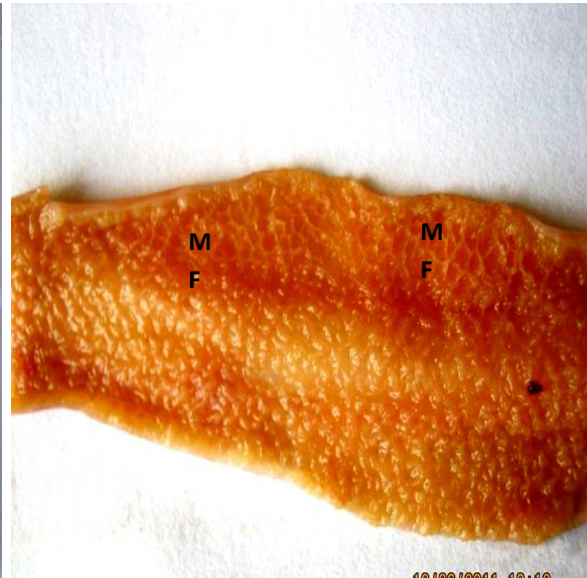


Figure 2: Dissected section of adult proximal intestine showing mucosal folds (MF) with honey comb-like appearance. x10

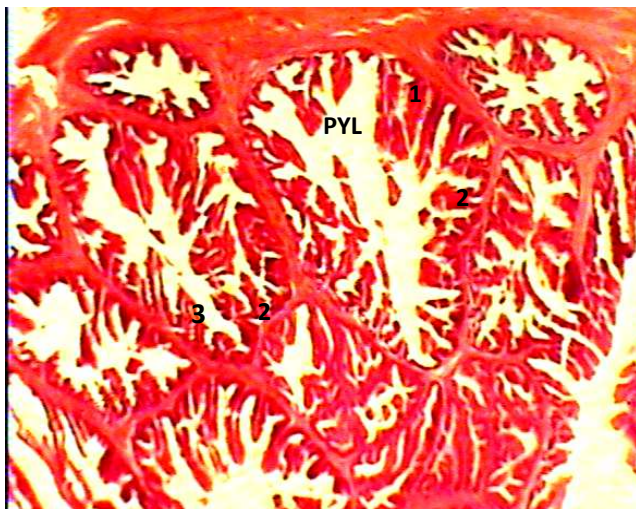


Figure 3: Transverse section of adult proximal intestine showing anastomosing branched mucosal fold resembling a honey comb- like structure. The primary folds (1) unite to form basal lumina (PYL), and secondary folds (2), which give off the tertiary folds (3). H & E x40

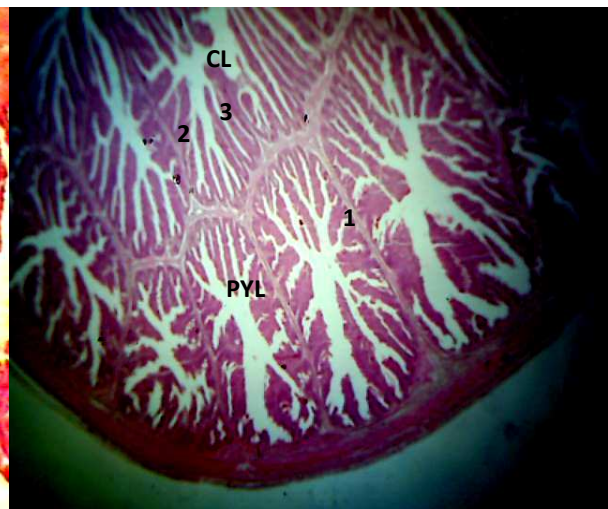


Figure 4: Transverse section of adult proximal intestine showing anastomosing branched mucosal fold resembling a honey comb like structure. The primary folds (1) unite to form basal lumina (PYL), and secondary folds (2), which give off the tertiary folds (3) that enters the central lumen (CL). H & E x40

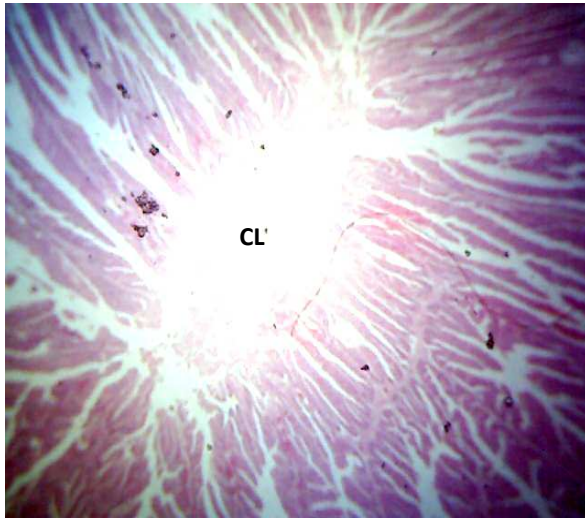


Figure 5: Transverse section of adult anterior intestine showing very narrow central intestinal lumen (CL) due to extensive branching of mucosal folds into the lumen. H & E x400

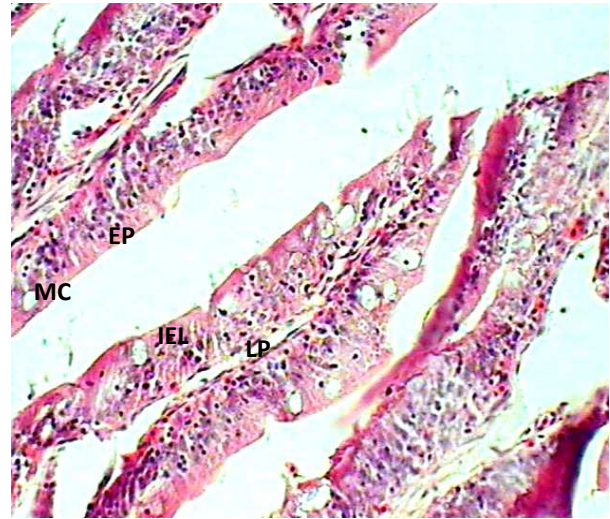


Figure 6: Section of anterior adult intestine showing goblet cell (GC), epithelium (EP), intraepithelial lymphocytes (IEL) and lamina propria (LP). H & E x400

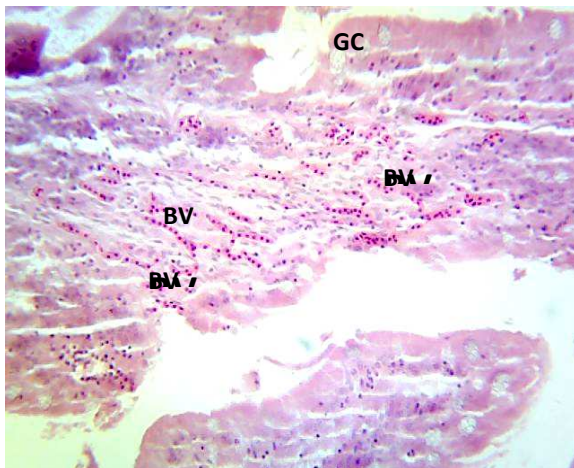


Figure 7: Transverse section of adult proximal intestine showing abundant mucosal vascularization (BV). Note the presence of goblet cells (GC). H & E x400

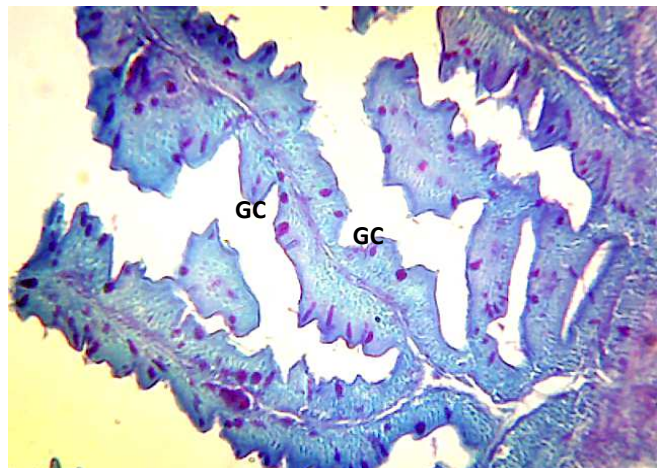


Figure 8: Transverse section of adult proximal intestine showing PAS positive goblet cells (GC). PAS x400

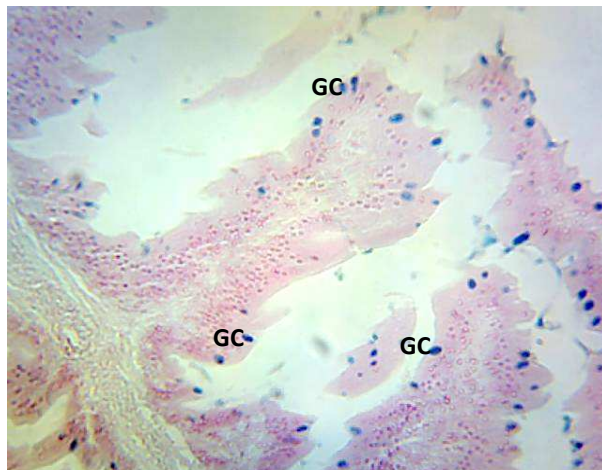


Figure 9: Transverse section of adult proximal intestine showing AB positive goblet cells (GC). AB x400

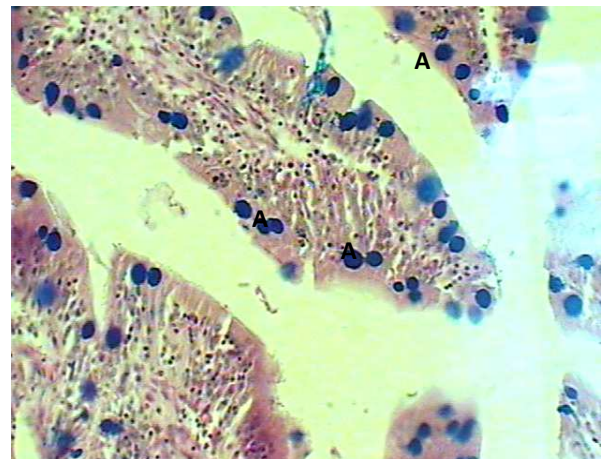


Figure 10: Transverse section of adult anterior intestine showing goblet cells that contained predominant acid mucin (A). AB/PAS x400

This specialization increases the surface area for nutrient absorption, and agrees with Al-Hussaini (1949), that shortness of the intestine may be compensated for by increase in mucosal folding complexity. This specialization is also a compensation for the absence of pyloric caeca which increases effective absorptive area of proximal intestine (Evans, 1998). The pyloric caeca and proximal intestine are structurally similar and have the same function in digestion (Catledi *et al.*, 1987). Hence the complex mucosal folds like the pyloric caeca strengthen the intestinal function in a limited space of the abdominal cavity without increasing the intestinal length (Buddington and Diamond, 1987; Bisbal and Bengtson, 1995; Baglole *et al.*, 1997). It has been reported that the complex folding of intestinal mucosa with resultant increase in surface area aids in the mixing of food with hepatic and pancreatic digestive juices as well as with mucus secreted by goblet cells (Grau *et al.*, 1992). The absence of pyloric caeca have also been reported in the walking catfish (*Clarias batrachus*) (Raji and Norouzi, 2010).

The goblet cells produce mucin which protects the epithelium from pathogen attack; (Neuhaus *et al.*, 2007) helps in absorption of easily digestive substances such as disaccharides and short-chain fatty acids (Elbal

et al., 2004), they also protect the epithelium from abrasion that nutritive particles produce (Elbal and Agulleiro, 1986). The lymphocytes are for immunologic defence (Abelli *et al.*, 1997; Monsedi *et al.*, 2010). The dense collagen fibres in the lamina propria-submucosa and the thick tunica muscularis strengthen and support the gut wall in the absence of a well developed stratum compactum (Burnstock, 1959; Ezeasor, 1986). The high vascularization seen in various layers of the wall especially the subserosal capillaries can be attributed to the high motility that necessitated high metabolic requirement (Singh, 2006). The high vascularization of the lamina propria facilitates the absorptive power of the mucosal folds (Cao and Wang, 2009).

The PAS positive result, after diastase treatment indicates the presence of neutral mucin. Neutral mucin has been associated with transport of small molecules, buffering the effect of stomach acid content (Kozaric *et al.*, 2008; Cao and Wang, 2009). The numerous mucosal blood vessels indicate respiratory function (Ghosh *et al.*, 2011). The AB positive result indicated the presence of acid mucin. The mucin secreted by the goblet cell that is predominantly acidic suggests a respiratory function for the proximal intestine since the acid will make the mucosal surface moist, hence facilitating gaseous exchange between the blood

in the abundant capillary bed and swallowed air (Singh *et al.*, 1974; Moitra *et al.*, 1989). The abundance of goblet cells producing mucin will help clear and protect delicate respiratory epithelium from mechanical abrasion (Moitra *et al.*, 1989; Ghosh *et al.*, 2011).

Also according to Banan-Khojasteh *et al.* (2009), the quality of gut mucosubstances is directly related to environmental condition which in turn may directly affect the function of the alimentary tract. Also considering the fact that the species is farmed intensively in concrete pond where they are over crowded due to overstocking with consequent competition for the limited dissolved oxygen. Park *et al.* (2003) suggested that the presence of numerous mucosal blood vessels and predominating acid mucin is an adaptation for respiratory function by the digestive tract in teleosts. The probability of an air breathing adult proximal intestine may explain the tolerance of farmed African catfish to low dissolved oxygen as observed by Micha (1973).

ACKNOWLEDGEMENT

We are grateful to the management and staff of Yuep Farms, Umuahia, Abia State, South East Nigeria for supplying the fish used for the research.

REFERENCES

- ABELLI, L., PICCIETTI, S., ROMANO, N., MASTRELIA, G. and SCAPIGLIATI, G. (1997). Immunohistochemistry of gut-associated lymphoid tissue of the sea bass *Dicentrarchus labrax* L. *Fish and Shellfish Immunology*, 7(4): 235 – 245.
- AL-HUSSAINI, A. H. (1949). On the functional morphology of the alimentary tract of some fish in relation to differences in their feeding habits: Anatomy and histology. *Quarterly Journal Microscopical Science*, 90(2): 109 – 138.
- BAGLOLE, C. J., MURRAY, H. M., GOFF, G. P. and WRIGHT, G. M. (1997). Ontogeny of the digestive tract during larval development of yellow flounder: a light microscopic and mucous histochemical study. *Journal of Fish Biology*, 51: 120 – 134.
- BANAN-KHAJASTEL, S. M., SHEIKHZADEL, F., MOHAMMADNEJAD, D. and AZANI, A. (2009). Histological, histochemical and ultrastructural study of the intestine of rainbow trout (*Oncorhynchus mykiss*). *World Applied Sciences Journal*, 6: 1525 – 1531.
- BANCROFT, J. D. and STEVENS, A. (1977). *Theory and Practice of Histological Techniques*. Churchill Livingstone, New York, USA.
- BISBAL, G. A. and BENGTON, D. A. (1995). Development of the digestive tract in larval summer flounder. *Journal of Fish Biology*, 47: 277 – 291.
- BUDDINGTON, R. K., and DIAMOND, J. M. (1987). Pyloric ceca of fish: a "new absorptive organ. *Am. J. physical*. 252, G. 65 – G76.
- BURNSTOCK, G. (1959). Morphology of the gut of the brown trout (*Salmo trutta*). *Quarterly Journal Microscopical Science*, 100: 183 – 198.
- CAO, X. J. and WANG, W. M. (2009). Histology and mucin histochemistry of the digestive tract of yellow catfish *Peltobagrus fulvidraco*. *Anatomy, Histology and Embryology*, 38: 254 – 261.
- CATLADI, E., CATAUDELLA, S., MONACO, G., ROSSI, A. and TANCIONI, L. (1987). A study of the histology and morphology of the digestive tract of the sea-bream, *Sparus aurata*. *Journal of Fish Biology*, 30: 135 – 145.
- CHAN, A. S., HORN, M. H., DICKSON, K. A. and GAWLICKA, A. (2004). Digestive enzyme activities in carnivores and herbivores: Comparisons among four closely related prickly back fishes (*Teleostei: Stichaeidae*) from a California Rocky intertidal habitat. *Journal of Fish Biology*, 65: 848 – 858.
- ELBAL, M. T. and AGULLEIRO, B. A. (1986). Histochemical and ultrastructural study of the gut *Mugil saliens* (teleost). *Acta Microscopica*, 9(1): 31 – 40.

- ELBAL, M. T., GARCIA HERNANDEZ, M. P., LOZANO, M. T. and AGULLEIRO, B. (2004). Development of the digestive tract of Gilthead Sea bream (*Sparus aurata* L.). Light and electron microscopic studies. *Aquaculture*, 234: 215 – 238.
- EVANS, D. N. (1998). *The Physiology of Fishes*. 2nd Edition, CRC Press, Boca Raton, USA.
- EZEASOR, D. N. (1986). The structure and functional significance of stratum compactum in the gut of the rainbow trout (*Salmo gairdneri*, Rich). *Zeitschrift fuer Mikroskopisch-Anatomische Forschung (Leipzig)*, 1004: 536 – 544.
- GHOSH, S.K., GHOSH, B. and CHAKRABARTI, P. (2011). Fine anatomical structures of the intestine in relation to respiratory function of an air-breathing loach, *Lepidocephalichthys guntea* (Actinopterygii: Cypriniformes: Cobitidae). *Acta Ichthyologica et Piscatoria*, 41: 1 – 5.
- GRAU, A., CRESPO, S., SARASQUELE, N. C., GONZALES, J. and CANALES, N. L. (1992). The digestive tract of the Amberjack, *Seriola dumexli*, Risso: A light and scanning electron microscope study. *Journal of Fish Biology*, 41: 387 – 390.
- HAMLIN, H. J., HUNT VON HERBING, I. and KWING, L. J. (2000). Histological and morphological evaluations of the digestive tract and associated organs of haddock throughout post-hatching ontogeny. *Journal of Fish Biology*, 57: 716 – 732.
- HUEBNER, E. and CHEE, G. (1978). Histological and ultrastructural specialization of the digestive tract of the intestinal air breather *Hoplosternum thoracatum* (teleost). *Journal of Morphology*, 157: 301 – 328.
- IKPEGBU, E., NLEBEDUM, U. C., NNADOZIE, O. and AGBAKWURU, I. (2011). Fast Green FCF or Ehrlich's haematoxylin as counter stain to periodic acid Schiff reaction: A comparative study. *Histologic Archives*, 54: 29 – 30.
- KOZARIC, Z., KUZIR, S., PETRINEC, Z., GJURCEVIC, E. and BOZIC, M. (2008). The development of the digestive tract in larval European catfish (*Silurus glanis* L.). *Anatomy, Histology and Embryology*, 37: 141 – 146.
- KOZARIC, Z., KUZIR, S., PETRINEC, Z., GJURCEVIC, E. and OPACAK, A. (2006). Histochemical distribution of digestive enzymes in intestine of goldline, *Sapa salpa* L. 1758. *Journal of Applied Ichthyology*, 22: 43 – 48.
- KRAMER, O. L. and BRYANT, M. J. (1995). Intestine length in the fishes of a tropical stream: 1. Ontogenetic allometry. *Environmental Biology of Fish*, 42: 115 – 127.
- LEV, R. and SPICER, S. S. (1964). Specific staining of sulphated groups with alcian blue at low pH. *Journal of Histochemistry and Cytochemistry*, 12: 309 – 310.
- LILLIE, R.D. and GRECO, J. (1947): Mact diastase ptyalin in place of saliva in the identification of glycogen. *Stain Technology*, 22: 67 – 70.
- MAZLAN, A. G. and GROVE, D. J. (2002). Gastric digestion and nutrient absorption along the alimentary tract of whiting (*Merlangius merlangus* L.) fed on natural prey. *Journal of Applied Ichthyology*, 19: 229 – 238.
- MCMAHON, B. R. and BURGGREN, W. W. (1987). Respiratory physiology of intestinal air breathing in the teleost fish *Misgurnus anguillicaudatus*. *Journal of Experimental Biology*, 133: 371 – 393.
- MICHA, J. C. (1973). Etude des populations piscicoles de l'Ubangui et tentatives de selection and D'adaptation de quelques especes a l'etang de pisciculture. C.T.F.T., Division de Recherches en Pisciculture, Paris, France.
- MOITRA, A., SINGH, O. N. and MUNSHI, J. S. D. (1989). Microanatomy and cytochemistry of the gastro-respiratory tract of an air-breathing cobitid fish *Lepidocephalichthys guntea*. *Japanese Journal of Ichthyology*, 36: 227 – 231.

- MONSEFI, M., GHOLAMI, Z. and ESMAEILI, H. (2010). Histological and morphological studies of digestive tube and liver of the Persian tooth-camp, *Aphanius persicus* (Actinoptergii: Cyprinodontidae). *IUFS Journal of Biology*, 69: 57 – 64.
- NEUHAUS, H., MAREL, M., CASPARI, N., MEYER, W., ENSS, M. L. and STEINHAYEN, D. (2007). Biochemical and histochemical study on the intestinal mucosa of the common carp *Cyprinus carpio* L. with special consideration of mucin glycoproteins. *Journal of Fish Biology*, 70: 1523 – 1534.
- PARK, J. Y. and KIM, I. S. (2001). Histology and mucin histochemistry of the gastro-intestinal tract of the mud loach, in relation to respiration. *Journal of Fish Biology*, 58: 861 – 872.
- PARK, J. Y., KIM, I. S. and KIM, S. Y. (2003). Structure and mucous histochemistry of the intestinal respiratory tract of the mud loach, *Misgurnus anguithicaudatus* (Cantor). *Journal of Applied Ichthyology*, 19: 215 – 219.
- PODKOWA, D. and GONIAKOWSKA-WITANLINSKA, L. (2002). Adaptations to air-breathing in the posterior intestine of the catfish (*Corydoras acneus*, Callichthyidae). A histological and ultrastructure study. *Folia Biology*, 50: 69 – 82.
- RAJI, A. R. and NOROUZI, E. (2010). Histological and histochemical study of the alimentary canal in Walking catfish (*Clarias batrachus*) and Piranha (*Serrasalmus nattereri*). *Iranian Journal of Veterinary Research, Shiraz University*, 11(3): 255 – 261.
- SANZ, A., LLORENTE, J. I., FURNE, M., OSTOS-GARRIDO, M. V., CARMONA, R., DOMEZAIN, A. and HIDALGO, M. C. (2011). Digestive enzymes during ontogeny of sturgeon *Acipenser naccarii*: intestine and pancreas development. *Journal of Applied Ichthyology*, 27(5): 1139 – 1146.
- SINGH, I. (2006). *Textbook of Human Histology*. 5th Edition, Jaypee Brothers Medical Publishers, India.
- SINGH, R. R., GUHA, G. and MUNSHI, J. S. D. (1974). Mucous cells of the respiratory sac in an air-breathing fish, *Saccobranchus fossilis* (Bloch). *La Cellule*, 70(1): 5 – 15.