

Detection of *Nocardia* from Chronic Skin and Lung Infections in Bangladeshi Patients

Afzalunnessa Binte Lutfor^{1,*}, Ritu Saha¹, Arpita Deb¹, Asif Mujtaba Mahmud², Abu Ahmed Ashraf Ali¹, Tasmin Haque¹, Sadia Rahman¹, Nadia Sharmin Shorno³, Amina Arafat¹

¹Department of Microbiology, Ad-din Women's Medical College Hospital, Dhaka, Bangladesh

²Department of Respiratory Medicine, Asgar Ali Hospital, Dhaka, Bangladesh

³Department of Critical care & Emergency Medicine, Dhaka Medical College Hospital, Dhaka, Bangladesh

*Corresponding author: lizablutfor@gmail.com

Abstract Nocardiosis is an acute or chronic infectious disease that may occur in cutaneous, pulmonary and disseminated form in both immunocompromised and immunocompetent host. It may become potentially severe due to delayed diagnosis and incomplete or ineffective treatment. So the aim of the study was to isolate *Nocardia* spp. from suspected samples, mainly from chronic unhealed wounds and to identify appropriate antimicrobials by susceptibility testing in Bangladeshi patients. **Methods:** From January 2015-2017, 62 samples were collected which were studied for Nocardial identification and susceptibility testing. **Results:** Out of total 62 cases, 18 (29.03%) cases were *Nocardia* positive cases. Besides 6 *Acinetobacter* spp. and 2 *Actinomyces* spp. with other varied pathogens were isolated. Among 18 identified nocardiosis patients, majority (10) were post surgery cases, 6 suspected skin and glandular tuberculosis (TB) cases, one had breast sinus, and one was suspected pulmonary TB case. In terms of susceptibility of nocardial isolates, 100% were susceptible to linezolid, 88.9% to amikacin and 78% to trimethoprim-sulphamethoxazole.

Keywords: chronic skin infection, discharging sinus, *Nocardia*, non healing wound, primary cutaneous nocardiosis

Cite This Article: Afzalunnessa Binte Lutfor, Ritu Saha, Arpita Deb, Asif Mujtaba Mahmud, Abu Ahmed Ashraf Ali, Tasmin Haque, Sadia Rahman, Nadia Sharmin Shorno, and Amina Arafat, "Detection of *Nocardia* from Chronic Skin and Lung Infections in Bangladeshi Patients." *American Journal of Infectious Diseases and Microbiology*, vol. 5, no. 2 (2017): 80-86. doi: 10.12691/ajidm-5-2-2.

1. Introduction

Nocardia is a Gram positive filamentous bacillus which can cause multiple illnesses that includes primary cutaneous and pulmonary nocardiosis among immune compromised and competent host [1]. It is available in fresh or salt water, soil, decomposing vegetation and other organic matter [2]. These bacteria unlike others, require extended culture and need a special approach to identify and confirm the isolate. A sensitive drug is to be given for 3 to 6 months or more [3,4,5,6]. It usually occurs as an infection among the immunocompromised patients with transplantation, HIV, cancer or patients having steroids for long time [3,7].

Cutaneous nocardiosis (CN) in healthy immunocompetent individual is not uncommon [8]. It is an important disease in tropical areas which should not just be considered as an opportunistic infection, as many immunocompetent patients were affected as well and major surgical wounds or traumatic inoculation are thought to be the pathway [9,10,11,12]. Primary cutaneous (PCN) may lead to acute, sub acute, chronic lesions, usually manifesting with single or multiple erythematous non tender swelling at the site which later

drains purulent or serous discharge [13]. Discharge from draining sinuses that has deep pockets inside is highly suspicious of nocardial infections [10,14]. Occurrence of PCN has been found to range between 5% to 24% in countries like India, UK and Spain [9,15,16,17]. *Nocardia* skin infections have also been found as non healing infections not improving with antibiotics [15,18].

Traditionally, there are three kinds of primary cutaneous nocardiosis (PCN), 1) a superficial acute skin and soft tissue infection, 2) a lymphocutaneous infection and 3) a deeper infection, mycetoma [15,18]. A distinct 4th kind secondary skin infection has been documented occurring from disseminated pulmonary disease [9,19].

Nocardia may also colonize the respiratory tract of immunocompetent people having compromised lung structure as in cystic fibrosis and bronchiectasis [4]. Nocardial pneumonia may occur which can also disseminate to other organs including brain [13,20,21]. Pleuropulmonary nocardiosis is thought to arise from inhalation exposure and disseminated nocardiosis by hematogenous route, usually from a pulmonary focus [9,13].

Nocardiosis can be caused by 10 different species or more, with *N. asteroides*, *N. brasiliensis* and *N. caviae* being more common among human diseases [22]. With appropriate treatment for 3 months to 1 year, *Nocardia*

cure rate may reach 100% if the infections remain within skin and subcutaneous tissue, and 90% for pleuropulmonary with overall recovery rate 89%. In disseminated cases, mortality may reach 66% inspite of treatment [22,23].

Till date, the occurrence of Nocardia in Bangladesh has not been determined. This may attributable to the fact that majority of nocardial infection go unsuspected by clinicians owing to nonspecific clinical picture. Furthermore, patients with skin and soft tissue infections may demonstrate granuloma on histopathology, for which clinicians initiate treatment of tuberculosis (TB). On the diagnostic side, microbiologists miss the organism since extended culture may cause contaminant growth masking the desired colonies or poor yield due to prolong intake of antibiotic/anti tubercular drugs.

The objective of this study was to identify Nocardia spp. from samples of clinically challenging cases through implementation of available microbiological procedure. The antibiotic susceptibility pattern was also observed in order to treat the patients with appropriate antibiotics.

2. Methods

2.1. Patients

Patients were referred to the Microbiology Department, Ad-din Women's Medical College Hospital (AWMCH), by surgical or medicine specialists from different districts of Bangladesh with request for identification of filamentous bacteria or Nocardia/Actinomyces.

Most of them had history of one or more discharging sinus, at or around the primary site of infection for more than 2 months. All had received antibiotics or anti tubercular drugs without satisfactory improvement. Detailed history was taken from all patients who fulfilled following criteria:

- visible discharge at the site of the wound/ infection
- no cleaning or dressing of the wound done within previous 24 hours
- intake of antibiotic or anti tubercular drugs stopped for at least three days.

2.2. Sample collection

Study period: January 2015 to January 2017.

For sample collection, lying position was chosen and after thorough proper antisepsis four samples were taken from the wound or discharging sinuses. In case of pneumonia properly expectorated sputum was accepted.

Procedure: The first two samples were used to prepare smear and staining of different types. Other samples were directly inoculated immediately onto two blood agar (BA) media, McConkey agar (MA) media, and Lowenstein Jensen (LJ) media. To avoid drying and contamination, BA and MA plates were wrapped in cellophane wrapper and kept in incubator at 37°C. Plates and McCartney bottles were kept 7 days before declaring negative and subcultures were done in growth positive cases.

2.3. Staining

For each sample many smears were made. Three types

of staining were performed. Gram staining, modified Ziehl Neelsen (ZN) staining with 3% H₂SO₄ and traditional ZN staining were done, remaining smeared and fixed slides were preserved with proper recording of patients.

Findings: On Gram staining, Nocardia spp. was suspected when Gram positive long thin, filamentous, or pleomorphic branching bacilli are seen with the pus cells [24,25,26]. Bacilli appearing Gram negative with such morphology is not excluded from the suspected group of Nocardia spp. as frequently they can become Gram negative due to variation in lipid content of the cell wall [27]. Modified ZN staining was done and presence of red colored thin and long branching bacilli along with pus cells was considered as Nocardia spp. (Figure 1). Traditional ZN staining was done to exclude presence of Mycobacterium tuberculosis (MTB) in the sample. Actinomyces spp. were suspected on the basis of Gram positive branching rod like filaments, non acid fast on modified ZN stain and no growth on aerobic culture.

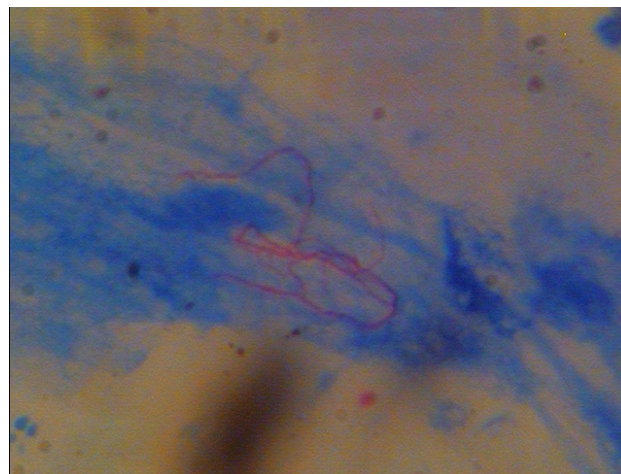


Figure 1. Nocardia spp. on Modified ZN stain from sputum

2. 4. Culture

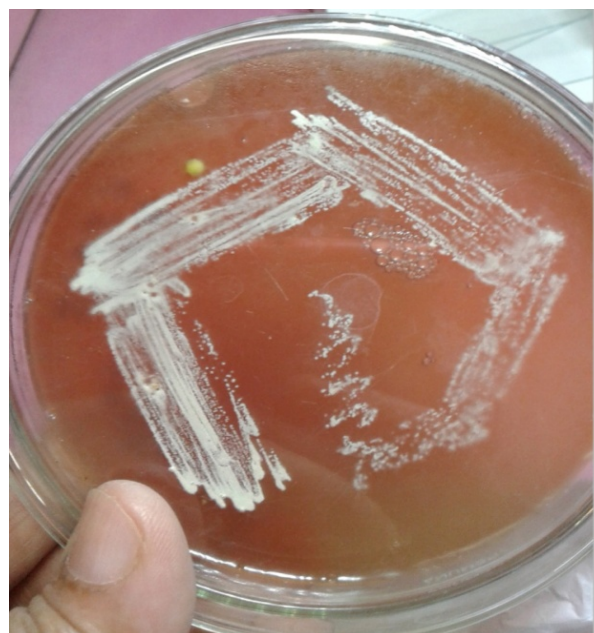

Figure 2a. Growth of Nocardia spp. on Blood Agar plate



Figure 2b. Growth of *Nocardia* spp. on L-J Media

Blood agar plates and LJ bottles were observed everyday for 7 days to see the growth of organisms. Growth of *Nocardia* was suspected when growth on BA/LJ media delayed 3 days or more and very tiny dry, rough or powdery white colony or moist yellowish colony appeared (Figure 2a & Figure 2b) [2,3,19]. Suspected colony was then stained with modified ZN and Gram staining to identify *Nocardia* spp. (Figure 3a & Figure 3b). Antibiotic susceptibility testing was done by disc diffusion technique and determined in accordance with guidelines provided by manufacturer and extrapolation of CLSI breakpoints [28]. Positive strains were preserved by sub culturing once in every month on BA plates. Growth of other organisms are identified according to growth on both BA and MA media, or single media, their morphology study, biochemical findings and susceptibility testing done for reporting within usual time period. *Nocardia* suspected cases needed seven days or more for reporting and plates/bottles were discarded after seven days in cases of contaminated or negative finding.

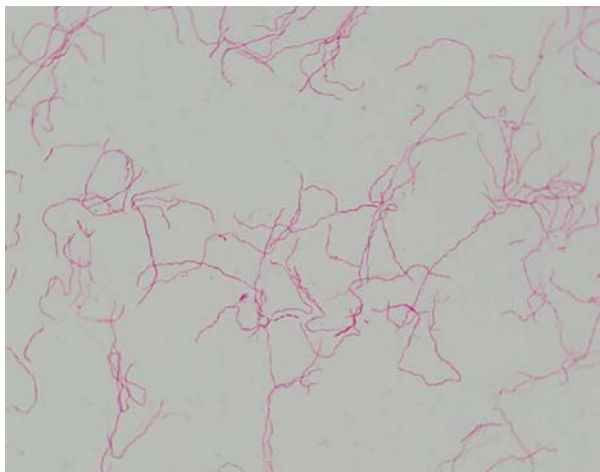


Figure 3a. *Nocardia* spp. (modified ZN) from BA plate

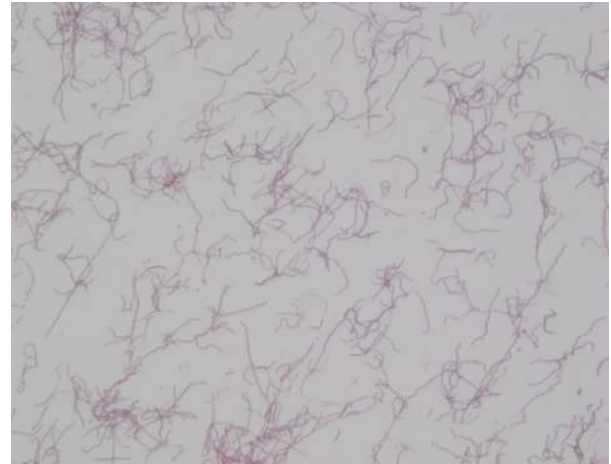

Figure 3b. *Nocardia* spp. (Gram stain) from BA plate

3. Results

Distribution of the patients according to their lesion illustrated in Figure 4. Majority of the patients came with post surgical wound (Figure 5a) infection (32, 51%) followed by suspected skin and glandular TB (16, 13%), breast sinus (5, 8%) and infection at other sites (8, 13%). Only 1 patient was a suspected pulmonary TB case.

A total 18 (29.03%) cases were diagnosed as *Nocardia* and 2 (11.11%) were identified as *Actinomyces* spp. Twenty three (37.1%) were growth positive for other organisms & 19 (30.6 %) were identified as no growth or non pathogens (Table 1).

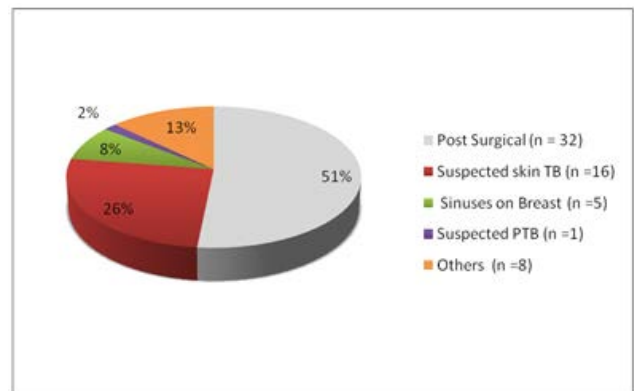


Figure 4. Distribution of patients according to their lesions

Table 1. Distribution of Pathogens From The Samples Received

Distribution of pathogens	Number	Percentage
<i>Nocardia</i> spp.	18	29.03
<i>Actinomyces</i> spp.	2	11.11
Other microorganism	23	37.1
No growth or non pathogens	19	30.64
Total	62	100

Distribution of organisms other than *Nocardia* has been tabulated in Table 2. Of these 23 isolates, 6 (23%) were diagnosed as *Acinetobacter* spp. Equal number (3/23) of Coagulase negative *Staphylococcus* and *Staphylococcus aureus* (13%) have been isolated from culture.

Table 2. Distribution of the Isolated Pathogenic Bacteria Other than Nocardia spp. and Actinomyces Spp.

Name of bacteria	Number	Percentage
Acinetobacter spp.	6	26
Coagulase negative Staphylococcus	3	13
Staphylococcus aureus	3	13
Diphtheroid	2	9
Moraxella	2	9
Klebsiella spp.	2	9
Micrococcus	2	9
Enterobacter	2	9
Pseudomonas spp.	1	4
Total	23	100

Table 3 shows particulars of the patients with nocardiosis (18 cases). No specific age patterns were seen among patients having nocardiosis. Most of the patients

were in the third decade. Majority of the patients were female and came from district or rural area of Bangladesh. Half of them (patient ID no 1-9) had post surgical abdominal wound and 1 had post orthopedic surgery wound (ID no 10). Six of them were suspected skin and glandular TB cases (ID11-16).

Only one was a suspected pulmonary TB case and one had discharging breast sinus (Table 3).

Drug susceptibility of Nocardia isolates are shown in Table 4. All strains were susceptible to linezolid (100%) with 88.9% to amikacin. Almost 78% were susceptible to trimethoprim-sulphamethoxazole, with 72.2% doxycyclin and 61.1% colistin respectively. Resistance was highest to azithromycin (88.9%) followed by cefipime (88.3%).

Table 3. Particulars of the Growth Positive Nocardiosis Cases

Patients ID	Age (Years)	Sex	Address (Came from)	Duration of complain	Wound Site & complains	History of taking anti tubercular drugs	Sample
1	26	Female	Kushtia	6 months	Discharge from post operative wound after LUCS	No	Wound swab
2	28	Female	Jessore	4 months	Discharge from post operative wound after LUCS	No	Wound swab
3	25	Female	Gendaria	9 months	Discharge from post operative wound after LUCS	No	Wound swab
4	56	Female	Dhaka	3 months	Discharge from post operative wound after LUCS	No	Wound swab
5	36	Female	Kushtia	8 months	Discharge from post operative wound after LUCS	No	Wound Swab
6	27	Female	Cox's Bazar	6 months	Discharge from post operative wound after LUCS	No	Pus
7	32	Female	Jessore	8 month	Discharge from post operative wound after LUCS	No	Wound swab
8	47	Female	Madaripur	3 month	Discharge from post operative wound after hysterectomy	No	Wound swab
9	35	Female	Kushtia	3 months	Post herniorrhaphy wound in lower abdomen	No	Pus
10	27	Male	Jessore	9 months	Discharge from post operative wound in leg	No	Wound swab
11	22	Female	Noakhali	6 months	Suspected tubercular discharging sinuses on breast	Yes	Pus
12	30	Female	Jessore	6 months	Discharging sinus on chest and back (suspected skin TB)	Yes	Wound swab
13	35	Female	Dhaka	3 months	Suspected skin TB	Yes	Wound Swab
14	23	Female	Faridpur	1 year	Suspected skin TB	Yes	Pus
15	16	Female	Dhaka	3 months	Discharging sinus on cervical lymph node (Suspected TB)	Yes	Wound Swab
16	12	Female	Meherpur	1 year	Discharge from suspected tubercular lymph node	Yes	Pus
17	27	Male	Khulna	1 year (Suspected pulmonary TB)	Chronic cough	Yes	Sputum
18	34	Female	Sutrapur	2 months	Discharge from sinuses in breast	No	Pus

Table 4. Antibiotic Susceptibility Pattern of Nocardia spp. (N=18)

Name of antibiotics	Number of sensitive strains	Percentages	No of Resistant cases	Percentages
Linezolid	18	100	0	0
Amikacin	16	88.9	2	11.1
Cotrimoxazole	14	77.8	4	22.2
Doxycycline	13	72.2	5	27.8
Colistin	11	61.1	7	38.9
Gentamycin	10	55.6	8	44.4
Ciprofloxacin	10	55.6	8	44.4
Levofloxacin	10	55.6	8	44.4
Meropenem	6	33.3	12	66.7
Ceftriaxone	5	27.8	13	72.2
Amoxycylav	5	27.8	13	72.2
Erythromycin	4	22.2	14	77.8
Cefipime	3	16.7	15	83.3
Azithromycin	2	11.1	16	88.9

4. Discussion

This study represents clinical cases of nocardiosis, most of which are cutaneous nocardiosis (CN) at or around the post operative wound with a history of discharging sinus or non healing infective sites, which has become chronic for more than 2 months. Despite receiving antibiotic regimes for optimum duration the infection did not heal completely. Nocardiosis among post operative wound infections is well documented [9]. Some of our cases showed partial healing with appearance of cutaneous swelling from other site around the original wound or surgical site which ends up with discharging sinus (Figure 5a). Similar lesions were also observed in other studies [17,29].

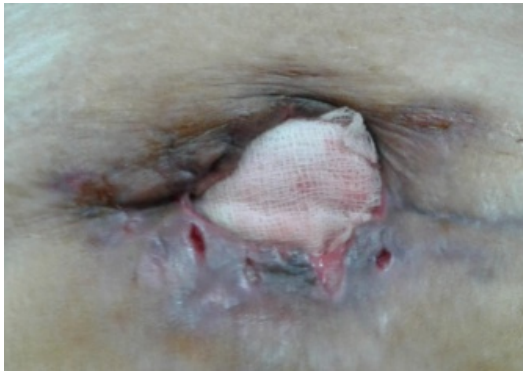

Figure 5a. Multiple discharging sinuses on each side of post herniorrhaphy wound

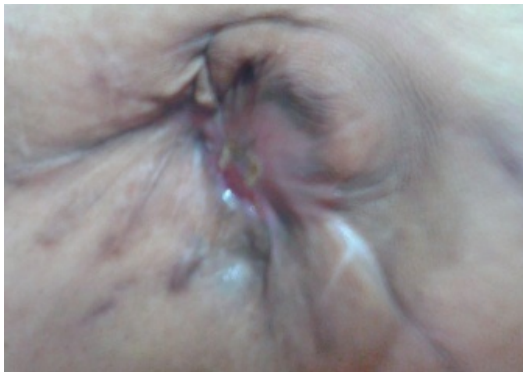

Figure 5b. Healed wound of the same patient showing puckered deep scar after treatment

A total of 62 patients were referred to this institute for ruling out of *Nocardia* or *Actinomyces* and for determination of antibiotic susceptibility of the causative agents. Among total samples, 18 (29%) were identified as *Nocardia* spp. in our study (Table 1). Similar finding (28.4%) and even more (48.4%) infections by *Nocardia* was found among healthy individuals in France and Queensland respectively [29,30]. Our patients were apparently healthy other than post operative wound infection and considered as immunocompetent. Many of them reported back after treatment (Figure 5b). Nocardiosis occurred in immunocompetent hosts following traumatic inoculation has been documented earlier [4]. A larger study reported 23 among 1000 nocardiosis cases who were apparently healthy and 643 cases had underlying predisposing factors or

immunosuppression. Incidence rate were found to be higher among organ transplanted and malignancy patients [12,29,31]. None of our patients had such history.

Among total 18 positive nocardia cases of our study, 17 were diagnosed as primary cutaneous nocardiosis (PCN) and only one case was pulmonary nocardiosis (Table 3). Out of 17 PCN cases, 9 had chronic wound infection at or around post abdominal surgery, of which 7 were post LUCS (lower uterine caesarean section) cases. This probably reflects the presently increasing trend of caesarean section operations in comparison to normal vaginal delivery. Many of our cases were from district or rural area where compromised infection control procedures, lack of skilled allied health professionals, usage of contaminated water, can be considered as factors responsible for infection. Infection at site of surgery is being increasingly reported [2,18]. Moreover, nocardiosis (27.6%) were diagnosed from wound infections in a larger 10 year study [3].

Among PCN cases, 6 patients were suspected for tuberculosis (2 gland TB, 3 skin TB and 1 breast sinus) on the basis of finding on histopathology report and were having anti tubercular drugs, but diagnosed finally as nocardiosis (Table 3). Some authors found that *Nocardia* induced granulomatous response has strong similarity with MTB with multinucleated giant cells except that epithelioid cells are not found in nocardiosis [32,33]. In our study, TB and *Nocardia* could not be demonstrated as co-existence or as predisposing factor of one another but co infections has been observed in other study [12].

Only one case of pulmonary nocardiosis was identified in our study (Table 3). Pulmonary nocardiosis is frequently found in immunocompromised patients [3]. Our patients were apparently immunocompetent. Pulmonary nocardiosis can also be misdiagnosed as tuberculosis, histoplasmosis, mycoplasmosis, actinomycosis or various forms of cancers [12].

Actinomyces spp. (Table 1) found in our study (two strains) were easily identified by their branching rod like filamentous morphology, negative modified ZN stain and no growth on aerobic culture. According to some authors, Gram stain is more sensitive method than culture for diagnosis of *Actinomyces* spp. [34].

In total six (29%) *Acinetobacter* spp. (Table 2) was identified here which deserves special mention since they were very confusing with their pleomorphic morphology (Figure 6). They were excluded from *Nocardia* group by their growth on McConkey agar plate and absence on modified ZN staining. Two of *Acinetobacter* strains were confirmed as *Acinetobacter* Iwoffii and *Acinetobacter* boumannii at an advanced laboratory in Dhaka, International Centre for Diarrhoeal Diseases Research Bangladesh (ICDDR) being identified by biochemical analyzer. *Acinetobacter* boumannii is considered to be an important cause of wound infection [35].

Acinetobacter Iwoffii usually considered as nonpathogens but has been found to cause wound infection. Some authors found that, surgical wound infections associated with *Acinetobacter* spp. constitutes 6.2%, of which *A. Iwoffii* contributes 2.8% [36].

Linezolid (Table 4) has been found to be 100% effective in *Nocardia* in our study as well as in other studies [3,4,6].

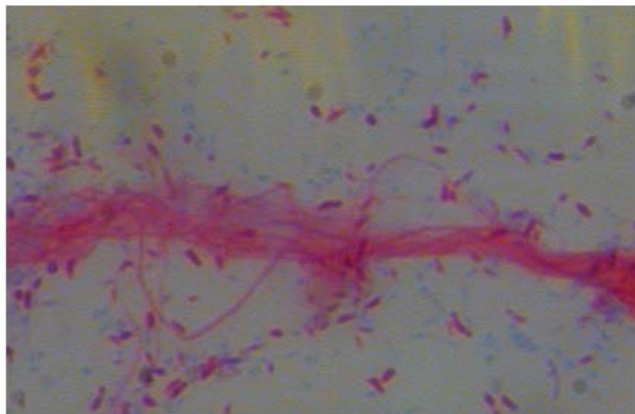


Figure 6. Coccobacillary form *Acinetobacter Iwoffii* (Gram stain from McConkey Agar plate)

Among the strains, 77.8% were susceptible to trimethoprim-sulphamethoxazole. Similar susceptibility pattern (76.8%) was observed in Pakistan [33] and only 2% resistance found in a multicenter survey on susceptibility testing by minimal inhibitory concentration (MIC) method [37]. On the contrary, 42% were susceptible among 765 *Nocardia* isolates in a 10 years study, by Udhe et al. at Centre for Disease Control (CDC), Atlanta [3].

In this study 88.9% (16/18) *Nocardia* spp. are susceptible to amikacin. Two cases who were taking amikacin as second line anti tubercular drugs (suspected TB cases) were found to be resistant to amikacin in our study. Similarly, 95% & 99% susceptibility to amikacin was found in other studies respectively [3,4]. Susceptibility to other antimicrobials was found to vary between 72% (doxycyclin) to 11% (azithromycin) against *Nocardia* in this study (Table 4).

One of the major limitations of this study is that, biochemical and molecular tests for identification of species were not done due to the resource constraints in our laboratory. Presence of Tuberculosis and *Nocardia* co-infection in suspected TB cases was not excluded in the study, MIC method for drug susceptibility testing was not possible either.

5. Conclusion

To achieve accurate diagnosis and successful outcome of treatment, clinicians should bear a strong index of suspicion and refer nonhealing skin infections with clinical history and specific request for identification of *Nocardia/Actinomyces*. Cases of suspected Tuberculosis not responding to anti tubercular drugs should be carefully investigated to exclude nocardiosis. *Nocardia* can easily be identified by Gram staining, modified ZN staining and growths on simple blood agar media with certain precautions, in a developing country like Bangladesh. Microbiologists are needed to be requested specifically for such cases as it requires extended incubation and contaminants can mask the growth of *Nocardia*. Trimethoprim-sulphamethoxazole is no more a drug of choice unless culture and sensitivity is done on the strain. Linezolid is universally active against all the isolates with a good sensitivity of amikacin. Further study with species

identification in a larger sample size should be done to assess the real picture of Nocardiosis in Bangladeshi patients.

Acknowledgements

Our special thanks to the laboratory technicians, Microbiology Department, AWMCH for their relentless effort. We are grateful to Professor Dr. Mustafa Kamal, Head, Microbiology Department, National Institute of Diseases of the Chest and Hospital (NIDCH), for supplying LJ media. Sincere thanks to Microbiology Department of Bangabandhu Sheikh Mujib Medical University and Kazi Shohedul Alam, DMD, Sarban International Limited for photomicrographs. Our thanks Dr. Dilruba Ahmed, Head, Clinical Microbiology and Immunology, ICDDRDB for identifying *Acinetobacter* species.

References

- [1] Minero MV, Marín M, Cercenado E, Rabadán PM, Bouza E, Muñoz P, "Nocardiosis at the turn of the century", *Medicine*, 88(4):250-61. Jul. 2009.
- [2] Saoji VA, Saoji SV, Gadegone RW, Menghani PR, "Primary cutaneous nocardiosis", *Indian journal of dermatology*, 57(5):404, Sep. 2012.
- [3] Uhde KB, Pathak S, McCullum I, Jannat-Khah DP, Shadomy SV, Dykewicz CA, Clark TA, Smith TL, Brown JM, "Antimicrobial-resistant nocardia isolates, United States, 1995-2004", *Clinical infectious diseases*, 51(12):1445-8, Dec.. 2010.
- [4] Wilson JW, "Nocardiosis: updates and clinical overview", *Mayo Clin Proc*, 87(4):403-7, Apr. 2012.
- [5] Angelika J, Hans-Jurgen G, Uwe-Frithjof H, "Primary cutaneous nocardiosis in a husband and wife", *J. Am Acad Dermatol*, 41(2 Pt 2):338-340, 1999.
- [6] Smego RA Jr, Moeller MB, Gallis HA, "Trimethoprim-sulfamethoxazole therapy for *Nocardia* infections", *Arch Intern Med*, 143(4):711-718, 1983.
- [7] Dawar R, Girotra R, Quadri S, Mendiratta L, Rani H, Imdadi F et al., "Epidemiology of Nocardiosis -A six years study from Northern India", *Journal of Microbiology and Infectious Diseases*, 6 (2): 60-64. 2016.
- [8] Beaman BL, Beaman L, "Nocardia species: host-parasite relationships", *Clin. Microbiol. Rev.*, 7(2): 213-264, 1994.
- [9] Cowan S T, Steel K J, "Manual for the identification of medical bacteria", Cambridge: Cambridge University Press. 1993.
- [10] Pintado V, Gomez ME, Forum J, Meseguer MA, Coba J, et al., "Infection with *Nocardia* species: clinical spectrum of diseases and species distribution in Madrid Spain 1978-2001", *Infection*, 30(6): 338-340, 2002.
- [11] Lerner PI, "Nocardiosis." *Clinical infectious diseases*, 22(6), 891-903, 1996.
- [12] Farina C, Boiron P, Ferrari I, Provost F, Goglio A, "Report of human nocardiosis in Italy between 1993 and 1997", *Eur J Epidemiol*, 17(11): 1019-1022, 2001.
- [13] Kurdgelashvili G, "Nocardiosis". *Emedicine.medscape.com*, (14 April 2017). Retrieved from <http://emedicine.medscape.com/article/224123-overview>
- [14] Pilszczek FH, Augenbraun M, "Mycetoma fungal infection: multiple organisms as colonizers or pathogens?", *Rev Soc Bras Med Trop*, 40(4):463-5, 2007.
- [15] Inamadar AC, Palit A, "Primary cutaneous nocardiosis: a case study and review", *Indian J of Dermatol Venerol Leprol*, 69(6): 386-391, 2003.
- [16] Das S, Cutaneous nocardiosis in east-Delhi, *Indian J Med Sci*, 55(6): 337-339, 2001.

- [17] Pintado V, Gomez ME, Forum J, Meseguer MA, Coba J, et al. "Infection with Nocardia species: clinical spectrum of diseases and species distribution in Madrid Spain, 1978-2001", *Infection*, 30(6): 338-340, 2002.
- [18] Atzori L, Pinna AL, Pau M, "Cutaneous Nocardiosis", *SOJ Microbiol Infect Dis*, 2(1): 8, 2014.
- [19] Kalb RE, Kaplan MH, Grossman ME, "Cutaneous nocardiosis. Case reports and review", *J Am Acad Dermatol*, 13(1): 125-133, 1985.
- [20] Lerner P I, "Nocardia species. In: Principles and practice of infectious diseases", New York: Churchill Livingstone, 1995; pp 2273-80.
- [21] Cowan S T, Steel K J, "Manual for the identification of medical bacteria", Cambridge: Cambridge University Press. 1993.
- [22] Wheeler KC, DeCesare GE; Rudolph J, et al., "Diagnostic Dilemmas: Cutaneous Nocardiosis", *Disclosures Wounds*, 17(5):131-136, 2005.
- [23] Lavalard E, Guillard T, Baumard S, Grillon A, Brasme L, Rodríguez-Nava V, et al., "Brain abscess due to Nocardia cyriacigeorgica simulating an ischemic stroke", *Ann Biol Clin (Paris)*, 71(3):345-348, 2013.
- [24] Murray PR, Baron EJ, Pfaller MA, et al., "Manual of Clinical Microbiology, 8th edn", Washington, D.C: American Society for Microbiology, 502-531, 2003.
- [25] Rodríguez-Nava V, Couble A, Devulder G, Flandrois JP, Boiron P, Laurent F, "Use of PCR-Restriction Enzyme Pattern Analysis and Sequencing Database for hsp65 Gene- Based Identification of Nocardia Species", *J Clin Microbiol*, 44: 536-546, 2006.
- [26] Saubolle MA, Sussland D, "Nocardiosis: Review of Clinical and Laboratory Experience", *J Clin Microbiol*, 41:4497-4501, 2003.
- [27] Baio PPV, Ramos JN, Dos Santos LS, Soriano MF, Ladeira EM, et al., "Molecular identification of nocardia isolates from clinical samples and an overview of human nocardiosis in Brazil", *PLoS Negl Trop Dis*, 7(12): e2573, 2013.
- [28] Gail. LW, Barbara ABE, Edward PD et al., "Susceptibility testing of Mycobacteria, Nocardiae and other aerobic Actinomycetes; approved standard-Second Edn", *CLSI*, 31(5), document M24-A2, 2011.
- [29] Boiron P, Provost F, Chevrier G, and Dupont B, "Review of nocardial infections in France 1987 to 1990", *Eur. J. Clin. Microbiol. Infect. Dis.*, 11: 709-714, 1992.
- [30] Georghiou PR, and Blacklock ZM, "Infection with Nocardia species in Queensland: a review of 102 clinical isolates", *Med. J. Aust*, 156: 692-697, 1992.
- [31] Kageyama A, Yazawa K, Ishikawa J, Hotta K, Nishimura K, et al., "Nocardial infections in Japan from 1992 to 2001, including the first report of infection by Nocardia transvalensis", *Eur J Epidemiol*, 19(4): 383-389, 2004.
- [32] Cruz PT and Clancy CF, "Nocardiosis: nocardial osteomyelitis and septicemia", *Am. J. Pathol*, 28:607-627, 1952.
- [33] Bibi S, Irfan S, Zafar A, Khan E, "Isolation frequency and susceptibility patterns of Nocardia species at a tertiary hospital laboratory in Karachi, Pakistan", *Journal of Infection in Developing Countries*, 5:499-501, 2011.
- [34] Valour F, Sénéchal A, Dupieux C, Karsenty J, Lustig S, Breton P, Gleizal A, Boussel L, Laurent F, Braun E, Chidiac C, "Actinomycosis: etiology, clinical features, diagnosis, treatment, and management. *Infect Drug Resist*", 7(7):183-97, 2014.
- [35] Barghouthi S, Hammad G, Kurdi M, "Acinetobacter Iwoffii Induced Cellulitis with Allergy-like Symptoms", *The Internet Journal of Microbiology*, 10(2): 1-6, 2012.
- [36] Giacometti A, Cirioni O, Schimizzi AM, Prete MSD, Barchiesi F, D'Errico MM et al., "Epidemiology and Microbiology of Surgical Wound Infections", *J Clin Microbiol*, 38, 918-922, (2000).
- [37] Brown-Elliott BA, Brown JM, Conville PS, Wallace RJ, "Clinical and laboratory features of the Nocardia spp. based on current molecular taxonomy", *Clin Microbiol Rev*, 19(2): 259-282, 2006.