



Case Report

Two Patients With an Anti-N-Methyl-D-Aspartate Receptor Antibody Syndrome-Like Presentation and Negative Results of Testing for Autoantibodies

Rikin Shah MBBS, Aravindhan Veerapandiyan MBBS, Sara Winchester MD, William Gallentine DO, Mohamad A. Mikati MD*

Division of Pediatric Neurology, Department of Pediatrics, Duke University Medical Center, Durham, North Carolina

ARTICLE INFORMATION

Article history:
Received 1 August 2011
Accepted 28 September 2011

ABSTRACT

We describe two boys whose distinct and remarkable clinical pictures suggested the possibility of anti-N-methyl-D-aspartate receptor antibody encephalitis. Both patients responded to immunotherapy, but neither manifested that antibody. Patient 1 exhibited florid encephalopathy with psychotic manifestations including inappropriate affect, intermittent delirium, visual hallucinations, severe anorexia, agitation, paranoid ideation, and abnormal electroencephalogram results. He responded to intravenous immunoglobulin, with steady improvement over 3 months to almost complete remission for 1 year, followed by a relapse that again responded, more quickly, to intravenous immunoglobulin. A second relapse occurred 1 month later, and again responded to intravenous immunoglobulin. Patient 2 exhibited progressive, severely debilitating limb dystonia that worsened over 1.5 years, with milder psychiatric symptoms including mood instability, aggressiveness, impulsivity, and depression. When he developed thymic hyperplasia 1.5 years into his illness, he underwent a thymectomy, and improved significantly on a regimen of plasmapheresis and intravenous immunoglobulin. Patients presenting with symptoms suggestive of autoimmune encephalitis, but without antibodies, may still respond to immunotherapy.

© 2011 Elsevier Inc. All rights reserved.

Introduction

Anti-N-methyl-D-aspartate receptor encephalitis is characterized by clinical features of memory impairment, behavioral and emotional problems, hypoventilation, epileptic seizures, and dyskinesia. About 30–50% of children with anti-N-methyl-D-aspartate receptor encephalitis exhibit associated neoplasms [1–3]. Other autoantibodies reportedly associated with paraneoplastic encephalitis include anti-crossveinless-2/collapsing response mediated protein 5, anti-Hu, anti-Ri, anti-Ma2, and anti-Yo antibodies. So far, to the best of our knowledge, only anti-Hu antibodies have been reported in children [4–7]. In addition, autoimmune encephalitis, associated with nonviral infections such as mycoplasma pneumonia and streptococcal infections, were also reported [8,9]. We describe two distinct cases, each with a remarkable clinical presentation suggestive of, although not identical to, anti-N-methyl-D-aspartate receptor encephalitis.

Neither patient manifested the antibody, although both responded to immunotherapy.

Case Reports

Patient 1

Clinical features

Patient 1 presented at age 13.5 years with a 3-day history of inappropriate affect, slowness of thinking and processing, confusion, impaired memory, intermittent delirium and agitation, visual hallucinations, anorexia, and paranoid ideation. His previous development was normal, and his immunizations were up to date. One week before presentation, he had complained of an upper respiratory infection. His history also included generalized anxiety disorder and social phobia, controlled with fluoxetine 1 year earlier. On examination, he was not oriented in regard to time, but was oriented in regard to place and person. He was withdrawn and lethargic but intermittently agitated, responded reluctantly to questions, expressed paranoid ideations, manifested slowness of thinking and constructional apraxia, and often appeared confused. He exhibited nystagmus on lateral gaze and difficulty in executing finger-to-nose-to-finger maneuvers and similar movements because of his apraxia. Other cerebellar, sensory, motor, and gait examinations produced normal results. He subsequently underwent an extensive workup, as detailed below. In the hospital, his condition worsened, he became completely withdrawn, and he would not read, write, or follow commands. He manifested frequent episodes of agitation, severe paranoia, marked anorexia, and recurrent facial tics. Magnetic resonance imaging of brain revealed increased meningeal enhancement over the left

* Communications should be addressed to: Dr. Mikati; Division of Pediatric Neurology; Department of Pediatrics; Duke University Medical Center; 2301 Erwin Road; T0913J Children Health Center; Durham, NC 27710.

E-mail address: mohamad.mikati@duke.edu

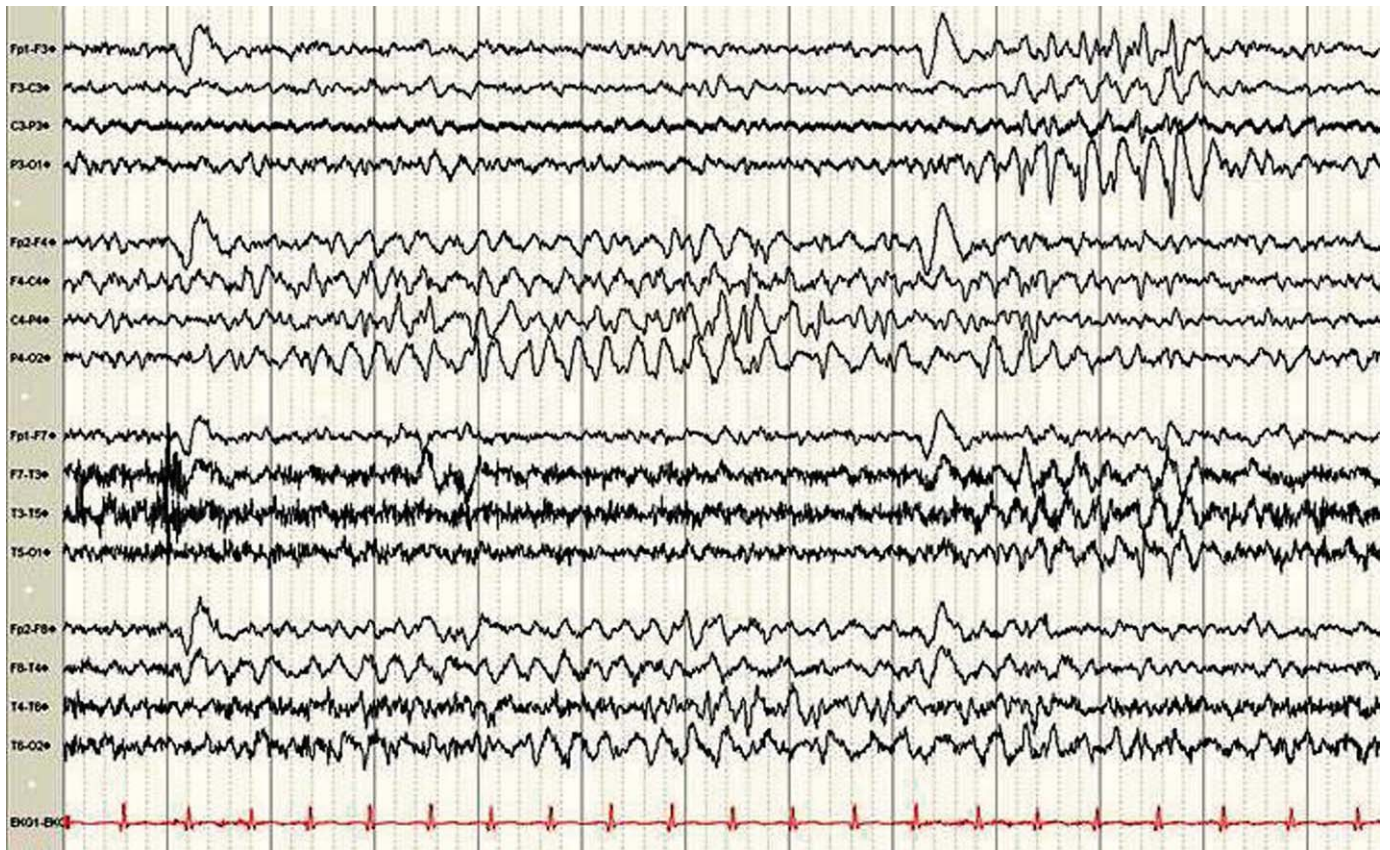


Figure 1. Electroencephalogram of patient 1 during his initial episode demonstrates runs of spike/slow waves in the right hemisphere lasting 9 seconds, followed by a similar shorter episode in the left hemisphere, both with left posterior predominance.

parietal cortex and posterior cerebellar fossa. Electroencephalography during his hospitalization revealed 3–10 second episodes of predominantly right hemispheric spike/slow wave activity, maximal in the right centroparietal and midtemporal regions, and occurring every 10–30 seconds. These bursts were occasionally generalized with right-sided predominance, and at times they were left-sided (Fig 1). He received sequential therapeutic doses of haloperidol and aripiprazole with minimal, if any, significant response. Therefore, these medications were discontinued, and he was maintained on carbamazepine, which appeared to result in a limited response. He received no benefit from pulse steroid therapy (24 mg/kg/day of intravenous methylprednisolone for 3 days, as of day 6 of admission). However, after intravenous immunoglobulin therapy (2 g/kg/day of intravenous immunoglobulin for 5 days, as of day 7 of admission), he began to improve. His hallucinations and paranoid ideations subsided over the next 2 weeks. During the same period, his apraxia improved and he was able to respond to commands and answer questions. He continued to receive intravenous immunoglobulin 0.5 g/kg once every 2 weeks for 6 weeks. He was discharged to a rehabilitation hospital after 60 days of hospitalization. He stayed in the rehabilitation hospital for 1 month, and received cognitive rehabilitation, psychotherapy, and occupational, physical, and speech therapies. A follow-up visit 1 month after discharge revealed a conscious, oriented, and cooperative boy who was not in distress, with normal mental status. A neurologic investigation, including cerebellar signs, reflexes, and motor, sensory, and gait examinations, produced normal results. He continued to exhibit steady improvement, and was described as 80–85% back to normal by his family at that stage. He subsequently completed the academic year catching up for missed schooling with the help of a tutor, and after summer vacation resumed his regular classes, in which he excelled aside from a need for methylphenidate because of difficulty with attention. The carbamazepine was discontinued for the next several months. At 6–12 months after discharge, his family considered his cognitive and social abilities to be 95% restored.

One year after his initial hospitalization (at age 15 years), he presented with a 5 day history of insomnia, confusion, anxiety, irritability, fearfulness, intermittent crying spells, and very frequent facial tics, with eye blinking and nose flicking. No history of hallucinations or delusions was reported. On examination, he was sleepy and slightly confused, but responded to simple commands. A neurologic examination produced otherwise normal results. An electroencephalogram produced normal results. He was rehospitalized and received 1 g/kg/day of intravenous

immunoglobulin for 2 days, which improved his mental status. He continued to exhibit residual agitation, paranoid ideations, and temper tantrums with confusion while receiving intravenous immunoglobulin 1 g/kg every 2 weeks. Therefore, the dose was increased after 2 months to 1 g/kg every week, which resulted in a complete resolution of his symptoms, except for some impulsiveness and occasional irritability. He began receiving mycophenolate 3 months later. One month afterward, an attempt to space the intravenous immunoglobulin at 1 g/kg every 2 weeks resulted in a relapse, involving agitation, confusion, paranoia, anxiety, tearfulness, and irritability 10 days after the last dose of intravenous immunoglobulin. He was again hospitalized. He received two doses of methyl prednisolone (500 mg) 12 hours apart, which worsened his symptoms. He also developed transient third nerve palsy during this episode. The weekly intravenous immunoglobulin dosing regimen was resumed, and was followed by a gradual resolution of his symptoms during the next 2 months.

Laboratory testing

Anti-N-methyl-D-aspartate receptor antibody, anti-neuronal antibody types 1, 2, and 3, anti-glial nuclear antibody type 1, Purkinje cell cytoplasmic antibodies 1 and 2, amphiphysin antibody, and anti-collapsing response mediated protein-5 produced negative results in serum and cerebrospinal fluid during both episodes. In addition, serum striational antibody, anti-voltage gated potassium channel antibody, anti-voltage gated calcium channel antibody P/Q type and N type, acetyl choline receptor binding antibody, acetyl choline receptor ganglionic neuronal antibody S, anti-microsomal thyroid antibody, anti-thyroglobulin thyroid antibody, and cerebrospinal fluid for oligoclonal bands produced negative results during both episodes. Testing for serum mycoplasma pneumonia antibodies during the first episode revealed borderline reactive immunoglobulin M mycoplasma antibodies (at 1:31; expected, ≤ 0.90) that were nondiagnostic, and elevated anti-streptolysin O titers (initially, 516 IU/mL; 3 days later, 528 IU/mL; 1 month later, 369 and 346 IU/mL, 2 days apart; reference range, <100 IU/mL). During his second hospitalization, mycoplasma immunofluorescence antibody testing produced negative results, and his anti-streptolysin titer was 147 IU/mL. In addition, several blood and serum investigations produced normal or negative results during both episodes, i.e., a complete blood count, a differential count, sedimentation rate, thyroid function tests, levels of folate, copper, zinc, creatine kinase, aldolase, and vitamins B6, B12, E, and D, cultures for viruses, anti-nuclear antibody, anti-Smith antibody, anti-Ro

antibody, anti-cardiolipin antibody, and anti-La antibody. Throat cultures for group A β -hemolytic streptococci produced negative results during both episodes. Cerebrospinal fluid cell counts and protein, neurotransmitter, and amino acid investigations produced normal results. The cerebrospinal fluid also produced negative results for Epstein-Barr, herpes simplex, human herpes-6, adenovirus, and arbovirus. Imaging studies, including magnetic resonance imaging of the chest, abdomen and pelvis, did not reveal any tumors.

Patient 2

Clinical features

An 8-year-old boy, born preterm, presented at age 6 years with a 2-month history of progressive slurring of speech, stuttering with frequent daily episodes of extension posturing of the right upper extremity, and twisting of the right leg, causing multiple trips and falls. These posturing episodes tended to last several minutes. In addition, he also exhibited sudden, jerky movements of the head and right arm that had begun 2 weeks before presentation. His previous medical history indicated normal growth and development, except for ectopic atrial tachycardia, treated by ablation therapy at age 5 years. No family history of any neurologic or movement disorder was reported. Our examination revealed an awake, alert, well oriented boy in no acute distress. A neurologic examination revealed dysarthric speech, dystonic posturing of the right upper and lower extremities (lower more than upper), and abnormal gait secondary to dystonia. An extensive workup for dystonia, including rheumatologic, infectious disease, genetic, and other etiologies, was unrevealing. Cranial magnetic resonance imaging produced normal results. He was treated with therapeutic doses of clonazepam, and risperidone and received physical, speech, and occupational therapies, with no significant benefit. He then received oral prednisolone (0.8 mg/kg/day) for 5 days, which resulted in a moderate improvement of his symptoms. He was discharged on that dose of steroids, with gradual withdrawal and discontinuation during the next 5 weeks. However, in the next 3 months his symptoms fluctuated, involving two exacerbations (each lasting for 2 weeks), without a complete return to baseline between them. He manifested a drop in his ability to concentrate and perform in school and an increase in his dystonia, and he became refractory to subsequent courses of steroids. The two acute exacerbations involved rehospitalizations and included severe dysarthria and total right hemibody dystonia. During both admissions, he was treated with intravenous immunoglobulin (2 g/kg/day for 5 days), after which he demonstrated moderate improvements in his symptoms.

Follow-up at 5 months after the initial episode revealed a worsening of his right hemibody dystonia with progression to his left side, severe dysarthria, frequent and superimposed myoclonic jerking of his head and arms, and orofacial dyskinesia. At that time he was receiving clonazepam (0.045 mg/kg/day), baclofen (1.25 mg/kg/day), gabapentin (18 mg/kg/day), and sertraline (0.3 mg/kg/day). His dystonia had become essentially continuous and prevented him from walking, with superimposed, very painful dystonic spasms lasting minutes or even hours at a time. He also developed changes in mental status, including mood instability, impulsivity, intermittent aggressiveness, memory problems, reading difficulties, and episodes of extreme withdrawal. A neurologic examination revealed severe dysarthria, constant writhing movements of the tongue and face, hypertonia in the right upper and lower extremities, dystonic posturing of both lower extremities, and adventitious choreiform movements. Testing for neurologic paraneoplastic autoantibodies produced negative results. Surveillance for associated tumors revealed an enlarged thymus (Fig 2), which was not present on previous chest radiographs. The thymus was resected, and a pathologic examination demonstrated benign thymic hyperplasia, which was also confirmed by immunophenotyping. Subsequently he received plasmapheresis (three times a week for 3 weeks, followed by twice a week for another 3 weeks, and then once a week for 3 weeks, and then discontinued) and intravenous immunoglobulin (2 g/kg/day once a week for 4 weeks, followed by once every month), which he continued to receive for 1 year.

Follow-up at age 8 years (1 year later) indicated significant improvement. He still exhibited residual dystonia, but without the previous superimposed severe dystonic spasms. He could sit with support, and pull himself up to sit. He also demonstrated better control of his right hand and was able to color and write with it, with some difficulty. He was able to move both lower extremities, and could stand while holding on to things. He was beginning attempts to walk with a walker. His speech had also improved, and he was able to use full sentences and read at a third grade level.

Laboratory testing

Anti-*N*-methyl-D-aspartate receptor antibody, anti-neuronal antibody types 1, 2, and 3, anti-glial nuclear antibody type 1, Purkinje cell cytoplasmic antibodies 1 and 2, amphiphysin antibody, and anti-collapsing response mediated protein 5 produced negative results in serum and cerebrospinal fluid. In addition, serum striational antibody, anti-voltage gated potassium channel antibody, anti-voltage gated calcium channel antibody P/Q type and N type, acetyl choline receptor binding antibody, acetyl choline receptor ganglionic neuronal antibody S, anti-nuclear antibody, anti-cardiolipin antibody, anti-microsomal thyroid antibody, anti-thyroglobulin thyroid antibody, and lupus anticoagulant produced negative results. Serum mycoplasma immunoglobulin G and immunoglobulin M antibodies

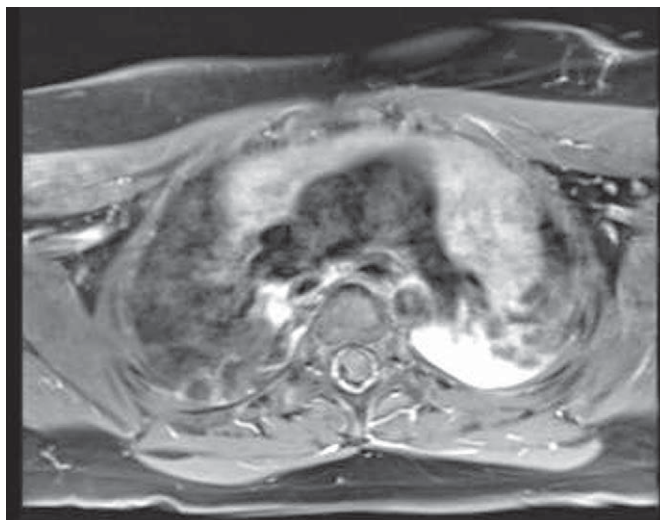


Figure 2. Magnetic resonance imaging of the chest in patient 2 reveals an enlarged thymus.

produced negative results. Repeated testing for these antibodies 1 year later also produced negative results. Testing for cerebrospinal fluid oligoclonal bands produced positive results. Throughout the course of his illness, the patient underwent extensive workups that all produced normal results, including complete blood counts, thyroid function tests, levels of creatine kinase, aldolase, copper, ceruloplasmin, and vitamins D, E, and B12, acyl carnitine profiles, levels of glutamic acid decarboxylase, cerebrospinal fluid examinations for cells, protein, amino acids, and neurotransmitters, magnetic resonance imaging of the brain and spine, electroencephalograms, muscle biopsies, gene testing for Niemann-Pick disease type C, ataxia, Huntington disease, myoclonus-dystonia syndrome, familial early-onset generalized dystonia, limb-onset focal dystonia, Lafora body disease, infantile neuroaxonal dystrophy, and Pelizaeus-Merzbacher disease, and enzyme assays for GM1-gangliosidosis, β -mannosidosis, fucosidosis, Tay-Sachs disease, metachromatic leukodystrophy, Krabbe disease, neuronal ceroid-lipofuscinosis, and mitochondrial diseases.

Discussion

Anti-*N*-methyl-D-aspartate receptor encephalitis was first reported in 2007 [10]. Numerous cases have been reported since [1,2,11]. However, before the identification of these antibodies, patients presenting with clinical symptoms similar to those of anti-*N*-methyl-D-aspartate receptor encephalitis were often diagnosed with encephalitis of unknown origin after the exclusion of infectious, autoimmune, or other causes. We think the earliest case with such a clinical picture was reported in 1985 [12]. That patient, with a florid presentation of protracted encephalopathy and psychotic and vegetative symptoms, was similar to our patient 1. Since the original report of anti-*N*-methyl-D-aspartate receptor antibody syndrome in 2007, to our knowledge, no cases were described with a clinical presentation suggestive of that syndrome with negative antibodies. Here, we report on two such patients.

Our patient 1 bears several similarities to those with anti-*N*-methyl-D-aspartate receptor encephalitis. These similarities include the presence of encephalopathy, abnormal electroencephalogram results, and psychiatric symptoms. As was the case for patient 1, about 75% of patients with anti-*N*-methyl-D-aspartate receptor encephalitis present with prodromal symptoms and then prominent psychiatric manifestations (Table 1) [1]. However, patient 1 differed from anti-*N*-methyl-D-aspartate receptor encephalitis in that he did not manifest seizures, dystonia, choreoathetosis (although he did have recurrent tics), cerebrospinal fluid lymphocytic pleocytosis, or associated neoplasms, which occur in about

Table 1. Clinical features of our two patients, compared with those of anti-N-methyl-D-aspartate receptor encephalitis and other autoimmune paraneoplastic encephalopathies

Clinical Features	Reported in Adults and Children		Reported in Adults Only				Our Patients (Both Children)	
	Anti-NMDA*	Anti-Hu	Anti-CV 2/ CRMP 5	Anti-CRMP 3-4	Anti-Yo	Anti-Ri	Patient 1	Patient 2
Prodromal symptoms	+ (48%)	–	–	–	–	–	+	–
Psychiatric symptoms	+ (59%)	–	–	+	–	–	+	+
Dystonia	+ (29%)	–	–	–	+	–	–	+
Orofacial dyskinesia	+ (45%)	–	–	–	–	–	–	+
Choreoathetoid movements	+ (32%)	+	+	–	–	+	+	–
Seizures	+ (77%)	–	–	–	–	+	–	–
Cerebellar ataxia	–	+	+	–	+	+	–	–
Retinopathy/optic neuritis	–	–	+	–	–	–	–	–
Peripheral neuropathy	–	–	+	–	–	+	–	–
Sensory symptoms	–	+	–	–	–	–	–	–
Olfactory disturbance	–	–	+	–	–	–	–	–
Cardiac arrhythmias	+ (57%)	–	–	–	–	–	–	+
Abnormal cerebrospinal fluid	+ (94%) [†]	+	+	+	+	+	–	+
Associated neoplasm [‡]	25-55% (Ovarian teratoma)	98% (SCLC)	96% (SCLC)	Thymoma [§]	98% (breast, ovary)	97% (breast, SCLC)	–	–

Abbreviations:

NMDA = N-methyl-D-aspartate

SCLC = Small cell lung cancer

* Percentages within parentheses pertain to incidence in children (≤ 18 years old) [3].[†] Abnormal cerebrospinal fluid findings include lymphocytic pleocytosis, increased protein, and oligoclonal bands (evident in patient 2).[‡] Neoplasms mentioned in parentheses are commonly associated neoplasms with the respective disease.[§] Only one case has been reported so far, to the best of our knowledge.

60% of patients with anti-N-methyl-D-aspartate receptor encephalitis. Our patient 2 also exhibited several similarities to patients with anti-N-methyl-D-aspartate receptor encephalitis. These similarities included orofacial dyskinesia, choreoathetoid movements, dystonia, and psychiatric symptoms [1]. He differed in that he did not manifest seizures, more marked encephalopathic changes, or an associated malignancy.

The mycoplasma immunoglobulin M antibody that was “possibly reactive” during the first episode in patient 1 raised the possibility of post-mycoplasma encephalitis. However, the absence of clinical manifestations, such as signs of meningeal irritability, convulsions, and ataxia [8], the lack of specificity in his very modest increase in immunoglobulin M titers, and the lack of increases of those titers during recurrences rendered the possibility of post-mycoplasma encephalitis much less likely. Patient 2 also presented no evidence of mycoplasma infection.

The presence of an elevated anti-streptolysin O titer in patient 1 also raised the possibility of pediatric autoimmune neuropsychiatric disorders associated with streptococcal infection. This entity reportedly involves a group of children with a rapid onset of obsessive-compulsive disorder or tic disorders after group A β -hemolytic streptococcal infections, and its existence is still controversial. However, patient 1 did not fit the criteria for these disorders [9], because the results of his throat cultures were negative, and he did not manifest increases in anti-streptolysin O titer during exacerbations of his symptoms or obsessive-compulsive disorder. The clinical evidence was also insufficient to support a diagnosis of Tourette syndrome or Sydenham's chorea, although they were included in his differential diagnosis. Similarly, patient 2 did not fit the criteria for pediatric autoimmune neuropsychiatric disorders associated with streptococcal infection. Some of the clinical manifestations observed in patient 2, such as limb dystonia, choreoathetosis, and dysarthria, were reported in patients with encephalitis associated with anti-neuronal antibody type 1 (anti-Hu), anti-neuronal antibody type 2 (anti-Ri), and anti-Purkinje cell antibody (anti-Yo) [4]. However, he did not manifest these antibodies and an associated malignancy. These autoantibodies are almost always (in >96% of cases) paraneoplastic [4].

In addition, a history of generalized anxiety disorder and social phobia in patient 1 raised the possibility of an acute exacerbation of these preexisting conditions. However, his clinical presentation, neurologic examinations, abnormal electroencephalogram findings, and response to intravenous immunoglobulin during his initial presentation as well as during exacerbations favored an immune-mediated process rather than the acute exacerbation of a preexisting problem. This idea was also supported by the occurrence of transient third nerve palsy for several days during one of his subsequent relapses. Furthermore, we could not entirely exclude the possibility that the clinical improvement of patient 1 during his initial episode was attributable to a slightly delayed effect of steroid, together with an effect of intravenous immunoglobulin, because the intravenous immunoglobulin was initiated immediately after the discontinuation of steroids. However, the patient's subsequent worsening on steroids during his second relapse and his repeated, although incomplete, response to immunoglobulin support the likelihood of a response to intravenous immunoglobulin rather than a response to combined immunoglobulin and steroids.

In conclusion, we describe two boys, both of whom demonstrated a clinical course with features that suggested anti-N-methyl-D-aspartate receptor encephalitis. However, neither patient manifested detectable anti-N-methyl-D-aspartate receptor antibodies in serum and cerebrospinal fluid. Immunotherapy helped both of them significantly. Their responses to intravenous immunoglobulin (both patients) and plasmapheresis (patient 2) suggest an antibody-mediated pathophysiology. Our experience indicates that patients who present with clinical features suggestive of autoimmune encephalitis may still respond to immunotherapy, even in the absence of demonstrable antibodies in serum or cerebrospinal fluid. Further research may identify other antibodies or soluble substances underlying the florid clinical symptomatology of such cases.

The authors thank Dr. Edward Smith, Dr. Carolyn Pizoli, the members of the pediatric neurology team, the hospitalists, and other colleagues for the excellent care these patients received, and that made this report possible.

References

- [1] Dalmau J, Gleichman AJ, Hughes EG, et al. Anti-NMDA-receptor encephalitis: Case series and analysis of the effects of antibodies. *Lancet Neurol* 2008; 7:1091–8.
- [2] Dalmau J, Lancaster E, Martinez-Hernandez E, Rosenfeld MR, Balice-Gordon R. Clinical experience and laboratory investigations in patients with anti-NMDAR encephalitis. *Lancet Neurol* 2011;10:63–74.
- [3] Florance NR, Davis RL, Lam C, et al. Anti-N-methyl-d-aspartate receptor (NMDAR) encephalitis in children and adolescents. *Ann Neurol* 2009;66:11–8.
- [4] Gozzard P, Maddison P. Which antibody and which cancer in which paraneoplastic syndromes? *Pract Neurol* 2010;10:260–70.
- [5] Gultekin SH, Rosenfeld MR, Voltz R, Eichen J, Posner JB, Dalmau J. Paraneoplastic limbic encephalitis: Neurological symptoms, immunological findings and tumour association in 50 patients. *Brain* 2000;123:1481–94.
- [6] Meyer JJ, Bulteau C, Adamsbaum C, Kalifa G. Paraneoplastic encephalomyelitis in a child with neuroblastoma. *Pediatr Radiol* 1995;25(Suppl. 1):S99–101.
- [7] Morales La Madrid A, Rubin CM, Kohrman M, Pytel P, Cohn SL. Opsoclonus-myoclonus and anti-Hu positive limbic encephalitis in a patient with neuroblastoma. *Pediatr Blood Cancer*; 2011 Apr 7 (Epub ahead of print).
- [8] Guleria R, Nisar N, Chawla TC, Biswas NR. *Mycoplasma pneumoniae* and central nervous system complications: A review. *J Lab Clin Med* 2005; 146:55–63.
- [9] Swedo SE, Leonard HL, Garvey M, et al. Pediatric autoimmune neuropsychiatric disorders associated with streptococcal infections: Clinical description of the first 50 cases. *Am J Psychiatry* 1998;155:264–71.
- [10] Dalmau J, Tuzun E, Wu HY, et al. Paraneoplastic anti-N-methyl-d-aspartate receptor encephalitis associated with ovarian teratoma. *Ann Neurol* 2007;61:25–36.
- [11] Gable MS, Gavali S, Radner A, et al. Anti-NMDA receptor encephalitis: Report of ten cases and comparison with viral encephalitis. *Eur J Clin Microbiol Infect Dis* 2009;28:1421–9.
- [12] Mikati MA, Lee WL, DeLong GR. Protracted epileptiform encephalopathy: An unusual form of partial complex status epilepticus. *Epilepsia* 1985;26: 563–71.