

## Topical application of substance P promotes wound healing in streptozotocin-induced diabetic rats



Vinay Kant<sup>a,\*</sup>, Dinesh Kumar<sup>a</sup>, Dhirendra Kumar<sup>a</sup>, Raju Prasad<sup>a</sup>, Anu Gopal<sup>a</sup>, Nitya N. Pathak<sup>a</sup>, Pawan Kumar<sup>b</sup>, Surender K. Tandan<sup>a</sup>

<sup>a</sup> Division of Pharmacology and Toxicology, Indian Veterinary Research Institute, Izatnagar, Bareilly 243 122, U.P., India

<sup>b</sup> Division of Pathology, Indian Veterinary Research Institute, Izatnagar, Bareilly 243 122, U.P., India

### ARTICLE INFO

#### Article history:

Received 19 October 2014

Received in revised form 9 December 2014

Accepted 9 December 2014

#### Keywords:

Substance P  
Diabetic rats  
Wound healing  
Epithelial layer  
Microvessel density

### ABSTRACT

Substance P (SP) is known to stimulate angiogenesis, fibroblasts proliferation and expressions of cytokines and growth factors involved in wound healing. However, SP level reduces in dermis in diabetics and, hence, it was hypothesized that exogenously applied SP could be helpful in improving wound healing in diabetic rats. Excision skin wound was created on the back of diabetic rats and rats were divided into three groups i.e. (i) saline-, (ii) gel- and (iii) SP-treated. Normal saline, pluronic gel and SP ( $10^{-6}$  M) in gel were topically applied once daily for 19 days. SP treatment significantly increased the wound closure, levels of interleukin-10, and expressions of vascular endothelial growth factor, transforming growth factor-beta1, heme oxygenase-1 and endothelial nitric oxide synthase, whereas it significantly decreased the expression of tumor necrosis factor-alpha, interleukin-1beta and matrix metalloproteinases-9 in the granulation/healing tissue. The inflammatory cells were present for long time in normal saline-treated group. Histological evaluation revealed better extracellular matrix formation with marked fibroblast proliferation and collagen deposition in SP-treated group. Early epithelial layer formation, increased microvessel density and greater growth associated protein-43 positive nerve fibers were also evidenced in SP-treated group. In conclusion, SP treatment markedly accelerated cutaneous wound healing in diabetic rats.

© 2014 Elsevier Ltd. All rights reserved.

### 1. Introduction

Diabetes mellitus (DM) is a very complex disease that drastically influences normal functioning of the affected individual including wound healing process, which is markedly delayed. The most common complications of delayed wound healing of diabetics are: reduction in chemotactic and phagocytic activities of neutrophils [1], decreased vasculogenesis [2], decreased endothelial nitric oxide synthase (eNOS) activity [3] and reduction of substance P (SP) level [4]. Abnormal nerve distribution and neuroinflammation are also connected with the chronic nonhealing wounds in DM. The patients suffering from DM have diminished number of nerves and depleted nerve growth factor in uninjured skin and cutaneous wounds [5].

SP, a 10-amino acid neuropeptide, is released by the sensory nerve fibers during tissue insult and has been reported to be a mediator of inflammation in wound healing [6]. It binds to neurokinin-1 (NK-1) receptors and elicits vasodilatory action via nitric oxide, alters vascular permeability and enhances the delivery and accumulation of leukocytes to tissues for the expression of the local immune response [7], SP stimulates the production of various cytokines such as, tumor necrosis factor-alpha (TNF- $\alpha$ ), interleukin-1beta (IL-1 $\beta$ ), IL-2, IL-8 and IL-6, and growth factors namely, vascular endothelial growth factor (VEGF) and transforming growth factor-beta1 (TGF- $\beta_1$ ), involved in wound healing [8–11]. It is also involved in the angiogenesis, epidermal cell proliferation, and capillary and fibroblast proliferation [12,13]. Depleted SP and decreased number of SP-positive fibers has been reported in the dermis of diabetic patients [4,14]. The reduction of SP directly contributes to the abnormal healing response in patients with diabetes [15]. SP has been shown to promote cutaneous wound healing in non-diabetic rats [11,16]. Topical application of SP ( $10^{-7}$  M) enhanced wound closure in nitric oxide synthase knock out mice and non-diabetic rats [5,11]. In addition, exogenously administration of SP stimulated fibroblast

\* Corresponding author at: Department of Veterinary Pharmacology & Toxicology, Lala Lajpat Rai University of Veterinary & Animal Sciences (LUVAS), Hisar 125001, Haryana, India.

E-mail addresses: [drvinaykant2001@yahoo.co.in](mailto:drvinaykant2001@yahoo.co.in), [drvinaykantlumas@gmail.com](mailto:drvinaykantlumas@gmail.com) (V. Kant).

**Table 1**  
Description of primers used.

S. No.	Gene	Primer sequences	Product size	Annealing temp. (°C)	Accession number
1	$\beta$ -actin	F: 5'-TCCTAGCACCATGAAGATCAA G-3' R: 5'-GACTCATCGTACTCTGCTTG-3'	132	59	NC_005111
2	TGF- $\beta_1$	F: 5'-AAG TGG ATC CAC GAG CCC AA-3' R: 5' GCTGCACCTGCAGGAGCGCA-3'	246	62	NM021578.2
3	VEGF	F: 5'-GCCAGCACATAGGAGAGATGAG-3' R: 5' ACCGCCTTGGCTTGTCAC-3'	234	62	NM031836.2
4	TNF- $\alpha$	F: 5'-GGCCACCACGCTCTTTCTGTCA-3' R 5'-TGGGCTACGGGCTTGTCACCTC-3'	153	60	NM012675.3
5	IL-1 $\beta$	F: 5'-GACAAGCAACGACAAAATCCC-3' R: 5'-TGGGTATTGTTGGGATCCAC-3'	124	58	NC_005102
6	MMP-9	F: 5'-CTTGAAGTCTCAGAAGTGGATC-3' R: 5'-CGCCAGAAGTATTTGTCATGG-3'	135	59	NC_005102
7	IL-10	F: 5'-CCTGCTCTTACTGGCTGGAG-3' R: 5'-TGTCAGCTGGTCTTCTTT-3'	161	60	NM012854.2
8	HO-1	F: 5'-AGAGTCCCTCACAGACAGTTTT-3' R: 5'-CCTGCAGAGAGAAGGCTACATGA-3'	247	60	NM012580.2
9	eNOS	F: 5'-TGATGTCATATGGCAACCAG-3' R: 5'-TGTGAGTCCGAAAATGTCCTC-3'	145	59	NC_005103

proliferation, angiogenesis and collagen organization during Achilles tendon healing in rats [13]. In view of the above, we hypothesized that topical supplementation of SP might be helpful in improving impaired wound healing in diabetics. Thus, the present study was planned to investigate the time-dependent effects of topically applied SP in open excision wound in diabetic rats. Additionally, we used pluronic F-127 (PF-127) gel for the topical delivery of SP at the wound site, as we found [17] that PF-127 gel markedly improved wound healing in non-diabetic rats.

## 2. Experimental procedures

### 2.1. Experimental animals and diabetes induction

Healthy adult male Wistar rats (170–200 g) were procured from Laboratory Animal Resource Section, Indian Veterinary Research Institute, Izatnagar (U.P.), India. The experimental protocol was approved by the Institute Animal Ethics Committee. All animals received humane care in accordance with National Institutes of Health's *Guide for the Care and Use of Laboratory Animals* (NIH Publication N. 85-23, revised 1985). Diabetes was induced by single intraperitoneal injection of streptozotocin (60 mg/kg; Sigma-Aldrich, USA). After 48 h, animals with blood glucose levels  $\geq 300$  mg/dl were selected. After 7 days of diabetic induction, the open excision-type wound  $2 \times 2$  cm<sup>2</sup> ( $\approx 400$  mm<sup>2</sup>,  $\approx 2$  mm depth including the panniculus carnosus) was created on the back of sixty diabetic animals under pentobarbitone sodium (40 mg/kg) anesthesia. Following recovery from anesthesia, rats were housed individually in properly disinfected cages.

### 2.2. Grouping

Animals were divided equally in the following three groups:

- (I) *Control*: Sterile normal saline was applied on the wounds once daily for 19 days.
- (II) *PF-127 gel-treated (gel-treated)*: 400  $\mu$ l of PF-127 gel (25%, Sigma Aldrich, USA) was applied topically once daily for 19 days.
- (III) *SP-treated*: 400  $\mu$ l of SP ( $10^{-6}$ M, Sigma Aldrich) in PF-127 gel (25%) was applied topically on wounds once daily for 19 days.

### 2.3. Photography and wound contraction

Photograph of each wound was taken on days 0, 3, 7, 11, 14 and 19 post-wounding. The wound area was determined planimetrically on these days and per cent wound contraction was calculated by Wilson's formula as follows:

% wound contraction

$$= \frac{0 \text{ day wound area} - \text{wound area on particular day}}{0 \text{ day wound area}} \times 100$$

### 2.4. Tissue harvesting

Five animals from each group were killed on days 3, 7, 14 and 19, and granulation/healing tissue was collected. One portion was stored in RNA stabilization reagent (RNAlater™, Qiagen, USA) at  $-20$  °C until RNA extraction. The second portion was preserved in 10% neutral buffer formalin for histopathological evaluation. Third portion was homogenized in ice-cold lysis buffer [100 mg tissue in 1 ml lysis buffer: 1% Triton X 100, 10 mM phenylmethylsulfonyl fluoride, 1 mg/ml aprotinin and 1 mg/ml leupeptin in phosphate buffer saline (pH 7.4)] and centrifuged at 12,000 rpm for 10 min at 4 °C. The aliquots of the supernatant were prepared and stored at  $-80$  °C till further processing for Western blotting and enzyme linked immunosorbant assay (ELISA).

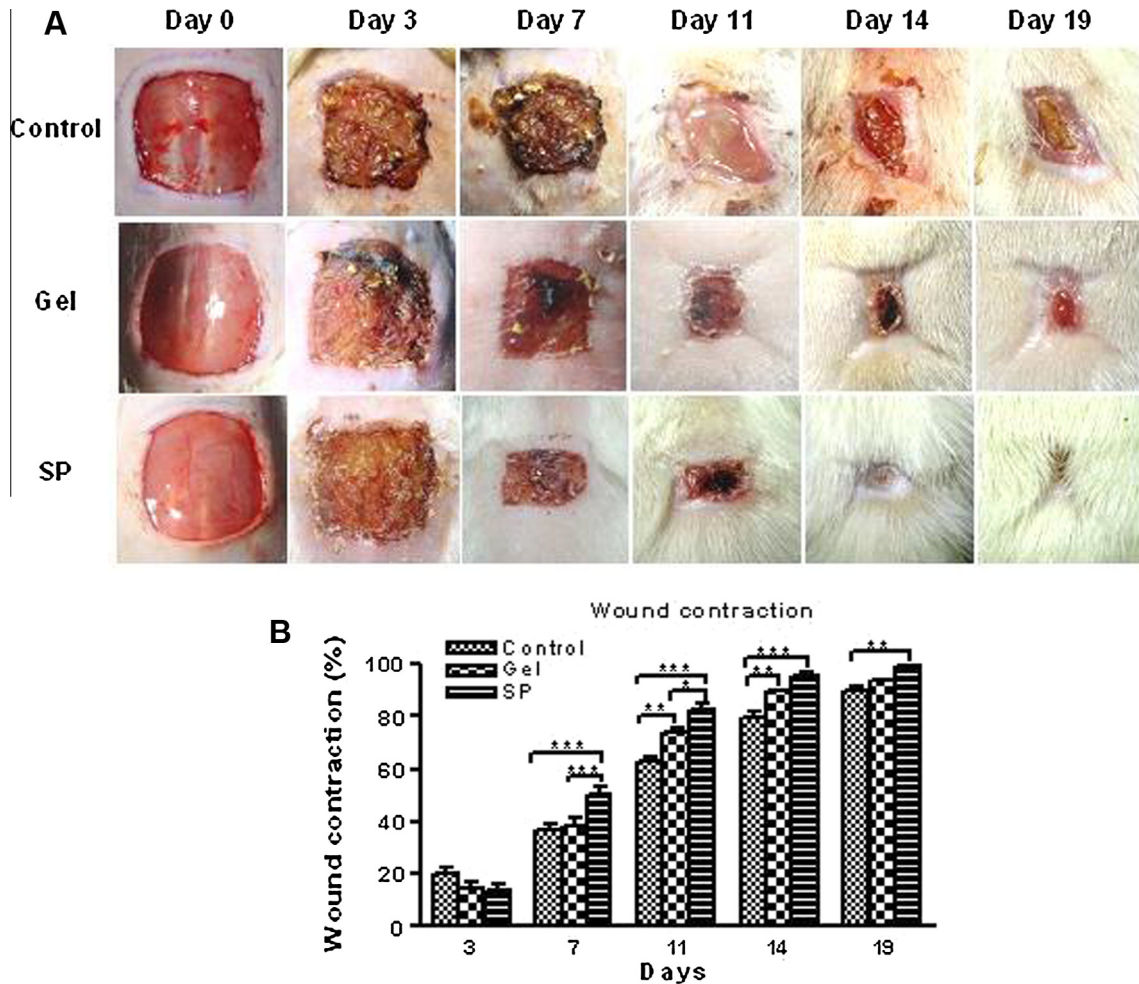
### 2.5. Real-time RT-PCR

The mRNA expressions of TNF- $\alpha$ , IL-10, TGF- $\beta_1$ , VEGF, IL-1 $\beta$ , matrix metalloproteinases-9 (MMP-9), heme oxygenase-1 (HO-1) and eNOS were determined with real-time RT-PCR. RNA was isolated from wound tissues using RiboZol™ RNA extraction reagents (Amresco, USA) and cDNA was synthesized using cDNA synthesis kit (Fermentas, Lafayette, CO, USA). cDNA was used as a template for the subsequent real time RT-PCR. The real time PCR assay was performed by using  $2 \times$  QuantiTect SYBR Green PCR Master Mix, (Qiagen, CA, USA) in CFX96 real time PCR DET SYS (C-1000 thermal cycler, BIO-RAD laboratories India). The real-time RT-PCR experiment was carried out according to the manufacturer's instruction and the following thermal cycling profile was used (40 cycles): 95 °C for 15 min, 94 °C for 15 s, 58–62 °C (depending on primer) for 30 s and 72 °C for 30 s. Details of the primers used

**Table 2**Fasting blood glucose levels in different groups before (normal blood glucose) and after administration of streptozotocin (STZ; 60 mg/kg body wt.) injection ( $n = 5$ ).

Group	Day 0 (STZ injected)	Day 2	Day 7 (day of wounding)	Day 3 post wounding	Day 7 post wounding	Day 14 post wounding	Day 19 post wounding
Control	102.6 ± 6.42 <sup>a</sup>	424.4 ± 33.81 <sup>b</sup>	464.2 ± 34.37 <sup>b</sup>	440.2 ± 26.08 <sup>b</sup>	427.8 ± 24.25 <sup>b</sup>	424.8 ± 20.39 <sup>b</sup>	478.8 ± 15.66 <sup>b</sup>
Gel	102.4 ± 4.23 <sup>aa</sup>	434.4 ± 30.24 <sup>b</sup>	444.8 ± 30.58 <sup>b</sup>	448.8 ± 33.41 <sup>b</sup>	446.2 ± 25.86 <sup>b</sup>	432.4 ± 22.06 <sup>b</sup>	417.6 ± 16.73 <sup>b</sup>
SP	98.6 ± 5.87 <sup>a</sup>	466.6 ± 33.61 <sup>b</sup>	475.8 ± 35.01 <sup>b</sup>	439.6 ± 24.71 <sup>b</sup>	451.2 ± 31.64 <sup>b</sup>	447.8 ± 20.69 <sup>b</sup>	425.8 ± 19.28 <sup>b</sup>

Blood glucose levels were compared to day 0 levels of the same group. Values with different superscripts (i.e. 'a' and 'b') vary significantly.

<sup>b</sup>  $p < 0.001$ .

**Fig. 1.** Effect of substance P (SP) on increased cutaneous wound closure. (A) Representative photographs of wounds of control, gel-treated and SP-treated groups revealing faster wound closure in SP-treated group. (B) Wound contraction (%) in different groups on days 3, 7, 11, 14 and 19 post-wounding. SP markedly increased the per cent wound contraction on days 7, 11, 14 and 19, as compared to other groups. \* $p < 0.05$ , \*\* $p < 0.01$  and \*\*\* $p < 0.001$  indicate significant difference compared with other group(s) on the same day. The data expressed are an average means  $\pm$  SEM,  $n = 5$ .

are given in Table 1. The  $\Delta\Delta\text{CT}$  method of relative quantification was used to determine fold change in expression and was obtained as  $2^{-\Delta\Delta\text{CT}}$  [18].

## 2.6. Western blotting

The expression levels of VEGF and TGF- $\beta_1$  were determined by Western analysis. Proteins were separated by using SDS-PAGE and transferred to polyvinylidene difluoride membrane. The membranes were then incubated with goat polyclonal antibodies against VEGF and TGF- $\beta_1$  (Santa Cruz Biotechnology, Santa Cruz, CA, USA). After washing, membranes were incubated with horseradish peroxidase (HRP)-conjugated chicken anti-goat IgG (Santa Cruz Biotechnology, Santa Cruz, CA, USA).  $\beta$ -actin was used to normalize protein loading. The blots were subsequently scanned and band

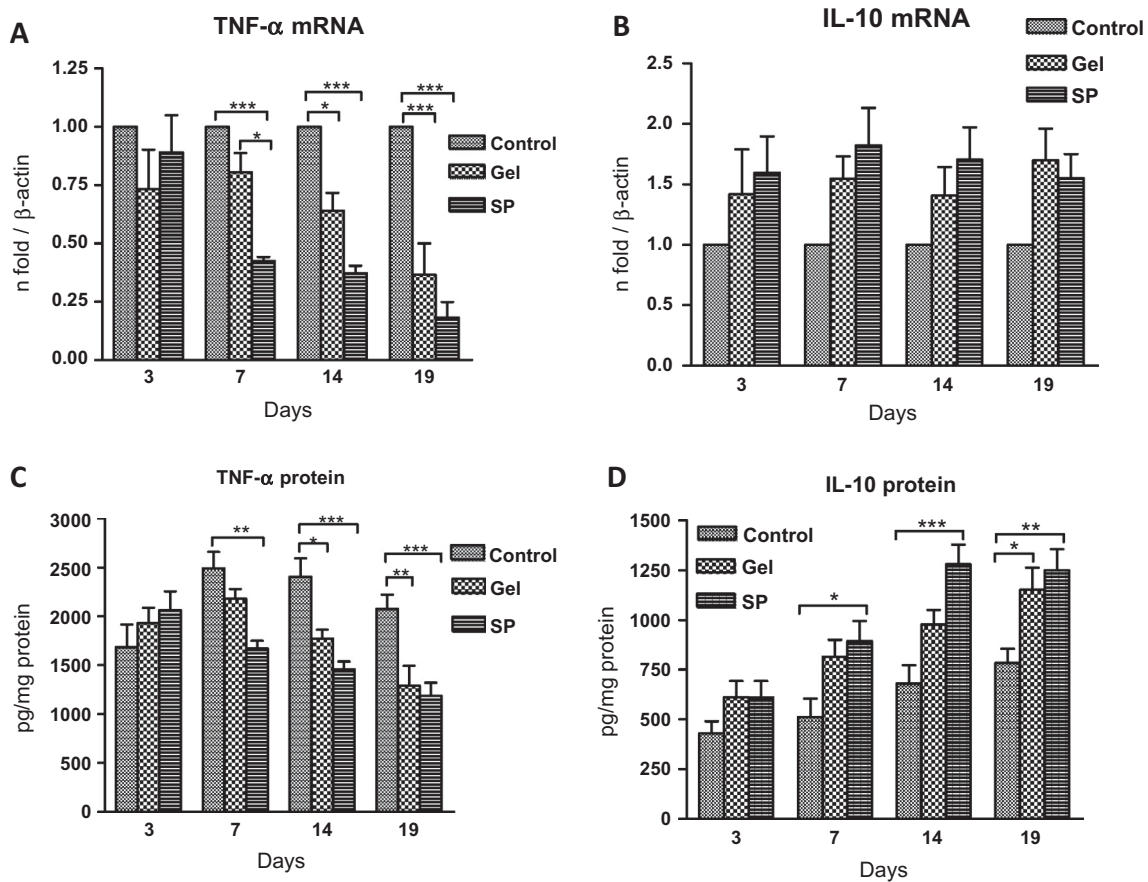
intensity was quantified by densitometry software (ImageJ, NIH). Four minimum such blots were performed for every protein analyzed.

## 2.7. ELISA

The supernatants of lysates were quantitatively assayed for TNF- $\alpha$  and IL-10 (Komabiotek Inc., Seoul, Korea) levels as per the manufacturer's instructions.

## 2.8. Hematoxylin and Eosin (H&E) staining

5  $\mu\text{m}$  thick tissue sections were stained with H & E as per standard method and visualized under light microscope (Leica DFC450C, Wetzlar, Germany) at magnification 10 $\times$  and 40 $\times$ . Ten



**Fig. 2.** Effect of substance P (SP) on mRNA expressions and protein levels of TNF- $\alpha$  and IL-10. (A) mRNA expressions of TNF- $\alpha$  in different groups on various days. The TNF- $\alpha$  mRNA expression was significantly lower on days 7, 14 and 19 in SP-treated wounds, as compared to control group. (B) mRNA expressions of IL-10 in different groups on various days. The IL-10 mRNA expression was markedly lower in control wounds, as compared to others. The mRNA expressions were normalized by  $\beta$ -actin at each time point and data are expressed as means  $\pm$  SEM fold change ( $n = 4$ ). (C) The TNF- $\alpha$  levels in different groups on various days and significantly lower levels on days 7, 14 and 19 in SP-treated wounds supports the mRNA results. (D) The IL-10 levels in different groups on various days and significantly higher levels were found on days 7, 14 and 19 in SP-treated wounds, as compared to control group. Data are expressed as means  $\pm$  SEM ( $n = 5$ ). \* $p < 0.05$ , \*\* $p < 0.01$  and \*\*\* $p < 0.001$  vs other group(s) on the same day.

random fields (40 $\times$ ) from different sections in each group were evaluated and scoring was done according to the method of Greenhalgh et al. [19] with some modifications. Briefly, scoring for each field was done from 1 to 15. The fields showing none to very less amount of inflammatory cell accumulation and granulation tissue were scored from 1 to 3. Score of 4–6 was given to the fields showing thin immature granulation tissue, which was dominated by inflammatory cells, few fibroblasts, blood vessels and collagen deposition. Score of 7–9 was assigned to the fields which showed moderate thick granulation tissue dominated by more fibroblasts and collagen deposition, more neovascularization, minimal to moderate epithelial layer formation and few inflammatory cells. Score of 10–12 was given to thick, vascular granulation tissue, which was dominated by fibroblasts with extensive extracellular collagen deposition and enveloped by partially immature to completely formed epithelial layer. Scoring 13–15 was given to the fields showing thick mature granulation tissue dominated by compact collagen deposition parallel to the well formed complete epithelial layer and decreased fibroblasts and blood vessels to normal.

### 2.9. Immunohistochemistry for CD31 and growth associated protein-43 (GAP-43)

Sections were immunostained for CD31 for neovascularization and GAP-43 for axonal regeneration by incubating with respective

primary mouse monoclonal antibody (Novus Biologicals, Littleton, CO, USA) and HRP-conjugated goat anti mouse IgG (Santa Cruz Biotechnology). The aminoethylcarbazole (AEC) was used as chromogen substrate (AEC Staining Kit; Sigma-Aldrich, USA). Microphotographs were captured (Leica DFC450C) and twenty random fields were observed (40 $\times$ ) for the semi-quantitative analysis of microvessel density (MVD). However, thirty fields were observed (40 $\times$ ) for the quantification of GAP-43 positive nerve fibers.

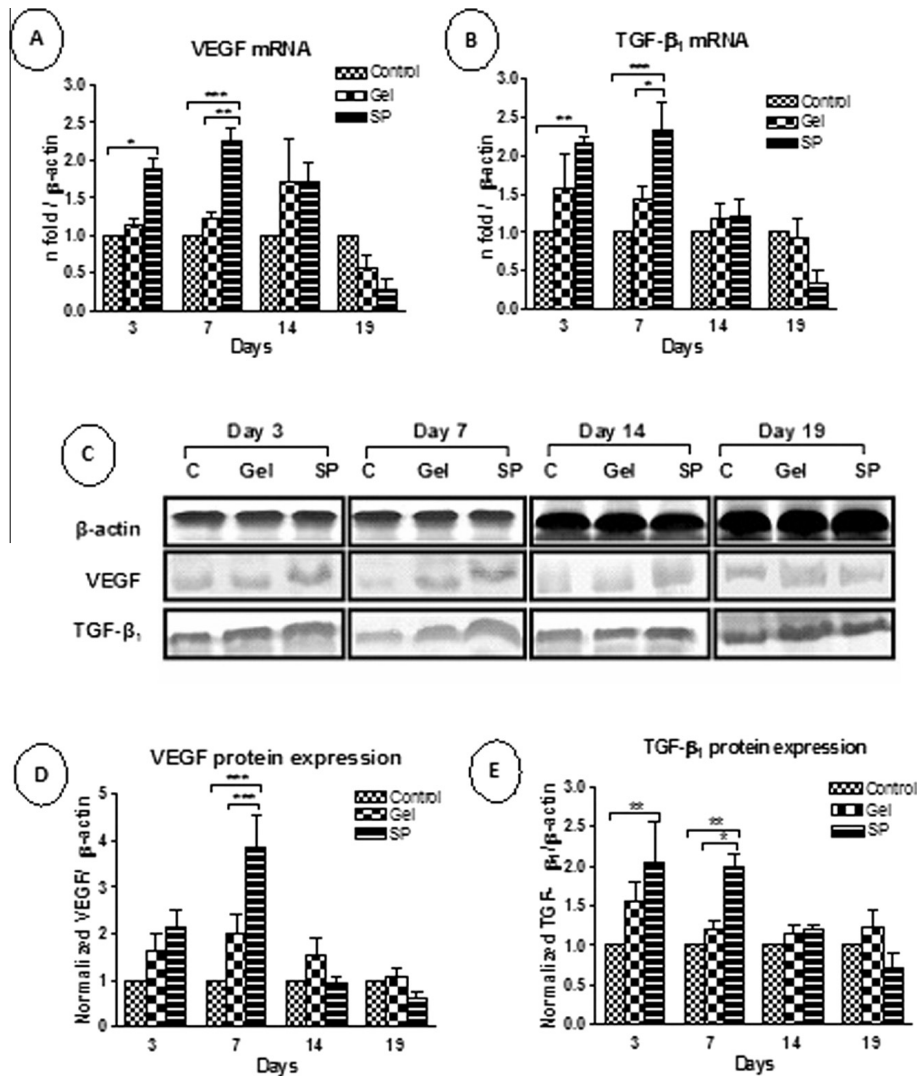
### 2.10. Picrosirius red staining

Assessment of collagen in wound sections was done by staining with picrosirius red (Direct Red 80, Sigma Aldrich, USA) by modified picrosirius procedure [20]. Stained sections were viewed under polarized light (Leica DM2500P) and quantitative study of images for total collagen fraction was done in eight random images (20 $\times$ ) from each group by using ImageJ software.

### 2.11. Statistical analysis

All data are expressed as mean  $\pm$  standard error and data were analyzed by two way analysis of variance (ANOVA) followed by Bonferroni's post test using the GraphPad Prism v4.03 software program (San Diego, CA, USA), and the statistically significant differences were considered at  $p < 0.05$ .





**Fig. 3.** Effect of substance P (SP) on mRNA and protein expressions of VEGF and TGF- $\beta_1$ . (A) and (B) The mRNA expressions of VEGF and TGF- $\beta_1$ , respectively, in different groups on various days. The VEGF and TGF- $\beta_1$  mRNA expressions were significantly increased on days 3 and 7 in SP-treated wounds. The mRNA expressions were normalized by  $\beta$ -actin at each time point and data are expressed as means  $\pm$  SEM fold change ( $n = 4$ ). (C) Representative Western blots of  $\beta$ -actin, VEGF and TGF- $\beta_1$  from the homogenate samples of control (c), gel- and SP-treated rats on days 3, 7, 14 and 19 post-wounding. (D) and (E) The semiquantitative protein expressions of VEGF and TGF- $\beta_1$  in wounds of different groups on various days. The VEGF expression was significantly higher on day 7 and TGF- $\beta_1$  expression was higher on days 3 and 7 in SP-treated wounds. The increased expression of these proteins supports the mRNA results. The values of each protein expressions were corrected for corresponding  $\beta$ -actin for the expression as normalized protein levels. Data are expressed as means  $\pm$  SEM ( $n = 4$ ). \* $p < 0.05$ , \*\* $p < 0.01$  and \*\*\* $p < 0.001$  vs other group(s) on the same day.

### 3. Results

The animals used in the present study showed the signs of the diabetes from second day after administration of streptozotocin. The blood glucose levels significantly increased in all the groups after 48 h of administration of streptozotocin and the levels remained significantly elevated during the entire experiment (Table 2). Other signs like loss of body weight, polyphagia, polydipsia, polyuria, increased ocular discharge and paraphimosis with bluish coloration of glans penis were also observed.

Grossly, healing of wound was better in SP-treated group, which was evidenced by early formation and shedding of scab. Well formed and thick red granulation tissue was also distinguishable in SP-treated rats at the time of tissue collection particularly on days 3 and 7 post-wounding.

#### 3.1. Wound closure

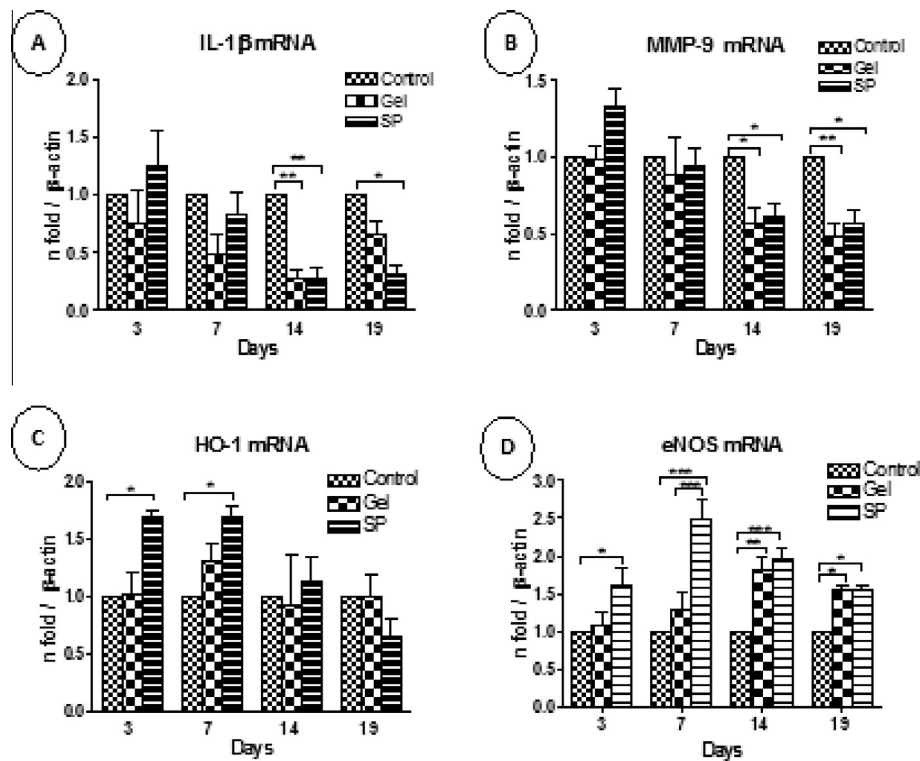
Gross evaluation of wound revealed that topical application of SP decreased the wound size (Fig. 1A) with significantly increased

per cent wound contraction (Fig. 1B), as compared to other groups. The mean per cent wound contraction of SP-treated group was markedly more from control and gel-treated group on day 7 and this difference continued till day 19 after wound creation. The gel-treated group also showed significantly increased wound contraction on day 11 and 14, as compared to control.

#### 3.2. mRNA expressions and protein expressions/levels of TNF- $\alpha$ , IL-10, VEGF and TGF- $\beta_1$

Relative mRNA expression of TNF- $\alpha$  significantly decreased in SP- and gel-treated groups on days 7, 14 and 19 post-wounding, as compared to control (Fig. 2A). TNF- $\alpha$  levels were lower in SP-treated group on days 7, 14 and 19 (Fig. 2C). The mRNA expression of IL-10 did not increase markedly in gel- and SP-treated groups (Fig. 2B). However, IL-10 levels increased significantly in SP-treated group on days 7, 14 and 19, as compared to control (Fig. 2D).

VEGF mRNA expression was markedly higher in SP-treated group on day 3 and 7, as compared to control (Fig. 3A). VEGF



**Fig. 4.** Effect of substance P (SP) on mRNA expressions of IL-1 $\beta$ , MMP-9, HO-1 and eNOS. (A) and (B) The mRNA expressions of IL-1 $\beta$  and MMP-9, respectively, in different groups on various days. The IL-1 $\beta$  and MMP-9 expressions were significantly lesser in SP- and gel-treated group on days 14 and 19, as compared to control. (C) The mRNA expressions of HO-1 in different groups on various days and the HO-1 expression were significantly up-regulated by SP-treated wounds on days 3 and 7, as compared to control. (D) The mRNA expressions of eNOS in different groups on various days and the eNOS expression were significantly higher throughout the experiment in SP-treated group, as compared to control. The mRNA expressions were normalized by  $\beta$ -actin at each time point and data are expressed as means  $\pm$  SEM fold change ( $n = 4$ ). \* $p < 0.05$ , \*\* $p < 0.01$  and \*\*\* $p < 0.001$  indicate significant difference compared with other group(s) on the same day.

protein expression was significantly ( $p < 0.001$ ) higher in SP-treated group on day 7, as compared to control and gel-treated rats (Fig. 3D). mRNA expression of TGF- $\beta_1$  was significantly up-regulated on days 3 and 7 in SP-treated group (Fig. 3B). The TGF- $\beta_1$  protein expression (Fig. 3E) was also increased significantly in SP-treated group on days 3 and 7.

### 3.3. mRNA expression of IL-1 $\beta$ , MMP-9, HO-1 and eNOS

The mRNA expression of IL-1 $\beta$  (Fig. 4A) and MMP-9 (Fig. 4B) were significantly decreased on days 14 and 19 in SP-treated group, as compared to control. Moreover, the mRNA expression of HO-1 was significantly increased on day 3 and 7 in SP group (Fig. 4C). The expression of eNOS was significantly higher in SP-treated group during the entire experiment (Fig. 4D).

### 3.4. H & E staining

The representative images of H & E-stained wound sections are presented in Fig. 5A (40 $\times$ ) and inset boxes represent lower magnification (10 $\times$ ). On day 3, SP-treated wounds comparatively showed more fibroblast with few inflammatory cells. On day 7, in control group, lower part of wound area covered by fibro fatty connective tissue (fat cells) and superficial area showed marked inflammatory changes within proliferative fibrous tissue. However, in SP-treated group, wound area covered by well formed granulation tissue with marked proliferation of fibroblasts, and new and well formed capillaries.

On day 14, SP-treated group showed well formed granulation tissue with collagen deposition and covered by newly formed epithelial layer. Whereas, control group still showed presence

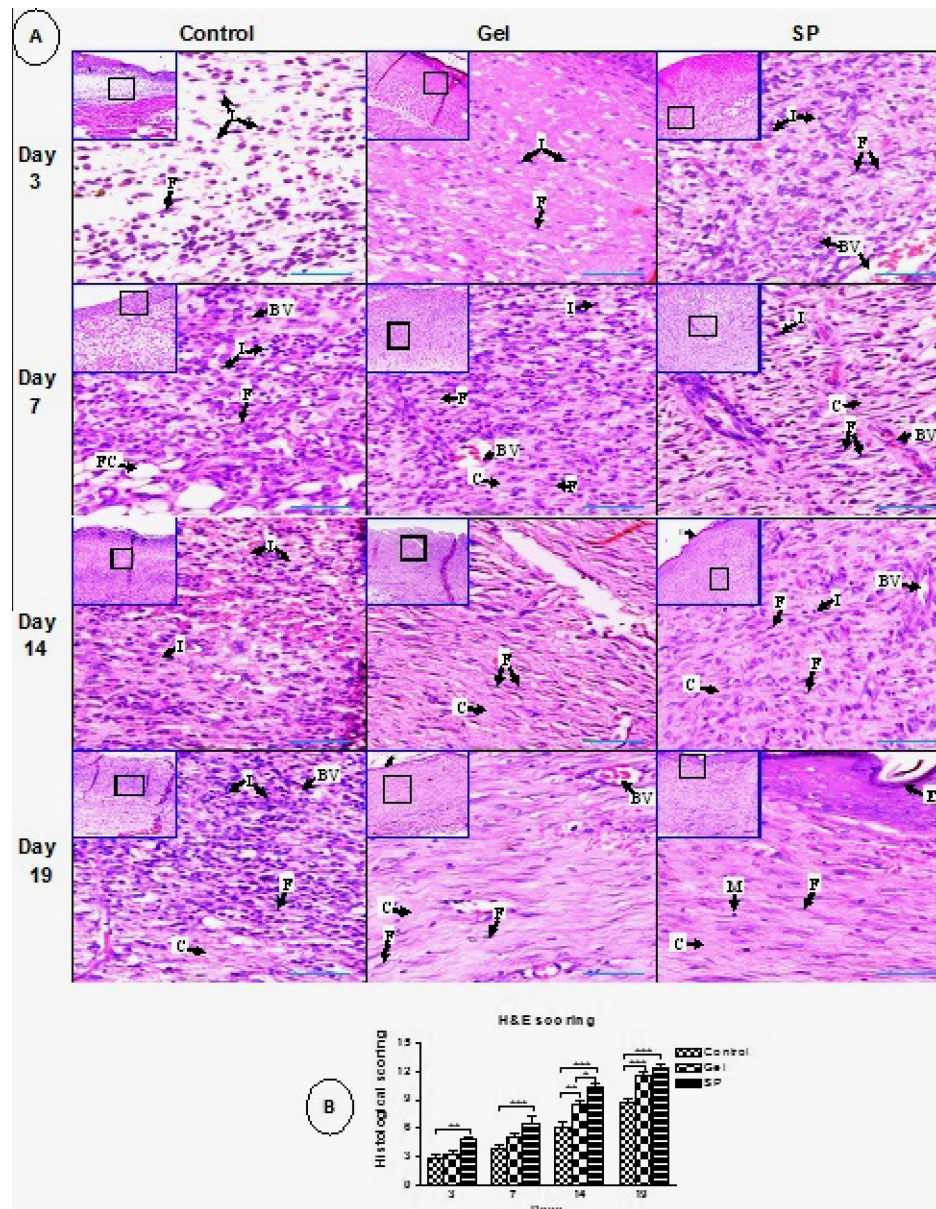
of marked inflammatory cells. On day 19, in SP-treated group, wound area covered by fibroblasts with compact well oriented collagen deposition and few macrophages. There was formation of complete and thick regenerated epithelial layer covering the healed tissue. The wound area of control group still showed prominent inflammatory reaction in upper part, whereas, lower part showed granulation tissue with collagen deposition. Gel-treated group depicted wound area enclosed by fibroblasts with prominent collagen deposition and covered by superficial epithelial layer. Histological scoring revealed significantly higher score of SP-treated group, as compared to other groups (Fig. 5B).

### 3.5. Neovascularization at wound site by immunostaining for CD31

The representative images of CD31-positive vessels are presented in Fig. 6A (40 $\times$ ) and inset boxes correspond to lower magnification (10 $\times$ ). The neovascularization was greater and better in SP-treated group, whereas, newly forming blood vessels were uniformly distributed within granulation tissue with well marked lumen of the vessels and large perimeter. However, in other groups, particularly in control group, the neovascularization was uneven, aberrant and frustrated in nature. The lumen of the vessels was not well marked and vascular occlusion was observed. The microvessel density in SP-treated group was significantly increased on days 3, 7 and 14, and decreased on day 19 (Fig. 6B).

### 3.6. GAP-43 positive nerve fibers

The representative images of GAP-43 positive fibers are presented in Fig. 7A (40 $\times$ ). The positive fibers were more in the vessels



**Fig. 5.** Effect of substance P (SP) on histological changes in the granulation/healing tissues on days 3, 7, 14 and 19 post-wounding. (A) Representative images of H & E stained wound sections of different groups on days 3, 7, 14 and 19 post-wounding (40 $\times$  magnification and scale bar 50  $\mu$ m). Low magnification (10 $\times$ ) images of wounds are shown in inset boxes in the left upper corner. SP-treated wounds comparatively showed more fibroblast with few inflammatory cells on day 3. On day 7, wounds of SP-treated group were covered by well formed granulation tissue with marked proliferation of fibroblasts, and new and well formed capillaries. However, in control group, inflammatory changes were observable within proliferative fibrous tissue in superficial area. On day 14, SP-treated group showed well formed granulation tissue with collagen deposition and covered by newly formed epithelial layer, as compared to marked presence of marked inflammatory cells in control group. On day 19, wound area of SP-treated group showed presence of fibroblasts with compact collagen deposition, and complete and thick regenerated epithelial layer covering the healed tissue was also evident. However, the wound area of control group still showed prominent inflammatory reaction in upper part, whereas, lower part showed granulation tissue with collagen deposition. I: inflammatory cells; F: fibroblasts; BV: blood vessels; FC: fat cells; C: collagen; E: epithelial layer. (B) Histological scoring of H & E stained wound sections. Histological scoring revealed significantly higher score of SP-treated group, as compared to other groups. The data expressed are an average means  $\pm$  SEM ( $n = 10$ ). \* $p < 0.05$ , \*\* $p < 0.01$  and \*\*\* $p < 0.001$  indicate significant difference compared with other group(s) on the same day.

and hypodermis. The quantification revealed more GAP-43 positive fibers in SP-treated group and number was significantly higher on day 14 (Fig. 7B).

### 3.7. Collagen synthesis and deposition

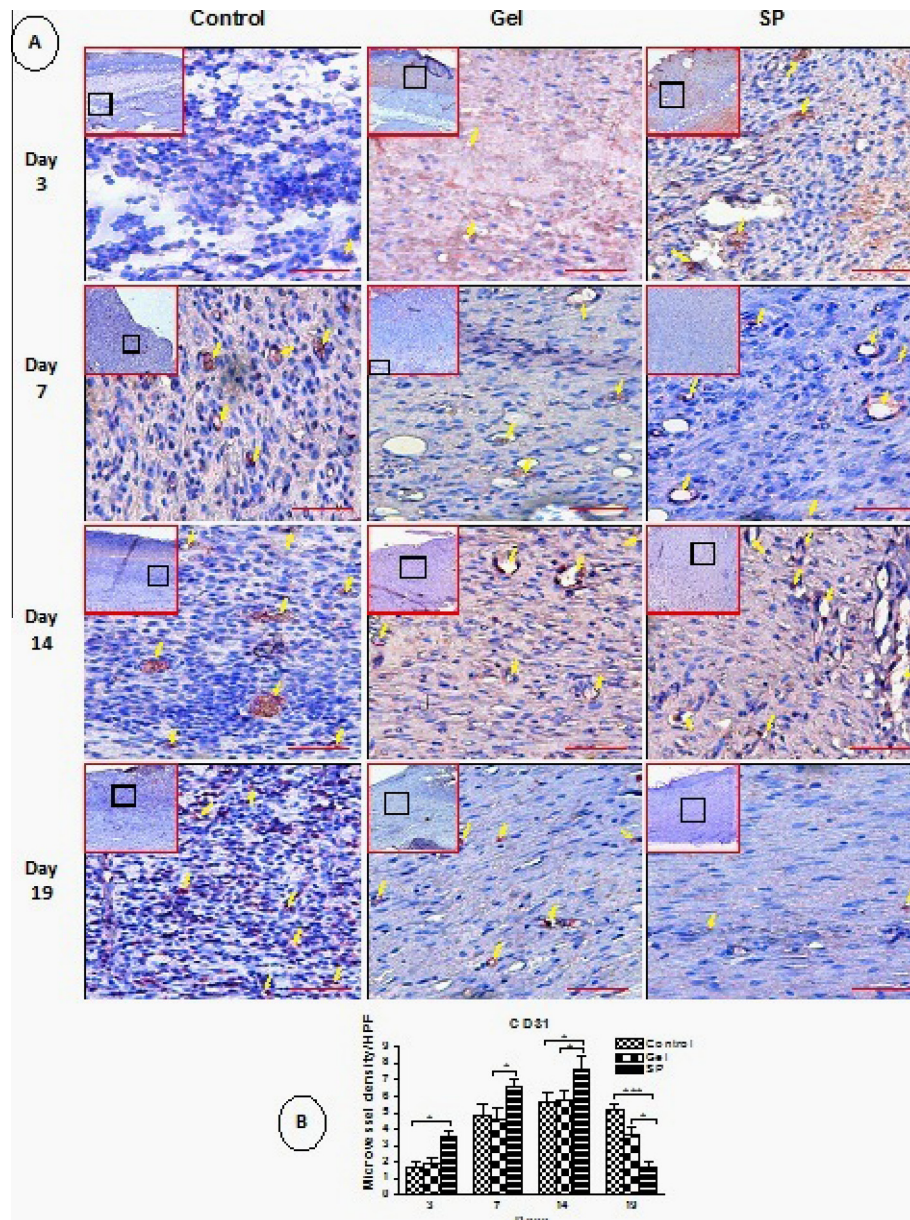
The representative pictures of picrosirius red stained sections are shown in Fig. 8A. The collagen fraction (%) increased in all the three groups in time-dependent manner with no significant difference between groups (Fig. 8B). Apparently, synthesis, deposition, compactness, orientation and organization of collagen were

much better in SP-treated wounds, as compared to other groups on respective days.

## 4. Discussion

The findings of our study showed markedly decreased expression/levels of TNF- $\alpha$ , IL-1 $\beta$  and MMP-9 and increase IL-10 levels in SP-treated group in comparison to control group. SP also increased the expressions of VEGF, TGF- $\beta$ 1, SDF-1 $\alpha$ , HO-1 and eNOS. In addition, histologically better granulation tissue with marked fibroblast proliferation, increased MVD, compact collagen





**Fig. 6.** Effect of substance P (SP) on neovascularogenesis at wound site on different days of treatment. (A) Representative immunohistochemical CD31 stained wound sections of control, gel-treated and SP-treated rats [40 $\times$  magnification and scale bar 50  $\mu$ m; low magnification (10 $\times$ ) images are in inset boxes]. The newly forming blood vessels were uniformly distributed within granulation tissue with well marked lumen of the vessels and large perimeter in SP-treated wounds. However, in other groups, particularly in control group, the neovascularization was uneven, aberrant and frustrated in nature. The lumen of the vessels was not well marked and vascular occlusion was observed in control group. (B) Semiquantitative analysis of microvessel density (MVD) ( $n = 20$ ). MVD was assessed by counting the number of CD31 positive microvessels in high-power fields (HPFs) (40 $\times$ ). The MVD in SP-treated group was significantly increased on days 3, 7 and 14, and decreased on day 19. The data expressed are an average means  $\pm$  SEM,  $n = 20$ . \* $p < 0.05$ , and \*\*\* $p < 0.001$  indicate significant difference compared with other group(s) on the same day.

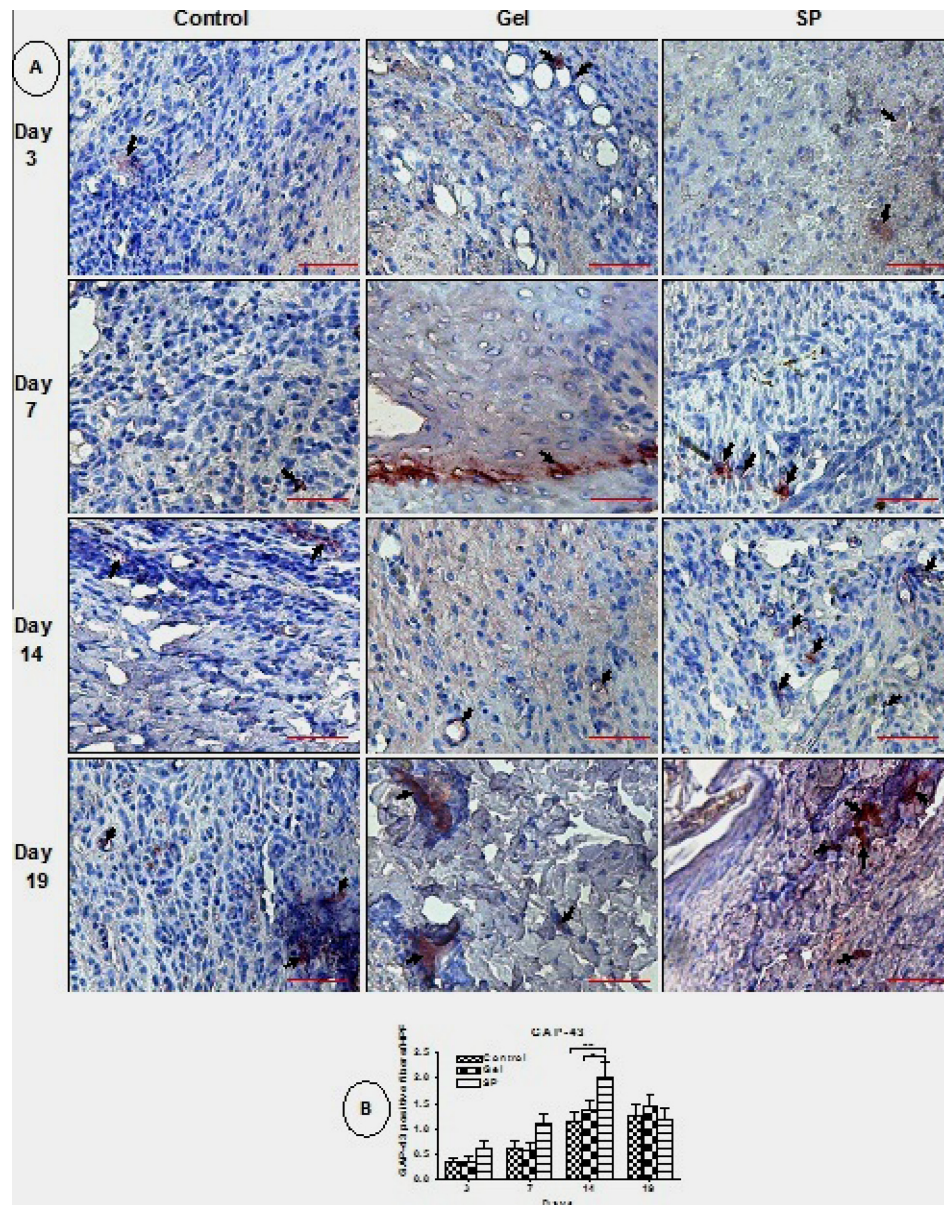
deposition and complete regenerated epithelial layer were evidenced in SP-treated group. The results are suggestive of significantly better wound closure in SP-treated rats. Progressively, better wound closure is duly represented by the photographs (Fig. 1A).

Normal wound healing process gets impaired in diabetes due to the alterations in interaction between cytokines and neuropeptides [21]. Hyperglycemia has been found to interrupts the action of vital inflammatory mediators in wound healing [21] and persistent inflammation is responsible for delay in granulation tissue formation and failure of wound closure in diabetes [22,23]. In order to evaluate the effect of once daily topical application of SP on persistent inflammation, we measured the expressions/levels of TNF- $\alpha$ ,

IL-1 $\beta$  and MMP-9 in the granulation/healing tissues of diabetic rats on different days. SP caused marked reduction in the expression/levels of TNF- $\alpha$  (Fig. 2A and C), IL-1 $\beta$  (Fig. 4A) and MMP-9 (Fig. 4B) on days 14 and 19 post-wounding, which suggests the marked reduction of inflammatory state at wound site, as compared to control.

Macrophages play a pivotal role in wound healing due to their capacity to produce inflammatory cytokines and growth factors [24,25]. The macrophages should change their phenotype from M1 (pro-inflammatory in nature and produce more TNF- $\alpha$ , IL-1 $\beta$ , IL-6, or IL-12) to M2 (anti-inflammatory/angiogenic in nature and are prominent source of TGF- $\beta$ ) during the normal healing process [26–28]. So, the failure in switching of M1 to





**Fig. 7.** Effect of substance P (SP) on axonal regeneration. (A) Representative immunohistochemical GAP-43 stained wound sections ( $40\times$  magnification and scale bar  $50\ \mu\text{m}$ ). The positive fibers were more in the vessels and hypodermis region in SP-treated group. (B) Semiquantitative analysis of GAP-43 positive nerve fibers in random high-power fields (HPFs) ( $40\times$ ). The quantification revealed that the number of GAP-43 positive fibers was significantly higher on day 14 in SP-treated group. The data expressed are an average means  $\pm$  SEM,  $n = 30$ .  $^*p < 0.05$ ,  $^{**}p < 0.01$  and  $^{***}p < 0.001$  indicate significant difference compared with other group(s) on the same day.

anti-inflammatory/angiogenic M2 macrophages, which is common in diabetic wound, leads to increased expression of TNF- $\alpha$  and decreased expression of IL-10 and results in impaired healing [29–33].

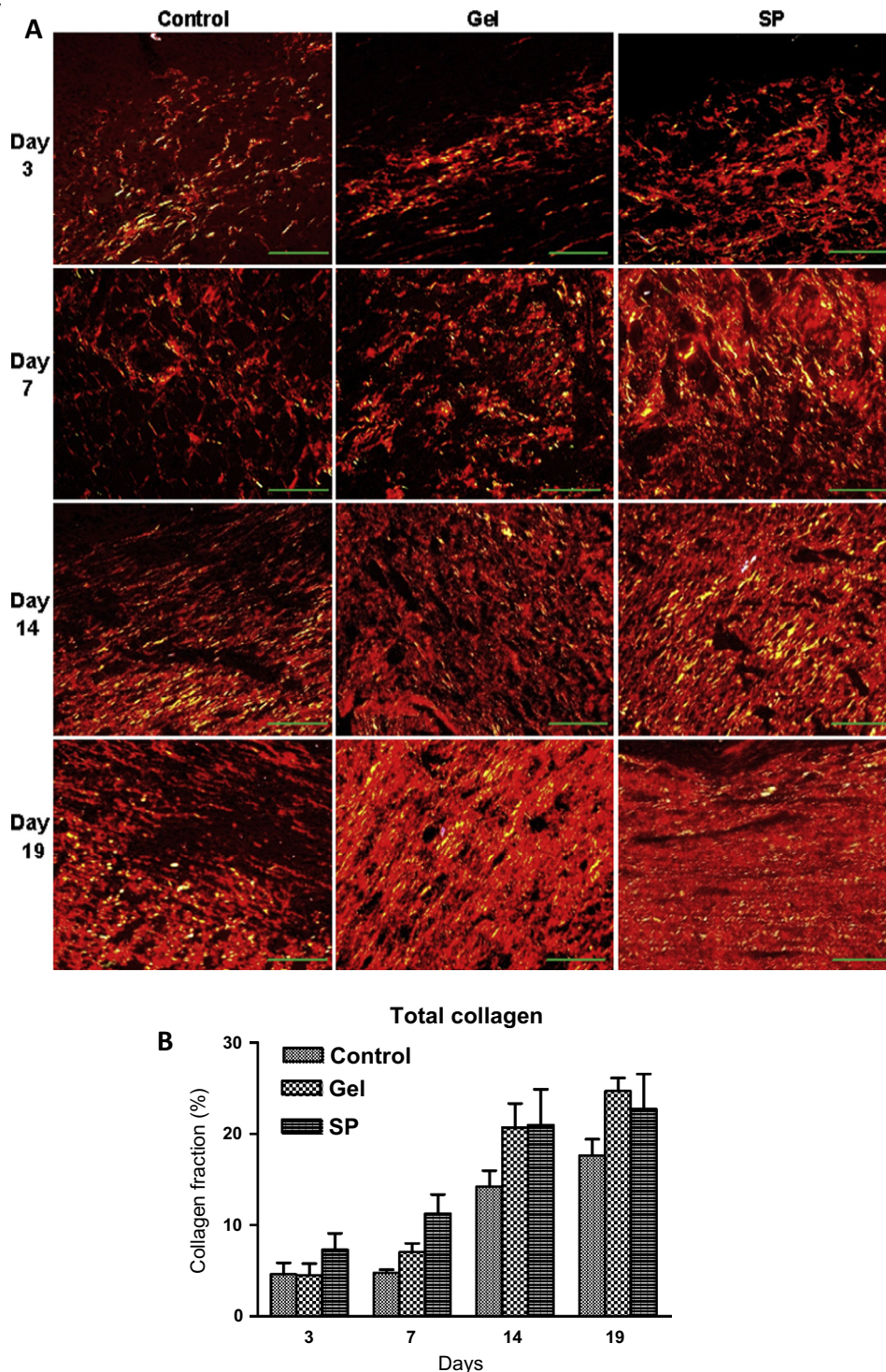
In present study, SP application might caused appropriate switching of the M1 to M2 macrophages, which in turn decreased the expression and levels of TNF- $\alpha$  in SP-treated group, as compared to other group after day 3 post-wounding. So, SP efficiently induces acute inflammation at early stage and reduces it in later stages, which is essential for a good skin repair. This is in agreement with the earlier studies by Leal et al. [34] and Jiang et al. [35].

To further support these effects of SP, we assayed the expression/levels of HO-1, IL-10, and TGF- $\beta_1$ . The expressions of HO-1 (Fig. 4C) and TGF- $\beta_1$  (Fig. 3B and D) were up-regulated by SP on days 3 and 7. However, the levels of IL-10 were increased on days 7, 14 and 19 by SP application (Fig. 2D). HO-1 has been shown as an anti-inflammatory enzyme [36] and SP induces its expression [37].

IL-10 ([38,39] and TGF- $\beta$  [40] also possess anti-inflammatory activity and SP has been shown to increase TGF- $\beta$  [11] and IL-10 [11,41] expressions/levels. Moreover, H & E staining evidently showed that SP markedly and progressively reduce the inflammatory cells at wound site until day 19, as compared to control and gel-treated group (Fig. 5A). These results suggest that SP efficiently abolishes the persistence of inflammatory state at wound site in diabetic rats.

Inhibition of angiogenesis impairs wound healing. VEGF and TGF- $\beta_1$  are involved in stimulation, promotion and stabilization of new blood vessels [42]. VEGF induces angiogenesis by promoting endothelial cell proliferation and prevent their apoptosis [43]. TGF- $\beta$  has also been connected to neovascularization pathways through several mechanisms. It activates the recruitment of VEGF-expressing hematopoietic effector cells, which establishes a potent signaling set-up in inflammatory wound environment that concurrently stimulates neovascularization [44]. Levels of VEGF





**Fig. 8.** Effect of substance P (SP) on collagen synthesis and arrangement. (A) Picosirius red stained histological sections of cutaneous wound showing collagen fibers under polarized light on days 3, 7, 14 and 19 post-wounding in control, gel-treated and SP-treated rats. Collagen formation as well as arrangement was better in the SP-treated group, as compared to other groups on respective days. Scale bar 100  $\mu$ m and magnification 20 $\times$ . (B) Average fraction of total collagen fibers in picosirius red stained histological wound sections of control, gel-treated and SP-treated rats on days 3, 7, 14 and 19 post-wounding. The collagen fraction (%) increased in all the three groups in time-dependent manner with no significant difference between groups. The data expressed are an average means  $\pm$  SEM,  $n = 8$ .

and TGF- $\beta_1$  are found to be decreased in diabetes [45,46]. In the present study, SP significantly increases the expressions of VEGF (Fig. 3A and C) and TGF- $\beta_1$  (Fig. 3B and D), as compared to control and gel-treated group. This supports the appropriate angiogenic response at wound site in SP-treated group. This was supported by the increased MVD at wound site in SP-treated group (Fig. 6B), which was confirmed by the immunohistochemistry of

CD31 (Fig. 6A). However, decreased MVD and abnormal angiogenesis in control diabetic group consequently delayed wound repair in the present study, which is in agreement with the earlier report [47]. Thus, application of SP seems to restore angiogenesis, with increased, evenly distributed and well formed blood vessels.

HO-1 induction is necessary for efficient wound closure in diabetic mice [48] and its role in angiogenesis is by regulating

the synthesis/activity of VEGF and SDF-1 $\alpha$  [49]. So, increased expression of HO-1 in SP-treated group further added to the potential of SP in neovascularization and faster wound healing in diabetic rats. The eNOS and its bioactive product nitric oxide (NO) are also well-established proangiogenic molecules and this endothelial-derived NO is vital for maintenance of proper vasodilatory nature and regulation of an anti-proliferative and anti-apoptotic state for endothelial cells [50]. In consequence, in the present study, the decreased expression of eNOS in control group resulted in reduced and frustrated angiogenesis, which was restored in SP-treated rats. In previous studies, the inhibition or genetic disruption of eNOS has resulted in delayed wound closure [51] and cutaneous eNOS expression has been reported to be significantly decreased in STZ-induced type 1 diabetic animals [52].

The enzymes primarily involved in the degradation of extra cellular matrix (ECM) are the MMPs. Disruption in the synthesis of MMPs and/or alteration in the balance between enzymes and their inhibitors have been shown to cause disorganization of the ECM [53]. Hence, in present study, decreased expression of MMP-9 (Fig. 4B) in the SP-treated group was responsible for well formed ECM and granulation tissue formation. Previous study in diabetics has shown that activation of MMP expression is consistent with a pattern associated with increased degradation of ECM [54]. Additionally, decreased expression of TGF- $\beta$  in control group further added to the increased expression of MMP-9. It has been reported that most MMP genes have TGF- $\beta$  inhibitory elements in their promoter regions and their expression is decreased by TGF- $\beta$  [55].

Contraction speeds up the wound healing [56]. So, increased wound contraction in SP-treated group (Fig. 1B), as compared to control and gel-treated groups on different days, further supports the fast healing in SP-treated rats. Re-epithelialization also increases the wound contraction and in the present study, well formed epithelial layer was present in SP-treated group on day 14 (Fig. 5A). TGF- $\beta$  also has a chemoattractant effect on fibroblasts and stimulates their proliferation [57]. Thus, in present study, increased expression of TGF- $\beta_1$  in SP-treated wound was responsible for the marked proliferation of fibroblasts, which in turn cause more collagen deposition. Collagen deposition is indispensable for granulation tissue formation and it also plays role in re-epithelialization in skin-wound repair process. As evident from H&E (Fig. 5A) as well as picosirius red staining (Fig. 8A) in our study, collagen deposition, organization and orientation were better in SP-treated group. Picosirius red staining also revealed that collagen fraction was more in SP-treated group (Fig. 8B). TNF- $\alpha$  application causes reduction in the expression of collagen, which further decreases the tensile strength of the wound [58]. Also, there is a sharp antagonism among the pro-synthetic role of TGF- $\beta_1$  and the opposite effect of TNF- $\alpha$  in terms of ECM deposition, wound contraction and maturation. TNF- $\alpha$  inhibits Smad phosphorylation through the c-Jun N-terminal kinase (JNK) pathway and reduces the transcription of TGF- $\beta_1$  [59]. Significantly decreased TNF- $\alpha$  and increased TGF- $\beta_1$  in SP-treated group in this study suggest that SP efficiently controlled the balance between TNF- $\alpha$  and TGF- $\beta_1$  for better granulation tissue formation. In agreement to earlier finding [60], the reduced microvessel density and lumen size in SP-treated group on day 19 was due to the deposition of compact and mature collagen fibers which in turn compressed the small blood vessels and reduced their perimeter, so that the endothelial cells go through apoptosis to form the less vascular scar.

Diabetes also contributes to impaired axon sprouting in experimental rat models [61]. GAP-43 is a marker of regeneration and remodeling of the nerve fibers [62,63]. The expression of GAP-43 immunoreactive fibers decreases in diabetic patients

[64]. In the present study, increased expression of GAP-43 positive fibers in SP-treated rats revealed better regeneration and remodeling of the axons.

In conclusion, topical SP treatment caused faster as well as organized healing of cutaneous wounds in diabetic rats. Up-regulation of various angiogenic genes like VEGF, TGF- $\beta_1$ , eNOS and HO-1, and stimulation of proliferative phase with marked fibroblast proliferation and collagen deposition are suggestive of improved healing by SP application. So, SP appears to possess great potential in treating cutaneous wounds in diabetics.

## Acknowledgements

The authors are thankful to the Director, Indian Veterinary Research Institute, Izatnagar, Uttar Pradesh, India, for providing necessary facilities and support for conducting present study and the Council of Scientific & Industrial Research (CSIR), New Delhi, India, for Senior Research Fellowship (Award letter no: 09/563(0091)/2012.EMR-1) to the first author. We are also thankful to the Director, Indian Institutes of Technology (IIT), New Delhi, for providing the facilities of polarized microscopy.

## References

- [1] Alba-Loureiro TC, Hirabara SM, Mendonca JR, Curi R, Pithon-Curi TC. Diabetes causes marked changes in function and metabolism of rat neutrophils. *J Endocrinol* 2006;188:295–303.
- [2] Loomans CJ, de Koning EJ, Staal FJ, Rookmaaker MB, Verseyden C, de Boer HC, et al. Endothelial progenitor cell dysfunction: a novel concept in the pathogenesis of vascular complications of type 1 diabetes. *Diabetes* 2004;53:195–9.
- [3] Gallagher KA, Liu ZJ, Xiao M, Chen H, Goldstein LJ, Buerk DG, et al. Diabetic impairments in NO-mediated endothelial progenitor cell mobilization and homing are reversed by hyperoxia and SDF-1 alpha. *J Clin Invest* 2007;117:1249–59.
- [4] Kunt T, Forst T, Schmidt S, Pflutzner A, Schneider S, Harzer O, et al. Serum levels of substance P are decreased in patients with type 1 diabetes. *Exp Clin Endocrinol Diabetes* 2000;108:164–7.
- [5] Muangman P, Muffley LA, Anthony JP, Spenny ML, Underwood RA, Olerud JE, et al. Nerve growth factor accelerates wound healing in diabetic mice. *Wound Repair Regen* 2004;12:44–52.
- [6] Dunnick CA, Gibran NS, Heimbach DM. Substance P has a role in neurogenic mediation of human burn wound healing. *J Burn Care Rehabil* 1996;17:390–6.
- [7] Pernow B. Substance P. *Pharmacol Rev* 1983;35(2):85–141.
- [8] Vishwanath R, Mukherjee R. Substance P promotes lymphocyte endothelial cell adhesion preferentially via LFA-1/ICAM-1 interactions. *J Neuroimmunol* 1996;71(1–2):163–71.
- [9] Pradhan L, Nabzdyk C, Andersen ND, LoGerfo FW, Veves A. Inflammation and neuropeptides: the connection in diabetic wound healing. *Expert Rev Mol Med* 2009;11:e2.
- [10] Theoharides TC, Zhang B, Kempuraj D, Tagen M, Vasiadi M, Angelidou A, et al. IL-33 augments substance P-induced VEGF secretion from human mast cells and is increased in psoriatic skin. *Proc Natl Acad Sci USA* 2010;107:4448–53.
- [11] Kant V, Gopal A, Kumar D, Bag S, Kurade NP, Kumar A, et al. Topically applied substance P enhanced healing of open excision wound in rats. *Eur J Pharmacol* 2013;715:345–53.
- [12] Benrath J, Zimmerman M, Gillardon F. Substance P and nitric oxide mediate wound healing of ultraviolet photodamaged rat skin: evidence for an effect of nitric oxide on keratinocyte proliferation. *Neurosci Lett* 1995;200:17–20.
- [13] Burssens P, Steyaert A, Forsyth R, van Ovost EJ, Depaeppe Y, Verdonk R. Exogenously administered substance P and neutral endopeptidase inhibitors stimulate fibroblast proliferation, angiogenesis and collagen organization during Achilles tendon healing. *Foot Ankle Int* 2005;26(10):832–9.
- [14] Lindberger M, Daa Schroder H, Schultzberg M, Kristensson K, Persson A, Ostman J, et al. Nerve fibre studies in skin biopsies in peripheral neuropathies. *J Neurol Sci* 1989;93:289–96.
- [15] Gibran NS, Jang YC, Isik FF, Greenhalgh DG, Muffley LA, Underwood RA, et al. Diminished neuropeptide levels contribute to the impaired cutaneous healing response associated with diabetes mellitus. *J Surg Res* 2002;108:122–8.
- [16] Delgado AV, McManus AT, Chambers JP. Exogenous administration of substance P enhances wound healing in a novel skin-injury model. *Exp Biol Med* 2005;230:271–80.
- [17] Kant V, Gopal A, Kumar D, Gopalkrishnan A, Pathak NN, Kurade NP, et al. Topical pluronic F-127 gel application enhances cutaneous wound healing in rats. *Acta Histochem* 2014;116:5–13.
- [18] Livak KJ, Schmittgen TD. Analysis of relative gene expression data using real-time quantitative PCR and the  $2^{-\Delta\Delta CT}$  method. *Methods* 2001;25:402–8.



- [19] Greenhalgh DG, Sprugel KH, Murray MJ, Ross R. PDGF and FGF stimulate healing in the genetically diabetic mouse. *Am J Pathol* 1990;136:1235–46.
- [20] Dayan D, Hiss Y, Hirshberg A, Bubis JJ, Wolman M. Are the polarization colors of picrosirius red-stained collagen determined only by the diameter of the fibers? *Histochemistry* 1989;93:27–9.
- [21] Jain M, Logerfo FW, Guthrie P, Pradhan L. Effect of hyperglycemia and neuropeptides on interleukin-8 expression and angiogenesis in dermal microvascular endothelial cells. *J Vasc Surg* 2011;53:1654–60.
- [22] Wetzler C, Kampfer H, Stallmeyer B, Pfeilschifter J, Frank S. Large and sustained induction of chemokines during impaired wound healing in the genetically diabetic mouse: prolonged persistence of neutrophils and macrophages during the late phase of repair. *J Invest Dermatol* 2000;115:245–53.
- [23] Roth D, Piekarek M, Paulsson M, Christ H, Krieg T, Davidson JM, et al. Plasmin modulates VEGF-A mediated angiogenesis during wound repair. *Am J Pathol* 2006;168:670–84.
- [24] Riches DWH. Macrophage involvement in wound repair, remodeling and fibrosis. In: Clark RAF, editor. *The molecular and cellular biology of wound repair*. New York, London: Plenum; 1996. p. 95–141.
- [25] Engelhardt E, Toksoy A, Goebeler M, Debus S, Brocker EB, Gillitzer R. Chemokines IL-8, Gro $\alpha$ , MCP-1, IP-10, and Mig are sequentially and differentially expressed during phase-specific infiltration of leukocyte subsets in human wound healing. *Am J Pathol* 1998;153:1849–60.
- [26] Daley JM, Brancato SK, Thomay AA, Reichner JS, Albina JE. The phenotype of murine wound macrophages. *J Leukoc Biol* 2010;87:59–67.
- [27] Lucas T, Waisman A, Ranjan R, Roes J, Krieg T, Muller W, et al. Differential roles of macrophages in diverse phases of skin repair. *J Immunol* 2010;184:3964–77.
- [28] Mantovani A, Sica A, Sozzani S, Allavena P, Vecchi A, Locati M. The chemokine system in diverse forms of macrophage activation and polarization. *Trends Immunol* 2004;25:677–86.
- [29] Khanna S, Biswas S, Shang Y, Collard E, Azad A, Kauh C, et al. Macrophage dysfunction impairs resolution of inflammation in the wounds of diabetic mice. *PLoS ONE* 2010;5(3):e9539. <http://dx.doi.org/10.1371/journal.pone.0009539>.
- [30] Mirza R, Koh TJ. Dysregulation of monocyte/macrophage phenotype in wounds of diabetic mice. *Cytokine* 2011;56:256–64.
- [31] Nwomeh BC, Yager DR, Cohen IK. Physiology of the chronic wound. *Clin Plast Surg* 1998;25(3):341–56.
- [32] Goren I, Muller E, Schiefelbein D, Christen U, Pfeilschifter J, Muhl H, et al. Systemic anti-TNF $\alpha$  treatment restores diabetes-impaired skin repair in ob/ob mice by inactivation of macrophages. *J Invest Dermatol* 2007;127:2259–67.
- [33] Lai JJ, Lai KP, Chuang KH, Chang P, Yu IC, Lin WJ, et al. Monocyte/macrophage androgen receptor suppresses cutaneous wound healing in mice by enhancing local TNF- $\alpha$  expression. *J Clin Invest* 2009;119:3739–51.
- [34] Leal EC, Tellechea A, Kuchibhotla S, Auster ME, LoGerfo FW, Pradhan-Nabzyk L, et al. SP regulates macrophage function in diabetic wound healing (Abstract). In: 50th EASD annual meeting. Vienna, Austria; 15th – 19th September 2014. <<http://www.easdvirtualmeeting.org/resources/19395>>.
- [35] Jiang MH, Chung E, Chi GF, Ahn W, Lim JE, Hong HS, et al. Substance P induces M2-type macrophages after spinal cord injury. *NeuroReport* 2012;23(13):786–92.
- [36] Lundvig DM, Immenschuh S, Wagener FA. Hemeoxygenase, inflammation, and fibrosis: the good, the bad, and the ugly? *Front Pharmacol* 2012;3:81.
- [37] Kook YA, Lee SK, Son DH, Kim Y, Kang KH, Cho JH, et al. Effects of substance P on osteoblastic differentiation and heme oxygenase-1 in human periodontal ligament cells. *Cell Biol Int* 2009;33:424–8.
- [38] Moore KW, Waal DE, Malefyt R, Coffman RL, O'garra A. Interleukin-10 and the interleukin-10 receptor. *Annu Rev Immunol* 2001;19:683–765.
- [39] Mosser DM, Zhang X. Interleukin-10: new perspectives on an old cytokine. *Immunol Rev* 2008;226:205–18.
- [40] Roberts AB, Sporn MB, Assoian RK, Smith JM, Roche NS, Wakefield LM, et al. Transforming growth factor- $\beta$ : rapid induction of fibrosis and angiogenesis in vivo and stimulation of collagen formation in vitro. *Proc Natl Acad Sci USA* 1986;83:4167–71.
- [41] Jiang MH, Chung E, Chi GF, Ahn W, Lim JE, Hong HS, et al. Substance P induces M2-type macrophages after spinal cord injury. *NeuroReport* 2012;23:786–92.
- [42] Johnson KE, Wilgus TA. Multiple roles for VEGF in non-melanoma skin cancer: angiogenesis and beyond. *J Skin Cancer* 2012. 6 pages, Article ID 483439.
- [43] Ferrara N. Role of vascular endothelial growth factor in regulation of physiological angiogenesis. *Am J Physiol Cell Physiol* 2001;280:C1358–66.
- [44] Fang S, Pentimikko N, Ilmonen M, Salven P. Dual action of TGF- $\beta$  induces vascular growth in vivo through recruitment of angiogenic VEGF-producing hematopoietic effector cells. *Angiogenesis* 2012;15:511–9.
- [45] Rivard A, Silver M, Chen D, Kearney M, Magner M, Annex B, et al. Rescue of diabetes-related impairment of angiogenesis by intramuscular gene therapy with adeno-VEGF. *Am J Pathol* 1999;154:355–63.
- [46] Al-Mulla F, Leibovich SJ, Francis IM, Bitar MS. Impaired TGF- $\beta$  signaling and a defect in resolution of inflammation contribute to delayed wound healing in a female rat model of type 2 diabetes. *Mol Biosyst* 2011;7:3006–20.
- [47] Martin A, Komada MR, Sane DC. Abnormal angiogenesis in diabetes mellitus. *Med Res Rev* 2003;23:117–45.
- [48] Grochot-Przeczek A, Lach R, Mis J, Skrzypek K, Gozdecka M, Sroczyńska P, et al. Heme oxygenase-1 accelerates cutaneous wound healing in mice. *PLoS ONE* 2009;4:e5803.
- [49] Lin HH, Chen YH, Chang PF, Lee YT, Yet SF, Chau LY. Heme oxygenase-1 promotes neovascularization in ischemic heart by co-induction of VEGF and SDF-1. *J Mol Cell Cardiol* 2008;45:44–55.
- [50] Yu J, deMunck ED, Zhuang Z, Drinane M, Kauser K, Rubanyi GM, et al. Endothelial nitric oxide synthase is critical for ischemic remodeling, mural cell recruitment, and blood flow reserve. *Proc Natl Acad Sci USA* 2005;102:10999–1004.
- [51] Lee PC, Salyapongse AN, Bragdon GA, Shears LL, Watkins SC, Edington HD, et al. Impaired wound healing and angiogenesis in eNOS-deficient mice. *Am J Physiol Heart Circ Physiol* 1999;277:H1600–8.
- [52] Luo JD, Wang YY, Fu W, Wu J, Chen AF. Gene therapy of eNOS and MnSOD restores delayed wound healing in type 1 diabetic mice. *Circulation* 2004;110(16):2484–93.
- [53] Nalbong G, Alessi MC, Juhan-Vague I. Systèmefibrinolytique, metalloproteases et pathologievasculaire. *Medecine/Sciences* 2001;17:170–6.
- [54] Wall SJ, Bevan D, Thomas DW, Harding KG, Edwards DR, Murphy G. Differential expression of matrix metalloproteinases during impaired wound healing of the diabetes mouse. *J Invest Dermatol* 2002;119(1):91–8.
- [55] McLennan SV, Death AK, Fisher EJ, Williams PF, Yue DK, Turtle JR. The role of the mesangial cell and its matrix in the pathogenesis of diabetic nephropathy. *Cell Mol Biol* 1999;45:123–35.
- [56] Bae SH, Bae YC, Nam SB, Choi SJ. A skin fixation method for decreasing the influence of wound contraction on wound healing in a rat model. *Arch Plast Surg* 2012;39(5):457–62.
- [57] Lal BK, Saito S, Pappas PJ, Padberg Jr FT, Cerveira JJ, Hobson RW. Altered proliferative responses of dermal fibroblasts to TGF- $\beta$  may contribute to chronic venous stasis ulcer. *J Vasc Surg* 2003;37:1285–93.
- [58] Salomon GD, Kasid A, Cromack DT, Director E, Talbot TL, Sank A, et al. The local effects of cachectin/tumor necrosis factor on wound healing. *Ann Surg* 1991;214:175–80.
- [59] Goldberg MT, Han YP, Yan C, Shaw MC, Garner WL. TNF- $\alpha$  suppresses alpha-smooth muscle actin expression in human dermal fibroblasts: an implication for abnormal wound healing. *J Invest Dermatol* 2007;127:2645–55.
- [60] Ribeiro MA, Albuquerque RL, Ramalho LM, Pinheiro AL, Bonjardim LR, Da Cunha SS. Immunohistochemical assessment of myofibroblasts and lymphoid cells during wound healing in rats subjected to laser photobiomodulation at 660 nm. *Photomed Laser Surg* 2009;27:49–55.
- [61] Bisby MA. Axonal transport of labeled protein and regeneration rate in nerves of streptozocin-diabetic rats. *Exp Neurol* 1980;69:74–84.
- [62] Rage M, van Acker N, Facer P, Shenoy R, Knaapen MWM, Timmers M, et al. The timecourse of CO $_2$  laser-evoked responses and of skin nerve fibre markers after topical capsaicin in human volunteers. *Clin Neurophysiol* 2010;121:1256–66.
- [63] Verze L, Parainfo A, Ramieri G, Viglietti-Panzica C, Panzica GC. Immunocytochemical evidence of plasticity in the nervous structures of the rat lower lip. *Cell Tissue Res* 1999;297:203–11.
- [64] Bursova S, Dubovy P, Vlckova-Moravcova E, Nemeč M, Klusakova I, Belobradkova J, et al. Expression of growth-associated protein 43 in the skin nerve fibers of patients with type 2 diabetes mellitus. *J Neurol Sci* 2012;315:60–3.