

## Case Report

# Safe use of Sunitinib in metastatic non-clear cell renal cell cancer in the setting of human immunodeficiency virus

Govender P. S.\* and Abdel Goad E. H.

P. O. Box 3019, Sunningdale, Durban, 4019 South Africa.

Accepted 19 October, 2011

**The introduction of targeted therapies has offered the promise of better survival outcomes for patients with metastatic renal cell carcinoma. Sunitinib malate, an oral, multitargeted tyrosine kinase inhibitor, is an important treatment option for patients with metastatic renal cell carcinoma. This case study explores the controversial use of sunitinib in a patient with a non-clear cell variant of renal cell carcinoma, also on treatment with combined antiretroviral treatment for a co-existing human immunodeficiency virus infection.**

**Key words:** Sunitinib, non-clear cell metastatic renal cell carcinoma, human immunodeficiency virus and antiretroviral treatment.

## INTRODUCTION

Metastatic renal cell carcinoma (mRCC) has historically been a challenging disease demonstrating resistance to radiotherapy, chemotherapy, and hormonal therapy. Until recently, the only treatments available were the cytokines, interferon- $\alpha$ , and interleukin-2. There has been notable progress in the management and treatment of mRCC with the recent development and introduction of targeted therapies (Mulders, 2008).

A useful management strategy dictates that patients with mRCC are categorised according to tumour histology and risk status: clear cell or non-clear cell renal cell carcinoma (RCC); and favourable, intermediate or poor Memorial Sloan-Kettering Cancer Center (MSKCC) risk profile (Schmidinger and Zielinski, 2009).

The role of the von Hippel-Lindau (VHL) gene in regulating proangiogenic factors has resulted in the development of several targeted agents, including sunitinib (Choueiri et al., 2008). Sunitinib inhibits receptor tyrosine kinases (all vascular endothelial growth factor receptors [VEGF 1, 2, 3] and other tyrosine kinase receptors such as platelet-derived growth factor receptor [PDGFR]- $\alpha$  and  $\beta$ , c-KIT, RET, FLT-3) by binding

to the intracellular signalling region of the receptor (Schmidinger and Zielinski, 2009).

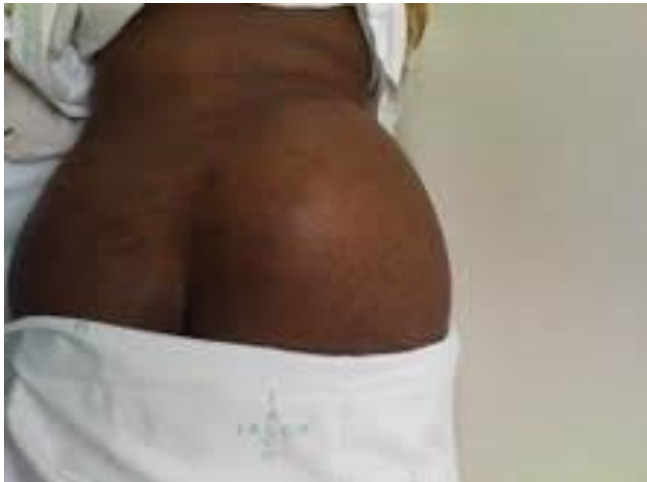The efficacy of Sunitinib in patients with favourable/intermediate risk profile clear cell mRCC was demonstrated in a pivotal phase 3 study. This trial demonstrated superior clinical efficacy for sunitinib as compared to IFN- $\alpha$  in treatment-naïve patients with advanced RCC, resulting in sunitinib approval in the first-line setting for the treatment of mRCC (Mulders, 2008).

The most common adverse effects reported in patients receiving first-line sunitinib, were diarrhoea (53%), fatigue (51%), nausea (44%), stomatitis (25%), vomiting (24%), hypertension (24%), and hand-foot syndrome (20%) (Négrier and Revaud, 2007).

The clear cell histological subtype constitutes more than 80% of all RCC's. Papillary RCC and chromophobe RCC represent the most common remaining histologic subtypes with an incidence of 7 to 14% and 6 to 11%, respectively. There is insufficient data regarding the activity of sunitinib and sorafenib in advanced non-clear cell RCC because recent trials were mostly restricted to clear cell RCC patients (Choueiri et al., 2008).

The scourge of human immunodeficiency virus (HIV) in South Africa has had a profound impact on the healthcare system and has also compounded the management of malignancies co-existing with HIV. The

\*Corresponding author. E-mail: [poovan.gov@gmail.com](mailto:poovan.gov@gmail.com).



**Figure 1.** Clinical examination showing a soft abdomen with no palpable renal masses.

total number of persons living with HIV in South Africa increased from an estimated 4.1 million in 2001 to 5.2 million by 2009. For 2009, an estimated 10.6% of the total population is HIV positive (Statistics, 2009).

Treatment of malignancies with combined antiretroviral treatment (cART) is often complicated by potential pharmacokinetic and pharmacodynamic drug interactions (Mounier et al., 2009). This is an important consideration for clinicians administering anti-neoplastic therapy concomitantly with cART.

We present the first reported case of non-clear cell mRCC in a HIV-infected patient on cART, treated with sunitinib.

## CASE HISTORY

A 54 year old female was referred to us with a 6 month history of a right buttock mass.

She was previously diagnosed with a renal cell carcinoma pT1bNxM0 in 2003. An open right radical nephrectomy was performed. Histology demonstrated a 6-cm chromophobe type tumour, Fuhrman Grade 3, in the lower pole of the right kidney with no renal vein invasion or extension of the tumour through the capsule. Enquiry into her co-morbid history revealed her to be HIV positive on cART (efavirenz, lamivudine and stavudine).

Clinical examination showed a soft abdomen with no palpable renal masses. She had a large mass occupying the entire right buttock (Figure 1).

Biopsy of the right buttock revealed features consistent with mRCC. Her baseline CD4 count was 206 cells /ul. Thyroid function tests, blood pressure and electrocardiogram (ECG) readings were within normal limits.

Sunitinib has been made available to financially deserving patients with mRCC in South Africa via an

expanded access programme (EAP). Our inability to access biological agents other than sunitinib in the public healthcare sector has resulted in patients not being routinely stratified into risk groups based on the Memorial Sloan-Kettering Cancer Center (MSKCC) risk model; hence serum calcium and serum lactate dehydrogenase levels were not done.

The fluorodeoxyglucose-positron emission tomography/computerised tomography (FDG-PET/CT) scan demonstrated a large mass in the right gluteal muscle infiltrating the right hemipelvis, sacrum and L5 vertebral body, consistent with metastatic recurrence of the renal cell carcinoma (Figure 2).

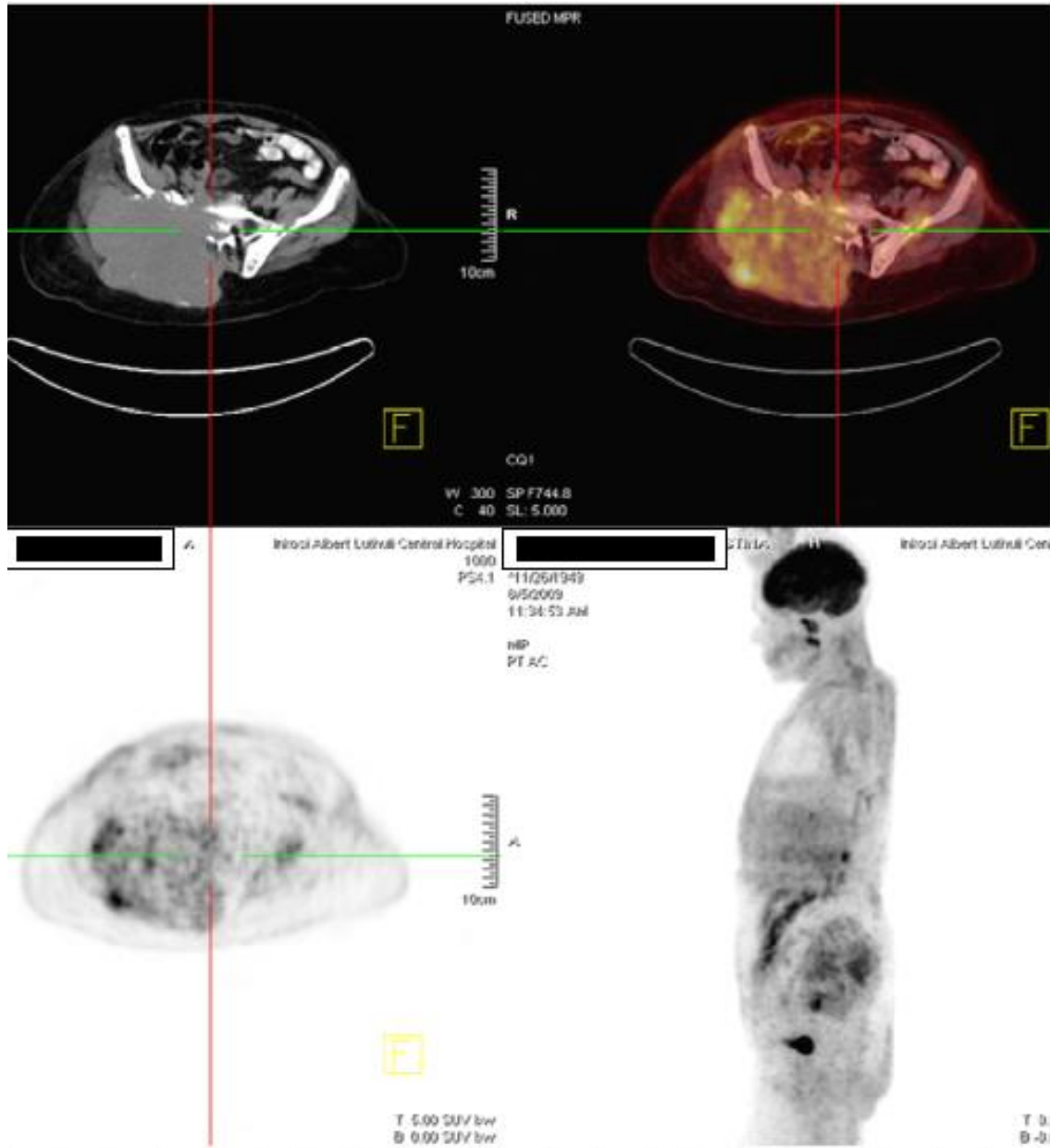
The patient was initially commenced on Interferon- $\alpha$  10 million units subcutaneously, daily from Monday to Friday. She experienced intolerable adverse effects after one month of therapy. She was then enrolled on the sunitinib EAP. She was started at a dose of 50 mg daily per os on a schedule of 4 weeks on treatment, followed by 2 weeks off. The drug was well tolerated with only Grade 1 (mild) fatigue reported while on treatment. There was also no decrement in her CD4 count noted during treatment.

Clinical assessment of treatment response using the right buttock mass as measurable disease demonstrated stable disease that lasted for 9 months. On disease progression she received palliative radiotherapy to the buttock mass (3000 cGy in 2 Gy fractions) with satisfactory local symptom relief reported on completion of treatment. The patient was then managed symptomatically.

## DISCUSSION

In South Africa, the public healthcare sector is thwarted by financial constraints. The EAP has offered patients diagnosed with mRCC an opportunity to benefit from sunitinib in the absence of access to other biological agents.

This case posed two management dilemmas, it begged exploration of the role of sunitinib in a non-clear cell mRCC and it also focused on the concomitant use of cART and sunitinib. Since many anticancer agents are metabolised to some degree by the Cytochrome P450 (CYP) system, there is a risk that concomitant cART use might result in either drug accumulation and possible toxicity, or decreased efficacy of one or both groups of agents. Continued vigilance for pharmacokinetic drug interactions is required when using non-nucleoside reverse transcriptase inhibitors (NNRTIs) and protease inhibitors (PIs), which are extensively metabolised via the cytochrome P450 (CYP) enzyme system, and may also be inhibitors or inducers of CYP. Despite many interactions of varying clinical significance being described with cART, there is still a dearth of knowledge about the potential for drug interactions with antineoplastic agents (Mounier et al., 2009).



**Figure 2.** Fluorodeoxyglucose-positron emission tomography/computerised tomography (FDG-PET/CT) scan demonstrating a large mass in the right gluteal muscle infiltrating the right hemipelvis, sacrum and L5 vertebral body, consistent with metastatic recurrence of the renal cell carcinoma.

Both sunitinib and its primary active metabolite are substrates of cytochrome P450 3A4 (CYP3A4). It is recommended that the use of concomitant drugs that may specifically increase the plasma level of sunitinib by competition at the liver level on CYP3A4 should be avoided and alternatives with no or minimal enzyme inhibition should be selected. CYP3A4 inducers can decrease the plasma level of sunitinib, and concomitant medication with minimal or no enzyme induction is recommended (Négrier and Revaud, 2007).

Nucleoside reverse transcriptase inhibitors (NRTIs)

such as stavudine and lamivudine are predominantly excreted by the renal system (tubular secretion) and interactions based upon CYP are uncommon. NNRTIs are extensively metabolised by the liver via the CYP enzyme system. Nevirapine and efavirenz are inducers of hepatic CYP3A4, and efavirenz also inhibits the CYP isoenzymes 2C9, 3C19, and 3A4 (Izzedine et al., 2004).

Efavirenz has the ability to both inhibit and induce CYP enzymes and in the absence of literature governing dose modification with concomitant sunitinib use, we chose to keep to the standard sunitinib treatment schedule.

Although the molecular mechanisms of pathogenesis between clear cell and non-clear cell RCC appear distinct, expanded-access trials of both sunitinib and sorafenib demonstrate clinical responsiveness of both drugs in patients with non-clear cell histologies. Whether activity is based on inhibition of the VEGF and PDGF receptor tyrosine kinases or inhibition of c-Kit or other molecular targets is still unclear. Current data are consistent with the notion that compared with clear cell RCC, clinical activity of both drugs expressed in overall response rates and progression free survival seems to be reduced in patients with non-clear cell histologies. However, due to the paucity of patients and lack of controlled trials, the current data remains inconclusive (Strumberg, 2008).

### Conclusion

It is noteworthy that this patient demonstrated a satisfactory tolerance to treatment and a 9 month progression free survival interval while on sunitinib. This is the first case documenting safe administration of sunitinib together with cART. The degree of efficacy of sunitinib in this patient is confounded by the absence of risk stratification.

### REFERENCES

- Choueiri TK, Plantade A, Elson P, Negrier S, Ravaud A, Oudard S, Zhou M, Rini BI, Bukowski RM, Escudier B (2008). Efficacy of sunitinib and sorafenib in metastatic papillary and chromophobe renal cell carcinoma. *J. Clin. Oncol.*, 26:127-31.
- Izzedine H, Launay-Vacher V, Baumelou A, Deray G (2004). Antiretroviral and immunosuppressive drug-drug interactions: an update. *Kidney Int.*, 66: 532-541.
- Mounier N, Katlama C, Costagliola D, Chichmanian RM, Spano JP (2009). Drug interactions between antineoplastic and antiretroviral therapies: Implications and management for clinical practice. *Crit. Rev. Oncol. Hematol.*, 72: 10-20.
- Mulders P (2008). Continued progress in the treatment of advanced renal cell carcinoma: an update on the role of sunitinib. *Eur. Urol.*, 7: 579-584.
- Négrier S, Revaud A (2007). Optimisation of sunitinib therapy in metastatic renal cell carcinoma: adverse-event management. *EJC Supplements*, 5: 12-19.
- Schmidinger M, Zielinski CC (2009). Novel agents for renal cell carcinoma require novel selection paradigms to optimise first-line therapy. *Cancer Treat. Rev.*, 35: 289-296.
- Statistics SA (2009). Mid-year population estimates 2009, Statistical Release P0302, July, Statistics SA, Pretoria. Available at <http://www.statssa.gov.za/publications/P0302/P03022009.pdf>
- Strumberg D (2008). Efficacy of sunitinib and sorafenib in non-clear cell renal cell carcinoma: results from expanded access studies. *J. Clin. Oncol.*, 26: 3469-71.