

Delayed presentation of a laryngeal haematoma following a road traffic accident

Oladejo Olaleye, Elizabeth Illing, Elizabeth Ross
Anna Jordan, Leonard Liew

ABSTRACT

Introduction: Laryngeal haematomas due to trauma are a relatively rare occurrence (less than 1% of all blunt traumas). Most laryngeal injuries are caused by external blunt trauma following a road traffic accident and present with external signs. Particular attention must always be taken to fully examine the neck and larynx. **Case Report:** Here we report a case which illustrates delayed presentation of laryngeal trauma after an initial discharge from the emergency department following a road traffic accident. This middle aged gentleman developed stridor from a laryngeal haematoma 24 hours after leaving hospital and was managed conservatively with steroids, antibiotics, humidification, soft diet, anti-reflux medication and daily endoscopic reviews till discharge. **Conclusion:** This case highlights a life threatening consequence of a road traffic accident, worryingly, with no external markings following the initial trauma. We discuss the case, presentation and management of laryngeal haematomas.

Keywords: Laryngeal haematoma, Stridor, Neck trauma

Olaleye O, Illing E, Ross E, Jordan A, Liew L. Delayed presentation of a laryngeal haematoma following a road traffic accident. International Journal of Case Reports and Images 2012;3(1):5-8.

doi:10.5348/ijcri-2012-01-80-CR-2

INTRODUCTION

Blunt laryngeal trauma is well documented, although it remains a relatively rare complication following involvement in a road traffic accident, sporting injury or strangulation. Presentation varies, but classical presentation, as a haematoma expands, is worsening stridor, voice changes and dysphagia. Laryngeal haematomas are possible, either in isolation or combined with other laryngeal injuries after trauma to the neck. Laryngeal haematomas due to trauma have been documented in the literature [1-6]. Here we discuss a delayed presentation with stridor and involvement of the aryepiglottic fold, piriform fossa and false cords. The recognition of these injuries relies on thorough clinical examination and management can be conservative or surgical depending on the extent of involvement of laryngeal tissues.

CASE REPORT

A middle-aged, previously healthy gentleman was the driver of a car travelling at sixty miles per hour that collided with a stationary van. He was under the influence of alcohol but wearing a seatbelt. After a brief loss of consciousness, he recalled being removed from

Oladejo Olaleye¹, Elizabeth Illing¹, Elizabeth Ross¹, Anna Jordan¹, Leonard Liew¹

Affiliations: ¹Department of Otolaryngology, Head & Neck Surgery Russells Hall Hospital, Dudley West Midlands, United Kingdom DY1 2HQ.

Corresponding Author: Dr. Oladejo Olaleye, Specialty Registrar, Department of Otolaryngology, Head & Neck Surgery Russells Hall Hospital, Dudley West Midlands, United Kingdom DY1 2HQ; Ph: +44 7818518726; Email: dejolaleye@yahoo.com

Received: 05 January 2011
Accepted: 04 April 2011
Published: 01 January 2012

the car by paramedics and police officers. He was assessed in the emergency department using the Advanced Trauma Life Support (ATLS) protocol and was found to have only minor bruising on his forehead with a Glasgow Coma Score (GSC) of 15/15. He did not complain of any neck or airway symptoms and his vital signs were normal. He had no external neck signs of note. Following a 4-hour period of observation in the emergency department (in line with government targets), he was discharged into police custody.

Twenty-four hours later, he returned to the hospital with stridor, hoarseness of voice, difficulty swallowing and a sore throat. At this point, he was referred to the Ear, Nose and Throat team. On examination, he had inspiratory stridor, was able to speak in complete sentences and maintained his oxygen saturations above 96% on room air. No external neck bruises, swelling, or subcutaneous emphysema was found, although on palpation, his trachea was mildly tender. Flexible nasendoscopy (FNE) revealed marked supraglottic oedema with a large left aryepiglottic fold haematoma that extended to the left pharyngeal wall, arytenoid, piriform fossa and false cords (figures 1, 2). His glottis was not visible and he became dyspnoeic towards the end of the examination.

After discussion, his laryngeal haematoma was treated conservatively and he was admitted for close observation and treatment on the high dependency unit. He was commenced on intravenous dexamethasone, antibiotics and humidified oxygen therapy with close monitoring. After the first day, oxygen supplementation was withdrawn and the patient remained stable throughout his four days in the hospital. Daily reviews of the laryngeal haematoma with FNE showed gradual resolution of the oedema and a considerable reduction in the size of the haematoma. Gastric reflux was also noted on FNE and a proton-pump inhibitor commenced. After gradually introducing clear fluids, he was soon able to tolerate solid foods. On day three of treatment, his glottis became visible with an associated

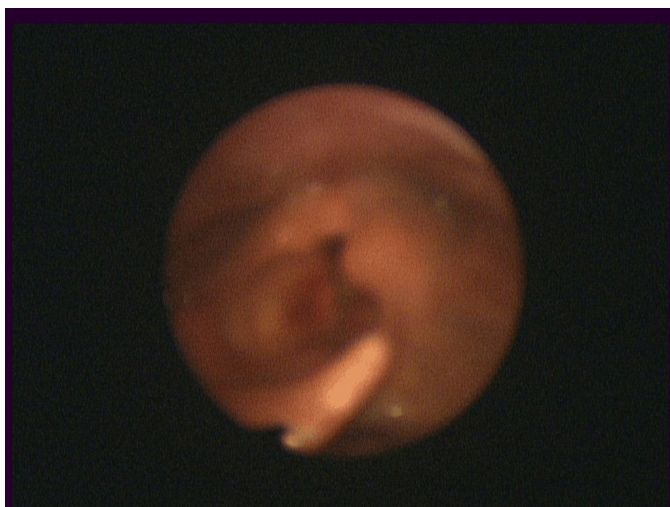


Figure 1: Flexible nasendoscopic view of larynx showing left laryngeal haematoma involving aryepiglottic fold, piriform fossa, arytenoids and false cords.

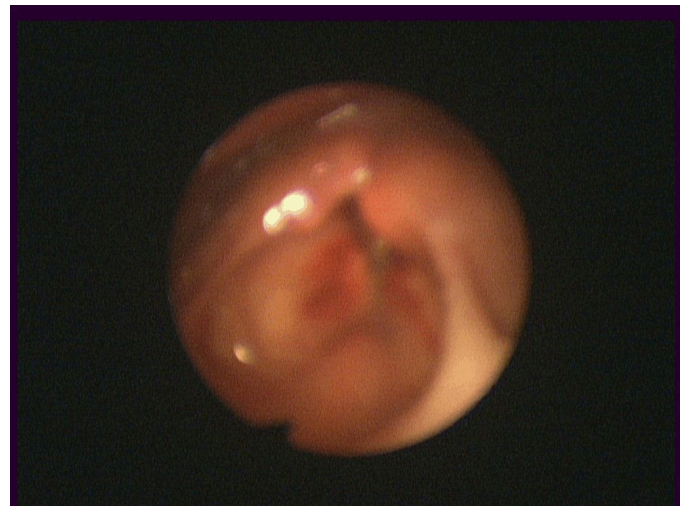

Figure 2: Haematoma involving left arytenoid and false cords with limited view of the glottis.

clinical improvement. He was observed for four days in hospital (the first 24 hours on HDU) and on discharge, the patient felt he had returned to his pre-morbid state. He was discharged on a low dose of oral prednisolone for one week.

Subsequent follow up showed complete resolution of his haematoma as well as the residual hoarseness. He has since returned to his normal daily activities with no further problems.

DISCUSSION

Trauma to the larynx can be blunt or penetrating. Blunt injuries are usually secondary to road traffic accidents and cause cartilage and soft tissue injury from shearing forces [7]. They can result in crushing of the larynx between the object and the cervical spine. Strangulation causes cartilage fracture without mucosal lacerations. Clothesline injury can be severe and occur when an individual on a motorcycle hits their neck against a stationary object, which can result in cricotracheal separation. In this case, the patient hit a stationary van whilst using a seat belt and may have had flexion and extension of his neck on impact. Penetrating injuries are usually due to gunshot or knife wounds with associated injuries to the blood vessels, oesophagus or cervical spine.

Common to all traumatic mechanisms is the direct transfer of forces to the larynx. These forces have the potential to produce many devastating injuries, including mucosal tears, dislocations (cricoarytenoid and cricothyroid), and fractures. Oedema, hematoma, cartilage necrosis, voice alteration, cord paralysis, aspiration, and airway loss may accompany these injuries [1, 7].

Laryngeal haematoma, in particular, is most often a sequela of laryngeal trauma [1-6] as in our patient, but may occur rarely in various coagulopathies, following

procedures for general anaesthesia, strangulation, and anticoagulant therapy. Other infrequently reported causes of airway haemorrhage include cervical spine injuries, and operative complications of which the areas most commonly affected are the retropharyngeal space, the sublingual space and the larynx [4]. There have been previously reported cases of laryngeal haematoma presenting as stridor in the literature [6] and it has also been reported as fatal [5].

Common presenting symptoms in such traumatic injuries to the larynx include; hoarseness, neck pain, dyspnoea, dysphonia, dysphagia, odynophonia, and odynophagia. Upon examination, it is imperative to identify signs of potential laryngeal injury, which include stridor, subcutaneous emphysema, haematoma, ecchymosis, laryngeal tenderness, vocal cord immobility, loss of thyroid cartilage prominence, and bony crepitus 1.

Potential red flags were missed in the initial history and assessment of this patient in the emergency unit. Clinicians in acute specialties need to be alert to the possibility of laryngeal trauma or oedema. If there is strong suspicion of laryngeal injury, it is mandatory to secure the airway and ensure an experienced anaesthetist and otolaryngologist are present. This patient had no neck complaints initially but A&E staff should have been more suspicious of possible neck injury given the history of a RTA collision whilst using a seatbelt. This was a diagnostic challenge particularly as this patient had no external neck signs. It would appear the laryngeal tenderness was missed on initial assessment (although he had been under the influence of alcohol). At this point, this patient was at risk of developing progressive laryngeal oedema which could also lead to airway compromise.

Stridor and mild tracheal tenderness were the only clinical signs found in our patient on his second presentation to hospital, when assessed by an otolaryngologist. At this point, an acute laryngeal fracture must be suspected and the supraglottic airway formally assessed. Consideration should also be taken to identify associated injuries such as intracranial trauma, cervical spine fractures and oesophageal injuries, although airway management must always remain the clinician's priority. Misdiagnosis and inappropriate management may lead to airway obstruction with potentially fatal consequences.

Management of a laryngeal haematoma, once recognised, may be conservative or invasive depending upon the clinical picture and the risk of airway compromise. Intervention with endotracheal intubation or tracheostomy may be necessary in life-threatening cases, but must be planned to reduce patient morbidity and mortality. With an unstable airway, tracheostomy under local anaesthesia is considered by most authors the safest and least traumatic method of securing the airway but an emergency cricothyrotomy can be used if there is no time for a formal tracheostomy. Endotracheal intubation should only be attempted by an experienced anaesthetist with a small diameter endotracheal tube as there is a risk of further iatrogenic

compromise of an already precarious airway. Once the airway is secured, formal tracheostomy can be performed if required.

A suspected haematoma should be confirmed by indirect laryngoscopy or flexible nasendoscopy performed by an experienced otolaryngologist. Medical management is generally appropriate for mucosal oedema, haematomas with intact mucosal coverage and small glottic and supraglottic lacerations without the exposure of cartilage. Whereas, disruptions of the anterior commissure, multiple displaced cartilage fractures and larger open lacerations require open laryngeal exploration. Radiographs do not play a significant role in the diagnosis of laryngeal injury but help in the assessment of associated cervical spine injury and increased soft tissue markings as part of the ATLS protocol.

The use of Computerised tomography (CT) scans in the diagnosis of laryngeal injury is very effective and is useful when flexible nasendoscopy is limited by oedema. Most authors utilize CT scans in assessing these injuries and some only request it if it will alter the management plan. In cases of obvious severe injury when neck exploration and tracheostomy is required, or in cases with minor trauma and no endoscopic findings, a CT scan is not necessary [8]. CT is contra-indicated when the airway is unstable. Medical management is effective in treating the majority of mucosal injuries.

Conservative management, as commenced for our patient, involves voice rest, humidified oxygen (if clinically appropriate), corticosteroids, empirical antibiotics and anti-reflux medication. The role of corticosteroids remains controversial but some studies suggest they reduce the inflammatory response and are of most benefit in the first few days after the injury [1, 9, 10].

Empiric antibiotics are not necessary in treating minor laryngeal trauma however when tears are visualized or with compound laryngeal fractures, they help to reduce the risk of infection and perichondritis which may delay healing and promote airway stenosis [7].

Gradual reintroduction of diet from clear fluids to soft diets and solids is advised if dysphagia and odynophagia are presenting symptoms. It is important however that with conservative management, there is daily monitoring of clinical symptoms and signs as there is the potential for rapid deterioration. Delayed treatment can lead to poor voice outcomes, cricoarytenoid joint subluxation and chronic laryngeal stenosis [3].

Surgical intervention is necessary with gross endoscopic abnormalities, mucosal lacerations, massive oedema with airway compromise, vocal cord immobility and laryngeal fractures. Depending on the severity of the injuries associated with laryngeal haematoma, surgical treatment could range from emergency tracheostomy, direct laryngoscopy and repair of mucosal tears, neck exploration, open reduction and internal fixation of laryngeal fractures and endolaryngeal stent insertions. Four of 10 victims of

blunt laryngeal injury die on the scene of the accident so recognition and management of airway compromise is essential [7].

CONCLUSION

The crucial message from our case is the importance of thorough clinical examination and early recognition of potential laryngeal injury and possible airway compromise by clinicians in acute specialties. Patients should be promptly referred to the Otolaryngologists for assessment and appropriate management.

This increased awareness for a potential laryngeal injury especially in cases of trauma, even after a benign initial examination will allow for prompt endoscopy, radiological assessment and the correct conservative or surgical treatment. We feel that this will have a significant impact on reducing future post-traumatic complications.

Author Contributions

Oladejo Olaleye – Substantial contributions to conception and design, acquisition of data, Drafting the article, revising it critically for important intellectual content, Final approval of the version to be published
Elizabeth Illing – Substantial contributions to conception and design, acquisition of data, Drafting the article, revising it critically for important intellectual content, Final approval of the version to be published
Elizabeth Ross – Substantial contributions to conception and design, acquisition of data, Drafting the article, revising it critically for important intellectual content, Final approval of the version to be published
Anna Jordan – Drafting the article, revising it critically for important intellectual content, Final approval of the version to be published
Leonard Liew – Drafting the article, revising it critically for important intellectual content, Final approval of the version to be published

Guarantor

The corresponding author is the guarantor of submission.

Conflict of Interest

Authors declare no conflict of interest.

Copyright

© Oladejo Olaleye et al. 2012; This article is distributed under the terms of Creative Commons attribution 3.0 License which permits unrestricted use, distribution and reproduction in any means provided the original authors and original publisher are properly credited. (Please see www.ijcasereportsandimages.com/copyright-policy.php for more information.)

REFERENCES

1. Schaefer, S. D. The acute management of External Laryngeal trauma, a 27 year experience, Archives of Otolaryngology Head and Neck Surgery June 1992;118:598-604.
2. Ayuso MA, Luis M, Doménech J, Sala X, Nalda MA. External laryngeal injuries [Study of 12 cases]. Rev Esp Anestesiol Reanim 1994 Nov-Dec;41(6):328-31.
3. Brosch S, Johanssen HS. Clinical course of acute laryngeal trauma and associated effects on phonation. Journal of Laryngology & Otology, January 1999;113/1(58-61),0022-2151.
4. Myssoirek D, Shalmi C. Traumatic retropharyngeal haematoma. Arch Otolaryngol Head Neck Surg 1989;115:130-2.
5. Maxeiner H. [Internal laryngeal hematoma. A contribution to death following blow to the neck]. Arch Kriminol. 1984 Jul-Aug;174(1-2):51-6.
6. Robin G, Denholm S, Tomkinson A. Stridor due to laryngeal haematoma. Journal of the Royal Society of Medicine November 1998;91/11(593):0141-0768.
7. Pancholi SS, Robbins WK, Desai A, Desai T. Laryngeal fractures. eMedicine <http://emedicine.medscape.com/article/865277-overview> Accessed Nov. 2010.
8. Schaefer SD, Brown OE. Selective application of CT in the management of laryngeal trauma. Laryngoscope Nov 1983;93(11 Pt 1):1473-5.
9. Braidy J, Breton G, Clément L. Effect of corticosteroids on post-intubation tracheal stenosis. Thorax 1989 Sep;44(9):753-5.
10. S. D. Rejali, J. D. Bennett, T. Upile, M. P. Rothera. Diagnostic pitfalls in sports related laryngeal injury. Br J Sports Med 1998 June;32(2):180-181.