

# The detection of periapical pathosis using periapical radiography and cone beam computed tomography – Part 1: pre-operative status

S. Patel<sup>1,2</sup>, R. Wilson<sup>3</sup>, A. Dawood<sup>2</sup> & F. Mannocci<sup>1</sup>

<sup>1</sup>Department of Conservative Dentistry, King's College London Dental Institute, London; <sup>2</sup>Special Practice, London, UK; and

<sup>3</sup>Department of Periodontology, King's College London Dental Institute, London, UK

[Correction added after online publication, 25th May 2012: title changed to refer to study being in two parts.]

## Abstract

**Patel S, Wilson R, Dawood A, Mannocci F.** The detection of periapical pathosis using periapical radiography and cone beam computed tomography – Part 1: pre-operative status.\* *International Endodontic Journal*, **45**, 702–710, 2012.

**Aim** Part 1 of this 2 part study aims to compare the prevalence of periapical lesions on individual roots viewed with intraoral (periapical) radiographs and cone-beam computed tomography (CBCT) of teeth treatment planned for endodontic treatment.<sup>§</sup>

**Methodology** Diagnostic periapical radiographs and CBCT scans were taken of 151 teeth in 132 patients diagnosed with primary endodontic disease. The presence or absence of periapical lesions was assessed by a consensus panel consisting of two calibrated examiners, a consensus agreement was reached if there was any disagreement. The panel viewed the images under standardised conditions. Part 2 will compare the radiographic outcome 1 year after completion of primary root canal treatment.<sup>¶</sup>

**Results** Two hundred and seventy-three paired roots were assessed with both radiological systems, periapical lesions were present in 55 (20%) and absent in 218 (80%) roots assessed with periapical radiographs. When the same 273 sets of roots were assessed with CBCT, lesions were present in 130 (48%) and absent in 143 (52%) roots. Seventy-five additional roots were detected with CBCT.

**Conclusion** The limitations of periapical radiographs which may hinder the detection of periapical lesions are overcome with CBCT. This results in firstly, more roots being assessed, and secondly, more periapical lesions being detected with CBCT.

**Keywords:** cone beam computed tomography, intra-oral radiographs, periapical lesions.

Received 25 May 2011; accepted 2 November 2011

## Introduction

Radiographic assessment is an essential component in the diagnosis of teeth with suspected endodontic problems (Patel *et al.* 2009a, Özen *et al.* 2009, Yoshioka *et al.* 2011). The specific view of choice for endodontic assessment is a periapical (intraoral) radiograph using a beam aiming device to ensure a minimally distorted and reproducible image (Jorge *et al.* 2008, Patel *et al.* 2009a).

Ideally, the radiographic image will confirm the number of root canals, their configuration together with the

Correspondence: Shanon Patel, 45 Wimpole Street, London W1G 8SB, UK (e-mail: shanonpatel@gmail.com).

\*[Correction added after online publication, 25th May 2012: title changed to refer to study being in two parts.]

§[Correction added after online publication, 25th May 2012: Aim changed to refer to study being in two parts.]

¶[Correction added after online publication, 25th May 2012: 'intraoral' changed to 'periapical radiographs' and sentence added to explain methodology of second part of study.]

presence or absence of periapical lesions and their location (Lofthag-Hansen *et al.* 2007, Low *et al.* 2008, Neelakantan *et al.* 2010). This important information not only helps to confirm the diagnosis, but also aids treatment planning and management and is a baseline for assessing the outcome of each unique endodontic problem.

It is well established that radiographs have limitations; these include anatomical noise, the two dimensionality and geometric distortion (Huomonen & Ørstavik 2002, Patel *et al.* 2009a). The ideal imaging technique should set the clinician free from the constraints of these limitations.

Cone-beam computed tomography (CBCT) may be used to overcome these limitations. CBCT has been specifically designed to produce three-dimensional images of the maxillofacial skeleton. With CBCT, the entire 'region of interest' is scanned in a single rotation of the X-ray source and reciprocal detector around the patient's head. For endodontic purposes, the limited volume or focused CBCT scanners capture small volumes of data encompassing just 3–4 individual teeth. For example, the 3D Accuitomo (J Morita, Osaka, Japan) can capture a 40-mm<sup>3</sup> volume of data, which is similar in overall height and width to a periapical radiograph. The major advantage of limited (small field of view) CBCT scanners over medical-grade computer tomography is the relatively low-effective radiation dose the patient is exposed to (Loubele *et al.* 2009). Software generates reconstructed images in three orthogonal planes within minutes. Reconstructed images of data without the overlying cortical plate (anatomical noise) that may otherwise hide what is actually occurring within the cancellous bone may therefore be assessed. The clinician can also orient the reconstructed slice(s) resulting in orthogonal views that are parallel and perpendicular to the long axis of the root under investigation. These factors ultimately result in the number of roots, canals and periapical lesions present in the tooth being significantly more perceptible to the clinician compared with periapical radiographs (Matherne *et al.* 2008, Paula-Silva *et al.* 2009a, Blattner *et al.* 2010). Not only can the presence of a periapical lesion be diagnosed with CBCT, but the specific root that it is associated with can also be confirmed (Rigolone *et al.* 2003, Gröndahl & Huomonen 2004).

Laboratory studies have confirmed that CBCT improves the detection of presence or absence of periapical lesions when compared with periapical radiographs (Stavropoulos & Wenzel 2007, Özen *et al.* 2009, Patel *et al.* 2009b). Clinical studies have compared periapical radiographs and CBCT scans for detecting periapical

periodontitis; however, these studies have generally focused on the prevalence of periapical lesions in teeth with failing root canal treatment (Lofthag-Hansen *et al.* 2007, Estrela *et al.* 2008, Low *et al.* 2008, Bornstein *et al.* 2011). There is a paucity of literature comparing periapical radiographs and CBCT scans for detecting periapical periodontitis in untreated teeth diagnosed with endodontic disease.

This clinical study has two purposes: firstly, to compare the prevalence of periapical lesions on individual roots of teeth viewed with periapical radiographs and CBCT of teeth treatment planned for primary root canal treatment, which is described below. The second part of this clinical study was to determine the radiological outcome one year after completion of primary root canal treatment for each tooth, and will be described in part 2. [Correction added after online publication, 25th May 2012: sentence changed to include purpose of second part of study.]

## Materials and methods

### Subject material

Subjects included in this study were recruited from patients referred to the first author in a specialist endodontic practice for the management of suspected endodontic problems. The patients were seen consecutively between 1 October 2008 and 30 April 2009. All patients were examined clinically, and those diagnosed with signs of endodontic disease and scheduled for treatment were considered for inclusion in the study. Exclusion criteria included pregnant women, immunosuppressed patients, unrestorable teeth and teeth with periodontal probing depths >3 mm. Approval was sought and granted by the Guy's Research Ethics Committee, Guy's and St. Thomas Hospital National Health Service Trust (National Research Ethics Service, UK).

One hundred and fifty-one teeth in 132 patients fulfilled the aforementioned criteria, and these patients were asked to give their written consent to be involved in the study. A detailed verbal and written explanation of the purpose of the study was provided. The patients were advised that the diagnostic phase and treatment protocol would not adversely affect the outcome of treatment.

### Radiographic technique

The clinical examination included exposure of periapical radiographs using a beam aiming device to

allow for standardization of the radiographs. All radiographs were taken with a dental X-ray machine (Planmeca Prostyle Intra, Helsinki, Finland) using a digital CCD (Schick Technologies, New York, NY, USA), and the exposure parameters were 66 kV, 7.5 mA and 0.10 s. The X-ray tube head, digital sensor and mandible were aligned to allow radiographs to be exposed using the paralleling technique. Small-volume (40 mm<sup>3</sup>) CBCT scans (3D Accuitomo F170; J Morita Manufacturing, Kyoto, Japan) with exposure parameters 90 kV, 5.0 mA and 17.5 s were then taken of the area of interest. All CBCT scans were reformatted (0.125 slice intervals and 1.5 mm slice thickness).

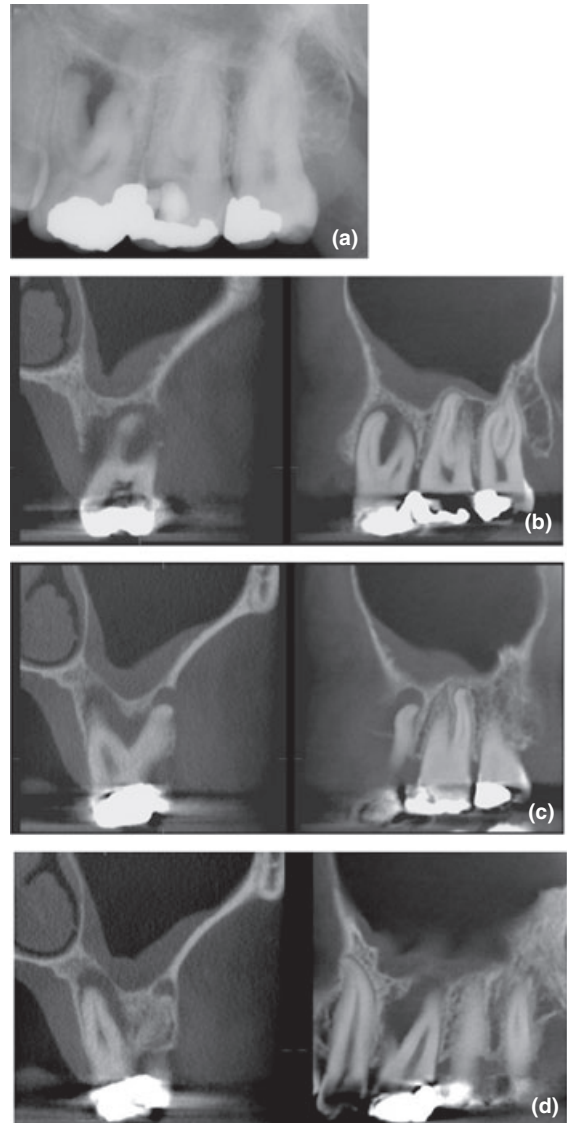
### Radiological assessment

The radiographic images were then assessed in two sessions as follows:

In session (1), the consensus panel assessed 50% of the periapical radiographs ( $n = 76$ ) followed by 50% of CBCT scans ( $n = 76$ ). In session (2), the consensus panel assessed the remaining 50% of CBCT scans ( $n = 77$ ) followed by remaining 50% of periapical radiographs ( $n = 77$ ).

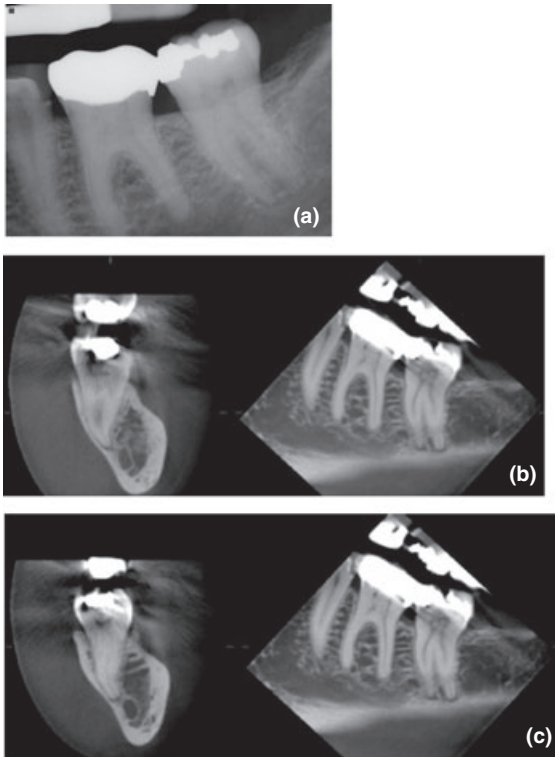
The radiographs and CBCT images for sessions 1 and 2 were randomly ordered in each session. CBCT images that best confirmed the presence or absence of a radiolucent periapical lesion in the sagittal, coronal and/or axial planes were used as the starting point for each root to be observed. These images were selected by an endodontist who was experienced in using CBCT in endodontic therapy. The consensus panel also had access to the whole CBCT scan using CBCT software (One-Volume viewer; Morita) allowing them to scroll through any of the images. No further multiplanar reconstruction of the data (e.g. changing the orientation of the scan) was carried out. All images were assessed in a quiet, dimly lit room. The radiographs and CBCT images were viewed as a Keynote presentation (Apple, Cupertino, CA, USA) on laptop computers (MacBook Pro; Apple), which had a 15.5-inch LED backlit screen with a pixel resolution of 1680 × 1050. Sessions (1) and (2) were divided into two separate viewing periods over the course of a day to minimize the likelihood of consensus panel fatigue. There was at least a 1-week interval between each of the main sessions.

The consensus panel included two endodontists who already had clinical experience in using CBCT. They were trained using examples of clinical radiographs and CBCT images with and without the presence of



**Figure 1** (a) Periapical radiograph of 26 reveals a periapical radiolucency associated with the mesio-buccal and palatal root, (b-d) coronal (left) and sagittal (right) reconstructed CBCT images reveal a periapical radiolucency associated with the (b) mesio-buccal, (c) disto-buccal-root and (d) palatal roots.

periapical lesions before embarking on the assessment. Before assessing the experimental material, the reliability of each member of the panel was assessed by asking them each to grade 30 periapical radiographs and 30 CBCT images for the presence and absence of periapical lesions. These radiographic images were not from experimental sample. The examiners were not involved in assessing or treating the patients.



**Figure 2** (a) Periapical radiograph of the 37 shows a healthy periapical tissues, (b-c) coronal (left) and sagittal (right) reconstructed CBCT images reveal periapical radiolucencies with the (b) mesial and (c) distal roots.

**Table 1** Numbering of roots observed and identified during assessment

Tooth type	Root number		
	1	2	3
Incisors, canines, premolars <sup>a</sup>	Single root		
Premolars <sup>b</sup>	Buccal	Lingual/palatal	
Mandibular molars	Buccal	Mesio-lingual	Distal
Maxillary molars	Mesio-buccal	Disto-buccal	Palatal

<sup>a</sup>Premolar with a single root canal.

<sup>b</sup>Premolar with two root canals.

A periapical lesion was defined as a radiolucency associated with the radiographic apex of the root, which was at least twice the width of the periodontal ligament space (Low *et al.* 2008, Bornstein *et al.* 2011). With multirooted teeth, the presence or absence of a periapical lesion on each specific identifiable root was noted (Figs 1 and 2). This allowed like-pairs of specific roots identified using periapical radiographs and CBCT to be assessed for

the absence or presence of a periapical lesion. A consensus decision was reached for each of the radiographs and series of reconstructed CBCT images. An Excel (Excel 2010; Microsoft Corporation, Richmond, WA, USA) spreadsheet was created to log data.

Each root was identified by number, so that individual roots could be compared between radiological systems as pairs (Table 1). It was expected that in some cases, there would be a discrepancy in the number of roots being assessed between the two radiological systems.

### Data analysis

Stata™ software (Stata 11, College Station, TX, USA) was used to analyse the data. The sample size was determined by assessing previous similar research. It was calculated that 150 teeth would provide 80% power to show a 25% difference in the number of lesions identified as present between the radiological systems. Kappa analysis was used to assess the reproducibility of each of the two examiners of the consensus panel prior to the main study (Altman 1990). Comparison of periapical radiographs and CBCT images for the identification of the presence and absence of lesions was made using McNemar tests on paired single roots per tooth. Assessment of the presence and absence of the number of roots and periapical lesions per tooth was described, but not statistically tested.

### Results

One hundred and fifty-one teeth in 132 patients were assessed in this study. The mean age of the patients was 44.7 (standard deviation 13.7), and the percentage of women and men was 58% and 42%, respectively.

The presence or absence of periapical lesions was detected in 273 pairs of roots with both periapical radiographs and CBCT images. Comparison of the 273 paired roots revealed that periapical lesions were present in 55 (20%) and absent in 218 (80%) roots when assessed with periapical radiographs. When the same 273 sets of roots were assessed with CBCT, lesions were present in 130 (48%) and absent in 143 (52%) roots.

An additional 76 (22%) roots were identified with CBCT alone. Therefore, the total number of roots detected with a periapical lesion present was 138 (40%), and 211 (61%) of roots had no periapical lesion in the 349 roots identified with CBCT. Owing to nonindependence, these data were not analysed statistically.

**Table 2** Breakdown of agreement of periapical lesions (percentage) present (1) and absent (0) with intraoral radiographs (PA) and CBCT

	PA (0) CBCT (0)	PA (1) CBCT (0)	PA (1) CBCT (1)	PA (0) CBCT (1)	Paired roots
Total paired roots	137	6	49	81	273
Roots 1	64	4	40	43	151
Roots 2	51	2	6	32	91
Roots 3	22	0	3	6	31

Table 2 shows the number of paired roots of teeth assessed for periapical lesions in roots identified as 1, 2 and 3, respectively, using the schedule in Table 1. In all cases, CBCT images revealed a greater number of positive identifications than periapical radiographs ( $P < 0.02$  to  $P < 0.001$ ).

There was agreement on the absence of a lesion between the two radiological systems in 50% roots where paired roots were visualized. When assessing for the presence of a periapical lesions, there was agreement in 18% pairs of roots.

The Kappa values for interexaminer agreement after the training session were 0.878 and 0.837 for periapical radiographs and CBCT images, respectively.

## Discussion

A reference standard to compare both radiological techniques would have been the ideal scenario. However, as this was a clinical study, this was not possible. The question arises: how valid were the diagnoses of the presence or absence of periapical lesions using either radiographic technique? *Ex vivo* studies in which the detection of simulated periapical lesions has been assessed with CBCT images and periapical radiographs have all confirmed the superior diagnostic ability of CBCT images over periapical radiographs (Stavropoulos & Wenzel 2007, Özen et al. 2009, Patel et al. 2009a,b, Soğur et al. 2009). These findings have been reinforced by more recent *in vivo* dog studies (Paula-Silva et al. 2009a,b). Intentionally created periapical lesions were induced around the roots of dog's teeth (one group had vital pulps to serve as a positive control). After 180 days (another group was left untreated to serve a negative control), periapical radiographs and CBCT scans were taken after which the animals were sacrificed, and the root apices and surrounding periapical tissues were evaluated histologically (providing a reference standard). These studies confirmed that CBCT not only was more sensitive at detecting periapical lesions, but also had a higher overall accuracy when compared with periapical radiographs.

The two examiners who constituted the consensus panel were experienced in interpreting CBCT data, as well as appreciating the limitations of this technology including its poorer resolution. The use of a consensus panel has been used previously in studies assessing detection ability of periapical lesions to reduce interexaminer variation (Lofthag-Hansen et al. 2007, Low et al. 2008). Consensus panels surpass the accuracy of individual expert diagnoses where clinical information elicits diverse judgments. Viewing sessions were kept as short as practically possible, and all images were randomized both within and between sessions to reduce the potential effect of examiner fatigue.

The differential detection rate of periapical lesions with CBCT images compared with periapical radiographs was the same when two parallax radiographs (Lofthag-Hansen et al. 2007) and single periapical radiographs were taken (Low et al. 2008, Bornstein et al. 2011). Therefore, only one radiograph per tooth was included in this study.

A digital periapical radiographic system was used, and the image produced was dynamic and allowed it to be enhanced (contrast/brightness) to potentially improve its diagnostic yield (Kullendorf & Nilsson 1996). In addition, the effective dose for a digital periapical radiographic system is lower than for its film counterpart (Nair & Nair 2007). Several well-designed *ex vivo* studies have shown that there is no difference in the detection ability of artificially created periapical lesions using conventional X-ray films and digital sensors (Kullendorf & Nilsson 1996, Barbat & Messer 1998, Stavropoulos & Wenzel 2007, Özen et al. 2009). Enhancing the radiographic images (e.g. colourizing and inverting) with software was not carried out as it has not been shown to improve the detection of periapical lesions (Barbat & Messer 1998).

Antiglare LCD screens with a high pixel resolution were used to provide a high-quality image for the assessment of radiographs and CBCT images. There is evidence to suggest that LCD and high-resolution cathode ray tubes are equally effective for assessing CBCT images and digital radiographs (Baksi et al. 2009).

In this study, periapical radiographs and reconstructed CBCT images were assessed for their diagnostic ability in detecting radiographic signs of periapical periodontitis in 151 teeth planned for primary root canal treatment. Previous clinical studies have tended to focus on teeth that have already been root filled. In the study conducted by Lofthag-Hansen *et al.* (2007), 42 (91%) of the 46 teeth assessed with signs of endodontic disease had already been root filled. In two other studies, all the teeth had been root filled (Low *et al.* 2008, Bornstein *et al.* 2011). These studies focused on either posterior teeth (Lofthag-Hansen *et al.* 2007), maxillary posterior teeth (Low *et al.* 2008) or mandibular teeth alone (Bornstein *et al.* 2011). Estrela *et al.* (2008) assessed 83 untreated teeth including all tooth groups (i.e. anterior and posterior).

The results of this study revealed that periapical lesions were detected in only 55 (20%) of paired roots with periapical radiographs compared to 130 (48%) with CBCT images. That is, 28% more periapical lesions were detected with CBCT images when paired roots were compared. Periapical lesions were absent in 80% and 52% of paired roots assessed with radiographs and CBCT images, respectively. In addition, 76 roots were identified only with CBCT images; periapical lesions were present in 8 (10%) of these roots and absent in 68 (90%) [Correction added after online publication, 25th May 2012: The '(22)' after '76' has been deleted and '11%' has been changed to '10%']. These results concur with previous studies; Lofthag-Hansen *et al.* (2007) compared the prevalence of periapical periodontitis in 46 maxillary and mandibular posterior teeth and concluded that 20% more teeth had periapical lesions when assessed with reconstructed CBCT images compared with periapical radiographs. Low *et al.* (2008) found that 34% more periapical lesions were detected with reconstructed CBCT images than with intraoral radiography in 74 posterior maxillary teeth referred for periapical microsurgery. Estrela *et al.* (2008) assessed 83 untreated teeth diagnosed with an endodontic problem and found that the prevalence of radiological signs of periapical pathosis with periapical and reconstructed CBCT images was 36% and 75%, respectively, a 39% difference. Interestingly, the prevalence of periapical periodontitis was even lower with panoramic radiographs at only 22%. None of these studies specifically assessed paired roots.

One important question to be addressed is the potential presence of false positives in the CBCT images. Perhaps the ideal test would be to compare CBCT images of periapical tissues to histologic assessment in humans;

however, this is impossible as it is unethical to carry out such an investigation. Owing to cross-infection control regulations, it would also not be possible to undertake a similar study on human cadavers. However, a study on the diagnostic accuracy of small-volume CBCT and periapical radiography for the detection of very small simulated external inflammatory root resorption recently undertaken on dry mandibles demonstrated that CBCT images were far superior to periapical radiographs not only in terms of sensitivity (100% vs. 87%), but also, and more significantly, in terms of specificity (96% vs. 43%) with a negative predictive value (that is the ability to detect the absence of a lesion) standing at 86% for periapical radiographs and at 100% for CBCT images (Durack *et al.* 2011). Other studies also found higher negative predictive value for CBCT images compared with periapical radiographs (Patel *et al.* 2009b, Paula-Silva *et al.* 2009c).

Bornstein *et al.* (2011) found that there was a 74% agreement between periapical radiographs and CBCT images for the presence of a periapical lesion on paired roots of mandibular molar teeth. Although they did not compare paired roots, Low *et al.* (2008) found that there was 66% agreement between periapical radiographs and CBCT images for the presence of a periapical lesion. In the present study, there was only a 17.9% agreement between the radiological systems for the detection of the presence of a periapical lesion. The higher agreement in the previously published studies may be due to the fact that the teeth considered for inclusion in these studies had clinical and/or radiological signs of failed existing endodontic treatment. Therefore, the likelihood of a periapical lesion being detected would naturally be higher. In the present study, none of the teeth had been previously root treated and consisted of teeth with vital (e.g. gross caries, irreversible pulpitis) as well as infected necrotic pulps (e.g. chronic periapical periodontitis). In this study, 59 (39%) teeth were diagnosed to have irreversible pulpitis after clinical and conventional radiographic examination (i.e. no signs of a periapical radiolucency); however, 26 (44%) of these teeth had periapical radiolucencies when assessed with CBCT images. The presence of periapical lesion(s) detected only by CBCT images changes the endodontic diagnosis to a chronic periapical periodontitis, this may change treatment strategy, for example multiple visit treatment with calcium hydroxide inter-appointment dressing rather than single-visit treatment, and it also changes the prognosis of the treatment of which the patient needs to be informed (Ng *et al.* 2011).

The detection of periapical lesions using CBCT images will also help the clinician in avoiding direct or indirect pulp capping procedures on teeth that appear to have pulps with reversible pulpitis (i.e. respond positively to vitality testing and show no periapical lesions with intraoral radiographs).

The higher prevalence of periapical lesions detected by CBCT images is a result of the three-dimensional assessment of the teeth and surrounding tissues. The CBCT software allowed the clinician to select the most favourable orthogonal views for each specific root being assessed. This allows slices of data to be reconstructed without the overlying anatomical noise (i.e. cortical plate, zygomatic buttress and/or superimposed roots) obscuring the area of interest, and therefore, the status of the periapical tissues could be assessed. Slice angles were selected so that the coronal and sagittal views were parallel to the root being assessed, thus minimizing any distortion. These factors ultimately resulted in the presence or absence of periapical lesions being significantly more perceptible with CBCT images than with periapical radiographs. This is also why more roots could be assessed with CBCT images (Özen et al. 2009, Patel et al. 2009a, Paula-Silva et al. 2009a). The lower prevalence of periapical lesions with periapical radiography was because of the combination of anatomical noise, geometric distortion and the two-dimensional nature of the image produced (Estrela et al. 2008, Matherne et al. 2008, Paula-Silva et al. 2009b).

Each endodontic problem assessed in the present study was unique; therefore, the nature and location of the periapical lesions varied from case to case. However, it was considered important to carry out a clinical study, as the mechanically 'machined' periapical lesions used in previous *ex vivo* studies, although standardized, do not truly reflect the nature of real periapical lesions, which are generally irregularly shaped cavities. CBCT scans not only aided diagnosis, but facilitated the overall management of each case, for example the presence and location of root canals may be determined before treatment commenced (Tu et al. 2009, Neelakantan et al. 2010). Therefore, the specialist endodontist will know exactly where to look with the aid of the dental operating microscope, therefore reducing the time 'exploring' the pulp chamber looking for canal entrances.

The effective radiation dose to patients when using CBCT is higher than with conventional digital radiography, and there is huge variation in effective dose between CBCT scanners. In this study, the effective dose from CBCT scan was in the same order of magnitude to 2–3 standard periapical exposures (Arai et al. 2001,

Mah et al. 2003, Loubele et al. 2009). It is essential to justify the need for exposing a patient to radiation and then optimize the radiation dose. Therefore, the smallest field of view was selected in this study, thus keeping the radiation dose as low as reasonably achievable (Farman 2005, Patel & Horner 2009).

At present, CBCT is typically used to help diagnose poorly localized endodontic problems (for example irreversible pulpitis) and/or to treatment plan complex endodontic problems, for example multirrooted teeth (Nair & Nair 2007, Patel 2009). In addition to revealing the true status of the periapical tissues, CBCT also provides other clinically relevant information, which cannot be readily elicited from intraoral radiographs, such as the number and configuration of root canals, proximity of adjacent neighboring anatomical structures and cortical plate topography (Rigolone et al. 2003, Estrela et al. 2008, Low et al. 2008, Matherne et al. 2008).

## Conclusion

This study revealed that the periapical lesions were detected in only 55 (20%) of paired roots with periapical radiographs compared to 130 (48%) with CBCT images, that is a 28% more periapical lesions were detected with CBCT when paired roots were compared. In view of the superior accuracy of CBCT compared with periapical radiographs for diagnosing periapical periodontitis, it may be time to review the way that both epidemiological and outcome studies are performed as CBCT data offer a more accurate objective baseline value that has the potential to reduce false negatives so often detected with periapical radiographs. [Correction added after online publication, 25th May 2012: intraoral has been replaced with periapical throughout.]

## References

- Altman DG (1990) *A reference for Kappa statistics, Practical Statistics for medical research*. London: Chapman & Hall, 403 pp.
- Arai Y, Honda K, Iwai K, Shinoda K (2001) Practical model '3DX' of limited cone-beam X-ray CT for dental use. *International Congress Series* **2001**, 713–8.
- Baksi BG, Sögür E, Gröndahl H-G (2009) LCD and CRT display of storage phosphor plate and limited cone beam computed tomography images for the evaluation of root canal fillings. *Clinical Oral Investigations* **13**, 37–42.
- Barbat J, Messer HH (1998) Detectability of artificial periapical lesions using direct digital and conventional radiography. *Journal of Endodontics* **24**, 837–42.

- Blattner TC, Goerge N, Lee CC, Kumar V, Yelton CDJ (2010) Efficacy of CBCT as a modality to accurately identify the presence of second mesiobuccal canals in maxillary first and second molars: a pilot study. *Journal of Endodontics* **36**, 867–70.
- Bornstein MM, Lauber R, Sendi P, von Arx T (2011) Comparison of periapical and limited cone-beam computed tomography in mandibular molars for analysis of anatomical landmarks before apical surgery. *Journal of Endodontics* **37**, 151–7.
- Durack C, Patel S, Davies J, Wilson R, Mannocci F (2011) Diagnostic accuracy of small volume cone beam computed tomography and intraoral periapical radiography for the detection of simulated external inflammatory root resorption. *International Endodontic Journal* **44**, 136–47.
- Estrela C, Bueno MR, Leles CR, Azevedo B, Azevedo JR (2008) Accuracy of cone beam computed tomography and panoramic radiography for the detection of apical periodontitis. *Journal of Endodontics* **34**, 273–9.
- Farman AG (2005) ALARA still applies-editorial. *Oral Surgery, Oral Medicine, Oral Pathology, Oral Radiology and Endodontics* **100**, 395–7.
- Gröndahl H-G, Huuononen S (2004) Radiographic manifestations of periapical inflammatory lesions. *Endodontic Topics* **8**, 55–67.
- Huuononen S, Ørstavik D (2002) Radiological aspects of apical periodontitis. *Endodontic Topics* **1**, 3–25.
- Jorge EG, Tanomaru-Filho M, Goncalves M, Tanomaru JM (2008) Detection of periapical lesion development by conventional radiography or computed tomography. *Oral Surgery Oral Medicine Oral Pathology Oral Radiology and Endodontology* **106**, 56–61.
- Kullendorf B, Nilsson M (1996b) Diagnostic accuracy of direct digital dental radiography for the detection of periapical bone lesions-II. Effects on diagnostic accuracy after application of image processing. *Oral Surgery, Oral Medicine, Oral Pathology* **82**, 585–9.
- Lofthag-Hansen S, Huuononen S, Gröndahl K, Gröndahl H-G (2007) Limited cone-beam CT and intraoral radiography for the diagnosis of periapical pathology. *Oral Surgery, Oral Medicine, Oral Pathology, Oral Radiology and Endodontology* **103**, 114–9.
- Loubele M, Bogaerts R, Van Dijk E et al. (2009) Comparison between effective radiation dose of CBCT and MSCT scanners for dentomaxillofacial applications. *European Journal of Radiology*, **71**, 461–8.
- Low MTL, Dula KD, Bürgin W, von Arx T (2008) Comparison of periapical radiography and limited cone-beam tomography in posterior maxillary teeth referred for apical surgery. *Journal of Endodontics* **34**, 557–62.
- Mah J, Danforth RA, Bumann A, Hatcher D (2003) Radiation absorbed in maxillofacial imaging with a new dental computed tomography device. *Oral Surgery, Oral Medicine, Oral Pathology, Oral Radiology and Endodontology* **96**, 508–13.
- Matherne RP, Angelopoulos C, Kulilid JC, Tira D (2008) Use of cone-beam computed tomography to identify root canal systems *in vitro*. *Journal of Endodontics* **34**, 87–9.
- Nair MK, Nair UP (2007) Digital and advanced imaging in endodontics: a review. *Journal of Endodontics* **33**, 1–6.
- Neelakantan P, Subbarao C, Subbarao VC (2010) Comparative evaluation of modified clearing technique, CBCT, peripheral quantitative CT, spiral CT, and plain and contrast medium-enhanced digital radiography in studying root canal morphology. *Journal of Endodontics* **36**, 1547–51.
- Ng Y-L, Mann V, Gulabivala K (2011) A prospective study of the factors affecting outcomes of nonsurgical root canal treatment: part 1: periapical health. *International Endodontic Journal* **44**, 583–609.
- Özen T, Kamburoglu K, Cebeci AR, Yuksel SP, Paksoy CS (2009) Interpretation of chemically created periapical lesions using 2 different dental cone-beam computerized tomography units, an intraoral digital sensor, and conventional film. *Oral Surgery Oral Medicine Oral Pathology Oral Radiology and Endodontology* **107**, 426–32.
- Patel S (2009) New dimensions in endodontic imaging: part 2. Cone beam computed tomography. *International Endodontic Journal* **42**, 463–75.
- Patel S, Horner K (2009) Editorial: the use of cone beam computed tomography in endodontics. *International Endodontic Journal* **42**, 755–6.
- Patel S, Dawood A, Whaites E, Pitt Ford T (2009a) New dimensions in endodontic imaging: part 1. Conventional and alternative radiographic systems. *International Endodontic Journal* **42**, 447–62.
- Patel S, Dawood A, Mannocci F, Wilson R, Pitt Ford T (2009b) Detection of periapical bone defects in human jaws using cone beam computed tomography and intraoral radiography. *International Endodontic Journal* **42**, 507–15.
- Paula-Silva FWG, Hassam B, da Silva LAD, Leonardo MR, Wu M-K (2009a) Outcome of root canal treatment in dogs determined by periapical radiography and cone-beam computed tomography scans. *Journal of Endodontics* **35**, 723–6.
- Paula-Silva FWG, Júnior MS, Leonardo MR, Consolareo A, Da Silva LAB (2009b) Cone-beam computerized tomographic, radiographic, and histologic evaluation of periapical repair in dogs' post-endodontic treatment. *Oral Surgery Oral Medicine Oral Pathology Oral Radiology and Endodontology* **108**, 796–805.
- Paula-Silva FWG, Wu MK, Leonardo MR, da Silva LAD, Wesselink PR (2009c) Accuracy of periapical radiography and cone-beam computed tomography scans in diagnosing apical periodontitis using histo-pathological findings as a gold standard. *Journal of Endodontics* **35**, 1009–12.
- Rigolone M, Pasqualini D, Bianchi L, Berutti E, Bianchi SD (2003) Vestibular surgical access to the palatine root of the superior first molar: "low-dose cone-beam" CT analysis of the pathway and its anatomic variations. *Journal of Endodontics* **29**, 773–5.



- Soğur E, Baksi BG, Gröndahl H-G, Lomcali G, Sen BH (2009) Detectability of chemically induced periapical lesions by limited cone beam tomography, intra-oral digital and conventional film radiography. *Dentomaxillofacial Radiology* **40**, 458–64.
- Stavropoulos A, Wenzel A (2007) Accuracy of cone beam dental CT, intraoral digital and conventional film radiography for the detection of periapical lesions: an ex vivo study in pig jaws. *Clinical Oral Investigations* **11**, 101–6.
- Tu M-G, Huang H-L, Hsue S-S et al. (2009) Detection of permanent three-rooted mandibular first molars by cone-beam computed tomography imaging in Taiwanese individuals. *Journal of Endodontics* **35**, 503–7.
- Yoshioka T, Kikuchi I, Adorno CG, Suda H (2011) Periapical bone defects of root filled teeth with persistent lesions evaluated by cone-beam computed tomography. *International Endodontic Journal* **44**, 245–52.