

# Extracorporeal Shock Wave Therapy Versus Ultrasonic Therapy on Functional Abilities in Children with Tennis Elbow a Randomized Controlled Trial

AMR A. ABO GAZYA, Ph.D.\*, ABD EL AZIZ A. SHERIEF, Ph.D.\*\* and MOHAMED A. ABD EL GHAFAR, Ph.D.\*\*\*

*The Departments of Basic Science, Faculty of Physical Therapy, Kafr El Shakh University, Egypt\*, Physical Therapy for Growth and Development Disorders in Children and its Surgery, Faculty of Physical Therapy\*\* and Pediatrics, Faculty of Physical Therapy, 6th of October University, Cairo, Egypt\*\*\**

## Abstract

**Background and Purpose:** Extracorporeal shock-wave therapy (ESWT) is low-to medium-energy type of shock-wave therapy. The purpose of the study was to compare the effect of extracorporeal shock wave therapy versus ultrasonic therapy in controlling the elbow pain, muscles weakness and limited range of motion due to tennis elbow in children.

**Design:** Randomized controlled trial.

**Subjects:** Thirty children with tennis elbow with the ages ranged from 12 to 16 years were randomly assigned to either group A (n=15) or group B (n=15) had participated in this study. Group A received a designed physical therapy program and ultrasonic therapy, while the group B received the same physical therapy program in addition to shock wave therapy. Both groups received treatment sessions three times per week for two successive months. The elbow pain was measured by Visual Analog Scale (VAS), range of motion of elbow joint was measured with elastic goniometer and hand grip power was measured by hand held dynamometer before as well as after application of the treatment program.

**Results:** The results revealed no significant differences when comparing the pre-treatment mean values of all measuring variables for the two groups, while significant improvement was observed in the two groups when comparing their pre and post treatment mean values. Also, significant difference was also observed when comparing the post treatment results of the two groups in favor of the study group B.

**Conclusion:** The results suggested that the use of ESWT for the management of tennis elbow is safe and effective, leading to a significant reduction in pain and improvement of elbow function after 8 weeks.

**Key Words:** *Extracorporeal shock wave therapy – Ultrasound therapy – Tennis elbow – Children.*

**Correspondence to:** Dr. Abd El Aziz A. Sherief,  
The Department of Physical Therapy for Growth and Development Disorders in Children and its Surgery,  
Faculty of Physical Therapy  
[E-mail: aabelazez10@yahoo.com](mailto:aabelazez10@yahoo.com)

## Introduction

**LATERAL** epicondylitis or tennis elbow is one of the most common lesions of the arm. This injury is a major challenge, as it is difficult to treat, prone to recurrence, and may last for several weeks or months, with the average duration of a typical episode reported to be between six months and two years [1]. Lateral epicondylitis or Tennis elbow is a condition where the outer part of the elbow becomes painful and tender, usually as a result of a specific strain or overuse [2]. Although it is called “tennis elbow” it should be noted that it is by no means restricted to tennis players. If one hyper extends an elbow in any sports, this may be classified as tennis elbow. Anyone who does a lot of work involving lifting at the elbow or repetitive movements at the wrist is susceptible to tennis elbow [3,4]. The prevalence of tennis elbow has been reported to range from 7% to 36% of the population, and the incidence is estimated to be between 2.5% to 20% [5]. Accurate diagnosis requires a thorough understanding of the anatomic, epidemiologic and pathological factors. Clinical features may include pain and tenderness over lateral epicondyle of the humerus. Pain is burning and radiating to forearm, pain on resisted dorsiflexion of the wrist, middle finger or both, decrease in grip strength, elbow range limited in chronic cases, tightness and inflexibility of forearm muscles and in some cases morning stiffness [6]. The onset of symptoms is usually abrupt after an unaccustomed activity, but it may also be gradual. Repetitive motions like gripping a racket during a swing can strain the muscles and put too much stress on the tendons, that constant tugging can eventually cause microscopic tears in the tissue [7]. Tennis elbow

presents as a history of occupation-or activity-related pain at the lateral elbow. Symptoms are usually reproduced with resisted supination or wrist dorsiflexion, particularly with the arm in full extension. The pain is typically located just distal to the lateral epicondyle over the extensor tendon mass [8]. Approximately 60% to 70% of patients have success with nonsurgical treatment. Conservative treatment includes therapeutic exercise, analgesic and nonsteroidal anti-inflammatory drugs, transcutaneous electrical nerve stimulation, steroid injections, and shock-wave therapy (SWT) [9]. A radial shock wave (RSW) is a low-to medium-energy shock wave that is pneumatically generated through the acceleration of a projectile inside the handpiece of the treatment device and then transmitted radically from the tip of the applicator to the target zone [10]. Radial shock waves show a lower peak pressure and a considerably longer rise time than extracorporeal shock waves (ESWs). Low-energy radial extracorporeal shock-wave therapy (rESWT) is recommended and increasingly being used for patients with tendinitis, calcarea and subacromial shoulder pain [11,12]. A recent experimental study suggests that extracorporeal shock-wave therapy activates the repair process of connective tissues. During the last 10 years, extracorporeal shock-wave therapy (ESWT) has been used successfully in people with tendon and muscle tissue disease [13].

### Patients and Methods

Thirty boys with tennis elbow with the ages ranged from 12 to 16 years were selected from Abu El-Rish Pediatric Hospital and Out-patient Clinic, Faculty of Physical Therapy, Cairo University from April to July 2014. The children were selected with inclusion criteria including, children who were diagnosed as tennis elbow, free from severe tightness or any congenital deformities or cardiopulmonary dysfunctions also they had no sensory impairment or other neurological, psychological problems or receiving muscle relaxant. All children were clinically and medically stable. The exclusion criteria included: Any infectious disease like osteomyelitis around the elbow, any bone tumor around the elbow, radial nerve compression fracture around the elbow joint, ligament injury around the elbow, trauma around the elbow, narcotic abused patients allergy to heat and Patients with sensory loss. The children were randomly assigned into two study groups of equal number: Group A and group B. All procedures involved for evaluation and treatment, purpose of the study, potential risks and benefits were explained to all children and their parents. The work is carried out in accordance

with the code of Ethics of the World Medical Association (Declaration of Helsinki) for experiments involving humans. Parents of the children signed a consent form prior to participation as well as acceptance of the Ethics Committee of the University was taken.

#### *Randomization:*

Following the baseline measurements, randomization process was performed using closed envelopes. The investigator prepared 30 closed envelopes with each envelope containing a card labeled with either group A or B. Finally, each child was asked to draw a closed envelope that contained one of the two groups.

#### *For evaluation:*

*Visual analog scale (VAS):* The severity of elbow pain was evaluated by Visual Analog Scale (VAS) after patients had remained in a weight bearing position (quadruped position). The researcher explained the treatment procedure and the exercise regime with full demonstration to the participant. Operationally a VAS is usually a horizontal line, 100mm in length, anchored by word descriptors at each end. The patient marks the line the point they feel which represents their perception of their current state. The VAS score is determined by measuring in millimeters from left hand end of the line to the point that the patient marks.

*Plastic goniometr:* Active ROM of elbow flexion was measured by Standard BASELINE-12-inch plastic goniometer, (Model 12-1000) Fabrication Enterprises, Inc: White Plains, New York. Measurement of elbow flexion ROM was made with the subject lying supine with the opposite upper extremity extended and the upper extremity being measured positioned beside the patient. The acromion and lateral epicondyle of the humerus and the head of radius were palpated and served as landmarks during measurement. We attempted to maintain shoulder flexion at 0 degrees while the forearm moved into the terminal position of elbow flexion, which was defined as the point at which the subject reported feeling of discomfort.

*Hand held dynamometer:* The muscles power of the hand was measured as by using the hand held dynamometer (JAMAR, IN, USA) that displays grip force in pounds and kilograms (200 pounds or 90 kilograms) with adjustable hand size (5-grip positions). The gage is instrumented with a peak hold needle that retains the highest reading until the examiner resets it. The muscles power were measured according to the standardized position, subject was seated with shoulder adducted

and neutrally rotated, elbow flexed at 90°, forearm in neutral position and wrist between 0°-30° dorsiflexion and 0°-15° ulnar deviation. The subjects were asked to exert maximum squeezing and hold for 2-3 seconds. Each pinch and grip measurement was repeated for three times separated by a resting period of 60 seconds, then the average of three successive trials were recorded.

*For treatment:*

Both groups received a designed physical therapy program which was applied for 45 minutes, three times per week for three successive months. This program included the following: Moist heat for 15 minutes-Gentle stretching exercises for biceps brachii, were done. They were applied for 20sec. stretch followed by 20sec. relaxation and repeated five times per session for each muscle, for 15 minutes (min.) Static muscle contraction for elbow flexors, extensors and shoulders flexors and extensors and hand flexors and extensors for 15min. Each contraction was maintained five counts then relaxed for another five counts for five times initially, building up to 10 repetitions as tolerated, two to three times per day [14].

*In addition, both study groups received the following:*

**Group A:** The children in this group received Ultrasound therapy using a son pulse 434 ultrasound unit at a frequency of 1MHz with an intensity of 1.5w/cm<sup>2</sup>. Position of the child: Sitting with back support Position of Hand: Resting on chair’s arm with pillow under the elbow Position of the Therapist: Sitting Technique: After positioning the patient, ultrasonic gel is applied on the affected area around the lateral epicondylitis and then the UST machine is set up at pulse mode and intensity of 1.2w/cm<sup>2</sup> for 8 minutes is applied. After the treatment treated part is cleaned with cotton swab. The above procedure is repeated day after day continuous for 8 weeks.

**Group B:** The children in this group received radial shock wave delivery system that it’s approved for distribution and use in the United States by the Food and Drug Administration (FDA). Position of the patient: Supine lying or sitting with back support Position of the Therapist: Sitting Application of SWT the treatment area was prepared with a coupling gel to minimize the loss of shock waves at the interface between applicator tip and skin. The treatment was performed with the Shock Master. The applicator (hand-piece) was pressed upon treatment area with application pressure categorized as “medium”. As the patient adjusted to the shock-wave-induced pain, the applied energy was increased during the treatment, analgesia of the treatment zone

was not necessary. Each patient received 2000 shock for one time, energy flux density 0.18mJ/mm<sup>2</sup>, energy level 2-4, pulse rate 160/min., 6Hz).

*Statistical analysis:*

The collected data of the elbow pain, muscle power and range of motion of elbow joint of both groups were statistically analyzed to compare between the effects of the effect of extracorporeal shock wave therapy versus ultrasonic therapy on all the measuring variables in children with tennis elbow. Descriptive statistics were done in the form of mean and standard deviation to all measuring variables in addition to the age, weight and height. *t*-test was conducted for comparing the pre and post treatment mean values of all measuring variables between both groups. Paired *t*-test was conducted for comparing pre and post treatment mean values in each group. All statistical analyses were conducted through SPSS (statistical package for social sciences, version 20).

**Results**

*Subject characteristics:*

Table (1), showed the mean ±SD age, weight, height, and BMI of control and study groups. There was no significant difference between both groups in the mean age, weight, height, and BMI (*p*>0.05).

Table (1): *t*-test for comparison between control and study groups in mean age, weight, height, and BMI.

	Study X±SD	Control X±SD	<i>p</i> value
Age (years)	14±1.36	14±1.35	0.89*
Weight (Kg)	40.06±4.54	39.66±5.43	0.82*
Height (cm)	142.12±4.59	146.33±8.85	0.11*
BMI (kg/cm <sup>2</sup> )	20.75±1.93	21.31±2.55	11.09*

X: Mean. SD: Standard deviation. *p*-value: Level of significance.

There were no significant differences in any of the presented variables between the groups A&B before the intervention period. All participants were present in at least 85% of the training sessions.

**Pain intensity:** The collected data from this study represent the statistical analysis of the pain intensity was measured before and after two months of treatment for the two groups. The raw data of the measured variables for the two groups were statistically treated to determine the mean and standard deviation. Student-test was then applied to examine the significance of the treatment conducted for each group. The obtained results in this study revealed no significant differences when comparing the pre-treatment mean values of the two groups (*p*<0.05). Significant improvement was observed in all the measuring variables of the two

groups study A and study B, when comparing their pre and post-treatment mean values. After treatment significant difference was observed when comparing the post-treatment results of the two groups in favor of the study group B ( $p < 0.05$ ).

Table (2): Comparison between mean values of pain measurements measured pre- and post-treatment within the same group and between the two studied groups.

	Group A (n=15)	Group B (n=15)	p value
Pre	6.53±0.74	6.60±0.81	0.816
Post	3.67±0.62	2.87±0.35	0.001 **
p-value	0.05 **	0.05 **	

Data are expressed as mean ±SD.  
 $p > 0.05$  = Not significant.  
 \*\* $p < 0.01$  = Highly significant.

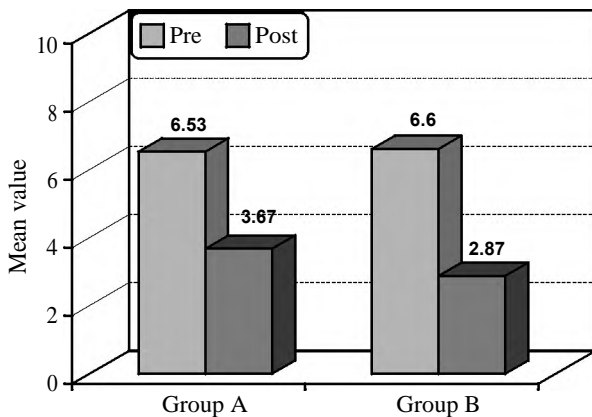


Fig. (1): Comparison between mean values of pain measurements measured pre- and post-treatment within the same group and between the two studied groups.

**ROM of elbow flexion:**

As shown in Table (3) & Fig. (2): There is no significant differences when comparing the pre-treatment mean values of the two groups. Significant improvement was observed in all the measuring variables of the two groups study A and study B, when comparing their pre and post-treatment mean values. After treatment significant difference was observed when comparing the post-treatment results of the two groups in favor of the study group B.

Table (3): Comparison between mean values of elbow range of motion measured pre- and post-treatment within the same group and between the two studied groups.

	Group A (n=15)	Group B (n=15)	p value
Pre	126.73±3.35	128.87±5.82	0.229
Post	137.13±2.83	142.53±2.56	0.05 **
p-value	0.05 **	0.05 **	

Data are expressed as mean ±SD.  
 $p > 0.05$  = Not significant.  
 \*\* $p < 0.01$  = Significant.

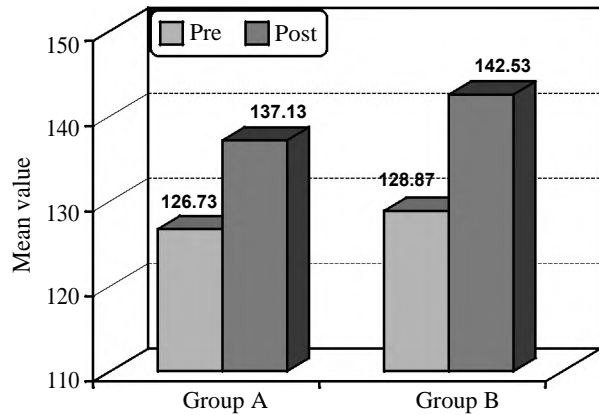


Fig. (2): Comparison between mean values of elbow range of motion measured pre- and post-treatment within the same group and between the two studied groups.

**Muscle power of the hand:**

There was no significant difference between both groups in muscle power pre-treatment ( $p > 0.05$ ). There was significant increase in power of hand grip in the study group compared to the control group post treatment there was a significant differences in hand grip strength in the control and study group when post treatment compared to pre-treatment ( $p < 0.05$ ).

Table (4): Comparison between mean values of hand healed dynamometer measured pre- and post-treatment within the same group and between the two studied groups.

	Group A (n=15)	Group B (n=15)	p value
Pre	28.07±2.58	28.2±2.48	0.886
Post	38.53±2.26	42.93±2.58	0.05 **
p-value	0.05 **	0.05 **	

Data are expressed as mean ±SD.  
 $p > 0.05$  = Not significant.  
 \*\* $p < 0.01$  = Highly significant.

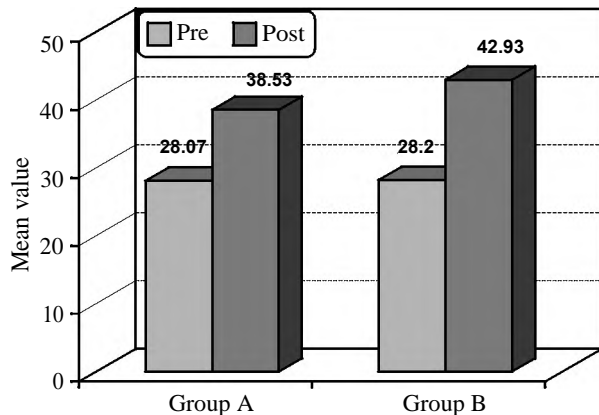


Fig. (3): Comparison between mean values of hand healed dynamometer measured pre- and post-treatment within the same group and between the two studied groups.

## Discussion

In recent decades, quality of life and life expectancy of individuals with tennis elbow have been improved by better quality in treatment and more recent devices. Tennis elbow has lower levels of fitness and strength than their healthy peers. The physical therapist, along with the tennis elbow care team, can assist in preparing an individual to begin or progress to a physical activity program that enhances fitness level, body composition and overall well-being, so this study aimed to compare the effects of shock wave therapy and ultrasonic therapy on functional mobility in children with tennis elbow.

Comparison between the mean values of pre-treatment results of ROM of elbow joint and muscles power of the hand in both groups showed no significant differences but also showed a significant decrease in their values which indicted that those children had a significant functional problem. Also Comparison between the mean values of pre-treatment results of pain measurement in both groups showed no significant differences but also showed a significant increase in their values which indicted that those children had a significant functional problem This comes in agreement with Maffulli et al., [15] who stated that, the larger the numerical value of the pain intensity, the greater the degree of difficulty in elbow mobility.

ROM and muscles power impairments could be due to pain and inflammation in side the joint. This comes in agreement with Wang et al., [16] who mentioned that, tennis elbow children present a decrease of proprioception of joints which can provoke alterations in basic muscles power. Likewise, stability is also impeded in certain positions of joint mobility. Abbott [17] added that, the physical condition, muscular strength, aerobic resistance, and proprioception have all diminished. Wessling et al., [18] mentioned that, tennis elbow joint is characterized by limited range of motion and chronic pain.

Comparing between pre and post treatment mean values of the functional mobility of affected upper limb parameters in the both groups showed significant improvement at the end of the treatment program. This improvement could be attributed to increasing in muscle strength and joint range of motion. This is supported by Boyer et al., [19] who mentioned that an appropriate motor response for upper limb requires an intact sufficient muscle strength and free ROM of the joint to participate

in functional mobility. Krischek et al., [20] emphasized that, regular physical activity is extremely essential for tennis elbow children as it results in such benefits, as increase in muscle strength, flexibility. Tasto et al., [21] state that two recent trials demonstrated that reduced pain and increased functional outcomes after radio frequent micro debridement of the symptomatic tendon in children suffering of tennis elbow.

Finally, comparing the post treatment mean values of all measuring variables shock wave therapy and ultrasonic groups showed that there are significant differences in favor of shock wave group. These differences could be due to more improvement in muscle strength and range of motion which results in improvement in functional mobility. This is supported by Medlock et al., [22] who stated that, shock wave therapy activates the repair process of connective tissues. Matsuno et al., [23] who mentioned that it was found that ESWT induces a long-term tissue regeneration effect in addition to having a more immediate analgic and anti-inflammatory outcomes. A “wash-out” of chemical inflammation mediators, a trigger to neovascularization, and a nociceptive inhibition (gate control theory) has been reported as the main biological effects of ESWT on tissues.

### Conclusion and Recommendation:

In this study, we compared between the effects of shock wave therapy and ultrasonic therapy on pain intensity, ROM of elbow joint and muscles power of the hand in children tennis elbow. The obtained results showed significant improvement in the post-treatment mean values of all measuring variables on pain intensity, ROM of elbow joint and muscles power of the hand in favor of shock wave therapy. So, it is recommended to include shock wave therapy as principle component in physical therapy programs directed toward improvement of functional ability of affected arm.

### Acknowledgments:

The authors express their thanks to all children and parents for their confidence and collaboration in this study. Also, the authors declare no conflict of interest or funding for this research.

## References

- 1- HURT G. and BAKER C.L. Jr.: Calcific tendinitis of the elbow. *Orthop. Clin. North. Am.*, 34: 567-575, 2009.
- 2- LUNDBERG J.: The prevalence of tennis elbow: Clinical and radiographical observations-the effect of manipulation under general anesthesia, structure and glycosaminoglycan content of the joint capsule, local bone metabolism. *Acta. Orthop. Scand*, 119 (Suppl): 1-59, 2008.

- 3- RUPP S., SEIL R. and KOHN D.: The incidence of tennis elbow. *Orthoped.*, 29: 852-867, 2010.
- 4- McKENDRY R.J., UHTHOFF H.K., SARKAR K. and HYSLOP P.S.: Calcifying tendinitis of the elbow: Prognostic value of clinical, histologic, and radiologic features in 57 surgically treated cases. *J. Rheumatol.*, 9: 75-80, 2002.
- 5- UHTHOFF H.K., SARKAR K. and MAYNARD J.A.: Calcifying tendinitis: A new concept of its pathogenesis. *Clin. Orthop. Relat. Res.*, 118: 164-168, 2006.
- 6- GIMBLETT P.A., SAVILLE J. and EBRALL P.: A conservative management protocol for calcific tendinitis of the elbow. *J. Manip. Physiol. Ther.*, 22: 622-627, 2009.
- 7- BANG M.D. and DEYLE G.D.: Comparison of supervised exercise with and without manual physical therapy for patients with tennis elbow. *J. Orthop. Sports Phys. Ther.*, 30: 126-137, 2008.
- 8- KAADA B.: Treatment of peritendinitis calcarea of the tennis elbow by transcutaneous nerve stimulation. *Acupunct. Electrother. Res.*, 9: 115-125, 2004.
- 9- WAGENHAUSER F.J.: Clinical physical examination of patients with tennis elbow. *Z. Allgemeinmed.*, 48: 451-469, 2008.
- 10- ROMPE J.D. and WIRTH C.J.: Medical treatment of tennis elbow: *Orthopade.*, 31: 609, 2002.
- 11- GERDESMEYER L., WAGENPFEIL S., HAAKE M., et al.: Extracorporeal shock wave therapy for the treatment of chronic calcifying tendonitis of the rotator cuff: A randomized controlled trial. *JAMA*, 290: 2573-2580, 2003.
- 12- HSU C.J., WANG D.Y., TSENG K.F., et al.: Extracorporeal shock wave therapy for calcifying tendinitis of the shoulder. *J. Shoulder. Elbow. Surg.*, 17: 55-59, 2008.
- 13- GREEN S., BUCHBINDER R., GLAZIER R. and FORBES A.: Systematic review of randomised controlled trials of interventions for painful shoulder: Selection criteria, outcome assessment, and efficacy. *BMJ*, 316: 354-360, 1998.
- 14- MOUZOPOULOS G., STAMATAKOS M., MOUZOPOULOS D. and TZURBAKIS M.: Physical activity recommendations for children with specific chronic health conditions. *Paediatr Child Health*, 15 (4), 2010.
- 15- MAFFULLI D., WILLIAMSON A. and HOGGART B.: Pain: A review of three commonly used pain rating scales. *J. Clin. Nurs.*, 14: 798-804, 2005.
- 16- WANG D., VICENZINO B. and WRIGHT A.: Lateral epicondylalgia. I. Epidemiology, pathophysiology, aetiology and natural history. *Phys. Ther. Rev.*, 1: 23-34, 1996.
- 17- ABBOTT J., HAAKE M., TOSCH A., et al.: Ultrasonic therapy for tendinitis of the supraspinatus: A prospective, randomised study. *J. Bone. Joint. Surg. Br.*, 83-B: 873-6, 2001.
- 18- WESSLING F., VICENZINO B.F. and WEBER K.: Experimental models of cartilage repair: Improved cartilage repair after treatment with low-intensity pulsed ultrasound. *Clin. Orth. Rel. Res.*, (391 Suppl.): S231-43, 2008.
- 19- BOYER C. EBENBICHLER V. and KASHMAN N.: Lateral humeral epicondylitis-a study of natural history and the effect of conservative therapy. *J. Rheumatol.*, 22: 73-76, 2009.
- 20- KRISCHEK M., EBENBICHLER G.R., ERDOGMUS C.B., RESCH K.L., et al.: Ultrasound therapy for calcific tendinitis of the shoulder. *N. Engl. J. Med.*, 340: 1533-1538, 1999.
- 21- TASTO S., WANG J.D., HOPF C., KULLMER K., HEINE J. and BURGER R.: Analgesic effect of extracorporeal shock-wave therapy on chronic tennis elbow. *J. Bone. Joint. Surg. Br.*, 78-B: 233-7, 1996.
- 22- MEDLOCK G., KRISCHEK O., HOPF C., NAFE B. and ROMPE J.D.: Shock-wave therapy for tennis and tennis elbow: One year follow-up. *Arch. Orth. Trauma. Surg.*, 119: 62-6, 2009.
- 23- MATSUNO N., RICHTER D., EKKERNKAMP A. and MUHR G.: Extracorporeal shock-wave therapy: An alternative concept for the treatment of epicondylitis of the humerus and radius? *Orthoped.*, 24: 303-6, 2008.