

## Plastic Surgery

Original Research Paper

# Contrast Enhanced Ultrasound (Ceus) in Detecting Ruptured Breast Implants Ex Vivo –Preliminary Results of a Unique Technique

Kuehlmann Britta<sup>1,2\*</sup> M.D., Jung E. M.<sup>3</sup> M.D., Clevert Dirk-André<sup>4</sup> M.D., Dreiner U. Helen<sup>5</sup> M.D., Prantl Lukas<sup>1</sup> M.D.

<sup>1</sup>Center for Plastic, Aesthetic, Hand & Reconstructive Surgery, University Hospital Regensburg, Regensburg, Germany

<sup>2</sup>Department of Surgery, Hagey Laboratory for Pediatric Regenerative Medicine, Stanford University School of Medicine, Stanford, California, USA

<sup>3</sup>Department of Diagnostic Radiology and Interdisciplinary Ultrasound Department, University Hospital Regensburg, Regensburg, Germany

<sup>4</sup>Department of Clinical Radiology, Ludwig-Maximilians-University of Munich-Großhadern Campus, Munich, Germany

<sup>5</sup>Department of Rheumatology, Slocum Dickson Medical Group, New Hartford, New York, USA

\*Corresponding author(s): Britta Kuehlmann, M.D., Department of Surgery, Hagey Laboratory for Pediatric Regenerative Medicine, Stanford University School of Medicine, Stanford, CA, USA;  
Center of Plastic, Aesthetic, Hand and Reconstructive Surgery  
Franz-Josef-Strauß-Allee 11  
93053 Regensburg, Germany  
Email: Britta.Kuehlmann@gmx.de

Accepted: 2016.12.21; Published: 2016.00.00.

## ABSTRACT

**Introduction:** Detection of ruptured breast implants can be challenging, even with MRI. The aim of this study was to examine different breast implants ex vivo with contrast-enhanced ultrasound (CEUS) to determine whether this technique allows screening of implant failure. **Objectives:** 20 breast implants were examined. Ultrasound was performed using B-mode and CEUS with a multifrequency linear probe after injecting SonoVue to a box filled with NaCl. For interpretation, a scoring system was created (CEUS 1: intact implant, CEUS 5: obvious leakage, called macro-leakage). **Results:** CEUS was able to detect leakages of all implants, including micro-leakages, verified via microscopy (sensitivity: 100%). Polyurethane (PU) implants with CEUS 2 had a median time of implantation of 14.1 years, silicone implants with CEUS 5 were implanted 3.1 years on average. Silicone implants displayed no significant linear correlation between foreign body capsule formation (Baker score) and CEUS score (correlation coefficient  $r=0.08$ ). Most of the PU implants with lower Baker grade 3 showed a lower CEUS grade and vice versa, leading to a high correlation ( $r=0.77$ ). **Conclusions:** CEUS can be useful to detect implant rupture as an additional method for patients with equivocal sonographic findings. This is a new technique that can help diagnose surface qualities of breast implants.

**Keywords:** Ultrasound, breast Implants, Ex vivo, Implant Failure, Silicone Implants

## INTRODUCTION

Breast augmentation with breast implants is a favored procedure in women for reconstructive and aesthetic purposes. In 2015 it has been the most frequently performed cosmetic surgical procedure in 2015 (up 10% compared to 2014). According to the International Society for Aesthetic Plastic Surgery (ISAPS), there were more than 46.627 breast augmentations with implants in Germany[1]. However, breast implants often impede the imaging of surrounding soft tissue of the breast as well as the implant itself.

Breast implants and their safety are of great public interest as complications are common[2]. In 2011 the FDA published an update on the safety of silicone breast implants declaring MRI to be the most effective method to detect silent implant rupture, recommending a follow-up every two years after augmentation[3]. Shortly thereafter, Song et al. published a meta-analysis on the diagnostic precision of MRI in identifying silicone breast implant rupture. Their study portended that MRI, with a sensitivity of 87.0% and a specificity of 89.9%, was flawed with methodological biases and a 14-fold higher accuracy rate in patients with symptoms compared to asymptomatic patients[4].

Clinical examination of women with breast implants is done by palpation using the Baker Score[5,6]. Unfortunately, this common measurement classification depends on the examiner's expertise, introducing subjectivity into the measurement. Needless surgical explanations of breast implants in the event of a false positive or false negative MRI are an undesirable consequence. In 2015 Stachs et al. used high-resolution ultrasound with real-time elastography to detect implant ruptures including silent ruptures, concluding that this diagnostic tool may enhance implant surveillance, making MRI possibly obsolete in the future[7]. Until now such investigations have not been done for unused implants.

MRI is not always available, is expensive and has several contraindications, making follow-ups periodically difficult.

Contrast-enhanced ultrasound (CEUS) is known to dynamically evaluate micro vascularization of tissue. Ultrasound contrast agents with microbubbles, used to increase vascular signals in sonography, have been shown to improve color-coded Doppler sonography. Generally, CEUS is used to improve the quality of ultrasound scans[8–10]. So far, there is no comparable study using CEUS to characterize non-vital materials, such as breast implants, in a non-vital setting, with the flow of contrast agent microbubbles that usually depend on circulating bloodstream.

The aim of this study was to use CEUS with SonoVue® as a novel examination tool to detect integrity or rupture of breast implants. As there is no existing efficient diagnostic standard to determine breast implant's integrity precisely *ex vivo*, we established a new scoring system to examine these parameters with CEUS *ex vivo*. This knowledge might represent an innovative strategy to accurately evaluate breast implants *in vivo*.

## MATERIALS AND METHODS

### Study Protocol

Twenty breast implants including ten silicone and ten polyurethane (PU) implants were examined. In each group two implants were unused and served as controls, the other eight had been explanted from patients. We had previously reported that it is possible to evaluate different breast implant qualities with elastography and multifrequency ultrasound using different settings[11]. Based on these findings, a specific protocol was developed to screen each implant with CEUS to detect leakage *ex vivo*. There was no patient overlap with our previous study.

The protocol was performed by a panel consisting of one plastic surgeon and one experienced diagnostic radiologist. Clinical correlation was done by using Baker score (Table 1).

**Table 1: Baker Classification System**

Grade	Baker score
1	Breast and implant shell are soft and not palpable, breast appears natural in size and shape
2	Breast and implant shell are slightly firm, breast appears normal
3	Breast and implant shell are clearly firm, implant is visible, breast appears abnormal
4	Breast and implant shell are firm, implant dislocation/deformation, breast is painful to the touch and appears abnormal

Two examiners assessed the breast preoperatively by palpation using Baker scoring criteria to reduce possible inter-physician variability. Two investigators in consensus divided the patients into groups according to Baker score. Indication for breast implant exchange or removal was a pain, foreign body sensations or an abnormal appearance of the breast. In our cases, grade 3 and grade 4 implied surgical revision. Baker graduation was done blinded to the radiologist's data, collected subsequently and all aspects of the technical evaluation were done in the absence of knowledge of Baker score, so results

were not influenced by clinical or radiological findings. The study was approved by the local university ethics committee.

### Surgical Technique

Surgical removal of the breast implant was necessary for all participating patients. The pre-existing incision scar was used for exchange or removal of the breast implant. Surgery was performed diligently to not further harm the implant iatrogenic. After explantation, the implant was examined for visible or

macro-leakages. Some of the explanted devices showed visible macro-leakages, whereas others seemed to be intact upon explantation. Observed leakages were marked with a sterile, waterproof-marker intraoperatively for subsequent localization. After that, each implant was put into a sterile box and handed over to the radiologist.

### **CEUS Examination**

Each breast implant was transferred immediately into a sterile box filled with 1-liter isotonic saline solution (NaCl 0.9%, B. Braun, Melsungen, Germany) using a standardized protocol. First, the whole implant was examined using two multifrequency linear transducers (6–9 MHz and 6–15 MHz, LOGIQ E9, GE Healthcare). A B-mode sonography of each breast implant in sweep technique was performed, connecting the linear probe directly to the implant surface. After that, 1ml of second-generation ultrasound contrast agent SonoVue® (SonoVue®, Bracco, Milan, Italy) was added and the examination was done with a probe using a sweep technique with digital storage of loops. Contrast harmonic imaging technique (CHI) was used for real-time evaluation of the contrast dynamic effects. Mechanical index (MI) was reduced

at less than 0.16 to realize the low MI technique of pulse inversion harmonic imaging.

The whole surface was scanned and digital images and cine loops in DICOM were stored. Implants with the irregular destruction of the surface or a penetration of micro bubbles into the implants were labeled at the surface in the region of penetration. The complete data of the contrast agent examination was recorded up to five minutes. To optimize penetration, the inner filling of breast implants was examined using harmonic imaging technique with CEUS and a 6–9 MHz linear probe.

Two independent readers performed analysis and evaluation in consensus. To obtain a stringent analysis of each examined implant a subjectively chosen classification system, called CEUS score (Table 2), was developed. Five different grades were chosen to distinguish the implant's shells integrity and the frequency of the contrast agent penetration. Score 1 implied a completely intact implant shell without any penetration of the contrast agent, whereas grade 5 showed macro-leakage with a high amount of microbubble infiltration. Leakages greater than or equal to 5 were characterized as macro-leakages.

**Table 2: CEUS Score**

Grade	CEUS score
1	Implant completely intact, no penetration of contrast agent
2	Surface proportionally regular, tiny penetration of contrast agent (<1mm)
3	Irregularity of the implant contour, 1-4mm discontinuity of surface, slight penetration of contrast agent
4	Significant irregularity of the implant contour, definite penetration of contrast agent inside the implant
5	Macro-leakage, obvious penetration of contrast agent

Penetration of the microbubbles (SonoVue®) into the implant indicated macro- or micro-leakages. The leakages were carefully marked with a sterile, waterproof marker and verified using a light microscope (Axiostar Plus, Carl Zeiss®, Goettingen, Germany) with 40 x objective magnification (CP-Achromat 40x/0,65; ∞/0,17).

### **Image Analysis**

All examinations were analyzed by two independent readers in consensus. For each modality used, the observer recorded the diagnostic findings according to the CEUS score. Imaging modalities were evaluated by the stored digital images and cine loops up to 10 sec using the data analysis software of the ultrasound system (LOGIQ E9, GE). The microscopic verification of leakages was done by one experienced biologist.

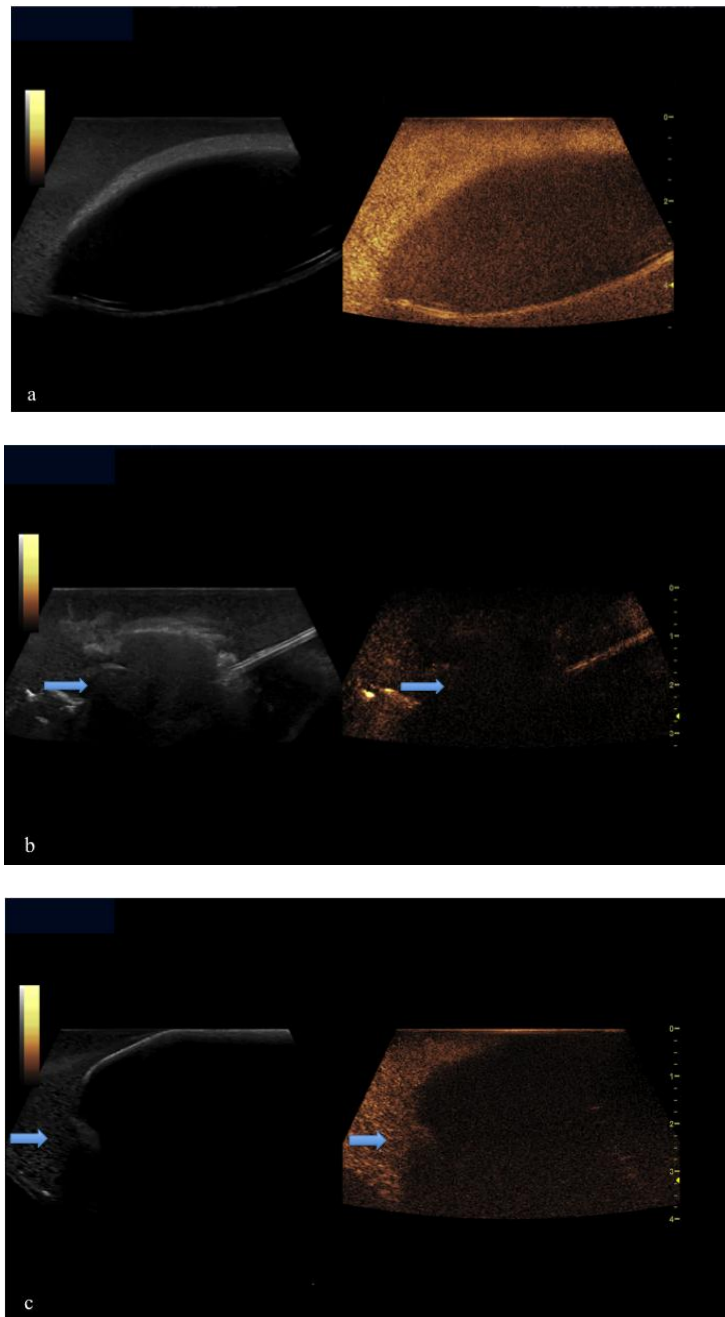
### **Statistical Analysis**

An independent reading of the ultrasound- and CEUS- digitally stored images was performed on the DICOM reading system

of the ultrasound machine (LOGIQ Works /GE). Statistical analyses were performed using SPSS Statistics for Mac OS (version 21.0; IBM SPSS Inc., Chicago, IL, USA). All data are presented as mean ± standard deviation (SD). Continuous variables were reported as median. Paired comparisons t-test for dependent samples and a two-sample t-test assuming unequal variances were used. Correlations were estimated by Pearson's test. Values of p less than 0.05 were considered significant.

### **RESULTS**

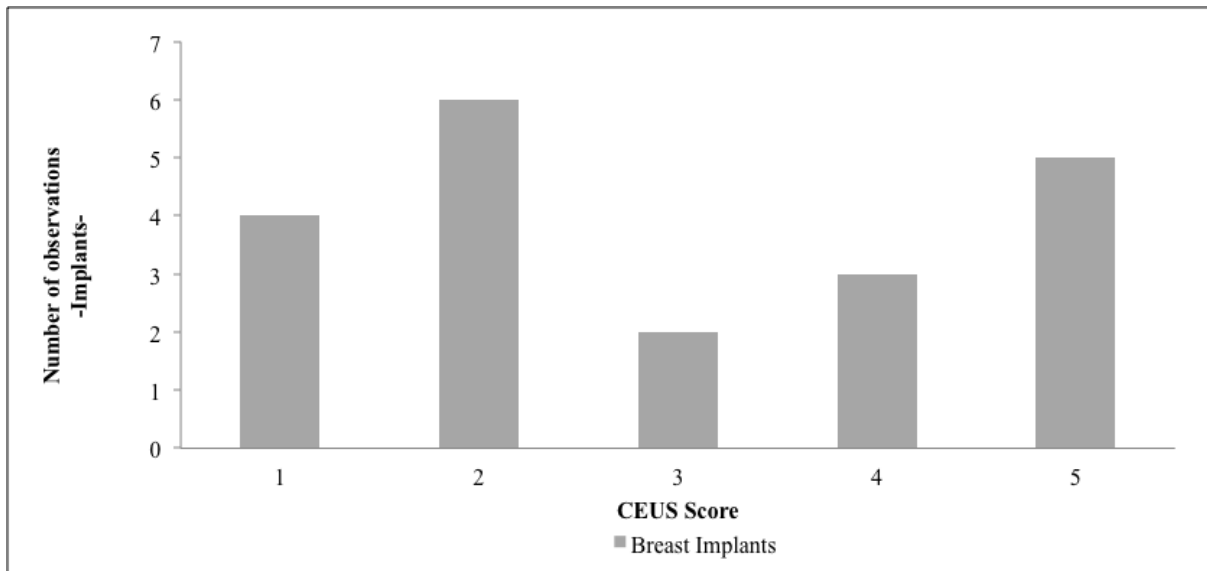
Twenty implants were examined in total, whereby one group consisted of 10 silicone implants and the other group of 10 polyurethane (PU) implants. In each group, two implants were unused devices while the others had been explanted. Using high-resolution CEUS with dynamic evaluation of penetration inside of the implants in cases of leakages, all defects had been detected as defects of the surface (Fig. 1) and were subsequently verified via microscopy.



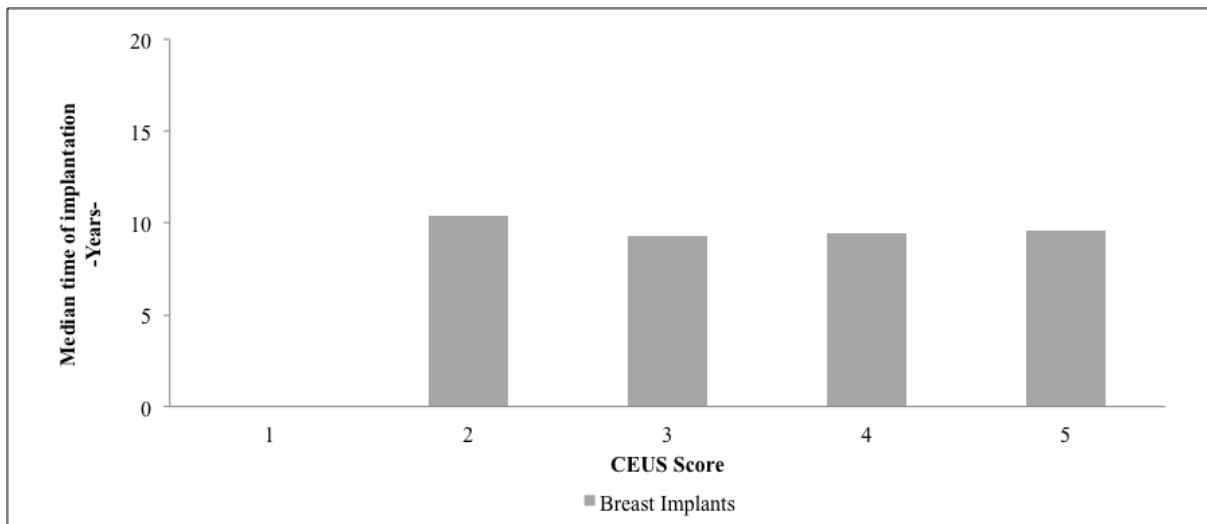
**Fig. 1** Breast implant shown in side by side B-mode and CEUS  
 (a) Intact implant without rupture (CEUS score 1) (b) Ruptured implant with macro-leakage (CEUS score 5) (c) Implant with slight penetration of microbubbles inside the implant (CEUS score 3)

All unused devices (two silicone and two PU) showed no leakages or fissures (CEUS score 1). Intraoperatively, two breast implants (one silicone and one PU) showed clear leakage which was verified using CEUS and scored as CEUS 5 (Fig. 2). Comparing these results with the median time of implantation a total of six implants with a median time of implantation of 14.11 years were scored CEUS 2. Two implants with a median time of implantation of 9.28 years

showed irregularities of their contour with a slight penetration of microbubbles into their inside and were found to correspond to CEUS 3. Three breast implants which were implanted for a median time of 9.43 years were scored CEUS 4. Five breast implants with the median time of implantation of 9.59 years showed an obvious penetration of contrast agent and were scored CEUS 5; unused devices were not included (Fig. 3).



**Fig. 2:** Number of observations of breast implants and CEUS score



**Fig. 3:** Median time of implantation of breast implants and CEUS score

Correlation ( $r = 0.40$ ) between CEUS and Baker score was fairly pronounced (Fig. 4). This medium correlation results from a low correlation for silicone implants ( $r = 0.08$ ) and a high correlation for PU implants ( $r = 0.77$ ) (Fig. 5).

There was no linear correlation between Baker score and CEUS score ( $r = 0.08$ ) for silicone implants. Three of five silicone implants (60%) with Baker grade 3 were diagnosed with the highest CEUS score 5, indicating a macro-leakage. Additionally, there was one silicone implant, without any leakage detected with CEUS, but preoperatively diagnosed Baker grade 3, because of the abnormal appearance of the breast. PU breast implants had a high correlation between Baker and CEUS score. Most of the PU implants with a lower Baker grade 3 showed a lower CEUS grade and vice versa in ascending order. CEUS detected significant irregularity or macro-leakages (CEUS score 4 or 5) in PU implants that were preoperatively evaluated Baker grade 4, corresponding to a high correlation coefficient ( $r = 0.77$ ) (Fig. 5).

Each of the twenty breast implants that were analyzed with CEUS, were subsequently examined using a light microscope. (sensitivity of CEUS: 100%). Previously detected irregularities with CEUS, such as fissures or leakages of the implants, were confirmed by microscopy (Fig. 6)

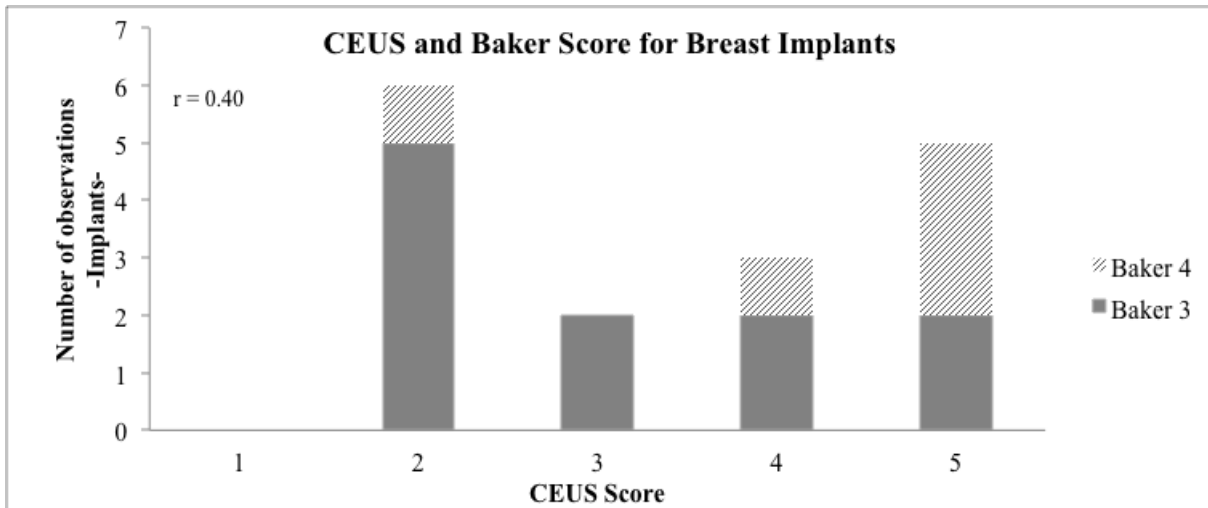


Fig. 4: Correlation between CEUS score and Baker score for breast implants in total

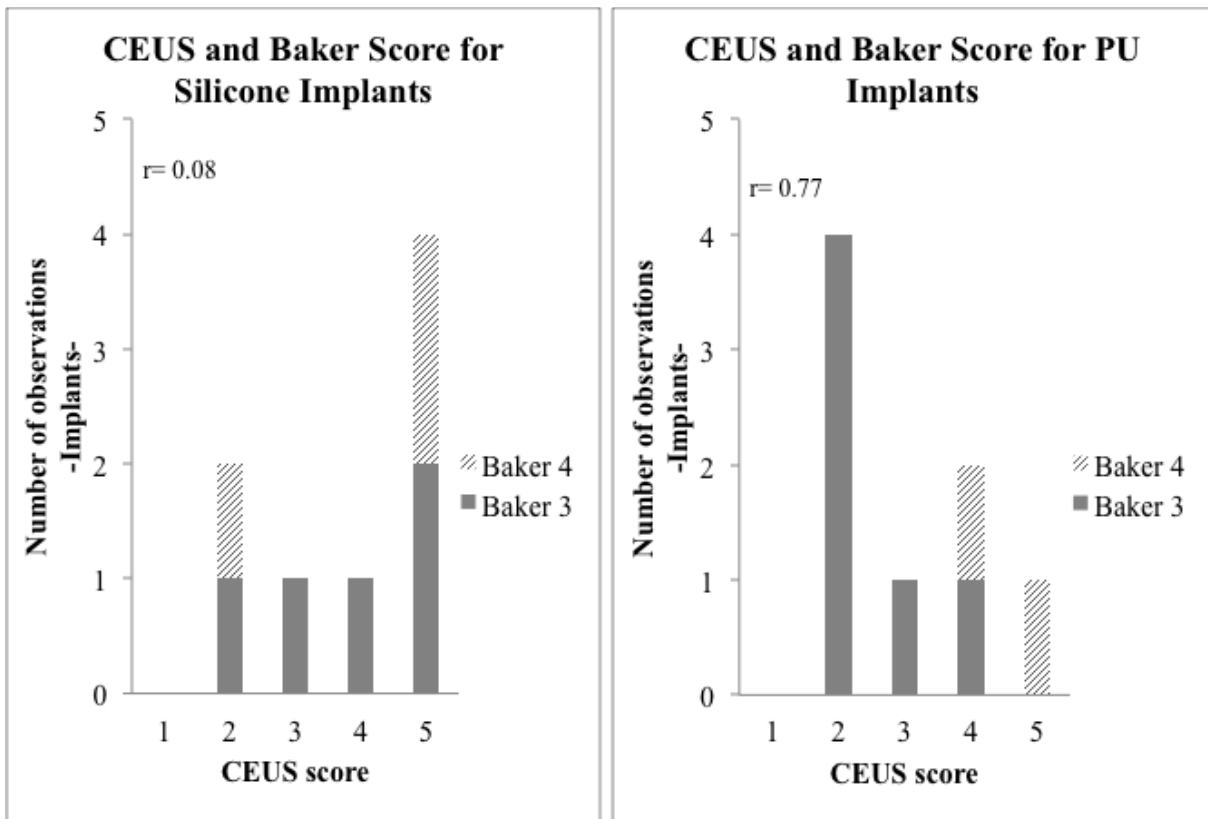
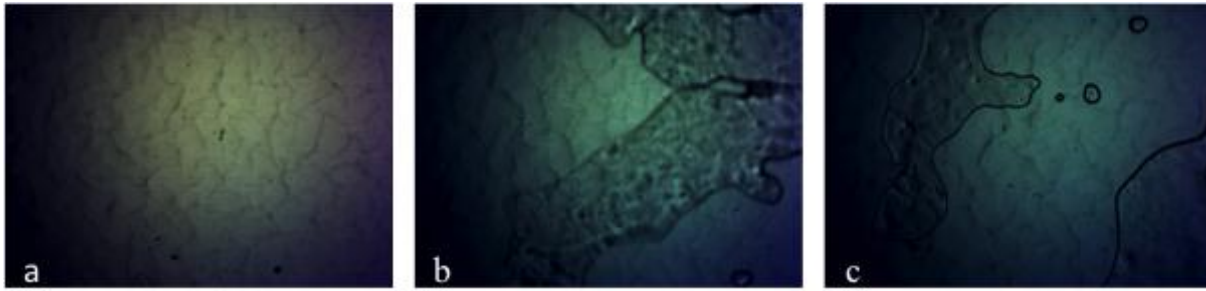


Fig. 5: Correlation between CEUS score and Baker score for silicone and PU implants



**Fig. 6:** Microscopy (magnification x40) of breast implant (a) Overview: Intact silicone implant without rupture. (b) Rupture of breast implant with penetration of silicone. (c) Rupture of implant with penetration and drops of silicone.

## DISCUSSION

Our current study aimed at developing a novel diagnostic tool and determining the correlation between Baker and CEUS score. In general, CEUS is useful to detect malignant or benign processes depending on the vascularization of living tissues. The principal finding of this study is the ability to detect integrity or rupture of breast implants *ex vivo* with the help of SonoVue®, although there is no vascular microcirculation. We showed a new application for CEUS using ultrasonic contrast media, like sulphur hexafluoride microbubbles. A potential explanation for the observed penetration of SonoVue® into the implants might be the passive transport of ultrasound contrast agents in a liquid surrounding without other disruptive factors.

An alternative explanation might be the use of multifrequency linear probes including tissue harmonic imaging and reduction of the mechanical index (MI) to less than 0.16. This technique helps to realize the low MI technique of pulse inversion harmonic imaging allows an oscillation of microbubbles for evaluation of the dynamic effects and enables penetration inside the implants. Microbubbles can be imaged as echoes with a high-intensity in contrast to their surroundings. This technique might serve as a potential strategy and a more sensitive screening tool to identify the integrity of breast implants *ex vivo*, with promising implications for future clinical applications. Additionally, the scoring system presented here to classify breast implants in terms of their integrity or rupture status may be helpful in enhancing clinical diagnosis.

According to ISAPS statistics, breast augmentation is ranked number one among surgical procedures worldwide in 2015[1]. Since the development of breast implants, they have undergone steady enhancements to improve their safety. Nevertheless, surgeons are still facing the short- and long-term consequences of implants. Breast implant rupture or leakage is a common complication. In 1999 Marotta et al. reported a 30% prevalence of breast implant rupture five years after augmentation, 50% at implant age of 10 years and 70% at 17 years[12]. A literature review reveals that the median age of implant ruptures is about 10.8 years (95% confidence interval (CI): 8.4–13.9 yrs)[13] with an incidence rate of 5.3 ruptures/100 implants per year (95% CI, 3.5–7.1)[14]. Sometimes there are silent ruptures of breast implants, that are not noticed by a patient because the implant is not dislocated or deformed and the rupture occurs within the breast capsule.

Another complication can be the so-called 'gel bleed' in breast implants. This phenomenon occurs with the microscopic diffusion of silicone gel through the intact implant shell. MRI is described to be the most effective method for identifying breast

implant ruptures[15–17], however, it has limitations in detecting all ruptures accurately[18]. The majority of gel bleeds cannot be detected by MRI. Lindenblatt et al. showed that rupture of only the inner layers of the implant shell with the integrity of the outer shell causes misdiagnoses on MRI[19]. MRI can be associated with high costs. Chung et al. analyzed in 2012 that the cost of screening and management of rupture with MRI ranges between \$2,067 and \$2,143[20] per implant rupture.

The need for revisions in the case of asymptomatic ruptures of breast implants is not clear. Similarly, the need for established radiological criteria to indicate surgical revision also needs further investigation. The surgical removal of the breast implant still is the gold standard for patients having pain or abnormal appearance. In the case of missing pain, frequent clinical follow-ups should be considered.

Bengtson et al. investigated alternative methods to precisely analyze breast implants[21]. They found high-resolution linear ultrasound (HRUS) to be useful to obtain remarkably good visualization of fourth- and fifth-generation silicone gel implants *in vitro* and *ex vivo*. In addition, ultrasound compound elastography seems to be helpful to evaluate the peri-implant capsule, the implant, and the surrounding tissue[22]. But still, a valid screening and detecting method for implant failure is lacking. To understand how medical devices behave inside the human body, we wanted to enhance the knowledge of different implant modalities to help improve future diagnostics. This requires an understanding of the numerous variations in implant construction that is encountered clinically. This knowledge of implant construction and appearance could help to avoid misdiagnosis of the different types of breast implants. There has not been an *ex vivo* study of different breast implants using an established radiologic method like CEUS yet. It is known for its intraoperative use that has a better sensitivity for identifying malignant liver lesions compared to intraoperative ultrasound or pre-operative imaging with CT or MRI[23].

But for CEUS a special ultrasound technique is necessary, using multifrequency linear probes including the tissue harmonic imaging and the technique of reduced mechanical index (MI<0.16) harmonic imaging. This enables oscillation of the microbubbles for up to 10 minutes without destruction. In this technique, CEUS is used for many clinical evaluations, including detection of breast tumors[24]. For endoprosthesis leakages after endovascular repair, CEUS is an excellent diagnostic tool in comparison to CT and MRI[25,26]. For breast implants, this is a first step towards the introduction of CEUS for the clinical use. The safety of SonoVue® has been proven in several studies[27–29]. It has clinical utility for patients with kidney or thyroid diseases because it is intravascularly

metabolized. Contrast-enhanced ultrasound has several advantages in comparison to other radiographic tools. It may reduce the need for more expensive diagnostic testing prospectively.

## CONCLUSIONS

Clinical symptoms should remain the leading impetus for further diagnostic testing and consideration of breast implant removal. CEUS can not only be a useful tool to evaluate the peri-implant breast capsule and its surrounding tissue but the implant itself can also be examined. As seen in this study, CEUS with SonoVue® presents a novel diagnostic tool to detect ruptures, irregularities, and leakages of breast implants in vitro. This diagnostic tool could be further developed as a screening method for breast implant integrity for clinical applications. Here, we showed that microbubbles penetrated into ruptures of breast implants when placed in saline. Similarly, it might be possible to apply a contrast agent in the surrounding tissue of a breast implant to evaluate breast implants in vivo in clinical practice.

However, further research is required to develop and advance our encouraging preliminary findings with CEUS. This new diagnostic procedure may enhance breast screening and contribute to preventing delays in diagnosis for breast implant-related complications in clinical practice.

## REFERENCES

- [1] ISAPS International Society of Aesthetic Plastic Surgeons. International Survey on Aesthetic/Cosmetic Procedures Performed in 2015. Available at: <http://www.isaps.org/Media/Default/global-statistics/2016%20ISAPS%20Results.pdf>. Accessed September 28, 2016.
- [2] M. Middleton, M. McNamara, *Radiographics* 2000, 20, 3.
- [3] Center for Devices and Radiological Health/U.S. Food and Drug Administration. FDA Update on the Safety of Silicone gel-filled breast implants, June 2011. Available at: <http://www.fda.gov/downloads/MedicalDevices/ProductsandMedicalProcedures/ImplantsandProsthetics/BreastImplants/UCM260090.pdf>. Accessed September 28, 2015.
- [4] J. W. Song, H. M. Kim, L. T. Bellfi, K. C. Chung, *Plast Reconstr Surg*. 2011, 127, 1029.
- [5] J. E. Mara, J. J. Baker Jr., *Rocky Mt Med J*. 1978, 75, 255.
- [6] S. L. Spear, J. L. Baker Jr., *Plast Reconstr Surg*. 1995, 96, 1119.
- [7] A. Stachs, M. Dieterich, S. Hartmann, J. Stubert, T. Reimer, B. Gerber, *Aesthet Surg J*. 2015, 35, 410.
- [8] E. M. Jung, N. Platz Batista da Silva, W. Jung, S. Farkas, C. Stroszczyński, J. Rennert, *PLoS One*. 2015, 10, e0123737.
- [9] M. Takahashi, K. Hasegawa, J. Arita, S. Hata, T. Aoki, Y. Sakamoto, Y. Sugawara, N. Kokudo, *Br J Surg*. 2012, 99, 1271.
- [10] M. Loss, J. Schneider, W. Uller, P. Wiggermann, M. N. Scherer, W. Jung, H. J. Schlitt, C. Stroszczyński, E. M. Jung, *Clin Hemorheol Microcirc*. 2012, 50, 65.
- [11] B. Kuehlmann, L. Prantl, E. M. Jung, *Clin Hemorheol Microcirc*. 2016, 61, 1.
- [12] J. S. Marotta, C. S. Widenhouse, M. B. Habal, E. P. Goldberg, *J Biomed Mater Res*. 1999, 48, 354.
- [13] S. L. Brown, M. S. Middleton, W. A. Berg, M. S. Soo, G. Pennello, *AJR Am J Roentgenol*. 2000, 175, 1057.
- [14] L. R. Hölmich, S. Friis, J. P. Fryzek, I. M. Vejborg, C. Conrad, S. Sletting, K. Kjølner, J. K. McLaughlin, J. H. Olsen, *Arch Surg*. 2003, 138, 801.
- [15] D. J. Cher, J. A. Conwell, J. S. Mandel, *Ann Plast Surg*. 2001, 47, 367.
- [16] D. M. Ikeda, H. B. Borofsky, R. J. Herfkens, A. M. Sawyer-Glover, R. L. Birdwell, G. H. Glover, *Plast Reconstr Surg*. 1999, 104, 2054.
- [17] D. P. Gorczyk, *Magn Reson Imaging Clin N Am*. 1994, 2, 659.

- [18] M. S. Middleton, *Radiol Clin North Am*. 2014, 52, 591.
- [19] N. Lindenblatt, K. El-Rabadi, T. H. Helbich, H. Czembirek, M. Deutinger, H. Benditte-Klepcko, *Int J Womens Heal*. 2014, 6, 703.
- [20] K. C. Chung, S. Malay, M. J. Shauver, H. M. Kim, *Plast Reconstr Surg*. 2012, 130, 225.
- [21] B. P. Bengtson, F. F. Eaves, *Aesthetic Surg J*. 2012, 32, 157.
- [22] L. Prantl L, M. A. Enlbrecht, M. Schoeneich, B. Kuehlmann, E. M. Jung, R. Kubale, *Clin Hemorheol Microcirc*. 2014, 58, 521.
- [23] E. M. Jung, D. A. Clevert, A. G. Schreyer, S. Schmitt, J. Rennert, R. Kubale, S. Feuerbach, F. Jung, *World J Gastroenterol*. 2007, 13, 6356.
- [24] T. Fischer, I. Sack, A. Thomas, *Rofo*. 2013, 185, 816.
- [25] J. Bamber, D. Cosgrove, C. F. Dietrich, J. Fromageau, J. Bojunga, F. Calliada, V. Cantisani, J. M. Correas, M. D'Onofrio, E. E. Drakonaki, M. Fink, M. Friedrich-Rust, O. H. Gilja, R. F. Havre, C. Jenssen, A. S. Klausner, R. Ohlinger, A. Saftoiu, F. Schaefer, I. Sporea, F. Piscaglia, *Ultraschall Med*. 2013, 34, 169.
- [26] D. Cosgrove, F. Piscaglia, J. Bamber, J. Bojunga, O. H. Gilja, A. S. Klausner, I. Sporea, F. Calliada, V. Cantisani, M. D'Onofrio, E. E. Drakonaki, M. Fink, M. Friedrich-Rust, J. Fromageau, R. F. Havre, C. Jenssen, R. Ohlinger, A. Săftoiu, F. Schaefer, C. F. Dietrich, *Ultraschall Med*. 2013, 34, 238.
- [27] D. Bokor, J. B. Chambers, P. J. Rees, T. G. Mant, F. Luzzani, A. Spinazzi, *Invest Radiol*. 2001, 36, 104.
- [28] N. Jiang, B. Xie, X. Zhang, M. He, K. Li, J. Bai, Z. Wang, J. He, L. Zhang, *Cardiovasc Intervent Radiol*. 2014, 37, 1321.
- [29] S. Peng, Y. Xiong, K. Li, M. He, Y. Deng, L. Chen, *Eur J Radiol*. 2012, 81, 3832.