

# Morphological and Topographical Study of the Degree of Angulation between Posterior Inferior Iliac Spine and Ischial Spine of the Human Hip Bone and its Role in Determination of Sex.

Abhishek Prasad Sinha<sup>1</sup>; Anamika Kumari<sup>1</sup>; Vijay P. Gupta<sup>2\*</sup>; and Dil Islam Mansoor<sup>3</sup>

<sup>1</sup>Department of Anatomy, ICARE Institute of Medical Sciences and Research, Vill. Bansbishnupur, P.O. Balughatta, District - Purba Medinipore, Haldia, West Bengal, India, Pin- 721645

<sup>2</sup>Department of Forensic Medicine and Toxicology, Gandaki Medical College, Rithepani, Lekhnath-2, Nepal.

<sup>3</sup>Department of Anatomy, KUSMS, Dhulikhel, Kathmandu, Nepal.

E-mail: [guptavijay4@gmail.com](mailto:guptavijay4@gmail.com)\*

## ABSTRACT

This study was undertaken to examine the degree of angulation between Posterior Inferior Iliac Spine and Ischial Spine (< PIIS-IS) of the human hip bone: which represents the angle of Greater Sciatic Notch. The study comprised unpaired 154 adult human hip bones of known sex. The posterior inferior iliac spine and ischial spine were identified macroscopically in all the hip bones and a transparent fiber protractor was placed along the lower margin of greater sciatic notch and angle between PIIS and IS was determined.

It was observed that the mean angle in males and females were 51.47 degree and 68.43 degree respectively. The standard deviation in males was 10.38 degree and that of females was 10.84 degree. Of the 154 hip bones taken for study, 79 were of males and 75 were of females. The Mean values of angle in females were observed to be more in comparison to males. Statistically calculated T- test reveals how significant, the parameter is in terms of sex differentiation

(Keywords: posterior inferior iliac spine, hip bone, ischial spine, morphology, topography, sex determination)

## INTRODUCTION

Humans are the only mammals who are unique among the primates, to assume an upright posture and a bipedal mode of locomotion.

The two hip bones articulate posteriorly with sacrum and form a bony pelvis, which transmits the body weight through the acetabulum to the lower limb and at the same time mediate the

propulsive thrust from the lower limb to the body [1]. In sitting position the body weight is taken up by the ischial tuberosity and the legs are relaxed for free movement. The different morphology of human hipbone (the innominate or os coxae) and its sexual dimorphism is of great importance in various fields of research and judgment such as anatomical, anthropological and forensic point of view. The metric and non-metric differences in skeletal component among populations are evident and that are related to genetic and environmental factors.

Based on size and proportion of skeletal component, metric and non-metric differences between male and female are available, which can be used for sex determination. Proper sex determination of a human skeleton is beneficial for bio archaeological practices.

The best methods for determining sex from adult skeletal remains involve measurement and inspection of the hip bone that presents a number of gender-related anatomical differences (Ferembach et al.,1980).

It has long been customary among anatomists, anthropologists and forensic experts to judge the sex of skeletal material by non-metric observations. Lately, sexual divergence has been based on actual measurements in different bones; such as, hipbone, sacrum, femur, humerus, clavicle, sternum, mandible, skull, etc.

But among all, current opinion regards only the hipbone as providing the highest accuracy level for sex determination [2]. Many authors have considered different variables in human hipbone

for the determination of sex such as; studies on obturator foramen, subpubic angle, acetabular cavity, iliac crest, iliac fossa, anterior border of human hipbone, anterior superior iliac spine, anterior inferior iliac spine, pubic length / ischium length ratio, composite arch, preauricular surface, greater sciatic notch, lesser sciatic notch, ischial spine, ischial tuberosity, posterior superior iliac spine, posterior inferior iliac spine, visual determination of sex using human hipbone. Indices and angles of greater sciatic notch are known to be highly sexually dimorphic. Consequently they have been considered to be reliable sex discriminators. The greater sciatic notch and acetabulum are located in central portion of the hip bone; hence they are better preserved [7].

The present study was undertaken since there were no studies set out to establish the morphological pattern of angle between posterior inferior iliac spine and ischial spine of hipbone or possible influence of sexual dimorphism by osteometric methods.

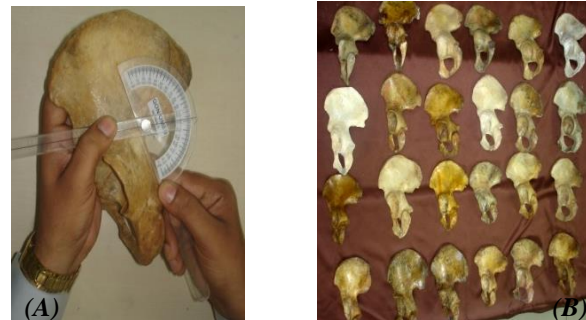**MATERIALS AND METHODS**

Materials for the present study consisted of dry, unpaired 154 adult human hip bones (79 males and 75 females) of known sex, obtained from the Department of Anatomy of our institution. A cardboard and a transparent fiber protractor was used for the measurement of angle. The hip bones were selected after rejecting the bones, having fracture, pathology or wear and tear. Only the bones with clear and intact posterior border were used for the study.

For each hipbone, the degree of angulations between Posterior Inferior Iliac Spine and Ischial Spine (PIIS-IS): Representing the angle of Greater Sciatic Notch was measured. Lower margin of greater sciatic notch was considered to be more accurate than upper margin, because of its linearity. However the upper margin was found to be curved hence cannot be appropriate for placing the straight part of the protractor. The straight part of protractor was placed along the lower margin of the greater sciatic notch and angle was measured (Figure 1).

The mean and standard error of the angle of the human Hip bones were calculated. T test calculation was also done to determine the significance of the study. The data were analyzed

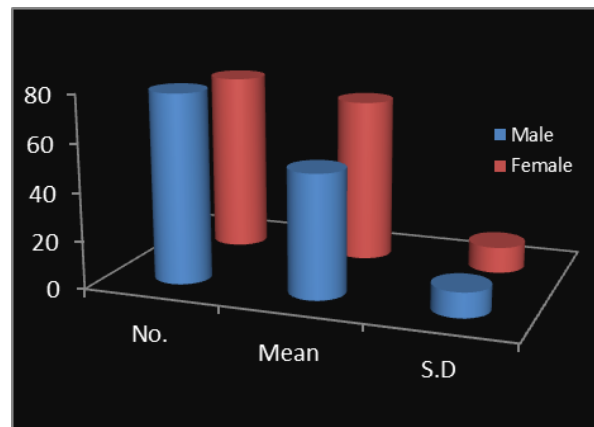
using the Statistical Package for the Social Sciences (SPSS). The graph was drawn using Microsoft Excel (Table 1).



**Figure 1:**(A) Showing the Measurement of Angle between PIIS-IS using Protractor (B) Hip Bone Samples.

**Table 1:** Mean Degree of Angulation between Posterior Inferior Iliac Spine and Ischial Spine (PIIS-IS) in Males and Females.

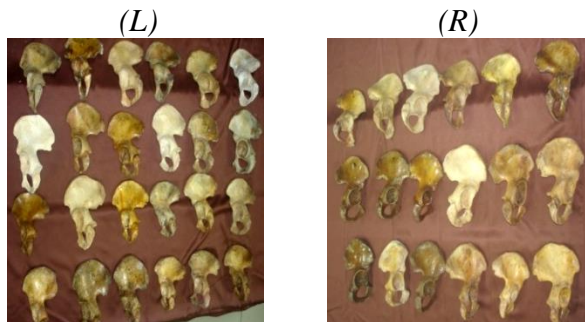
Sex	No.	Mean	S.D.
Male	79	51.49	10.38
Female	75	68.43	10.84



**RESULTS**

In the present study the mean degree of angulations between Posterior Inferior Iliac Spine and Ischial Spine (PIIS-IS in degrees) were calculated in both the sexes. The mean angle in males was 51.47 degree and the mean angle in females was 68.43 degree. The difference in the mean angulations between PIIS-IS between

males and females were found to be very highly significant. The standard deviation (SD) is maximum in females suggesting greater variation in the degree of angulations between PIIS-IS along the posterior border of the hip bone (Table-1).



**Figure 2:** Human Hip Bones of Left (L) and Right (R) side showing its Posterior Border.

## DISCUSSION

Susruta in the sixth century BC correctly described the hip bone. In the fifth century BC Hippocrates wrote on the articulation of the hip joint. In the late nineteenth century, Eadweard Muybridge photographed human motion in rapid sequence to examine the action of various levers of the body. Recently many researchers have attempted to determine the sex from various parameters of the hip bone. The morphology of posterior border of the hip bone has been used in different studies addressing different populations for sex determination. In 1875, Verneau was the first person to notice the greater sciatic notch is narrower in males and shallower in females.

Washburn, 1948 pointed out that the sex difference in greater sciatic notch belonged to a system different from that of pubic bone. In addition to depth, width and various indices, Singh and Potturi, [24] 1978 measured the total and posterior angle of greater sciatic notch in 200 adult hip bone from their comparative values it was noted that posterior angle of greater sciatic notch was best discriminating measurement for identification of male from female hipbones.

MacLaughlin and Bruce. 1986 [16] estimated the sciatic notch/acetabular index and its rule of thumb application on two European series of documented sex. Mewalal 1993 [17] evaluated the reliability of many commonly used parameters,

including these three chilitic line index, ischio-pubic index, and acetabulo - pubic index, on large number of hip bones. He found that most of these parameters when subjected to vigorous statistical analysis were not effective. Isaac, 2002 [7] measured 42 hip bones (27 males and 15 females) of known sex and observed eight variables on its posterior border for the determination of sex.

M. Patriquin 2003 [18] examined a sample of 400 ostensibly healthy known sex/race os coxae from the Pretoria and Dart collection. A series of 13 measurements were taken. Data were subjected to SPSS stepwise and direct discriminant function analysis. Pubic length was chosen as best for discriminating between races for males and iliac breadth as best in females. Highest average accuracies were 88% for males (pubic length, greater sciatic notch posterior width, acetabulum diameter, total height) and 85% for female (pubic length, greater sciatic notch posterior width, acetabulum diameter, iliac breadth).

M. Steyna, et al., 2003,[19] used the geometric morphometric method to study the greater sciatic notch of 115 known skeletons of South African origin, and observed that the South Africans have the typical narrow shape of the greater sciatic notch, while both black and white females have typical greater sciatic notches. Hence they indicated that for identification of sex the width of greater sciatic notch may not be a reliable criteria, especially in South Africans white males.

liknur Ari, 2005 [8] studied the morphometry of greater sciatic notch on 26 adult male coxae excavated from remains of male Byzantine skeletons from Nicea. He measured the width and depth of posterior segment and two indexes to find out the variation in right and left.

Hideo Takahashi 2006 [6] studied the curvature of the greater sciatic notch in sexing the human pelvis. In his study the maximum curvature of the greater sciatic notch and two standardized indices were calculated on 164 Japanese hip bones of known sex. For the measurements of hip bone he photographed the lateral view of hip bones with a digital camera from a distance of one meter. The best discriminating variable was found to be the posterior angle with an accuracy of 91%. The new parameters of his study represent localized shape of the sharply curved

edge of the notch, diagnosed sex with an accuracy of 88%.

In the present study an effort has been made to find the average angle of greater sciatic notch, of human hip bones for determination of sex. Several authors have attempted to determine the sex from human hip bone in the course of their research. It has been performed in a variety of ways, including direct measurement on dry hip bones, direct measurement of fresh or embalmed cadavers, radiographic measurement of hip bones harvested from cadavers, radiographic measurements in living patients and measurements on photographs of hip bone taken from one meter distance. These studies have been performed on different races and populations.

As per the search and study a very few authors have done work on the greater sciatic notch.

Issac [7] has done substantial work on various parameters related to the posterior border of the hip bones. In the present study the parameter taken for the study was angle between posterior inferior iliac spine and ischial spine which has not been considered by any author in their studies. This parameter has been found highly significant for determination of sex. This makes the present study more objective as well as relevant.

In the present study the mean angle between Posterior Inferior Iliac Spine and Ischial Spine in males was 51.47 degree with standard deviation of 10.38 degree and in females was 68.43 degree with standard deviation of 10.84 degree. In females the mean angle is apparently greater, and statistically it was found to be Very Highly Significant. This shows that the mean angle between PIIS-IS in males was very less than that of females.

## CONCLUSION

There was a significant difference observed in the angle between posterior inferior iliac spine and ischial spine which is an additional method not been performed earlier. Hence the above mentioned parameters and statistical calculations can be considered as a helpful tool for forensic experts in determination of sex of the hip bone.

## ACKNOWLEDGEMENTS

We gratefully acknowledge all the non-teaching staff members of our department for their help and cooperation.

## REFERENCES

1. Datta, A.K. 2004. *Essentials of human anatomy, 3rd edition.*
2. Williams, P. 1996. *Gray's: Anatomy of the Human Body.* 38<sup>th</sup> edition.
3. Albanese, J. 2003. "A Metric Method for Sex Determination using the Hipbone and the Femur". *Journal of Forensic Sciences.*48:263-273.
4. Anders, B.E. 2005. "Ventral Arc of the Os Pubis: Anatomical and Developmental Considerations". *American Journal of Physical Anthropology.* 83(4):449-458.
5. Arsuaga, J.L. and J.M. Carretero. 2005. "Multivariate Analysis of Sexual Dimorphism of the Hip Bone in a Modern Human Population and in Early Hominids". *American Journal of Physical Anthropology.* 93:241-257.
6. Takahashi, H. 2006. "Curvature of Greater Sciatic Notch in Sexing Human Pelvis". *Journal of Anthropological Science.* 114:187-191.
7. Isaac, B. 2002. "Biometry of the Posterior Border of the Human Hip Bone: Normal Values and their use in Sex Determination". *J. Anat. Soc. India,* 51(1):43-46.
8. Iknur, A. 2005. "Morphometry of the Greater Sciatic Notch on Remains of Male Byzantine Skeletons from Nicea". *Eur.J. Anat.* 9(3):161-165.
9. Bruzek, J. 1996. "Degree of Pelvic Sexual Dimorphism in Human Populations. A Greene t-Test Application". *Human Evolution.* 11(2):183-189.
10. Bruzek, J.J. 2002. "A Method for Visual Determination of Sex, using the Human Hip Bone". *Am J Phys Anthropol.* 117:157-168.
11. Nagesh, K., T. Kanchan, and B. Bastia. 2003. "Sexual Dimorphism of Acetabulum-Pubis Index in South-Indian Population". *Legal Medicine.* 9(6):305-308.
12. Pellico, L.G. and F.J. Fernandez Camacho. 1992. "Biometry of the Anterior Border of the Human Hip Bone: Normal Values and their use in Sex Determination". *J. Anat.* 181:417-422.

13. Moerman. 1981. "A Longitudinal Study of Growth in Relation to Body Size and Sexual Dimorphism in the Human Pelvis". Ph.D. dissertation. University of Michigan: Ann Arbor, MI.
14. Meindl, R.S., C.O. Lovejoy, R.P. Mensforth, and R.A. Walker. 1985. "A Revised Method of Age Determination using the Os Pubis, with a Review and Tests of Accuracy of other Current Methods of Pubic Symphyseal Aging". *Am J Phys Anthropol.* 68(1):29-45.
15. MacLaughlin, S.M. and M.F. Bruce. 1986. "The Sciatic Notch/Acetabular Index as a Discriminator of Sex in European Skeletal Remains". *J. Forensic Sci.* 31:1380–1390.
16. Mewalal. 1994. "Evaluation of Various Indices of Adult Human Pelvic Girdle for Sex Determination". Thesis submitted for the degree of Doctor of Medicine. University of Delhi: Delhi, India.
17. Patriquin, M. 2003. "Metric Assessment of Race from the Pelvis in South Africans". *Forensic Science International.* 127(1-2):104.
18. Steyna, M., E. Pretoriusa, and L. Huttena. 2004. "Geometric Morphometric Analysis of the Greater Sciatic Notch in South Africans". *J. of Homo.* 54:197-206.
19. Phenice, T.W. 1969. "A Newly Developed Visual Method of Sexing the Os Pubis". *American Journal of Physical Anthropology.* 30:297–301.
20. Patriquin, M.L., M. Steyn, and S.R. Loth. 2002. "Metric Assessment of Race from the Pelvis in South Africans". *Forensic Sci Int.* 127:104–113.
21. Pal, G.P., S. Bose, and S.M. Choudhary. 2007 "Reliability of Criteria used for Sexing of Hip Bones". *Journal of Anatomical society of India.* 53(2).
22. Walker, P.L. 2005. "Greater Sciatic Notch Morphology: Sex, Age, and Population Differences". *American Journal of Physical Anthropology.* 127:385-391.
23. Singh, S. and B.R. Potturi. 1978, "Greater Sciatic Notch in Sex Determination". *J. Anat.* 125:619-624.
24. Dixit, S.G., S. Kakar, S. Agarwal, and R. Choudhry. 2007. "Sexing of Human Hip Bones of Indian Origin by Discriminant Function Analysis". *Forensic Leg Med.* 14(7):429-435.
25. Luo, Y. 1990. "Sex Determination from the Pubis by Discriminant Function Analysis". *Forensic Science International.* 74(2):89–98.

## SUGGESTED CITATION

Sinha, A.P., A. Kumari, V.P. Gupta, and D.I. Mansoor. 2013. "Morphological and Topographical Study of the Degree of Angulation between Posterior Inferior Iliac Spine and Ischial Spine of the Human Hip Bone and its Role in Determination of Sex". *Pacific Journal of Science and Technology.* 14(2):379-383.

