

Research report

# Immediate changes in radiographically determined lateral flexion range of motion following a single cervical HVLA manipulation in patients presenting with mechanical neck pain: A case series

César Fernández-de-las-Peñas<sup>a,\*</sup>, Cristobal Downey<sup>b</sup>, Juan C. Miangolarra-Page<sup>a</sup>

<sup>a</sup> *Department of Physical Therapy, Occupational Therapy, Physical Medicine and Rehabilitation, Universidad Rey Juan Carlos, Avenida de Atenas s/n, 28922 Alcorcón, Madrid, Spain*

<sup>b</sup> *Escuela de Osteopatía de Madrid, Madrid, Spain*

Received 6 July 2005; received in revised form 6 October 2005; accepted 5 November 2005

## Abstract

**Background:** It is generally assumed that inter-vertebral joint dysfunction results in a temporary reduction of mobility of a spinal segment and it has been purported that spinal manipulation can directly affect the biomechanical behaviour of the spine. Functional X-rays are used to assess dynamic alterations of spinal function.

**Objective:** The aim of this case series was to describe the immediate changes of inter-vertebral motion at an identified dysfunctional cervical segment, as measured by functional X-rays in lateral flexion, following a supine cervical rotation manipulation in patients presenting with mechanical neck pain.

**Methods:** Fifteen patients who presented with mechanical neck pain and who exhibited inter-vertebral joint dysfunction at C3–C4 or C4–C5 levels were recruited to participate in this case series. The radiological distance between the transverse process of the identified hypomobile vertebra and the transverse process of the subjacent vertebra, was measured pre- and 5 min post-manipulation during contralateral side flexion.

**Results:** Analysis of the pre-post-intervention radiographs showed a significant increase ( $P = 0.01$ ) of the distance between the transverse process on the dysfunctional side following cervical manipulation. The mean pre-manipulative inter-vertebral radiological measurement was 18.9 mm (SD 2.1), and 20.6 mm (SD 2.1) at the post-manipulative assessment.

**Conclusions:** These preliminary results demonstrated a trend toward an increase in inter-vertebral motion at the hypomobile segment, measured by functional radiography.

© 2005 Elsevier Ltd. All rights reserved.

**Keywords:** Osteopathic medicine; Mechanical neck pain; Zygapophyseal joint; Cervical manipulation; Inter-vertebral radiological motion; Functional radiography

## 1. Background

Mechanical neck pain affects 45–54% of the general population at some time during their lives<sup>1</sup> and can

result in severe pain and disability.<sup>2</sup> The exact pathology of mechanical neck pain is not clearly understood but has been purported to be related to various anatomical structures including zygapophysial joints, uncovertebral joints, inter-vertebral discs, neural tissues, muscular disorders and ligaments.<sup>3</sup> It has been hypothesised that the pathogenesis of mechanical neck pain is mainly produced by zygapophysial joint dysfunction or hypomobility.<sup>4</sup> Cervical joint dysfunction, known also as somatic

\* Corresponding author. Tel.: +34 91 488 88 84; fax: +34 91 488 89 57.

E-mail address: [cesarfdlp@yahoo.es](mailto:cesarfdlp@yahoo.es), [cesar.fernandez@urjc.es](mailto:cesar.fernandez@urjc.es) (C. Fernández-de-las-Peñas).

dysfunction, inter-vertebral joint dysfunction, chiropractic subluxation, and hypomobility by the various manipulating professions,<sup>5</sup> is defined as a reduction of mobility of a cervical segment,<sup>6</sup> and if identified on clinical examination is often the focus of treatment for mobilisation/manipulation.<sup>7</sup>

Previous studies have demonstrated that spinal manipulative therapy is effective in reducing pressure pain threshold<sup>8</sup> and increasing cervical range of motion<sup>9–11</sup> in patients presenting with mechanical neck pain; while another study has reported no lasting changes in passive cervical range of motion occur after spinal manipulation.<sup>12</sup> It is generally assumed that inter-vertebral joint dysfunction provokes a reduction of mobility of a spinal segment and that spinal manipulation may improve motion thus affecting the biomechanical behaviour of the spine.<sup>6</sup> The identification of joint hypomobility is a common criteria used as an indication for the application high velocity-low amplitude (HVLA) techniques. If identification of inter-vertebral dysfunction is accurate and the spinal manipulation procedure is precise, the biomechanical behaviour of that spinal segment should be expected to exhibit an increase in range of motion.<sup>9–11</sup>

Typically the study of the effects of spinal manipulation on the kinematics of the cervical spine entails radiological and goniometric studies. Functional radiographs are commonly used to assess positional abnormalities and potential instability of the spinal segments. Yeomans<sup>13</sup> assessed changes on inter-segmental motion with functional radiography in flexion extension and reported an increase in mobility after the manipulative procedure directed at the cervical spine. However, in the clinical setting, cervical hypomobility is usually identified either at the left or the right aspect of an inter-vertebral segment. Therefore, the radiological analysis of the inter-segmental motion of the hypomobile segment should be a unilateral analysis, for example in lateral flexion. The aim of this case series was to describe the immediate changes of inter-vertebral motion at a cervical segment identified as hypomobile by functional radiography in lateral flexion, after a supine cervical rotation manipulation in patients presenting with mechanical neck pain. It was hypothesised that measurements taken after the manipulative procedure would exhibit an increased inter-vertebral motion at the dysfunctional segment.

## 2. Materials and methods

### 2.1. Subjects

Fifteen patients who presented with mechanical neck pain and who were referred by their primary care physician to a private clinic of osteopathy in Madrid, Spain,

from January to June 2004 were recruited to participate in this case series. For the purpose of this study mechanical neck pain was defined as generalised neck and/or shoulder pain with mechanical characteristics including: symptoms provoked by maintained neck postures or by neck movement and/or by palpation of the cervical muscles. Inclusion criteria included: (1) patients suffering from mechanical neck pain of at least 1 month in duration; and (2) clinical presentation of inter-vertebral joint dysfunction at C3–C4 or C4–C5 levels diagnosed by the lateral gliding test. Patients were excluded if they exhibited any of the following: (1) any contraindication to manipulation; (2) diagnosis of fibromyalgia syndrome<sup>14</sup> (3) previous history of whiplash injury; (4) history of cervical spine surgery; (5) diagnosis of cervical radiculopathy or myelopathy determined by their primary care physician; (6) having undergone spinal manipulative therapy within the past month before the study; (7) exhibiting a positive extension rotation test<sup>15</sup> or (8) less than 18 years old. The clinical history for each patient was solicited from their primary care physician to assess the presence of any exclusion criteria or 'red flags', e.g. infection, osteoporosis. All patients provided informed consent prior to beginning the trial. This case series was supervised by the Department of Physical Therapy, Occupational Therapy, Physical Medicine and Rehabilitation of the Universidad Rey Juan Carlos and the International School of Osteopathy in Madrid (EOM). The study protocol was approved by the local Committee in Clinical Research of the University.

### 2.2. Procedures

All patients were examined by therapist 1 (jointly qualified osteopath and physical therapist), who had more than 5 years experience in the assessment of joint dysfunction, for the presence of joint hypomobility in the cervical spine. The therapist used the lateral gliding test for the cervical spine as described by Greenman<sup>16</sup>

1. The patient is supine with the cervical spine in a neutral position.
2. The therapist places the fingers over the zygapophyseal joints of a specific cervical vertebra.
3. The examining therapist laterally glides each vertebra from right to left and from left to right (Fig. 1).

Passive lateral gliding, end-feel and reproduction of the patients' symptoms were assessed. Patients who demonstrated restricted mobility in lateral gliding were included. The lateral gliding test had to be associated with a reproduction of the patient's neck pain as a criteria for the presence of inter-vertebral joint dysfunction.<sup>17</sup> The clinician recorded the level and the side of any identified dysfunction. Our research group has recently validated the lateral gliding test for the cervical

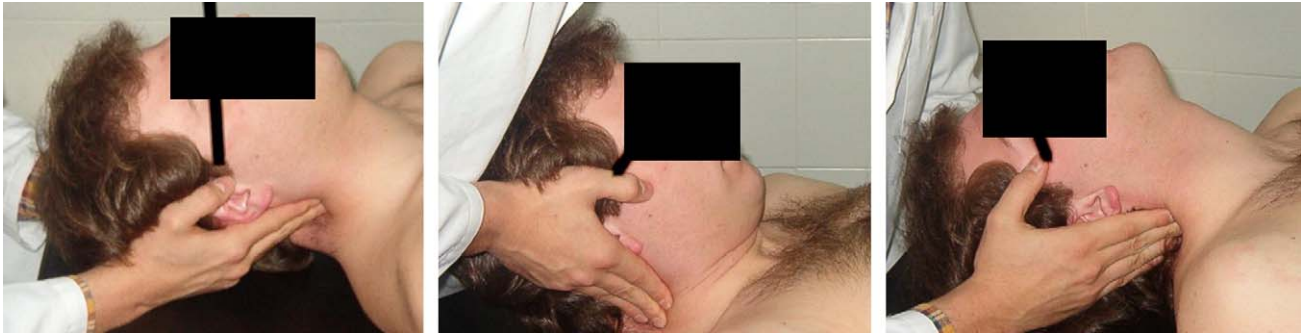

Fig. 1. Lateral gliding test for the cervical spine.

spine using functional radiographs to measure intervertebral motion at a hypomobile segment, which was 3.4 mm less than the contralateral side.<sup>18</sup> Based on our previous study, the lateral gliding test for the cervical spine is as valid as a radiological assessment of intervertebral dysfunctions in the mid and lower cervical spine.<sup>18</sup>

Once joint examination was completed, therapist 2, who had more than 4 years of experience in radiographic imaging, performed the pre-manipulative radiological examination as follows: each subject was seated upright in a chair in an X-ray suite. Patients were instructed to depress their shoulders to allow for clear visualisation of the cervical spine. Patients were instructed to laterally flex their cervical spine to the right to end range and then pause for an instant while anterior-posterior (AP) cervical spine radiographs were taken. This procedure was then repeated with the patient in cervical lateral flexion to the left. A total of 30 anterior-posterior cervical spine radiographs were obtained (two per patient).

Following the pre-manipulative radiographs, therapist 1 performed a cervical manipulation directed at the dysfunctional level. The manipulation was performed as follows: the patient was supine with the cervical spine in a neutral position. The index finger of the therapist applied contact over the posterior-lateral aspect of the articular pillar at the dysfunctional side of the identified vertebra. The therapist's other hand

cradled the patient's head. Gentle ipsilateral side flexion and contralateral rotation, were introduced from the restricted side until slight tension was palpated in the tissues at the contact point. A high velocity-low amplitude (HVLA) thrust was directed upward and medially in the direction of the patient's contralateral eye.<sup>19</sup> (Fig. 2) A specific cracking or popping sound, indicating joint cavitation, accompanied all manipulations.

After the manipulation the patient rested in a sitting position for 5 min. Therapist 2 then obtained the post-manipulative radiographs using the exact methods used to collect the pre-manipulative images. However, the post-manipulative radiography was only performed in contralateral cervical side flexion. Therefore, 15 anterior-posterior cervical spine radiographs were taken during the post manipulative assessment (one per patient).

### 2.3. Instrumentation

X-Ray equipment distributed by the Seneca X-Ray company was used for all radiological examinations. The radiographic settings were 250 mA of radiation exposure rate, 7.5 ms/frame exposure time, and 20 frames/s frame speed. A medium kilovoltage technique (average 60 kV) was used. The focal film distance (FFD) for each exposure was 100 cm. Radiography development was performed on 24 × 30 cm films, with PROTEC equipment.

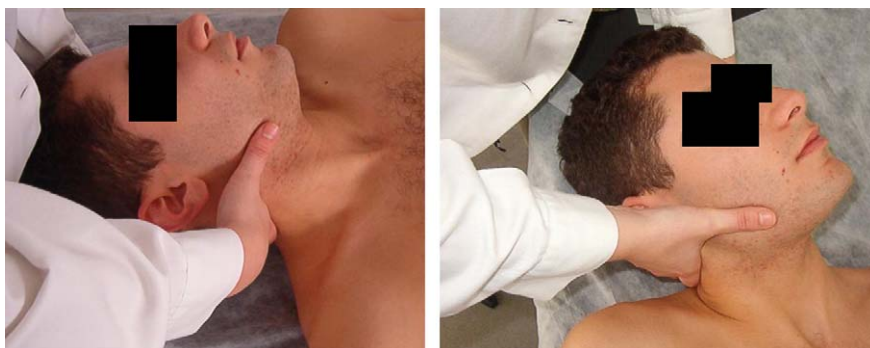

Fig. 2. High velocity-low amplitude manipulation technique applied to an inter-vertebral joint dysfunction located on the right side.

#### 2.4. Radiological analysis of the inter-vertebral motion

The analysis of the inter-segmental motion of cervical lateral flexion motion was performed by the second therapist. The inter-vertebral motion of the dysfunctional inter-vertebral segment was measured from radiographs taken during both left and right side flexion. The radiographic analysis of inter-vertebral motion was performed as follows:

1. Therapist 2 placed markings on the radiographs to ascertain the distance, measured in millimetres, between the transverse process of the vertebrae making up the inferior joint surface of the dysfunctional segment and the vertebrae making up the superior joint surface of the subjacent vertebrae.
2. Tips of both transverse processes of each cervical vertebra were plotted on the radiographs.
3. Both tips of the transverse process of the clinically identified restricted vertebra, determined by the lateral gliding test, were connected with a continuous line.
4. The same procedure was performed at the subjacent (inferior) vertebra.
5. The distance, measured in millimetres, between the transverse process of the dysfunctional vertebra and the transverse process of the subjacent vertebra was measured. This measurement was considered as the inter-vertebral motion at the inter-vertebral dysfunctional level (Fig. 3).

#### 2.5. Statistical analysis

Descriptive data were collected on all patients and then the group mean was calculated. The level and the side of the identified cervical dysfunction were recorded for each patient. The pre-post data were analysed with the non-parametric two-tailed Wilcoxon signed rank test. The statistical analysis was conducted at a 95% confidence level because the testing was non-parametric and a small sample size was used. A  $P < \alpha/2 = 0.025$  was considered as statistically significant. Data were analysed with the SPSS package version 11.5.

### 3. Results

Nine males and 9 females were recruited for this study. One male was excluded as he did not show C3–C4 or C4–C5 joint dysfunction. One male and one woman were also excluded as their neck pain began after a motor vehicle accident. Finally, seven males and eight females, aged 20–39 years old (mean  $\pm$  SD =  $27 \pm 6$ ), were included in this case series. The duration of neck symptoms ranged from 5 weeks to 6 months (mean  $\pm$  SD =  $3.3 \pm 1.7$  months). The demographic data are shown in Table 1.

At the beginning of the study, the radiological inter-vertebral distance between the transverse process of the hypomobile vertebra and the transverse process of the subjacent vertebra at the dysfunctional side was 18.9 mm (SD 2.1), whereas the radiological inter-vertebral motion at the contralateral joint was significantly different

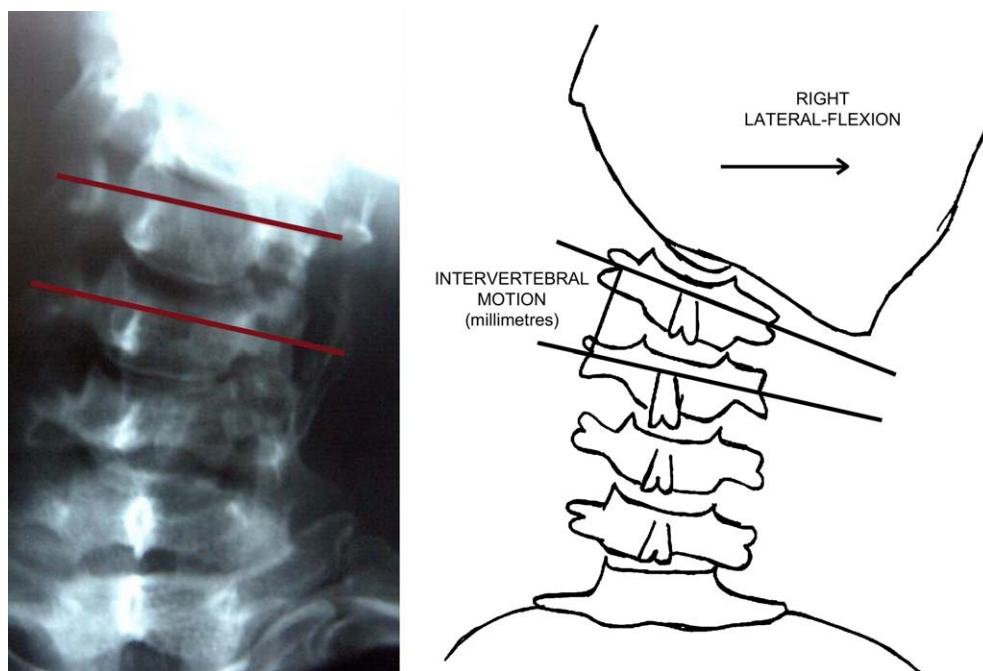


Fig. 3. Radiological assessment of the inter-vertebral motion of an inter-vertebral joint dysfunction on the left side measured by right lateral-flexion of the cervical spine.

Table 1  
Clinical data of each patient at the beginning of the study

Patient	Age (years)	Gender	Inter-vertebral joint dysfunction		Inter-vertebral motion at the dysfunctional segment (mm)	
			Level	Side	Ipsilateral	Contralateral
1	29	Female	C3–C4	Left	25	16
2	20	Male	C3–C4	Right	20	18
3	32	Male	C3–C4	Left	25	20
4	26	Male	C3–C4	Left	24	22
5	24	Female	C4–C5	Right	23	20
6	21	Female	C3–C4	Right	20	17
7	22	Male	C3–C4	Right	23	18
8	39	Female	C3–C4	Right	20	17
9	25	Female	C3–C4	Left	22	17
10	28	Male	C4–C5	Right	22	19
11	26	Female	C4–C5	Left	21	18
12	30	Male	C3–C4	Left	25	23
13	33	Female	C4–C5	Left	20	18
14	25	Female	C3–C4	Right	23	19
15	21	Male	C3–C4	Right	24	22
Mean					22.4 (SD 1.9)	18.9 (SD 2.1)

$P$  value = 0.006 (based on two-tailed Wilcoxon signed rank test).

( $P = 0.006$ ) at 22.4 mm (SD 1.9). The pre-post analysis demonstrated a significant increase ( $P = 0.01$ ) of the inter-vertebral motion on the dysfunctional side 5 min after the cervical manipulation. The mean of the inter-vertebral radiological motion was 18.9 mm (SD 2.1) in the pre-manipulative measurement and 20.6 mm (SD 2.05) in the post-manipulative measurement. Table 2 summarizes the pre-post data of the inter-segmental motion at the dysfunctional segment of each patient.

Table 2  
Pre-post-radiological measurements of each patient

Patient	Inter-vertebral motion at the dysfunctional segment measured on contralateral side flexion to the hypomobile side (mm)		
	Pre-treatment	Post-treatment	Improvement
1	16	20	4
2	18	20	2
3	20	22	2
4	22	23	1
5	20	22	2
6	17	19	2
7	18	20	2
8	17	17	0
9	17	18.5	1.5
10	19	21	2
11	18	19	1
12	23	25	2
13	18	20	2
14	19	20	1
15	22	23	1
Total score	Mean 18.9 (SD 2.1)	Mean 20.6 (SD 2.1)	Mean 1.7 (95% CI 2.1–1.2)

$P$  value = 0.01 (based on two-tailed Wilcoxon signed rank test).

#### 4. Discussion

It has been purported that inter-vertebral joint dysfunction is characterised by a reduction of mobility of a spinal segment; and that spinal manipulation can potentially affect the mobility of the joint resulting in alterations of the kinematic behaviour of the spine.<sup>6</sup> If treatment is precise, the spinal manipulation should affect the mobility of the hypomobile joint and lead to an increased range of motion at that particular segment.<sup>9–11</sup> To our knowledge this case series is the first to provide preliminary evidence of increased inter-vertebral motion (1.7 mm; SD 0.8) as measured by functional radiography in lateral flexion, in a spinal segment exhibiting clinical restriction of lateral gliding following a supine cervical spine rotation manipulation.

We were unable to identify any other studies investigating radiological changes in mobility following cervical spine manipulation that allowed for direct comparison to our results. Previous studies<sup>9–11,20</sup> have analysed changes on either active or passive range of motion, but not radiological changes. Yeomans<sup>13</sup> demonstrated radiological changes in inter-vertebral motion after spinal manipulation and reported an increased cervical range of motion after a cervical manipulation; however the manipulative technique was not described. Moreover, the radiological analysis employed in that paper was functional radiography in flexion extension. It should be taken into account that inter-vertebral joint dysfunctions are usually identified on the left or the right of the segment; therefore a unilateral analysis should be used, such as the analysis employed in the present case series, for the radiological analysis of the inter-segmental motion on that spinal segment. There are limitations to this type of radiographic analysis, and in

future studies, more sophisticated techniques, such as cineradiography should be considered as a means of assessing the inter-segmental motion of the cervical spine.

This cases series has a number of limitations. First, an observer bias could be present as therapist 2 only had unilateral lateral flexion radiographs to measure post-intervention. By taking post-intervention radiographs only in the direction of restricted side flexion, therapist 2 may have been looking to maximise the documented side flexion range. Under these circumstances there is no possible way that therapist 2 could be blinded to side of thrust and side of the range of motion restriction. A stronger design study should include both lateral flexion views, with side bending left and right, in both pre- and post-intervention assessments, although this would involve more exposure to radiation. Second, patient bias may also have occurred as they may have unconsciously attempted to support the practitioner by actively applying more effort at lateral flexion prior to radiographs being taken 5 min post-intervention. It is also possible that patients experienced symptomatic improvement following manipulation and it was the effects of pain modulation rather than direct range of motion effects that led to the changes in transverse process distance. Third, without a control group it could not be assumed that a cause and effect relationship existed between the manipulation procedure and increases in inter-vertebral motion. In order to further investigate this, we assessed the pre-post data of the inter-segmental motion in other cervical segments, which did not receive the manipulative procedure. The analysis of these data did not show a statistically significant difference between the pre- and post-manipulation measurements (based on non-parametric two-tailed Wilcoxon signed rank test), obtaining a radiological difference ranging from 0 to 0.5 mm depending on the cervical segment. Although the therapist attempted to be precise in the manipulative procedure, it was possible that other segments were also manipulated. Moreover, Clements et al. found that HVLA manipulation of the atlanto-axial joint produced a significant immediate amelioration of passive atlanto-axial rotation asymmetry regardless of whether the HVLA technique was applied unilaterally, either towards or away the restricted rotation, or bilaterally.<sup>20</sup> Therefore, it could be that the thrust has inherent qualities that can alter radiological motion, and that the direction of thrust may not be important. However, without a control group we cannot confirm if HVLA had effects on the inter-segmental motion of the dysfunctional segment. Future studies should repeat the same procedures with a larger sample size and the inclusion of a control group that does not receive any manipulative intervention. In addition, this case series was limited to a short-term follow-up. However, the fact that statistically significant changes occurred after spinal manipulation provides impetus for future research in this

area. Finally, although the lateral gliding test for the cervical spine has been recently validated,<sup>18</sup> its intra-examiner or inter-examiner reliability has not yet been documented.

This is the first study designed to investigate inter-vertebral motion using functional radiological studies during side flexion motions of the neck. Previous authors<sup>21,22</sup> have documented an intra-observer inherent error of 0.6 mm (SD 0.8) and 0.4 mm (SD 0.1) using functional radiography in flexion extension motion in the cervical spine. Since we were unable to locate any study analysing the reliability of functional radiography in lateral flexion motion, we assessed the intra-observer reliability of our imaging, obtaining an inherent error ranging from 0.3–0.6 mm depending on the cervical segment measured.<sup>18</sup> Although the obtained error was similar to that reported by Henderson and Dormon<sup>21</sup> and Yeomans<sup>13</sup>, the reliability of this technique requires further investigation.

## 5. Conclusions

The results of the current case series suggest that a supine cervical rotation manipulation results in increased inter-segmental motion at the dysfunctional side of a cervical vertebra as measured with plain film radiographs during contralateral cervical side flexion. While these preliminary results are encouraging and suggest that spinal manipulation might affect the kinematic behaviour of an inter-vertebral joint in the cervical spine, caution should be exercised when attempting to extrapolate these findings to clinical practice. Before we can make firm conclusions that a single manipulation to the cervical spine increases the radiologically determined lateral flexion interval, further studies that address those issues of methodology and bias identified in this paper should be undertaken.

## References

1. Côte P, Cassidy JD, Carroll L. The factors associated with neck pain and its related disability in the Saskatchewan population. *Spine* 2000;**25**:1109–17.
2. Côte P, Cassidy JD, Carroll L. The Saskatchewan health and back pain survey. The prevalence of neck pain and related disability in Saskatchewan adults. *Spine* 1998;**23**:1689–98.
3. Bronfort G, Evan R, Nelson B, Aker PD, Goldsmith CH, Vernon H. A randomized controlled clinical trial of rehabilitative exercise and chiropractic spinal manipulation for chronic neck pain. *Spine* 2001;**26**:788–99.
4. Hurwitz EL, Aker PD, Adams AH, et al. Manipulation and mobilization of the cervical spine: a systematic review of the literature. *Spine* 1996;**21**:1746–59.
5. Fryer G, Morris T, Gibbons P. Paraspinal muscles and intervertebral dysfunction: part one. *J Manipulative Physiol Ther* 2004;**27**:267–74.

6. Triano JJ. Biomechanics of spinal manipulative therapy. *Spine J* 2001;**1**:121–30.
7. Gross AR, Kay T, Hondras M, Goldsmith C, Haines T, Peloso P, et al. Manual therapies for mechanical neck disorders: a systematic review. *Man Ther* 2002;**7**:131–49.
8. Vernon HT, Aker P, Burns S, Viljakaanen S, Short L. Pressure pain threshold evaluation of the effect of spinal manipulation in the treatment of chronic neck pain: a pilot study. *J Manipulative Physiol Ther* 1990;**13**:13–6.
9. Cassidy JD, Lopes AA, Yong-Hink K. The immediate effect of manipulation versus mobilization on pain and range of motion in the cervical spine: a randomized controlled trial. *J Manipulative Physiol Ther* 1992;**15**:570–5.
10. Nansel D, Peneff A, Cremata E, Carlson J. Time course considerations for the effects of unilateral lower cervical adjustments with respect to the amelioration of cervical lateral-flexion passive end-range asymmetry. *J Manipulative Physiol Ther* 1990;**13**:297–304.
11. Schalkwyk RV, Parkin-Smith GF. A clinical trial investigating the possible effect of the supine cervical rotatory manipulation and the supine lateral break manipulation in the treatment of mechanical neck pain. A pilot study. *J Manipulative Physiol Ther* 2000;**23**:324–31.
12. Nilsson N, Christensen HW, Hartvigsen J. Lasting changes in passive range of motion after spinal manipulation: a randomized, blind, controlled trial. *J Manipulative Physiol Ther* 1996;**19**:165–8.
13. Yeomans SG. The assessment of cervical intersegmental mobility before and after spinal manipulative therapy. *J Manipulative Physiol Ther* 1992;**15**:106–14.
14. Wolfe F, Smythe HA, Yunus MB, et al. The American College of Rheumatology 1990 criteria for classification of fibromyalgia: report of the multicenter criteria committee. *Arthritis Rheum* 1990;**33**:160–70.
15. Mitchell JA. Changes in vertebral artery blood flow following normal rotation of the cervical spine. *J Manipulative Physiol Ther* 2003;**26**:347–51.
16. Greenman P. *Principles of manual medicine*. Baltimore: Williams and Wilkins; 1989.
17. Jull G, Treleaven J, Versace G. Manual examination: is pain provocation a mayor cue for spinal dysfunction? *Aust J Physiother* 1994;**40**:159–65.
18. Fernández de las Peñas C, Downey C, Miangolarra Page JC. Validity of the lateral gliding test as tool for the diagnosis of intervertebral dysfunctions in the lower cervical spine. *J Manipulative Physiol Ther* 2005;**28**:610–6.
19. Gibbons P, Tehan P. *Manipulation of the spine, thorax and pelvis*. Edinburgh: Churchill Livingstone; 2000.
20. Clements B, Gibbons P, McLaughlin P. The amelioration of atlanto-axial rotation asymmetry using high velocity low amplitude manipulation: is the direction of thrust important? *J Osteopath Med* 2001;**4**:8–14.
21. Henderson DJ, Dormon TM. Functional roentgenometric evaluation of the cervical spine in the sagittal plane. *J Manipulative Physiol Ther* 1985;**8**:219–27.
22. Tallroth K, Ylikoski M, Landtman M, Santavirta S. Reliability of radiographical measurements of spondylolisthesis and extension flexion radiographs of the lumbar spine. *Eur J Radiol* 1994;**18**:227–31.