

Pornpan Youngnak-Piboonratanakit¹, Kittipong Dhanuthai²

Oralni bijeli spužvasti madež u četirima generacijama jedne porodice: prikaz slučaja

Oral White Sponge Nevus in a Four-Generation Family: Case Report

¹ Zavod za oralnu medicinu Stomatološkog fakulteta Sveučilišta Chulalongkorn, Bangkok 10330, Tailand
Department of Oral Medicine, Faculty of Dentistry, Chulalongkorn University, Bangkok 10330, Thailand² Zavod za oralnu patologiju Stomatološkog fakulteta Sveučilišta Chulalongkorn, Bangkok 10330, Tailand
Department of Oral Pathology, Faculty of Dentistry, Chulalongkorn University, Bangkok 10330, Thailand

Sažetak

Bijeli spužvasti nevus ili madež (WSN) rijedak je dobroćudni autosomno dominantni poremećaj obično poput mekane, bijele, spužvaste naslage na mukoznoj membrani, najčešće oralnoj. Pojavljuje se odmah nakon rođenja ili u djetinjstvu, bez obzira na spol. U prikazu je opisan slučaj dječaka u dobi od četiri godine i njegova 42-godišnjeg oca. Obojica su se žalili na bezbolne bijele lezije u usnoj šupljini. Obiteljska i porodična anamneza otkrila je da od osamnaestero članova njihove porodice njih jedanaestero (61,11%) ima WSN. Kliničkim pregledom otkrivena je difuzna, preklopljena, spužvasta bijela naslaga koja je obostrano zahvatila bukalnu sluznicu i druge dijelove oralne sluznice. Histološkim pregledom ustanovljena je akantoza, hiperkeratoza spongioza i eozinofilna kondenzacija u perinuklearnom području spinoznog sloja. Dijagnoza WSN-a postavljena je na temelju pozitivne porodične anamneze tijekom četiriju generacija, te kliničkih i histoloških značajki. Za WSN nema specifične terapije. Iako je bijeli spužvasti madež rijedak, potrebno ga je uključiti u diferencijalnu dijagnozu bijelih lezija u djetinjstvu, posebice u slučaju pozitivne obiteljske anamneze.

Zaprimljen: 7. rujna 2012.

Prihvaćen: 25. studeni 2012.

Adresa za dopisivanje

Pornpan Piboonratanakit
Department of Oral Medicine
Faculty of Dentistry, Chulalongkorn
University
Bangkok 10330, Thailand
tel : +6622188942
fax : +6622188941
pornpan.p@chula.ac.th

Ključne riječi

leukokeratoza sluznice, nasljedna; oralna sluznica

Uvod

Bijeli spužvasti nevus ili madež (WSN; OMIM broj 193900) rijedak je dobroćudni autosomno dominantni poremećaj koji pogađa nekeratinizirani višeslojni pločasti epitel, uglavnom u oralnoj sluznici (1). Ekstraoralna mjesta – nazalna, ezofagealna, laringealna, vaginalna i analna sluznica – rjeđe su zahvaćena (1 – 3). Gotovo ravnomjerno obolijevaju oba spola jer je svojstvo madeža nepravilno prodiranje, a česti su i obiteljski slučajevi (4, 5).

WSN-a se obično pojavljuje odmah nakon rođenja ili u ranom djetinjstvu, no može se intenzivirati i otkriti u pubertetu (1, 2, 5).

WSN klinički karakteriziraju asimptomatske obostrane mekane, sivo-bijele spužvaste naslage. Debele su, nabrane i mogu se odljuštiti od potpornog tkiva (1, 5, 6). Najčešće se pojavljuje na bukalnoj sluznici, zatim na jeziku, labijalnoj sluznici, alveolarnim grebenima i u dnu usne šupljine (5). Histološke značajke WSN-a su hiperkeratoza, akantoza, vakoulizacija suprabazalnog sloja epitela i karakteristične perinuklearne eozinofilne kondenzacije u gornjim dijelovima spinoznog sloja, što je posljedica abnormalne agregacije poveznih keratinskih niti.

Introduction

White sponge nevus (WSN; OMIM number 193900) is a rare benign autosomal dominant disorder which affects non-keratinized stratified squamous epithelia, primarily oral mucosa (1). Extraoral sites including nasal, esophageal, laryngeal, vaginal and anal mucosa are less frequently affected (1-3). Both genders are affected equally since its trait has irregular penetration and familial cases are uncommon (4, 5). The onset of WSN usually occurs at birth or during early childhood; however, it may be detected or become more intense in puberty (1, 2, 5).

Clinically, WSN is characterized by the presence of asymptomatic, bilateral, soft, gray-white and spongy plaque. The plaque surface is thick, folded and may peel away from the underlying tissue (1, 5, 6). The buccal mucosa is the most common site, followed by the tongue, labial mucosa, lips, alveolar ridges and floor of the mouth (5). The histological features of WSN are hyperparakeratosis, acanthosis, vacuolization of the suprabasal layer of the epithelium and the characteristic perinuclear eosinophilic condensation in the upper spinous layer resulting from the abnormal aggregation of keratin intermediate filaments. The basement membrane

Bazalna membrana je intaktna i potporno vezivno tkivo ne pokazuje znakove upale (2, 3, 6, 7). Nema malignih promjena, niti je potrebna terapija (6, 8). U nekoliko studija istaknuto je da su određena poboljšanja postignuta primjenom sistemskih antibiotika, uključujući tetracikline i penicilin (9 – 11). U novijom istraživanjima ustanovljeno je da je za razvoj WSN-a odgovorna mutacija keratina specifičnih za sluznice – K4 i K13 (4, 12 – 14).

Svrha prikaza ovog slučaja bila je opisati zanimljiv slučaj WSN-a u četirima generacijama jedne tajlandske porodice.

Prikaz slučaja

Dječak u dobi od četiri godine upućen je u Kliniku za oralnu medicinu Stomatološkog fakulteta Sveučilišta u Chulalongkornu zbog asimptomatskih bijelih lezija na objema stranama sluznice obraza. Imao ih je od rođenja. Kliničkim pregledom otkrivene su difuzne, prirasle, malo izdignute i lagano spužvaste bijele naslage koje su zahvaćale sluznicu obraza i obje strane retromolarnog područja (slika 1. a).

Prema riječima njegova 42-godišnjeg oca i on od ranog djetinjstva ima takve opsežne bijele naslage u ustima. Ni kod sina ni kod oca nije bilo nikakvih promjena na očima, koži ili drugim sluznicama. Nisu bile prisutne ni ekstraoralne lezije. Kliničkim pregledom ustanovljene su asimptomatske, difuzne, prirasle, debele i izbrazdane bijele naslage na sluznici obraza, u retromolarnom području na prijelazu sluznice između kutnjaka i obraza, na ventralnoj strani jezika i na donjoj usni bilateralno (slika 1.b). Otac je objasnio da je nekoliko članova njihove porodice u zadnje četiri generacije imalo slične promjene i to njih jedanaestero od osamnaestero (61,11%) (slika 2.).

Ocu je obavljena incizijska biopsija zbog pozitivne porodične anamneze s njegove strane, sličnosti lezija s onima kod sina te zato što se protivio da se biopsiju obavi na sinu. Nalaz je pokazao da je epitel zadebljan i hiperkeratotičan, lagano akantotičan i uočena je vakuolizacija citoplazmi stanica spinoznog sloja. Kod nekih je primijećena eozinofilna perinuklearna kondenzacija keratinskih tonofilamena. Okolno vezivno tkivo bilo je uredno i bez znakova upale (slika 3.). Razmazak 10-postotnog KOH-a bio je negativan na gljivičnu infekciju. Postavljena je dijagnoza WSN-a i pacijent nije dobio nikakvu terapiju, nego su mu određeni redoviti kontrolni pregledi.

Rasprava

WSN je genetski poremećaj uzrokovan mutacijom gena koji kodira keratine K4 i K13, specifične za sluznicu. Oni se eksprimiraju u subbazalnim keratinocitima u bukalnoj, nazalnoj i ezofagealnoj sluznici te u anogenitalnom epitelu pa na sluznicama nastaju karakteristične bijele naslage (3, 4, 12). U ovom slučaju došlo se do podatka da jedanaestero od osamnaestero (61,11%) članova porodice ima WSN. Pogođeni potomci su, bez obzira na spol, bili djeca barem jednog roditelja s poremećajem, što upućuje na autosomno dominantno nasljeđivanje. WSN se kod ostalih petero temeljio na osnovi očeve anamneze, te ne možemo zanemariti moguć-

is intact and the connective tissue usually shows no or slight inflammation (2, 3, 6, 7). There is no malignant transformation and no need for treatment (6, 8). However, some benefits have been reported with using systemic antibiotics including tetracycline and penicillin (9-11). Recent studies have reported that the mutations of the mucosal specific keratins, K4 or K13, are responsible for the development of WSN (4, 12-14).

The aim of this paper was to describe an interesting case of WSN in a four-generation Thai family.

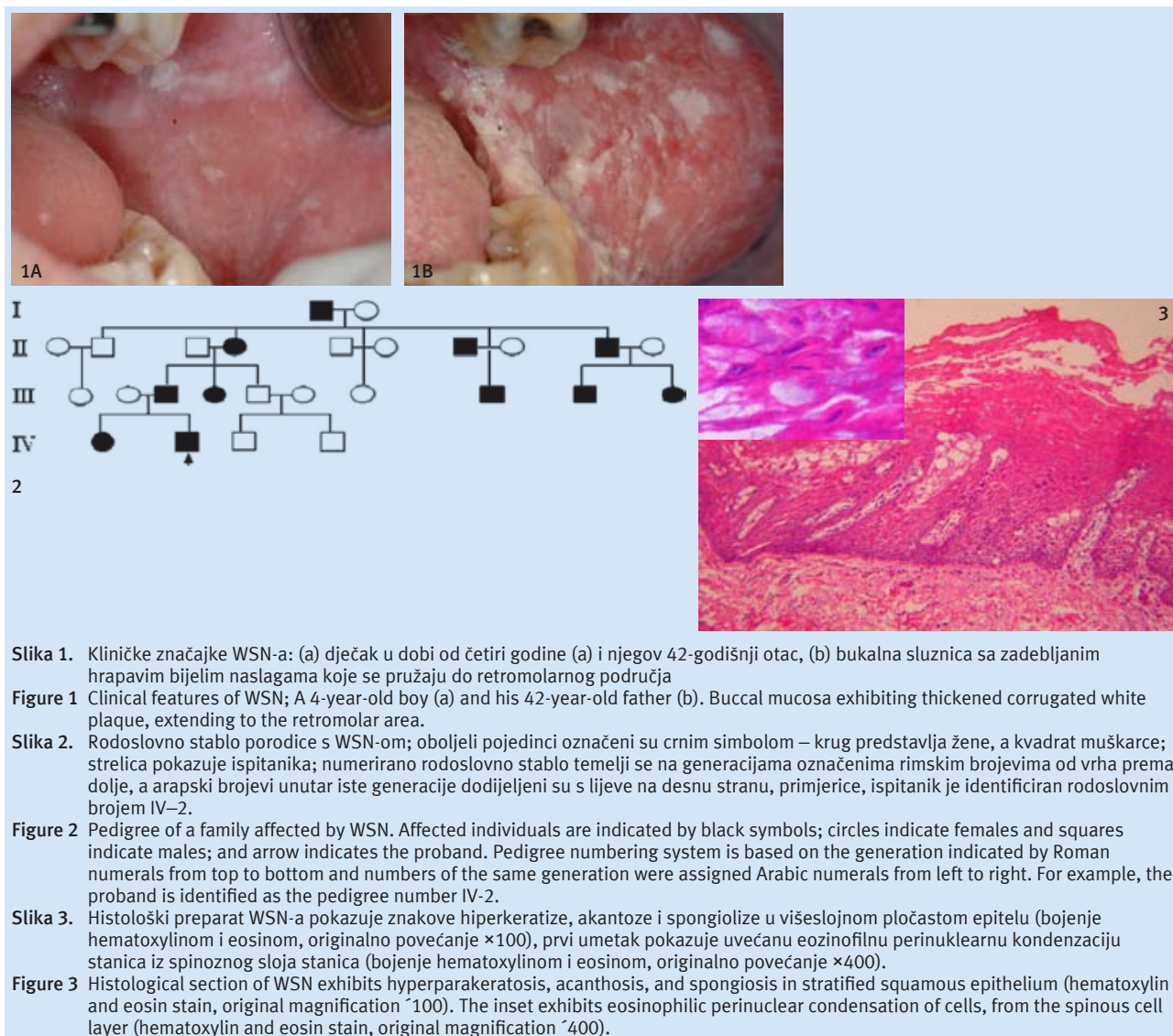
Case Report

A 4-year-old boy was referred to the Oral Medicine Clinic, Faculty of Dentistry, Chulalongkorn University because of the presence of asymptomatic white lesions at both sides of buccal mucosa since his birth. Oral examination revealed diffuse, non-removable, slightly raised, light spongy, white plaque involving the buccal mucosa and retromolar mucosa bilaterally (Figure 1a). The 42-year-old father reported that he also had asymptomatic extensive white plaque in his mouth since his early childhood. There were no associated extraoral lesions of their eyes, skin and other mucosal surfaces. Clinical examination revealed asymptomatic, diffuse, non-removable, thick, corrugated white plaque of the buccal mucosa, the retromolar areas, the mucobuccal folds of posterior teeth, the ventral aspects of the tongue and lower lip bilaterally (Figure 1b). The father reported that in the 4 most recent generations, 11 out of 18 descendants (61.11%) were similarly affected (Figure 2).

The incisional biopsy of the buccal mucosa of the father was carried out due to the positive family history on the paternal side of the child, the similar clinical appearances between the lesions of the father and the child and the father's refusal to perform the biopsy on the child. Biopsy report revealed that the epithelium was thickened and exhibited hyperparakeratosis, slight acanthosis and vacuolation of the cytoplasm of the cells of the spinous layer. Some cells of the spinous layer showed eosinophilic perinuclear condensation of the keratin tonofilaments. The subjacent fibrous connective tissue was normal with no signs of inflammation (Figure 3). In addition, 10% KOH smear was negative for fungal infection. Following the diagnosis of WSN, our patients received no treatment but underwent the periodic follow-up evaluations.

Discussion

WSN is a genetic disorder caused by mutations in the genes encoding for mucosal-specific keratins K4 and K13, which were expressed specifically in suprabasal keratinocytes of the buccal, nasal, esophageal mucosa, and anogenital epithelia and led to the characteristic mucosal white plaque (3, 4, 12). In the present paper, it was revealed that 11 out of 18 descendants (61.11%) had WSN. The affected descendants regardless of gender were the offspring of at least one affected parent reaffirming the autosomal dominant pattern of transmission. Nevertheless, the presence of WSN lesions in other five descendants was based on the father's account; there-



Slika 1. Kliničke značajke WSN-a: (a) dječak u dobi od četiri godine (a) i njegov 42-godišnji otac, (b) bukalna sluznica sa zadebljanim hrapavim bijelim naslagama koje se pružaju do retromolarnog područja

Figure 1 Clinical features of WSN; A 4-year-old boy (a) and his 42-year-old father (b). Buccal mucosa exhibiting thickened corrugated white plaque, extending to the retromolar area.

Slika 2. Rodoslovno stablo porodice s WSN-om; oboljeli pojedinci označeni su crnim simbolom – krug predstavlja žene, a kvadrat muškarce; strelica pokazuje ispitanika; numerirano rodoslovno stablo temelji se na generacijama označenima rimskim brojevima od vrha prema dolje, a arapski brojevi unutar iste generacije dodijeljeni su s lijeve na desnu stranu, primjerice, ispitanik je identificiran rodoslovnim brojem IV-2.

Figure 2 Pedigree of a family affected by WSN. Affected individuals are indicated by black symbols; circles indicate females and squares indicate males; and arrow indicates the proband. Pedigree numbering system is based on the generation indicated by Roman numerals from top to bottom and numbers of the same generation were assigned Arabic numerals from left to right. For example, the proband is identified as the pedigree number IV-2.

Slika 3. Histološki preparat WSN-a pokazuje znakove hiperkeratize, akantozu i spongiolizu u višeslojnom pločastom epitelu (bojenje hematoxylinom i eosinom, originalno povećanje $\times 100$), prvi umetak pokazuje uvećanu eozinofilnu perinuklearnu kondenzaciju stanica iz spinoznog sloja stanica (bojenje hematoxylinom i eosinom, originalno povećanje $\times 400$).

Figure 3 Histological section of WSN exhibits hyperparakeratosis, acanthosis, and spongiosis in stratified squamous epithelium (hematoxylin and eosin stain, original magnification $\times 100$). The inset exhibits eosinophilic perinuclear condensation of cells, from the spinous cell layer (hematoxylin and eosin stain, original magnification $\times 400$).

nost pogrešne informacije. O oralnom WSN-u kod članova iste obitelji pisali su i drugi autori (1–6, 8, 12–15). Istraživanje triju generacija jedne porodice iz Brazila pokazalo je da je osmero od dvadeset i troje potomka (34,78%) imalo taj poremećaj (5), a također je osamnaestero od četrdeset i troje potomka (41,86%) bilo je pogođeno u četirima naraštajima jedne škotske porodice (13). U nedavnom istraživanju istaknuto je da je u trima uzastopnim generacijama jedne turske porodice od WSN-a patilo dvadesetero članova (15). U dosadašnjim izvještajima o WSN-u zabilježenom u jednoj tajlandskoj obitelji, pacijent je naveo kako zna da je i otac imao taj poremećaj, ali nije znao je li još koji član porodice imao slične lezije (6).

Klinička i histopatološke značajke WSN-a u ovom prikazu slažu se s onima u dosadašnjim izvještajima (1, 2, 4–7, 14, 16). WSN se može lako zamijeniti s drugim bijelim lezijama, uključujući kandidijazu, leukoedem, lichen planus (LP), leukoplakiju, kroničnu ugriznu ranu obraza, kemijske opekline i ostale prirodne poremećaje kao što su nasljedna benigna intraepitelialna diskeratoza (HBID), kongenitalna pahionihija, Darijerova bolest i kongenitalna diskeratoza

fore, we cannot neglect a possibility of the risk of the recall bias. The presence of oral WSN in the same family members has been reported in the previous studies (1-6, 8, 12-15). The study of WSN in a three-generation family in Brazil showed that 8 out of 23 descendants (34.78%) were affected (5) and 18 out of 43 descendants (41.86%) were noted for a four-generation Scottish family (13). The recent study has reported that 20 family members were affected in a three consecutive generations in Turkey (15). In the previous report of WSN in a Thai family, the patient reported that only his father was similarly affected, but he did not know whether other paternal family members had similar lesions (6).

The clinical and histopathologic features of WSN in this study are in agreement with prior reports (1, 2, 4-7, 14, 16). WSN may be confused with other oral white lesions including candidiasis, leukoedema, lichen planus (LP), leukoplakia, chronic cheek biting, chemical burns and other congenital or familial disorders such as hereditary benign intraepithelial dyskeratosis (HBID), *pachyonychia congenita*, Darier's disease, *dyskeratosis congenita* (1-3, 5, 6, 16). The differential diagnosis among these diseases should be based on

(1 – 3, 5, 6, 16). Diferencijalna dijagnoza se u slučaju navedenih bolesti treba temeljiti na obiteljskoj anamnezi, usporednim kožnim lezijama, te kliničkim i histopatološkim svojstvima. Za razliku od bijelog plaka, kod WSN-a koji je čvrsto pričvršćen na podlogu, bijele pseudomembranozne naslage od kandidijaze mogu se lako ukloniti s eritematozne površine. Kronična hiperplastična kandidijaza može se isključiti ako se biopsijom ne pronađu gljivične hife, kultura je negativna na kandidu i lezije ne reagiraju na protugljivičnu terapiju (1, 2, 14). Lezija leukoedema nestaje rastezanjem sluznice, a kod WSN-a perzistira i onda..... (6). Naslage LP-a imaju bijele keratotične strije na rubovima (1). Osim toga, LP se može uglavnom isključiti jer je rijedak u djetinjstvu ili odmah nakon rođenja. Leukoplakija je malo vjerojatna dijagnoza kod djeteta koje ne puši i ne pije alkohol. Pozitivna obiteljska anamneza također govori protiv leukoplakije. Kronična ugrizna lezija obraza i kemijske opekline mogu se isključiti pozornim uzimanjem anamneze, kliničkim pregledom i odsutnošću pozitivne obiteljske i porodične anamneze. WSN se može zamijeniti i s HBID-om – kongenitalnom pahinoihijom, Darierovom bolešću i kongenitalnom diskeratozom zato što navedene lezije imaju i ekstraoralne lezije (5). Premda WSN pogađa primarno oralnu sluznicu, dokumentirano je nekoliko mogućih ekstraoralnih lokalizacija, poput nosne, laringealne, ezofagealne i anogenitalne sluznice, ali ne i konjunktive (1, 3, 12, 13). HBID je endemski u trorasnom stanovništvu Sjeverne Karoline u SAD-u. Osim oralnih lezija, pacijenti pate od okularnih lezija bulbarne konjunktive (1, 2, 5, 9). Kongenitalna pahinoihija je hiperkeratoza dlanova, stopala i hrpta stopala, a pojavljuju se i abnormalnosti noktiju (1, 3, 5). Kožne promjene u slučaju Darierove bolesti opsežnije su nego oralni pokazatelji bolesti (9). Kongenitalna diskeratoza ima ekstraoralne manifestacije, poput kožne hiperpigmentacije i displastičnih promjena na noktima te hematološke probleme uz prisutne oralne lezije (5). Trebalo bi obaviti biopsiju kako bi se postavila konačna dijagnoza i isključila opasnost od displazije ili malignosti. Kad se postavi dijagnoza WSN-a, nije potrebno nikakvo liječenje (6, 8). U nekoliko je studija istaknuta učinkovitost terapije penicilinom i tetraciklinom, premda su rezultati dobiveni na malom broju pacijenata (9 – 11). Povoljan utjecaj antibiotske terapije na WSN može biti rezultat modulacije epitelne keratinizacije (9, 11). Osim toga, kod djece kojoj se zubi razvijaju treba izbjegavati sustavnu terapiju tetraciklinima (9). Pacijentu je važno objasniti prirodu poremećaja i pratiti ga na kontrolnim pregledima, posebice kod onih s fobijom od raka jer lezije izgledaju velike, no još nikada nije opisana maligna transformacija WSN-a.

Zaključak

Opisana su dva slučaja WSN-a iz četiriju generacija jedne porodice. Kada se postavlja dijagnoza trebale bi se uzeti u obzir obiteljska i porodična anamneza te kliničke i histopatološke karakteristike. A nakon što se postavi dijagnoza WSN-a, nije potrebna nikakva terapija nego samo praćenje pacijenta. Važno je razmotriti WSN u diferencijalnoj dijagnostici bijelih lezija kod djece, posebice ako su pozitivne obiteljska i porodična anamneza.

family history, concomitant skin lesions, clinical and histological characteristics. Unlike white plaque of WSN which is firmly attached to the underlying tissue, white plaque of pseudomembranous candidiasis can be easily removed leaving erythematous surfaces. Chronic hyperplastic candidiasis can be excluded when no fungal hyphae are encountered in the biopsy specimen, candidal culture is negative, and the lesion is unresponsive to antifungal treatment (1, 2, 14). The lesion of leukoedema disappears upon stretching the mucosa while the lesion of WSN still persists (6). The plaque type of LP should have white keratotic striae at the periphery (1). Furthermore, LP could be largely eliminated because its onset is uncommon in childhood or at birth. Leukoplakia is an unlikely diagnosis in a child with no history of smoking and alcohol consumption. Positive familial history is also against the diagnosis of leukoplakia. Chronic cheek biting and chemical burns can be ruled out by careful history taking, clinical examination and absence of family history. WSN may be confused with HBID, *pachyonychia congenita*, Darier's disease, *dyskeratosis congenita*. The aforementioned disorders have extra-oral lesions (5). Although WSN primarily affects the oral mucosa, several extraoral mucosal sites including nasal, laryngeal, esophageal and anogenital mucosa, but not conjunctival involvement have been documented (1, 3, 12, 13). HBID is endemic in a triracial population in North Carolina. Apart from oral lesions, patients also develop ocular lesions in the bulbar conjunctiva (1, 2, 5, 9). *Pachyonychia congenita* has palmar and plantar hyperkeratosis, hyperhidrosis and nail abnormalities (1, 3, 5). Skin changes in Darier's disease are more conspicuous than the oral counterpart (9). *Dyskeratosis congenita* also exhibits extra-oral manifestations such as skin hyperpigmentation, dysplastic nail changes and hematologic problems in addition to oral lesions (5). In addition, biopsy should be performed for definitive diagnosis and to rule out the risk of dysplasia or malignancy.

Once the diagnosis of WSN is established, no treatment is required (6, 8). However, a few reports have shown the efficacy of the treatment with penicillin and tetracycline, although the results were derived from a small cohort of patients (9-11). The beneficial effect of antibiotics in the treatment of WSN may result from the modulation of epithelial keratinization (9, 11). Furthermore, administration of systemic tetracycline therapy in children with developing dentition should be avoided (9). It is important to reassure the patient of the nature of this disorder and follow-up the patient periodically, especially in cancer phobia patients since the lesion seems to be extensive. However, malignant transformation has never been reported.

Conclusion

We described two cases of WSN from a four-generation family. The family history, clinical and histopathologic characteristics should all be taken into account when establishing the diagnosis. Once the diagnosis of WSN is reached, no treatment other than follow-ups is required. It is important to consider WSN in the differential diagnosis of white lesions in children, particularly with the presence of a family history.

Abstract

White sponge nevus (WSN) is a rare benign autosomal dominant disorder which is usually manifested as soft, white, and spongy plaque involving the mucous membrane, predominantly the oral mucosa. Onset is at birth or during childhood with no gender predilection. We present a 4-year-old boy and the 42-year-old father, complaining of painless white lesions in the oral cavity. The family history revealed that of the 18 descendants, 11 (61.11%) had WSN. Clinical examination revealed diffuse, folded, spongy, white plaque involving the buccal mucosa bilaterally and other oral mucosal areas. Histological examination showed acanthosis, hyperparakeratosis, spongiosis and the presence of an eosinophilic condensation in the perinuclear region from the spinous layer. The diagnosis was established as WSN based on the positive four-generation family history, clinical and histological features. There is no specific treatment for WSN. Despite the rarity of WSN, this lesion should be included in the differential diagnosis of white lesions in childhood, especially with a positive family history.

Received: September 7, 2012

Accepted: November 25, 2012

Address for correspondence

Pornpan Youngnak-Piboonratanakit DDS, MS, Ph.D
Chulalongkorn University
Faculty of Dentistry
Department of Oral Medicine
Bangkok 10330, Thailand
Tel : +6622188942
Fax : +6622188941
pornpan.p@chula.ac.th

Key words

Leukokeratosis, Hereditary Mucosal;
Mouth Mucosa

References

- Jorgenson RJ, Levin S. White sponge nevus. *Arch Dermatol.* 1981 Feb;117(2):73-6.
- Vucicevic-Boras V, Cekic-Arambasin A, Bosnjak A. White sponge nevus. *Acta Stomatol Croat.* 2001;35(2):287-92.
- Cutlan JE, Saunders N, Olsen SH, Fullen DR. White sponge nevus presenting as genital lesions in a 28-year-old female. *J Cutan Pathol.* 2010 Mar;37(3):386-9.
- Zhang JM, Yang ZW, Chen RY, Gao P, Zhang YR, Zhang LF. Two new mutations in the keratin 4 gene causing oral white sponge nevus in Chinese family. *Oral Dis.* 2009 Jan;15(1):100-5.
- Martelli H Jr, Pereira SM, Rocha TM, Nogueira dos Santos PL, Batista de Paula AM, Bonan PR. White sponge nevus: report of a three-generation family. *Oral Surg Oral Med Oral Pathol Oral Radiol Endod.* 2007 Jan;103(1):43-7.
- Iamaroon A, Pongsiriwet S. Oral white sponge naevus: case report. *Dent Update.* 2003 Jun;30(5):252-3.
- Morris R, Gansler TS, Rudisill MT, Neville B. White sponge nevus. Diagnosis by light microscopic and ultrastructural cytology. *Acta Cytol.* 1988 May-June;32(3):357-61.
- Lopez Jornet P. White sponge nevus: presentation of a new family. *Pediatr Dermatol.* 2008 Jan-Feb;25(1):116-7.
- Lamey PJ, Bolas A, Napier SS, Darwazeh AM, Macdonald DG. Oral white sponge naevus: response to antibiotic therapy. *Clin Exp Dermatol.* 1998 Mar;23(2):59-63.
- Becker LR, Lutz C, Erbard H, Brocker EB, Hamm H. White sponge naevus successfully treated with tetracycline mouth rinse. *Acta Derm Venereol.* 1997 Sep;77(5):413.
- Otobe IF, de Sousa SO, Matthews RW, Migliari DA. White sponge naevus: improvement with tetracycline mouth rinse: report of four cases. *Clin Exp Dermatol.* 2007 Nov;32(6):749-51.
- Shibuya Y, Zhang J, Yokoo S, Umeda M, Komori T. Constitutional mutation of keratin 13 gene in familial white sponge nevus. *Oral Surg Oral Med Oral Pathol Oral Radiol Endod.* 2003 Nov;96(5):561-5.
- Terrinoni A, Rugg EL, Lane EB, Melino G, Felix DH, Munro CS, et al. A novel mutation in the keratin 13 gene causing oral white sponge nevus. *J Dent Res.* 2001 Mar;80(3):919-23.
- Chao SC, Tsai YM, Yang MH, Lee JY. A novel mutation in the keratin 4 gene causing white sponge naevus. *Br J Dermatol.* 2003 Jun;148(6):1125-8.
- Kurklu E, Ozyanat G, Ak G, Tanyeri H, Deger S. Oral white sponge nevus and dental implants: Report of two cases. *Acta Stomatol Croat.* 2012;46(1):59-64.
- Lucchese A, Favia G. White sponge naevus with minimal clinical and histological changes: report of three cases. *J Oral Pathol Med.* 2006 May;35(5):317-9.