

# Identification of Diabetic Retinopathy in Retinal Images using Support Vector Machine

<sup>1</sup> Sneha Purushartha, <sup>2</sup> Bhakti Kurhade

<sup>1</sup> Department of Computer Science and Engineering, G.H.R.A. of engineering and technology, RTMN University, India

<sup>2</sup> Department of Computer Science and Engineering, G.H.R.A. of engineering and technology, RTMN University, India

**Abstract** - Retinal vessel segmentation algorithms are a fundamental component of automatic retinal disease screening systems. It helps in not only detecting the retinal diseases but also can help to recover that disease in time like diabetic retinopathy, retinopathy of prematurity (ROP) etc. Supervised Retinal vessel segmentation algorithms are most widely research and studied by researcher. As more research work is published on supervised algorithm we are decided to work on this paper. In this work we are simply examines the supervised blood vessel segmentation methodologies in two dimensional retinal images acquired from a fundus camera along with a survey along with provide the most of the databases which are locally present for this work. The aim of this paper is to review and analyze the supervised retinal vessel extraction algorithms, techniques and methodologies, giving a brief description, highlighting the key points and the performance measures given by the different authors in systematic form. We trying to provide the reader a framework for the existing research; to introduce the all supervised retinal vessel segmentation algorithms along with databases which are locally present over for work and future directions and summarize the survey. The performance of algorithms is compared and analyzed on two publicly available databases (DRIVE and STARE) of retinal images using a number of measures which include accuracy, true positive rate, false positive rate, sensitivity, specificity and area under receiver operating characteristic (ROC) curve.

**Keywords** - Supervised, diabetic, segmentation, diabetic.

## 1. Introduction

Automatic segmentation of the vasculature in retinal images is important for the detection of a number of eye diseases. Some diseases, e.g. retinopathy of prematurity, affect the morphology of the vessel tree itself[1,2]. In other cases, e.g. pathologies like microaneurysms, the performance of automatic detection methods may be improved if regions containing vasculature can be excluded from the analysis [3, 4]. Another important

application of automatic retinal vessel segmentation is in the registration of retinal images of the same patient taken at different times [5]. The registered images are useful in automatically monitoring the progression of certain diseases [6]. Finally, the position, size and shape of the vasculature provides information which can be used to locate the optic disk and the fovea [11]. Therefore automatic vessel segmentation forms an essential component of any automated eye-disease screening system.

Automatic generation of retinal maps and extraction of branch points have been used for temporal or multimodal image registration [4], retinal image mosaic synthesis [5], optic disk identification and fovea localization [6]. Moreover, the retinal vascular tree is found to be unique for each individual and can be used for biometric identification [7,8]. Manual segmentation of retinal blood vessels is a long and tedious task which also requires training and skill. It is commonly accepted by the medical community that automatic quantification of retinal vessels is the first step in the development of a computer-assisted diagnostic system for ophthalmic disorders. A large number of algorithms and techniques have been published relating to the segmentation of retinal blood vessels. In this paper, we have presented a survey of supervised algorithms particularly focusing on the extraction of blood vessels from two dimensional, colored, non-dilated retinal images acquired either from a fundus camera or using fluoresce in angiography.

Reviews and surveys on the algorithms for segmentation of vessel like structures in medical images are present in the literature [9,10]. For instance, Kirbas and Quek [11] presented a comprehensive survey of the techniques and algorithms for extraction of vessels and elongated structures in 2-D as well as 3-D medical images focused

in a variety of application domains. A brief survey on retinal segmentation and registration algorithms is presented by Mabrouk et al. [12] which limits discussion to the extraction of cores and edges of retinal blood vessels. The most recent studies [13,14] discuss the algorithms for automatic detection of diabetic retinopathy in retinal images. This survey is particularly focuses on the supervised techniques, algorithms and methodologies for the segmentation of blood vessels in two dimensional colored retinal images acquired from a fundus camera. The objectives of this paper are to review the supervised retinal vessel segmentation methodologies; to provide a detailed resource of the algorithms employed for vessel segmentation to researchers for ready reference; to discuss the advantages and disadvantages of the various supervised approaches; to discuss the current trends and future directions and summarize the open problems.

The paper is structured in five sections; Section 2 describes the challenges associated with retinal vessel segmentation, the materials used for analysis, and quantitative measures of performance for vessel segmentation. The classification of the supervised extraction methods and brief description of papers for this category is given in Section 3. The discussion is given in Section 4. Finally the conclusion and summarization in Section 5.

## 2. Retinal Image Preprocessing and Datasets

### 2.1 Retinal Vessel Segmentation

The retinal vasculature is composed of arteries and veins appearing as elongated features, with their tributaries visible within the retinal image. There is a wide range of vessel widths ranging from one pixel to twenty pixels, depending on both the width of the vessel and the image resolution. Other structures appearing in ocular fundus images include the retina boundary, the optic disc, and pathologies in the form of cotton wool spots, bright and dark lesions and exudates as shown in Fig. 1(b–d). The vessel cross-sectional intensity profiles approximate a Gaussian shape or a mixture of Gaussians in the case where a central vessel reflex is present. The orientation and grey level of a vessel does not change abruptly; they are locally linear and gradually change in intensity along their lengths. The vessels can be expected to be connected and, in the retina, form a binary treelike structure. However, the shape, size and local grey level of blood vessels can vary hugely and some background features may have similar attributes to vessels as illustrated in Fig. 1(a and d). Vessel crossing and branching can further

complicate the profile model. As with the processing of most medical images, signal noise, drift in image intensity and lack of image contrast pose significant challenges to the extraction of blood vessels.

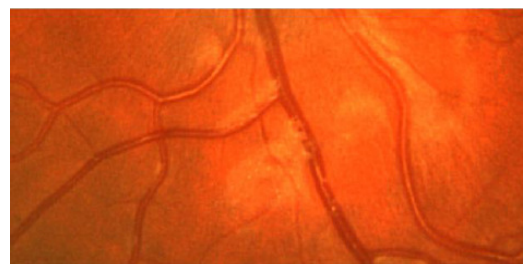
Retinal vessels also show an evidence of a strong reflection along their center line known as a central vessel reflex as evident in Fig. 1(a), which is more apparent in arteries than veins, is stronger at images taken at longer wavelengths, and typically found in the retinal images of younger patients.

### 2.2 Publicly Available Retinal Image Databases

A summary of all the publicly available retinal image databases known to us is given in this section. Most of the retinal vessel segmentation methodologies are evaluated on two databases (DRIVE and STARE).

#### 2.2.1 DRIVE Database

The DRIVE (Digital Retinal Images for Vessel Extraction) [15] is a publicly available database, consisting of a total of 40 color fundus photographs. The photographs were obtained from a diabetic retinopathy screening program in the Netherlands. The screening population consisted of 453 subjects between 31 and 86 years of age. Each image has been JPEG compressed, which is common practice in screening programs. Of the 40 images in the database, 7 contain pathology, namely exudates, hemorrhages and pigment epithelium changes. See Fig. 2 for an example of both a normal and a pathological image. The images were acquired using a Canon CR5 non-mydratic 3-CCD camera with a 45° field of view (FOV). Each image is captured using 8 bits per color plane at 768 × 584 pixels. The FOV of each image is circular with a diameter of approximately 540 pixels. The set of 40 images was divided into a test and training set both containing 20 images. Three observers, the first author is a computer science student manually segmented a number of images. The first observer segmented all 20 images of the training set .The test set



(a)

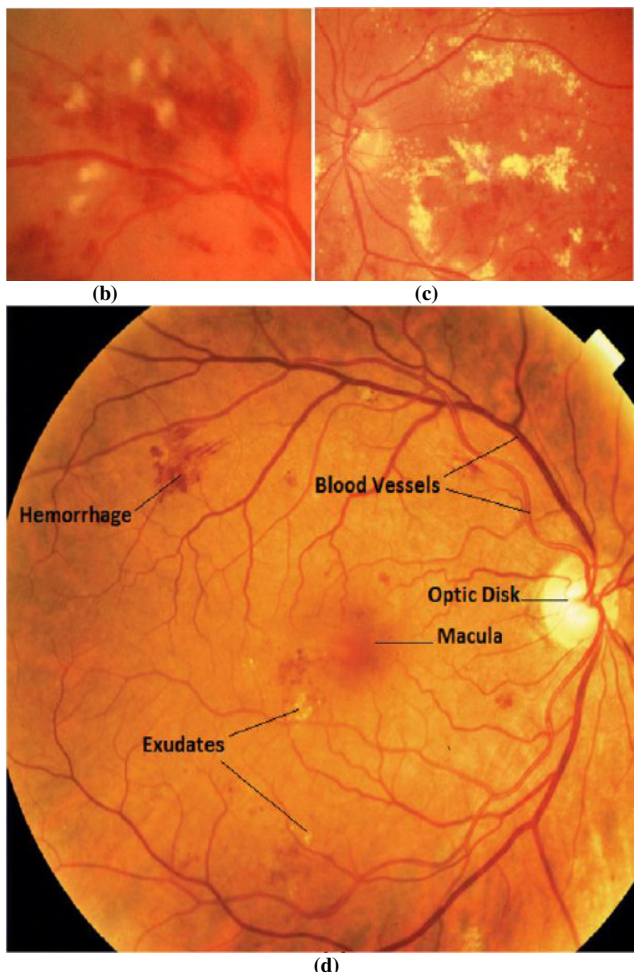


Fig. 1 – Morphology of retinal images: (a) central vessel reflex and uneven background, (b) cotton wool spots, (c) hard exudates, (d) anatomical structures in the retina.

was segmented twice resulting in a set X and Y. Set X was segmented by the first observer while set Y was completely segmented by the first observer but under the guidance of both guide and head. The performance of the vessel segmentation algorithms is measured on the test set.

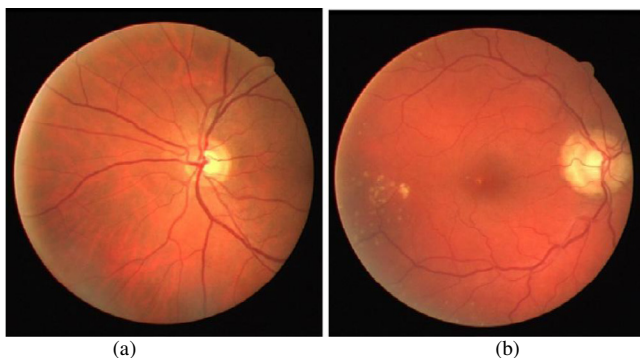


Fig. 2 – Retinal images from DRIVE: (a) healthy retina, (b) retina showing pathologies.

In set X the observers marked 577,649 pixels as vessel and 3,960,494 as background (12.7% vessel). In set Y 556,532 pixels are marked as vessel and 3,981,611 as background (12.3% vessel). The second author is guide and the third author is our Head to guide the whole things that is to be done.

### 2.2.2 STARE database

The STARE database [16] contains 20 images for blood vessel segmentation; ten of these contain pathology. Fig. 3 shows retinal images from the STARE database. The digitized slides are captured by a TopCon TRV-50 fundus camera at 35° field of view. The slides were digitized to 605 × 700 pixels, 8 bits per color channel. The approximate diameter of the FOV is 650 × 500 pixels. Two observers manually segmented all the images. The first observer segmented 10.4% of pixels as vessel, against 14.9% vessels for the second observer. The difference in segmentation between the two observers is due to the fact that the second observer segmented many more of the thinner vessels than the first one. Performance is computed with the segmentation of the first observer as the ground truth.

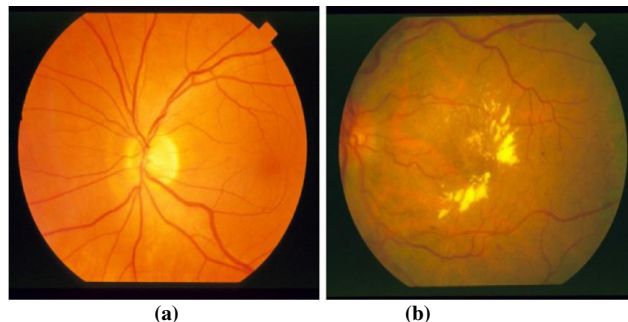


Fig. 3 – Retinal Images from STARE: (a) healthy retina, (b) pathological retina.

### 2.2.3. ARIA Online

This database was created in 2006, in a research collaboration between St. Paul’s Eye Unit, Royal Liverpool University Hospital Trust, Liverpool, UK and the Department of Ophthalmology, Clinical Sciences, University of Liverpool, Liverpool, UK [17]. The database consists of three groups; one has 92 images with age-related macular degeneration, the second group has 59 images with diabetes and a control group consists of 61 images. The trace of blood vessels, the optic disc and fovea location is marked by two image analysis experts as the reference standard. The images are captured at a resolution of 768 × 576 pixels in RGB color with 8-bits per color plane with a Zeiss FF450+ fundus camera at a

50° FOV and stored as uncompressed TIFF files. 2.3.4. ImageRet The ImageRet database was made publicly available in 2008 and is subdivided into two sub-databases, DIARETDB0 and DIARETDB1 [18]. DIARETDB0 contains 130 retinal images of which 20 are normal and 110 contain various symptoms of diabetic retinopathy. DIARETDB1 contains 89 images out of which 5 images are of a healthy retina while the other 84 have at least some signs of mild proliferative diabetic retinopathy. The images are marked by four experts for the presence of microaneurysms, hemorrhages, and hard and soft exudates. The images are acquired with a 50° FOV using a fundus camera with unknown settings at a size of 1500 × 1152 pixels in PNG format.

#### 2.2.4. Messidor

The Messidor-project database [19] is the largest database of 1200 retinal images currently available on the internet and is provided courtesy of the Messidor program partners. The images were acquired at three different ophthalmology departments using a non-mydratic 3CCD camera (Topcon TRC NW6) at 45° FOV with a resolution of 1440 × 960, 2240 × 1488 or 2304 × 1536 pixels and are stored in TIFF format. Out of 1200 Images 800 are captured with pupil dilation. The reference standard provided contains the grading for diabetic retinopathy and the risk of macular edema in each image.

#### 2.2.5 Review

The Retinal Vessel Image set for Estimation of Widths (REVIEW) [20] was made available online in 2008 by the Department of Computing and Informatics at the University of Lincoln, Lincoln, UK. The dataset contains 16 mydratic images with 193 annotated vessel segments consisting of 5066 profile points manually marked by three independent experts. The 16 images are subdivided into four sets, the high resolution image set (HRIS, 8 images), the vascular disease image set (VDIS, 4 images), the central light reflex image set (CLRIS, 2 images) and the kickpoint image set (KPIS, 2 images).

#### 2.2.6 ROC Microaneurysm Set

The ROC microaneurysm dataset [21] is part of a multi-year online competition of microaneurysm detection that was arranged by the University of Iowa in 2009. The database consists of 100 digital color fundus photographs containing microaneurysms and is subdivided into a training set of 50 images and a test set of 50 images. A reference standard indicating the location of

microaneurysms is provided with the training set. The images are captured using either a TopCon NW100 or a Canon CR5-45NM camera at 45° FOV and was JPEG compressed in the camera. There are three different image sizes present in the database; 768 × 576, 1058 × 1061 and 1389 × 1383 pixels.

#### 2.2.7 VICAVR database

The VICAVR database [22] is a set of retinal images used for the computation of the A/V ratio. The database currently includes 58 images. The images have been acquired with a TopCon nonmydratic camera NW-100 model and are optic disc centered with a resolution of 768 × 584. The database includes the caliber of the vessels measured at different radii from the optic disc as well as the vessel type (artery/vein) labeled by three experts.

#### 2.2.8 VEVI0

It consist of thirty-two image database of VIO images, the Vessel Extraction in Video Indirect Ophthalmoscopy (VEVIO) dataset[23]. VEVIO consists of sixteen manually selected frames and sixteen corresponding enhanced large FOV mosaics from sixteen different premature infants imaged. All images are of each patient's right eye. Figure 4 showcases some of the frames and mosaics in the dataset.

Four steps were needed to construct the VEVIO dataset: video recording, manual frame selection, automatic mosaicing and manual vessel segmentation. Each video was recorded at a resolution of 720×576 pixels in 24-bit color and saved as an interlaced, compressed Audio Video Interleaved (AVI) file.

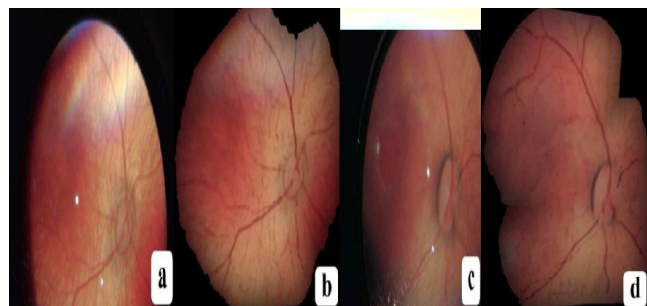


Fig. 4. VEVIO images: Two pairs of manually selected frames (a), (c) and two automatically generated mosaics (b), (d). Although each pair was obtained from the same video, the manual frames were not used to generate the mosaics.

### 2.2.9 Gold Standard Database for Evaluation of Fundus Image Segmentation Algorithms

This database has been established by a collaborative research group to support comparative studies on automatic segmentation algorithms on retinal fundus images. The database will be iteratively extended and the webpage will be improved. The public database contains at the moment 15 images of healthy patients, 15 images of patients with diabetic retinopathy and 15 images of glaucomatous patients. Binary gold standard vessel segmentation images are available for each image. Also the masks determining field of view (FOV) are provided for particular datasets[24]. The gold standard data is generated by a group of experts working in the field of retinal image analysis and clinicians from the cooperated ophthalmology clinics. We intend to add further gold standard data to the existing images to help the evaluation of algorithms which localize the macula, optic disc, or differentiate between arteries and v

### 2.3. Performance measures

In the retinal vessel segmentation process, the outcome is a pixel-based classification result. Any pixel is classified either as vessel or surrounding tissue. Consequently, there are four possibilities; two classifications and two misclassifications. The classifications are the true positive (TP) where a pixel is identified as vessel in both the ground truth and segmented image, and the true negative (TN) where a pixel is classified as a non-vessel in the ground truth and the segmented image. The two misclassifications are the false negative (FN) where a pixel is classified as non-vessel in the segmented image but as a vessel pixel in the ground truth image, and the false positive (FP) where a pixel is marked as vessel in the segmented image but non-vessel in the ground truth image. The true positive rate (TPR) represents the fraction of pixels correctly detected as vessel pixels. The false positive rate (FPR) is the fraction of pixels erroneously detected as vessel pixels. The accuracy (Acc) is measured by the ratio of the total number of correctly classified pixels (sum of true positives and true negatives) to the number of pixels in the image field of view. Sensitivity (SN) reflects the ability of the algorithm to detect the vessel pixels. Specificity (SP) is the ability to detect non-vessel pixels. It can be expressed as  $1 - \text{FPR}$ . The positive predictive value (PPV) or precession rate gives the proportion of identified vessel pixels which are true vessel pixels. The PPV is the probability that an identified vessel pixel is a true positive. A receiver operating characteristic (ROC) curve plots the fraction of vessel pixels correctly

classified as vessel, namely the TPR), versus the fraction of non-vessel pixels wrongly classified as vessel, namely the FPR). The closer the curve approaches the top left corner; the better is the performance of the system. The most frequently used performance measure extracted from the ROC curve is the value of the area under the curve (AUC) which is 1 for an optimal system. For retinal images, the TPR and FPR are computed considering only pixels inside the FOV. Table 1 summaries the performance metrics used by retinal vessel segmentation algorithms.

Table 1: Performance metrics for retinal vessel segmentation

Margin	Description
TPR	TP/vessel pixel count
FPR	FP/non-vessel pixel count
Specificity(SP)	TN/(TN+FP)
Sensitivity(SN)	TP/(TP+FN)
Accuracy(Acc)	(TP+TN)/FOV pixel count

### 3. A Summary on Supervised Retinal Vessel Segmentation Approach

A common categorization of algorithms for segmentation of vessel like structures in medical images [15] includes image driven techniques, such as edge-based and region-based approaches; pattern recognition techniques, model-based approaches, tracking-based approaches and neural network based approaches. Only supervised segmentation method category is introduced, discussed and the papers of this category are summarized. The performance measures used by the segmentation algorithm is tabulated at the end of section 3. Moreover, a table allowing a qualitative comparison of methods is also provided at the end of each section which includes the input image type, the image database used for evaluation, the quantitative performance measure used to evaluate the algorithm, whether the method is automated or involves human interaction, whether the algorithm deals with noisy retinal images, whether pathologies in the retina are taken into account by the algorithm and finally, whether the algorithm particularly handles the central vessel reflex problem or not. In this survey, a total of 11 papers have been selected from peer-reviewed publications related supervised technique. The reviewed papers are summarized in Table 2 on the basis of the image processing technique used for segmentation.

The fourth column illustrates the performance metrics used to evaluate the algorithm. The penultimate column indicates that the algorithm's capability to handle noisy

images, pathological images and images containing central vessel reflex. “Nse”, “Pth” and “Cvr” values in this column indicate that algorithm is capable of handling the noisy, pathological and central vessel reflex images, respectively.

The algorithms based on pattern recognition deal with the automatic detection or classification of retinal blood vessel features and other non vessel objects including background. Pattern recognition techniques for vessel segmentation are divided into two categories; supervised approaches and unsupervised approaches. Supervised methods exploit some prior labeling information to decide whether a pixel belongs to a vessel or not, while unsupervised methods perform the vessel segmentation without any prior labeling knowledge. In this paper we are mainly focus on supervised methods (algorithms). This methods are as follows In supervised methods, the rule for vessel extraction is learned by the algorithm on the basis of a training set of manually processed and segmented reference images often termed as the gold standard. This vascular structure in these ground truth or gold standard images is precisely marked by an ophthalmologist. However, as noted by Hoover et al. [16] there is significant disagreement in the identification of vessels even amongst expert observers.

In a supervised method, the classification criteria are determined by the ground truth data based on given features. Therefore the prerequisite is the availability of the already classified ground truth data, which may not be available in real life applications. As supervised methods are designed based on pre-classified data, their performance is usually better than that of unsupervised ones and can produce very good results for healthy retinal images. Artificial neural networks have been extensively investigated for segmenting retinal features such as the vasculature [25] making classifications based on statistical probabilities rather than objective reasoning. These neural networks employ mathematical weights to decide the probability of input data belonging to a particular output. This weighting system can be adjusted by training the network with data of known output typically with a feedback mechanism to allow retraining. Nekovei and Ying [26] describe an approach using a backpropagation network for the detection of blood vessels in angiography. The method applies the neural network directly to the angiogram pixels without prior feature detection. The pixels of the small sub-window, which slides across the angiogram image, are directly fed as input to the network. The feature vectors are formed by gray-scale values from the sub window centered on the pixel being classified. The ground truth images of

manually labeled angiograms are used as the training set to set the network’s weights. A modified version of the common delta-rule is used to obtain these weights.

The use of principal component analysis (PCA) followed by neural networks is demonstrated by Sinthanayothin et al. [27] for localization of anatomical structures in retinal images. They reported a success rate of 99.56% for the training data and 96.88% for the validation data, respectively, with an overall sensitivity and specificity of 83.3% (standard deviation 16.8%) and 91% (standard deviation 5.2%), respectively. The result of the approach was compared with an experienced ophthalmologist manually mapping out the location of the blood vessels in a random sample of seventy three  $20 \times 20$  pixel windows and requiring an exact match between pixels in both images. Niemeijer [28] extracts a feature vector for each pixel that consists of the green plane of the RGB image and the responses of a Gaussian matched filter and its first and second order derivatives at the scales of 1, 2, 4, 8, 16 pixels. The algorithm is tested on the DRIVE database resulting in an average accuracy of 0.9416 and area under the ROC curve of 0.9294. Staal [29] presented a ridge based vessel segmentation methodology from colored images of the retina which exploits the intrinsic property that vessels are elongated structures. The technique is based on an extraction of image ridges, which are natural indicators of vessels and coincide approximately with vessel centerlines. Image primitives are computed by grouping the ridge pixels into the sets that approximate straight line elements. The image is partitioned into convex set regions by assigning each image pixel to the closest line element from these sets. Every line element defines a local coordinate frame within each patch, in which local features are extracted for every pixel. In total, 27 features are selected from convex set regions, collectively as well as from individual pixels, using a sequential forward selection method. A  $k$ -NN classifier is used for classification. The methodology is tested on the publicly available STARE and Utrecht database obtained from a screening programme in the Netherlands. The method achieves an average accuracy of 0.9516 and an area under the ROC curve of 0.9614 on the STARE database.

The use of a 2-D Gabor wavelet and supervised classification for retinal vessel segmentation has been demonstrated by Soares et al. [30]. Each pixel is represented by a feature vector composed of the pixel’s intensity and two-dimensional Gabor wavelet transform responses taken at multiple scales. A Gaussian mixture model classifier (a Bayesian classifier in which each

class-conditional probability density function is described as a linear combination of Gaussian functions) is used to classify each pixel as either a vessel or non-vessel pixel. The methodology is evaluated on the DRIVE and STARE datasets resulting in an average accuracy of 0.9466 and 0.9480 and the area under the ROC curve as 0.9614 and 0.9671 for DRIVE and STARE, respectively. The algorithm takes in to account the information local to each pixel through image filters, ignoring useful information from shapes and structures present in the image. It does not work very well on the images with non uniform illumination as it produces false detection in some images on the border of the optic disc, hemorrhages and other types of pathologies that present strong contrast. The application of line operators as feature vector and SVM for pixel classification is proposed by Ricci and Perfetti [31]. A line detector which is based on the evaluation of the average grey level along lines of fixed length passing through the target pixel at different orientations is applied to the green channel of an RGB image and the response is thresholded to obtain unsupervised pixel classification.

Moreover, two orthogonal line detectors are also employed along with the grey level of the target pixel to construct a feature vector for supervised classification using a support vector machine. With respect to other supervised techniques, the algorithm (1) requires fewer features, (2) feature extraction is computationally simpler, and (3) fewer examples are needed for training. The algorithm makes use of local differential computation of the line strength which makes the line detector robust with respect to non-uniform illumination and contrast. Also the line detector behavior in the presence of a central reflex is satisfactory. The performance of both methods is evaluated on the publicly available DRIVE and STARE databases through ROC analysis, resulting in average accuracy of 0.9563 and 0.9584 and the area under ROC curve as 0.9558 and 0.9602 for DRIVE and STARE, respectively. Osareh and Shadgar [32] use multiscale Gabor filters for vessel candidate identification, then the features are extracted using principal component analysis. The parameters for Gabor filters are optimally tuned with experimentations. The image pixels are classified as vessels and non-vessels using the corresponding feature vectors by the Gaussian mixture model (GMM) and support vector machines (SVM). The methodology is tested on DRIVE as well as on the author's dataset consisting of 90 normal and abnormal images. The classification accuracy obtained is 95.24%, with 96.14% sensitivity and 94.84% specificity with the GMM. The best overall accuracy, using optimal parameters for SVM is 96.75% with 96.50% sensitivity and 97.10% specificity.

The methodology achieves area under the ROC curve as 0.965 on the DRIVE database. However, there are some false positives due to background noise and non-uniform illumination, the border of the optic disc and other types of pathologies and the thinnest vessels are also not detectable, however, these thin vessels are not of much clinical importance. The combination of several image processing techniques with SVM classification for vessel segmentation is proposed by Xu and Luo [33]. The background of the green channel is normalized, the large vessels are segmented using adaptive local thresholding and the optic disc edges are removed. The original image is then processed by wavelets at multiple scales for feature extraction. The line detectors are used to identify thin vessels. A 12 dimensional feature vector for each residual pixel in the binary retinal image excluding large vessels is constructed and an SVM is used to distinguish thin vessel segments from all the fragments. A tracking method based on a combination of vessel direction and the eigenvector of the Hessian matrix is used for thin vessel growth to obtain a segmented vessel tree. The method achieves an average accuracy of 0.9328 and an average sensitivity of 0.7760 on the DRIVE database.

The combination of several image processing techniques with SVM classification for vessel segmentation is proposed by Xu and Luo [34]. The background of the green channel is normalized, the large vessels are segmented using adaptive local thresholding and the optic disc edges are removed. The original image is then processed by wavelets at multiple scales for feature extraction. The line detectors are used to identify thin vessels. A 12 dimensional feature vector for each residual pixel in the binary retinal image excluding large vessels is constructed and an SVM is used to distinguish thin vessel segments from all the fragments. A tracking method based on a combination of vessel direction and the eigenvector of the Hessian matrix is used for thin vessel growth to obtain a segmented vessel tree. The method achieves an average accuracy of 0.9328 and an average sensitivity of 0.7760 on the DRIVE database. The combination of the radial projection and the semisupervised self-training method using SVM is employed by You et al. [35] for vessel segmentation. The vessel centerlines and the narrow and low contrast blood vessels are located using radial projections. A modified steerable complex wavelet is employed for vessel enhancement. The line strength measures are applied to the vessel enhanced image to generate the feature vector. The SVM classifier is used in a semi-supervised self training to extract the major structure of vessels. The segmented vasculature is obtained by the union of the two. The algorithm self learns from human-labeled data and

weakly labeled data therefore yielding good results with decrease in the detection of false vessels. The method is very good in detecting narrow and low contrast vessels but prone to errors in case of pathologies. The average accuracy, sensitivity and specificity on the DRIVE database is 0.9434, 0.7410, and 0.9751, respectively and for the STARE database 0.9497, 0.7260, and 0.9756, respectively. Marin et al. [36] presented a neural network based supervised methodology for the segmentation of retinal vessels. The methodology uses a 7-D feature vector composed of gray-level and moment invariant-based features. A multilayer feed forward neural network is utilized for training and classification. The input layer consists of seven neurons, the three hidden layers consist of fifteen neurons each and output layer is comprised of single neuron. The method proves to be effective and robust with different image conditions and on multiple image databases even if the neural network is trained on only one database. The average accuracy, AUC, sensitivity and specificity on the DRIVE database is 0.9452, 0.9588, 0.7067, and 0.9801, respectively and for the STARE database 0.9526, 0.9769, 0.6944, and 0.9819, respectively.

#### 4. Discussion

It seems that the performance of algorithms based on supervised classification is better in general than their counterparts. Almost all the supervised methods report the area under ROC of approximately 0.95 and among them Soares et al. [30] reported the highest. However, these methods do not work very well on the images with non uniform illumination as they produce false detection in some images on the border of the optic disc, hemorrhages and other types of pathologies that present strong contrast. Matched filtering has been extensively used for automated retinal vessel segmentation. The background homogenization followed by the use of gray level and moment invariant based features for supervised classification [36] is observed to be training set robust. The classifier is trained on the DRIVE database and the application to the STARE database yields high accuracy. The combination of radial projections with steerable wavelets and semi-supervised classification [35] resulted in very good performance in the detection of narrow and low contrast vessels, thus producing highest sensitivity.

#### 5. Conclusions

The segmentation of the blood vessels in the retina has been a heavily researched area in recent years. The accurate extraction of the retinal vascular tree forms the

backbone of many automated computer aided systems for screening and diagnosis of cardiovascular and ophthalmologic diseases. Even though many promising techniques and algorithms have been developed, there is still room for improvement in blood vessel segmentation methodologies. Most of the all techniques available in the literature are evaluated on a limited range of datasets which include twenty images each from the DRIVE and STARE databases. The performance measures presented in most of the papers are calculated on a small number of images of particular morphological characteristics. The limited range of images in the DRIVE and STARE databases do not cater for the image related characteristics such as, inter-image and intra image variability in luminance, drift in contrast and uneven background gray level values. The development of techniques which work for images acquired from different imaging equipment, under different environmental conditions is also an open area for research in vessel segmentation algorithms.

The classification of retinal blood vessels into arterioles and venules is essential in clinical diagnosis for vessel caliber measurement and to calculate the CRAE/CRVE/AVR. Therefore, in order to expand the utility of vessel segmentation algorithms for healthcare, there is a need to create larger datasets with available ground truths which include the labeling of vessels, other anatomical structures and classification of arterioles and venules. Besides DRIVE and STARE, the other publicly available retinal image databases include REVIEW [25] for vessel width measures, MESSIDOR [19], ImageRet [18] and ARIA Online [17] for diabetic retinopathy, ROC microaneurysm set [21] for microaneurysm detection. The VICAVR database [22] used for the computation of the A/V Ratio.video indirect ophthalmoscopy (VIO) [23] a low resolution dataset which may provide different guideline for work and Gold Standard [24] Database used for Evaluation of fundus image in different segmentation algorithms.

Accuracy and robustness of the segmentation process is essential to achieve a more precise and efficient computer aided diagnostic system. It is not expected that the vessel segmentation systems will replace the experts in diagnosis; rather they will reduce the workload of the experts in processing the sheer volume of medical images. This paper provides a survey of current supervised retinal blood vessel segmentation methods as supervised algorithm are best in providing result and we also want to develop an supervised algorithm that why we work on this paper. We have covered both early and recent literature focusing on supervised retinal vessel segmentation algorithms and techniques. Our aim is to introduce the



database available publically for different users for research purpose and also providing brief review of supervised vessel segmentation algorithm.

## References

- [1] J. J. Kanski, *Clinical Ophthalmology: A Systematic Approach*. London, U.K.: Butterworth-Heinemann, 1989.
- [2] J.J. Kanski, *Clinical Ophthalmology*, 6th ed., Elsevier Health Sciences, London, UK, 2007.
- [3] J. Lowell, A. Hunter, D. Steel, A. Basu, R. Ryder, R.L.Kennedy, Measurement of retinal vessel widths from fundus images based on 2-D modeling, *IEEE Transactions on Medical Imaging* 23 (2004) 1196–1204.
- [4] F. Zana, J.C. Klein, A multimodal registration algorithm of eye fundus images using vessels detection and Hough transform, *IEEE Transactions on Medical Imaging* 18 (1999) 419–428.
- [5] K. Fritzsche, A. Can, H. Shen, C. Tsai, J. Turner, H.L.Tanenbaum, C.V. Stewart, B. Roysam, J.S. Suri, S. Laxminarayan, Automated model based segmentation, tracing and analysis of retinal vasculature from digital fundus images, in: *State-of-The-Art Angiography, Applications and Plaque Imaging Using MR, CT Ultrasound and X-rays*, Academic Press, 2003, pp. 225–298.
- [6] L. Huiqi, O. Chutatape, Automated feature extraction in color retinal images by a model based approach, *IEEE Transactions on Biomedical Engineering* 51 (2004) 246–254.
- [7] C. Mariño, G. Penedo, M. Penas, J. Carreira, F. Gonzalez, Personal authentication using digital retinal images, *Pattern Analysis and Applications* 9 (2006) 21–33.
- [8] C. Köse, C. Ikibas, A personal identification system using retinal vasculature in retinal fundus images, *Expert Systems with Applications* 38 (2011) 13670–13681.
- [9] P. Felkel, R. Wegenkittl, A. Kanitsar, Vessel tracking in peripheral CTA datasets – an overview, in: *Computer Graphics, Spring Conference on*, 2001, 2001, pp. 232–239.
- [10] K. Buhler, P. Felkel, A.L. Cruz, Geometric methods for vessel visualization and quantification – a survey, *Geometric Modelling for Scientific Visualization* (2003) 399–421.
- [11] M.S. Mabrouk, N.H. Solouma, Y.M. Kadah, Survey of retinal image segmentation and registration, *ICGST International Journal on Graphics, Vision and Image Processing* 6 (2006) 1–11.
- [12] R.J. Winder, P.J. Morrow, I.N. McRitchie, J.R. Bailie, P.M. Hart, Algorithms for digital image processing in diabetic retinopathy, *Computerized Medical Imaging and Graphics* 33 (2009) 608–622.
- [13] O.R.A.U. Faust, E. Ng, K.-H. Ng, J. Suri, Algorithms for the automated detection of diabetic retinopathy using digital fundus images: a review, *Journal of Medical Systems* 36 (2010) 1–13.
- [14] B. Cassin, S.A.B. Solomon, *Dictionary of Eye Terminology*, 2nd ed., Triad Publishing Company, 1990.
- [15] M. Niemeijer, J.J. Staal, B.v. Ginneken, M. Loog, M.D. Abramoff, DRIVE: digital retinal images for vessel extraction, <http://www.isi.uu.nl/Research/Databases/DRIVE>, 2004.
- [16] A.D. Hoover, V. Kouznetsova, M. Goldbaum, Locating blood vessels in retinal images by piecewise threshold probing of a matched filter response, *IEEE Transactions on Medical Imaging* 19 (2000) 203–210.
- [17] ARIA Online, Retinal Image Archive <http://www.eyecharity.com/aria online/>, 2006.
- [18] T. Kauppi, V. Kalesnykiene, J.-K. Kamarainen, L. Lensu, I. Sorri, A. Raninen, R. Voutilainen, J. Pietilä, H. Kälviäinen, H. Uusitalo, DIARETDB1 diabetic retinopathy database and evaluation protocol, in: *Medical Image Understanding and Analysis (MIUA2007)*, Aberystwyth, Wales, UK, 2007, pp. 61–65.
- [19] MESSIDOR: Methods for Evaluating Segmentation and Indexing techniques Dedicated to Retinal Ophthalmology, <http://messidor.crihan.fr/index-en.php>, 2004.
- [20] B. Al-Diri, A. Hunter, D. Steel, M. Habib, T. Hudaib, S. Berry, REVIEW – a reference data set for retinal vessel profiles, in: *Engineering in Medicine and Biology Society, 2008 EMBS 2008. 30th Annual International Conference of the IEEE*, 2008, pp. 2262–2265.
- [21] M. Niemeijer, B. van Ginneken, M.J. Cree, A. Mizutani, G. Quellec, C.I. Sanchez, B. Zhang, R. Hornero, M. Lamard, C. Muramatsu, X. Wu, G. Cazuguel, J. You, A. Mayo, L. Qin, Y. Hatanaka, B. Cochener, C. Roux, F. Karray, M. Garcia, H. Fujita, M.D. Abramoff, Retinopathy online challenge: automatic detection of microaneurysms in digital color fundus photographs, *IEEE Transactions on Medical Imaging* 29 (2009) 185–195.
- [22] The VICA VR database, <http://www.varpa.es/vicavr.html>, 2010.
- [23] "Exploratory Dijkstra forest based automatic vessel segmentation: applications in video indirect ophthalmoscopy (VIO)", R. Estrada, C. Tomasi, M. T. Cabrera, D.K. Wallace, .F. Freedman, S. Farsiu *Biomedical Optics Express*, 3(2), pp. 327-339. Feb. 2012.
- [24] Jan Odstrcilik, Jiri Jan, Radim Kolar, and Jiri Gazarek. "Improvement of vessel segmentation by matched filtering in colour retinal images". In *IFMBE Proceedings of World Congress on Medical Physics and Biomedical Engineering*, pages 327 - 330, 2009. <http://www5.informatik.uni-erlangen.de/fileadmin/research/datasets/fundus-images/all.zip>.

- [25] K. Akita, H. Kuga, A computer method of understanding ocular fundus images, *Pattern Recognition* 15 (1982) 431–443.
- [26] R. Nekovei, S. Ying, Back-propagation network and its configuration for blood vessel detection in angiograms, *IEEE Transactions on Neural Networks* 6 (1995) 64–72.
- [27] C. Sinthanayothin, J.F. Boyce, H.L. Cook, T.H. Williamson, Automated localisation of the optic disc, fovea, and retinal blood vessels from digital colour fundus images, *British Journal of Ophthalmology* 83 (1999) 902–910.
- [28] M. Niemeijer, J.J. Staal, B. van Ginneken, M. Loog, M.D. Abramoff, Comparative study of retinal vessel segmentation methods on a new publicly available database, in: J.M. Fitzpatrick, M. Sonka (Eds.), *SPIE Medical Imaging*, SPIE, 2004, pp. 648–656.
- [29] J. Staal, M.D. Abramoff, M. Niemeijer, M.A. Viergever, B. Van Ginneken, Ridge-based vessel segmentation in color images of the retina, *IEEE Transactions on Medical Imaging* 23 (2004) 501–509.
- [30] J.V.B. Soares, J.J.G. Leandro, R.M. Cesar, H.F. Jelinek, M.J. Cree, Retinal vessel segmentation using the 2-D Gabor wavelet and supervised classification, *IEEE Transactions on Medical Imaging* 25 (2006) 1214–1222.
- [31] E. Ricci, R. Perfetti, Retinal blood vessel segmentation using line operators and support vector classification, *IEEE Transactions on Medical Imaging* 26 (2007) 1357–1365.
- [32] A. Osareh, B. Shadgar, Automatic blood vessel segmentation in color images of retina, *Iranian Journal Of Science And Technology Transaction B – Engineering* 33 (2009) 191–206.
- [33] L. Xu, S. Luo, A novel method for blood vessel detection from retinal images, *BioMedical Engineering Online* 9 (2010) 14.
- [34] C.A. Lupascu, D. Tegolo, E. Trucco, FABC: retinal vessel segmentation using AdaBoost, *IEEE Transactions on Information Technology in Biomedicine* 14 (2010) 1267–1274.
- [35] X. You, Q. Peng, Y. Yuan, Y.-m. Cheung, J. Lei, Segmentation of retinal blood vessels using the radial projection and semi-supervised approach, *Pattern Recognition* 44 (2011) 2314–2324.
- [36] D. Marin, A. Aquino, M.E. Gegundez-Arias, J.M. Bravo, A new supervised method for blood vessel segmentation in retinal images by using gray-level and moment invariants-based features, *IEEE Transactions on Medical Imaging* 30 (2011) 146–158.

**First Author** Passed out BE. In information technology from Amravati university in 2012., and Pursuing MTech in CSE. Currently working as a lecturer.