

# Robotic Rectal Cancer Surgery

Minia Hellan, Joshua Ellenhorn and Alessio Pigazzi  
*City of Hope, Duarte, California*  
USA

## 1. Introduction

Minimally invasive surgery has influenced the approach used in a variety of operations. Laparoscopic surgery is an accepted modality for the treatment of colon cancer, resulting in superior short term functional outcome and equivalent survival when compared with open surgery (Veldkamp et al., 2004; Nelson et al., 2004). However, minimally invasive rectal cancer surgery is still a matter of great debate. The concept of a sharp total mesorectal excision (TME) has become standard of care for the treatment of rectal cancer with the lowest recurrence rates published in literature (Heald et al., 1998). TME includes the routine excision of the intact mesorectum by precise sharp dissection of the areolar tissue between the visceral and parietal layers of the fascia. Multiple authors have shown that this approach can be carried out laparoscopically offering the patient the advantages of minimally invasive over open techniques (Morino et al., 2003; Leroy et al., 2004; Leung et al., 2004). However, there is little doubt that laparoscopic TME is technically very challenging with a steep learning curve. We therefore began using robotic technology to facilitate the dissection in the pelvis, a confined space requiring precise movements, thus taking advantage of the enhanced dexterity of the robot.

This chapter will review our operative technique of robotic-assisted total mesorectal excision for low rectal cancer as well as advantages and disadvantages of this technology.

## 2. Operative Technique

### 2.1 Positioning of the patient

We prefer a “hybrid” technique with laparoscopic mobilization of the splenic flexure and robotic-assisted TME. After induction of general anesthesia, the patient is moved to a modified lithotomy position with the legs 30-45° apart to ensure room for the robot, which will be brought in between the legs at a later time. The patient is kept in a steep Trendelenburg position during the whole procedure in order to remove the small bowel from the pelvis. During the laparoscopic mobilization a 20-30° right lateral rotation aids in better exposure of the ligament of Treitz and vessel dissection. Both the assistant and the surgeon stand on the patient’s right side throughout the procedure.

### 2.2 Port placement

Pneumoperitoneum is created with the Verres needle technique, and the abdomen is insufflated to 15 mm Hg. A 12 mm camera port C is placed halfway between the umbilicus

Source: Medical Robotics, Book edited by Vanja Bozovic, ISBN 978-3-902613-18-9, pp.526, I-Tech Education and Publishing, Vienna, Austria

and the xiphoid. During the laparoscopic dissection a 30° 10-mm telescope is used, which is subsequently replaced with the 0° standard 12-mm robotic laparoscope. Under direct vision two 8 mm robotic trocars (R1, R2) are placed in the midclavicular line approximately 12-14 cm from the symphysis to reach the pelvic floor. The robotic ports themselves need to be at least 10 cm apart from each other in order to avoid collision of the arms. The third robotic port, which is used for retraction, is placed after the robot is docked to find the most suitable position lateral and superior to the anterior superior iliac spine (ASIS). The laparoscopic ports L1 and L2 (5-mm ports) are placed each 10 cm above the other in the midclavicular line. Finally a 10-mm laparoscopic port is inserted just lateral and superior to the ASIS to be used for staplers and the ligasure device.

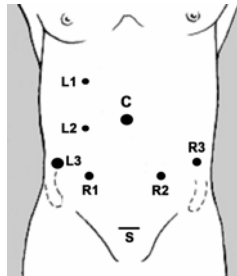


Figure 1. Port site placement

### 2.3 Laparoscopic mobilization of splenic flexure and left colon

During the laparoscopic portion of the operation the surgeon uses R1 and L2, while the assistant holds the camera and uses L1. Both are standing on the patient's right side. We routinely carry out a medial-to-lateral mobilization of the left and sigmoid colon. After inspection of the abdominal cavity for metastatic disease, the inferior mesenteric vein (IMV) is identified and used as initial anatomic landmark. To expose the IMV the ligament of Treitz and the loose attachments between the proximal jejunum and the descending mesocolon may have to be divided sharply so that the small bowel can be retracted towards the right upper quadrant (Fig. 2).

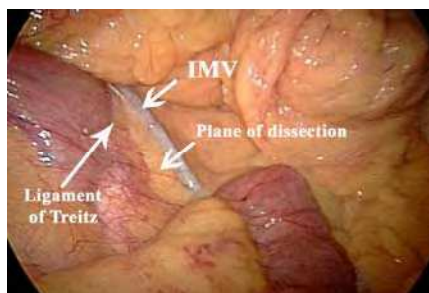


Figure 2. Exposure of the inferior mesenteric vein (IMV)

Next, the peritoneum just under the vein is incised, and the space between mesocolon and Toldt's fascia is developed toward the abdominal wall; ureter and gonadal vessels are identified. In order to avoid traction injuries we recommend early division of the IMV near its insertion posterior to the pancreas where the IMV is azygous, traveling without a paired

artery. More distally, the IMV runs parallel to the upward traveling left colic artery (LCA). Therefore the IMV/left colic artery pedicle should be followed inferiorly and freed from its posterior attachments to the aorta until the origin of the inferior mesenteric artery (oIMA) is encountered (Fig.3)

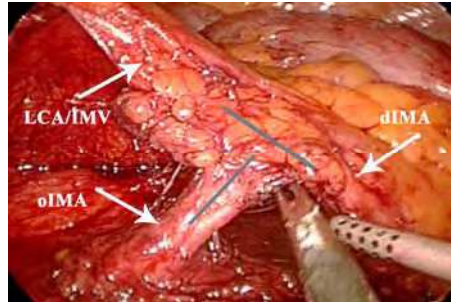


Figure 3. Identification of inferior mesenteric artery

The IMA can now be divided at the origin or distal to the left colic artery depending on the particular case. Division of these vessels can be carried out with an endoscopic linear stapler device or clips inserted through the L3 port. The medial-to-lateral dissection is completed as far laterally as possible, the white line of Toldt is incised and the colon freed from its attachments to the abdominal wall. If necessary the splenic flexure is taken down after the omentum is divided from the transverse colon.

#### 2.4 Robotic Total Mesorectal Excision

A four-arm DaVinci robotic system is used. With the patient remaining in a steep Trendelenburg position, the DaVinci robotic system is brought into the field in between the patient's legs.

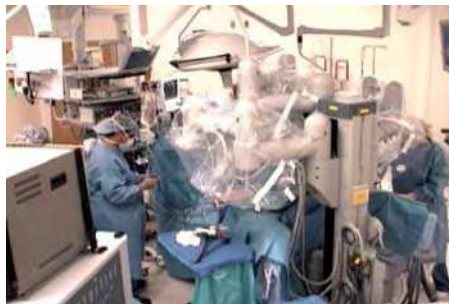

Figure 4. Position of the DaVinci robot

The three arms are docked to ports C, R1 and R2. These are the working arms usually carrying a grasper on the left connected to bipolar cautery and a hook with monopolar cautery on the right. Now the port for the fourth robotic arm is placed laterally and docked. A Cadere grasper is used through this port to help with anterior retraction of the bladder or rectum during part of the dissection. The assistant remains on the right side. He/she uses ports L2 and L3 for suctioning and additional retraction of the sigmoid colon/rectum out of the pelvis. The rectosigmoid mesentery is elevated superiorly and anteriorly. The plane between the fascia propria of the rectum and the presacral fascia is identified and entered (arrow, Fig. 5).

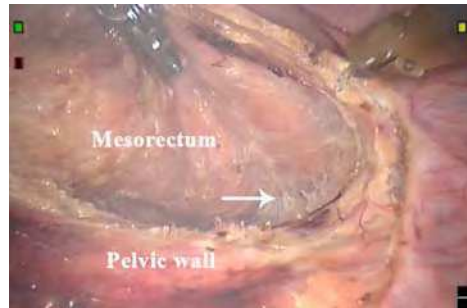


Figure 5. Entering the plane posterior to the mesorectum

This plane consists of fine areolar tissue that can be divided sharply with the electric hook cautery. The ureters on both sides are identified and remain lateral to the dissection. The hypogastric nerve plexus lies posterior to the presacral fascia and should not be injured if the dissection is continued along the correct plane. The dissection continues circumferentially around the rectum. Anteriorly the peritoneal reflection is incised and the anterior dissection is continued along the rectovaginal septum in women or the rectovesical/retroprostatic (Denonvilliers) fascia in men (Fig.6).

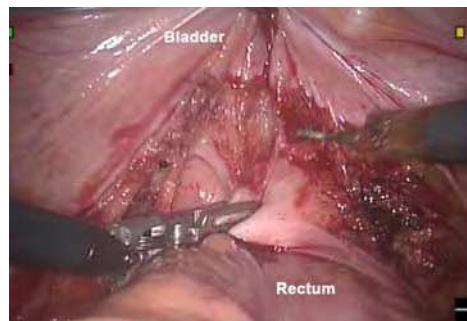


Figure 6. Anterior dissection

This posterior dissection is carried out all the way to the pelvic floor by dividing the retrosacral fascia (Waldeyer's fascia) thus ensuring a total mesorectal excision (Fig.7)

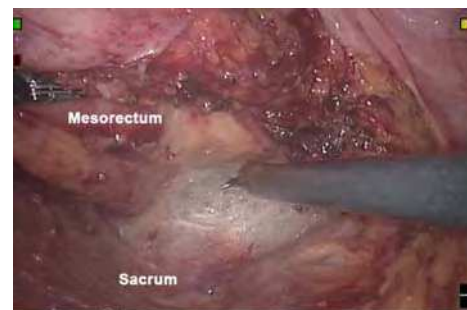


Figure 7. Posterior dissection

At completion of the TME the pelvic floor muscles should be clearly visible. The muscle fibers of the puborectalis sling are divided around the rectum for full mobilization (arrow, Fig. 8).

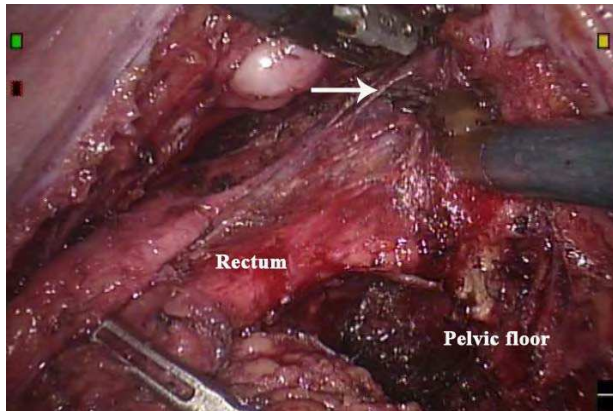


Figure 8. Full mobilization of rectum to pelvic floor

Before dividing the rectum, one member of the team performs a digital rectal exam under direct visualization to assess the distal margin. A margin of at least 1 cm is targeted.

### 2.5 Creation of Anastomosis

The distal rectum is divided by the assistant with multiple loads of a reticulating 30-mm linear stapler (blue load) (Fig. 9).

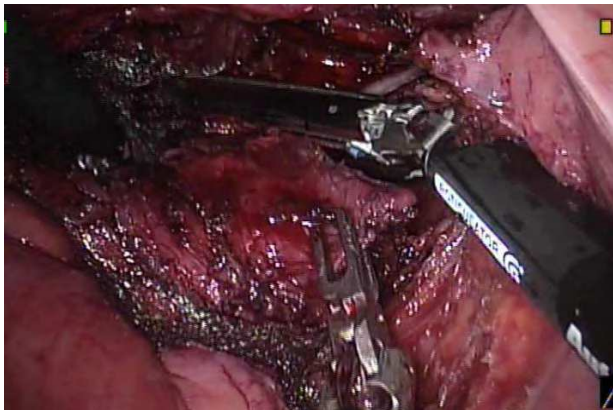


Figure 9. Division of rectum

The specimen is extracted by creating a 4-cm suprapubic mini-laparotomy covered with a plastic wound protector. The proximal bowel is divided and an anvil is introduced into the proximal stump. The bowel is dropped back into the abdomen, the incision closed and the pneumoperitoneum reinsufflated. The anastomosis is now created with a circular stapler under direct laparoscopic visualization. Care is taken to assure that no tension is exerted on the anastomosis (Fig.10).



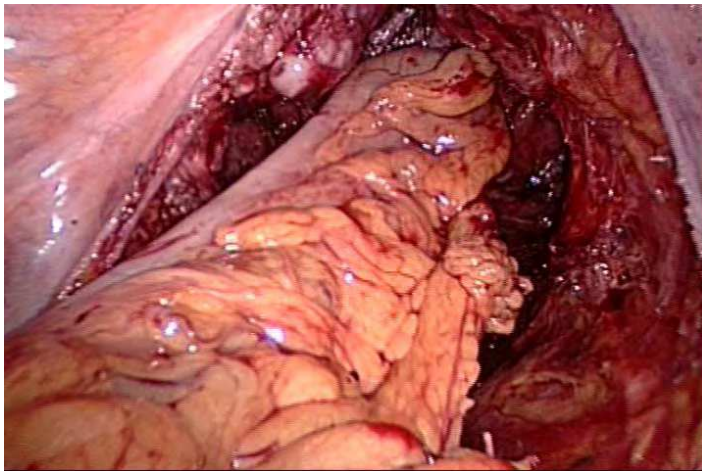


Figure 10. Completed anastomosis

In case of a very low rectal cancer the dissection can be continued along the intersphincteric plane with the robot. The mucosa is then divided from below just above the dentate line, the intersphincteric plane is entered, and the specimen pulled through the anus and divided. A hand-sewn coloanal anastomosis is then created in the standard fashion. We usually perform a diverting ileostomy when the anastomosis is at 5 cm from the anal verge or fewer.

### 2.6 Full robotic approach

Full robotic approaches are described for resection of the lower rectum. Two robotic positions may be used as described by D'Annibale et al (2004). For the left colon and splenic flexure mobilization the robot is positioned beside the patient's left shoulder. The DaVinci system is then moved down between the patient's legs for the rectal dissection. To avoid moving the robotic cart a compromise in the setup is necessary to achieve completion of a left flexure mobilization, TME and rectal resection. In this setting the robotic cart comes from the left thigh of the patient. However due to the limited reach of the robot this setup is only feasible for short and average build patients. The use of the new DaVinci S system may eliminate some of these problems as a larger range of motion will be possible with the robotic arms.

### 3. Results

Since November 2004 a total of 37 patients underwent robotic-assisted laparoscopic rectal resection with total mesorectal excision for primary rectal cancer. The operative and short-term outcomes are listed in Table 1. Low anterior resections were performed in 22 patients, 10 patients had intersphincteric and 5 abdominoperineal resections (APR). There was only one conversion to open surgery in a morbidly obese patient (conversion rate 2.7%). A total of four patients experienced anastomotic leaks (12.5% leak rate). One patient experienced severe hemorrhage during an APR as consequence of the perineal resection. A total mesorectal excision with negative circumferential and distal margins was accomplished in all patients.

<b>Results</b>	
Operative time (min)	285 (180-540)
TME time (min)	60 (35-135)
Estimated blood loss (ml)	200 (25-6000)
# nodes harvested	13 (7-28)
Distal margin (cm)	2.75 (0.2-6.4)
Time to clear liquid diet (days)	2 (1-11)
Length of stay (days)	4 (2-22)

Table 1. Operative and short-term outcomes (median values)

#### 4. Discussion

Major pitfalls of laparoscopic rectal surgery are the technical and anatomic complexity in the narrow pelvis where some maneuvers are difficult to perform with non-articulating instruments. Because of the potential advantages of robotic assistance in the pelvis, we started to assess the utility of the DaVinci system for total mesorectal excisions. We found that telerobotic surgery facilitates several aspects of the pelvic dissection in the confined pelvic space, and that the three-dimensional imaging gives excellent view of the pelvic anatomy.

Early experiences with different robotic-assisted colorectal procedures such as colectomies (Rawlings et al., 2006; D'Annibale et al., 2004), rectopexy (Munz et al., 2004) and anterior resections (D'Annibale et al., 2004, Anvari et al., 2004) are described in recent literature including our previous early report of robotic-assisted TMEs (Pigazzi et al., 2006). These studies found no difference in specimen length, number of lymph nodes retrieved, estimated blood loss, recovery of bowel function or hospital stay between laparoscopic and robotic colorectal resections. Our data showing no positive circumferential or distal margins support these findings. Additionally our leak rate of 12.5% is comparable to a leak rate of 13-19% seen in laparoscopic TME series (Morino et al., 2003; Leroy et al., 2004). Our operative times of 180-540 minutes also compare favorable to reported operative times (88-600 minutes) for laparoscopic rectal surgery (Morino et al., 2003; Leroy et al., 2004; Leung et al., 2004). However, increased operative times due to robotic and operating room set-up have been reported (D'Annibale et al., 2004, Anvari et al., 2004). The low conversion rate of 2.7% and high success rate of TMEs suggest that the advantage of the robot system may translate in better patient outcome.

Nevertheless, there are some drawbacks to current robotic systems. The most significant disadvantage is the inability of the robotic arms to self-adjust around the bed to allow the surgeon to gain access to more than one quadrant of the abdominal cavity at any one time. Another criticism of current robotic systems includes a lack of adequate instruments for bowel surgery such as staplers and suction devices necessitating the use of additional laparoscopic ports.

## 5. Conclusion

In conclusion we can confirm that robotic surgery for rectal cancer is safe and feasible. Rectal cancer surgeons without extensive laparoscopic colorectal experience who wish to transition from open to minimally invasive TME may benefit from this modality. Future studies are necessary to determine the long-term oncologic outcomes of robotic assisted total mesorectal excision.

## 6. References

- Veldkamp, R. ; Gholghesaei, M. ; Bonjer, HR. ; Meijer, DW., Buunen, M. ; Jeekel, J. ; Anderberg, B. ; Cuesta, MA. ; Cuschier, A. ; Fingerhut, A. ; Fleshman, JW. ; Guillou, PJ. ; Haglind, E. ; Himpens, J. ; Jacobi, CA. ; Jakimowicz, JJ. ; Keockerling, F. ; Lacy, AM. ; Lezoche, E. ; Monson, JR. ; Morino, M. ; Neugebauer, E. ; Wexner, SD. & Whelan, RL. (2004). Laparoscopic resection of colon cancer. Consensus of the European Association of Endoscopic Surgery (EAES). *Surg Endosc*, 18, 8, Aug. 2004, 1163-1185, 0930-2794
- D'Annibal, A. ; Morpurgo, E. ; Fiscon, V. ; Trevisan' P. ; Sovernigo, G. ; Orsini, C. & Guidolin, D. (2004). Robotic and laparoscopic surgery for treatment of colorectal diseases. *Dis Colon Rectum*, 47, 12, Dec. 2004, 2162-2168, 0012-3706
- Nelson, H. ; Sargent, DJ. ; Wieand, HS. ; Fleshman, J. ; Anvari, M. ; Stryker, SJ. ; Beart, RW. ; Hellinger, M. ; Flanagan, R. ; Peters, W. & Ota, D. (2004). A comparison of laparoscopically assisted and open colectomy for colon cancer. *N Engl J Med*, 350, 20, 2050-2059, 0028-4793
- Heald, RJ. ; Moran, BJ. ; Ryall, RD. ; Sexton, R. & MacFarlane, JK. (1998). Rectal Cancer : the Basingstoke experience of total mesorectal excision, 1978-1997. *Arch Surg*, 133, 8, Aug. 1998, 894-899, 1591-1063
- Leung, KL. ; Kwok, SP. ; Lam, SC. ; Lee, JF. ; Yiu, RY. ; NG, SS. ; Lai, PB. & Lau WY. (2004). Laparoscopic resection of rectosigmoid carcinoma : prospective randomised trial. *Lancet*, 363, 9416, April 2004, 1187-1192, 0140-6736
- Morino, M. ; Parini, U., Giraudo, G., Salval, M., Contul, RB. & Garrone, C. (2003). Laparoscopic total mesorectal excision: a consecutive series of 100 patients. *Ann Surg*, 237, 3, March 2003, 335-342, 0003-4932
- Leroy, J., Smith, M., Rubino, F., Mutter, D., & Marescaux, J. (2004). Laparoscopic total mesorectal excision (TME) for rectal cancer surgyer: long-term outcomes. *Surg Endosc*, 18, 2, Feb. 2004, 281-289, 0930-2794
- Munz, Y., Moorthy, K., Kudchadkar, R., Hernandez, JD., Martin, S., Darzi, A. & Rockall, T. (2004). Robotic assisted rectopexy. *Am J Surg*, 187, 1, Jan. 2004, 88-92
- Pigazzi, A., Ellenhorn, JD., Ballantyne, GH. & Paz, IB. (2006). Robotic-assisted laparoscopic low anterior resection with total mesorectal excision for rectal cancer. *Surg Endosc* 20, 10, Oct. 2006, 1521-1525, 0930-2794
- Rawlings, AL., Woodland, JH. & Crawford, DL. (2006). Telerobotic surgery for right and sigmoid colectomies: 30 consecutive cases. *Surg Endosc* 20, 11, Nov. 2006, 1713-1718
- Anvari, M., Birch, DW., Bamehriz., F., Gryfe, R. & Chapman T. (2004). Robotic-assisted laparoscopic colorectal surgery. *Laparosc Endosc Percutan Tech* 14, 6, Dec. 2004, 311-315, 1530-4515





## **Medical Robotics**

Edited by Vanja Bozovic

ISBN 978-3-902613-18-9

Hard cover, 526 pages

**Publisher** I-Tech Education and Publishing

**Published online** 01, January, 2008

**Published in print edition** January, 2008

The first generation of surgical robots are already being installed in a number of operating rooms around the world. Robotics is being introduced to medicine because it allows for unprecedented control and precision of surgical instruments in minimally invasive procedures. So far, robots have been used to position an endoscope, perform gallbladder surgery and correct gastroesophageal reflux and heartburn. The ultimate goal of the robotic surgery field is to design a robot that can be used to perform closed-chest, beating-heart surgery. The use of robotics in surgery will expand over the next decades without any doubt. Minimally Invasive Surgery (MIS) is a revolutionary approach in surgery. In MIS, the operation is performed with instruments and viewing equipment inserted into the body through small incisions created by the surgeon, in contrast to open surgery with large incisions. This minimizes surgical trauma and damage to healthy tissue, resulting in shorter patient recovery time. The aim of this book is to provide an overview of the state-of-art, to present new ideas, original results and practical experiences in this expanding area. Nevertheless, many chapters in the book concern advanced research on this growing area. The book provides critical analysis of clinical trials, assessment of the benefits and risks of the application of these technologies. This book is certainly a small sample of the research activity on Medical Robotics going on around the globe as you read it, but it surely covers a good deal of what has been done in the field recently, and as such it works as a valuable source for researchers interested in the involved subjects, whether they are currently “medical roboticists” or not.

### **How to reference**

In order to correctly reference this scholarly work, feel free to copy and paste the following:

Minia Hellan, Joshua Ellenhorn and Alessio Pigazzi (2008). Robotic Rectal Cancer Surgery, Medical Robotics, Vanja Bozovic (Ed.), ISBN: 978-3-902613-18-9, InTech, Available from:

[http://www.intechopen.com/books/medical\\_robotics/robotic\\_rectal\\_cancer\\_surgery](http://www.intechopen.com/books/medical_robotics/robotic_rectal_cancer_surgery)

# **INTECH**

open science | open minds

### **InTech Europe**

University Campus STeP Ri  
Slavka Krautzeka 83/A  
51000 Rijeka, Croatia  
Phone: +385 (51) 770 447

### **InTech China**

Unit 405, Office Block, Hotel Equatorial Shanghai  
No.65, Yan An Road (West), Shanghai, 200040, China  
中国上海市延安西路65号上海国际贵都大饭店办公楼405单元  
Phone: +86-21-62489820

Fax: +385 (51) 686 166  
www.intechopen.com

Fax: +86-21-62489821

© 2008 The Author(s). Licensee IntechOpen. This chapter is distributed under the terms of the [Creative Commons Attribution-NonCommercial-ShareAlike-3.0 License](#), which permits use, distribution and reproduction for non-commercial purposes, provided the original is properly cited and derivative works building on this content are distributed under the same license.