

# ARTERY VEIN CLASSIFICATION OF BLOOD VESSELS IN RETINAL IMAGE: AN AUTOMATED APPROACH

S.Maheswari<sup>1</sup>, S.V. Anandhi<sup>2</sup>

<sup>1</sup>Final Year PG, <sup>2</sup>AP – CSE,

Dr. Sivanthi Aditanar College of Engineering, Tiruchendur, (India)

## ABSTRACT

Artery/Vein (A/V) of retinal vessel is helpful for the automating the detection of various diseases such as Diabetic Retinopathy, high blood pressure, pancreas, and other vascular conditions. An automated approach is presented in this paper for classification of blood vessels into Artery/Vein based on the features extracted from the centerline pixels. The proposed method consists of 4 important phases: 1) Segmentation 2) Centerline Extraction 3) Feature Extraction and 4) Classification. First input image is converted into green channel then retinal vessels are extracted using segmentation process after that centerline of the vessels is extracted using the thinning algorithm. Next step is to extract the features from the centerline pixels and finally vessels are classified using the extracted features. Input images are available on the databases like VICAVR [7], DRIVE[5] and INSPIRE-AVR[6].

**Keywords-Retina, Vessel Segmentation, Centerline, A/V Classification**

## I. INTRODUCTION

Retina is a layer which is present at the back side of the eye ball which plays main role for visualization. Any diseases in retina of the eye lead to severe problems. Retinal vessels segmentation and classification of retinal vessels into arteries and veins is an essential thing for detection of various diseases like Diabetic Retinopathy, high blood pressure, pancreas etc. In [1], author has mentioned the difference between arteries and veins. Blood vessels of retina are divided into 2 types. They are

1. Arteries.
2. Veins.

Blood rich in oxygen is transported by arteries to the various organs of the body. The veins transfer blood low in oxygen level. Arteries are very brighter but Veins are very darker. For identification of various diseases it is more essential to distinguish the vessels into veins and arteries. An abnormal ratio of the size of arteries to veins is one of significant symptom of several diseases like high blood pressure, diabetes retinopathy, pancreas etc. For instance diabetic patients have unusually wide veins, where as patients affected by pancreas have narrowed arteries and high blood pressure patients have thickened arteries. To detect these diseases of the retina, it has to be examined routinely. Blood vessel of retina has to be segmented before classifying the blood vessels into arteries and veins. In general as mentioned in [1], there are four important differences between arteries and veins:

- Veins are darker alternatively arteries are brighter than Veins.
- Arteries are thinner than the nearby veins.

- The central reflex of Arteries is wider but Veins have smaller central reflex.
- Near the optic disk veins and arteries are generally alternate to each other before branching out. Near the optic disk single vein is usually next to 2 arteries.

Automated recognition of retinopathy in eye fundus images using digital image analysis methods has huge potential advantage, allowing the examination of a huge number of images in less time, with lesser cost and reduced subjectivity than current observer-based techniques. Another advantage is the possibility to perform automated screening for pathological conditions, such as diabetic retinopathy, in order to lessen the workload necessary of trained manual graders [12].

Retinal vessels are affected by several diseases, specifically diabetes, vascular disorders and hypertension. Blood vessels show abnormalities at early stages in diabetic retinopathy [13], as well as diameter of vessel alterations [14]. Changes in blood vessels of retina, such as significant dilatation and elongation of main veins, arteries and its branches [14], [15], are also often associated with other cardiovascular pathologies and hypertension.

This paper is organized as follows. In Section II, some of the methods previously presented for retinal vessel classification are briefly reviewed. Section III presents the proposed approach for A/V classification. Finally, Section V summarizes the conclusions.

## II. VARIOUS METHODOLOGIES FOR ARTERY AND VEIN CLASSIFICATION

Artery/Vein classification method proposed in [2] consists of three most important steps. Several Image enrichment techniques are applied in the initial step which is essential and used to improve the images. To divide major arteries from veins specific feature extraction procedure is employed. Feature extraction and vessel classification are not applied to every vessel point instead it is applied to every small vessel segment. At last, the results obtained from the previous step are enhanced by applying the post processing step. Post processing step depends on structural characteristics of the retinal vascular network. Some mistakenly labelled vessels are correctly labelled by means of this step. The vessels are labelled rightly based on the nearby vessel or by means of the other vessels connected to it.

Artery/Vein classification method proposed in [3] is a novel algorithm for classifying the vessels, in which the peculiarity of retinal images is exploited. By applying divide et impera approach a concentric zone in the region of the optic disc are partitioned into quadrants, there by a extra robust local classification analysis can be performed. The results obtained by this method were compared with manual classification provided on a validation set having four hundred and forty three vessels. The overall classification fault reduces from 12 % to 7 % if assessment is based only on the diagnostically significant retinal vessels.

In [1] author has used two feature extraction methods like profile-based and region of interest (ROI) and also used support vector machines and neural networks classification methods to classify retinal vessels into artery/vein.

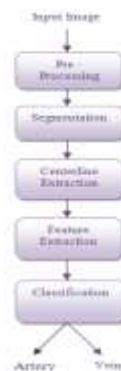Vazquez et al. [10] describes a method which combines vessel tracking method with a color-based clustering algorithm. Initially the clustering approach divides retinal image into 4 quadrants, then it classifies separately the vessels detected in each quadrant, and lastly it combines the results. Then, a strategy based on a minimal path approach is applied to connect the vessel segments located at different radii in order to support the classification by voting.

A piecewise Gaussian model to describe the intensity distribution of vessel profiles has been projected by Li et al. [11]. The central reflex has been considered in this model. A minimum distance classifier based on the Mahalanobis distance was used to differentiate between the vessels types using features derived from the parameters estimated.

### III Proposed Method for Artery Vein Classification

The block diagram of the proposed method for A/V classification is shown in figure 1. The Proposed method consists of 4 important phases:

- 1) Segmentation
- 2) Centerline extraction
- 3) Feature Extraction and
- 4) Classification.

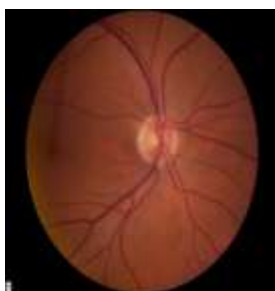

**Figure 1 – Flow of Proposed method**

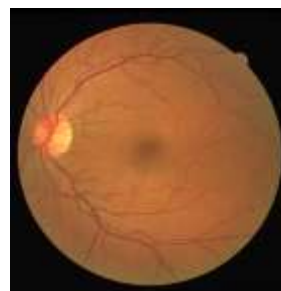First input image is converted into green channel then retinal vessels are extracted using segmentation process after that the centerline of the vessels is extracted using the thinning algorithm. Next step is to extract the features from the centerline pixels and finally vessels are classified using the extracted features

#### 2.1 Input Image

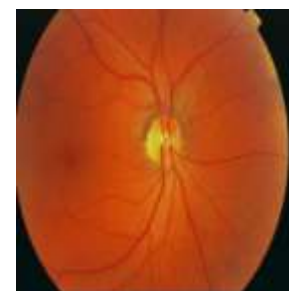Retinal image can be obtained from the publically available databases like VICAVR [7], DRIVE [5] and INSPIRE-AVR [6]. The retinal image is the soft part of the inner eye. The retinal image contains parts like blood vessels, optic disk and fovea. Blood vessels of retina are divided into two types. One is called arteries and another one is called Veins. Main objective is to discriminate those vessels. This discrimination is very help full for the identification of several diseases. Sample images of this dataset are shown in Figure2, Figure 3, and Figure 4.



**Figure 2 –Sample Retinal image of Inspire-AVR [6] Database**



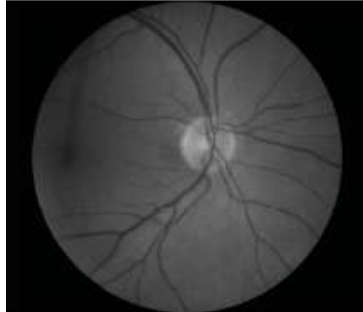
**Figure 3 - Sample Retinal image of Drive [5] Database**



**Figure 4 - Sample Retinal image of Vicar [7] Database**

## 2.2 Converting RGB Image to Green or Red Channel

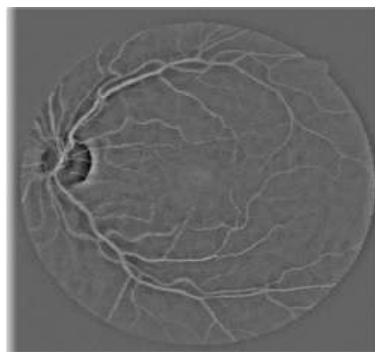
It is more important because arteries and veins are better visible in green or red channel and that's why RGB image should be converted into red or green channel in the first step itself. For few images green channel is suitable while others require red channel



**Figure 5 - Green channel of Retinal Image**

## 2.3 Preprocessing

After converting the image to the green channel, Preprocessing is the first step for the classification of blood vessels into artery/vein where the intensity is normalized by subtracting an estimation of the image background, results by filtering with large arithmetic mean kernel



**Figure 6 - Preprocessed Image**

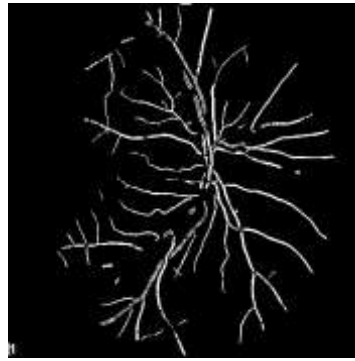
## 2.4 Segmentation

Morphological processing is used for vessel extraction. Closing precedes the opening result which is followed by a comparison, using a minimum operator, to get an image equal to the original one everywhere except for peaks and ridges.

The edges of an image can be found by applying a morphological edge detector named the modified top-hat transformation. Modified top-hat used which involves a closing operator that proceeds by an opening is applied to the original image; the result will be compared to the original image using a minimum operator to attain an image equal to original image except for edges.

The modified top-hat transformations are represented as follows:

$$\text{Top-hat}(I) = I - \min((I \cdot S) \circ S; I)$$



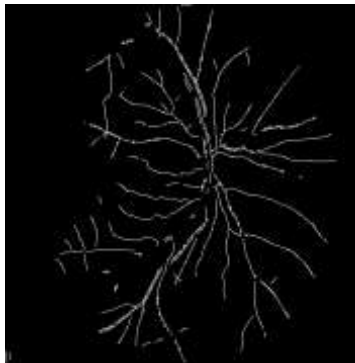
**Figure 7 - Segmented Retinal Vessel**

After that thresholding is applied to get the segmented vessel.

### **2.5 Centreline Extraction**

The centerline image is obtained by applying an thinning algorithm described in [9] to the vessel segmentation result. This algorithm removes border pixels until the object shrinks to a minimally connected stroke. The vessel centerlines from the segmented image of Figure 7 are shown in Figure 8.

It consists of two subiterations: one aimed at deleting the south-east boundary points and the north-west corner points while the other one is aimed at deleting the north-west boundary points and the south-east corner points. End points and pixel connectivity are preserved. Each pattern is thinned down to a "skeleton" of unitary thickness. Experimental results show that this method is very effective.



**Figure 8 - Centerline Extraction**

### **2.6 Feature Extraction**

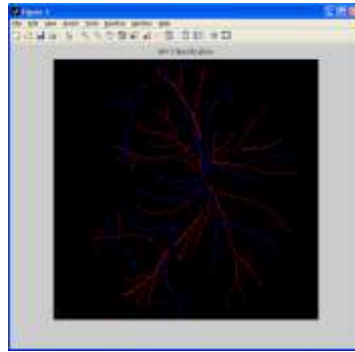
The following features are extracted for each centre line pixel. This features are used by the author [4].Some of these features were used previously in [3], [16].

- ✓ Green, Red and Blue intensities of the centerline pixels.
- ✓ Saturation, Hue and Intensity of the centerline pixels.
- ✓ Mean of Green, Red and Blue intensities in the vessel.
- ✓ Mean of Saturation, Hue, and Intensity in the vessel.
- ✓ Standard deviation of Green, Red and Blue intensities in the vessel.
- ✓ Standard deviation Saturation, Hue and Intensity in the vessel.
- ✓ Maximum and minimum of Green and Red intensities in the vessel.

### **2.6 Classification**

Linear discriminant analysis (LDA), Quadratic discriminant analysis (QDA), and k-nearest neighbor (kNN) can

be used to classify the vessel into artery/Vein. Above all requires training set. Half of the image in the dataset has to be trained.



**Figure 9 - Classified retinal vessel (Red –vein, Blue-artery)**

#### **IV. CONCLUSION**

Retinal vessel classification is very helpful for the detection of various diseases. Based on the intensity features of retinal vessel, classification is performed. This can be further used to calculate the AVR ratio for detection of diseases.

#### **ACKNOWLEDGEMENT**

The authors like to thank authors of, DRIVE [5], INSPIRE-AVR [6] and VICAVR [7] databases for making their retinal image databases publicly available.

#### **REFERENCES**

1. "Blood vessel classification into arteries and veins in retinal images," C Kondermann, Daniel Kondermann and Michelle Yan, Proc. SPIE, February 2007.
2. "Automated characterization of blood vessels as arteries and veins in retinal images," Qazaleh Mirsharifa, Farshad Tajeripoura, Hamidreza Pourreza, Elsevier, 2013.
3. "A divide et impera strategy for automatic classification of retinal vessels into arteries and veins," E. Grisan and A. Ruggeri, IEEE Engineering Med. Biol. Soc., Sep. 2003.
4. "An automatic graph-based approach for artery/vein classification in retinal images," Dashtbozorg B, Mendonca AM, Campilho A, IEEE Transaction, 2014-March.
5. DRIVE - Digital Retinal Images for Vessel Extraction, M. Niemeijer, J. Staal, Bram van Ginneken, M. Loog, and Michael Abramoff, url:<http://www.isi.uu.nl/Research/Databases/DRIVE>, 2004.
6. INSPIRE-AVR - Iowa Normative Set for Processing Images of the RETina-Artery Vein Ratio, M. Niemeijer, X. Xu, A. Dumitrescu, P. Gupta, Bram van Ginneken, J. Folk, and M. Abramoff, url:[http://webeye.ophth.uiowa.edu/misc/index.php?option=com\\_breezingforms&view=form&Itemid=537](http://webeye.ophth.uiowa.edu/misc/index.php?option=com_breezingforms&view=form&Itemid=537), 2011.
7. VICAVR: VARPA Images for the Computation of the Arterio/Venular Ratio, ,url: <http://www.varpa.es/vicavr.html>, 2010
8. C. Kondermann, D. Kondermann, and M. Yan, "Blood vessel classification into arteries and veins in retinal images," February 2007.
9. "A Fast Parallel Algorithm for Thinning Digital Patterns" T. Y. ZHANG and C. Y. SUEN. March 1984.
10. "On the automatic computation of the arterio-venous ratio in retinal images: Using minimal paths for the

- artery/vein classification,” S. Vazquez, B. Cancela, N. Barreira, M. Penedo, and M. Saez, 2010.
11. “A piecewise Gaussian model for profiling and differentiating retinal vessels,” H. Li, W. Hsu, M. Lee, and H. Wang, September 2003.
  12. “Retinal image analysis: Concepts, applications and potential,” N. Patton, T. M. Aslam, T. MacGillivray, I. J. Deary, B. Dhillon, R. H. Eikelboom, K. Yogesa, and I. J. Constable, January 2006.
  13. “Retinal vascular changes and diabetic retinopathy,” T. T. Nguyen and T. Y. Wong, August 2009.
  14. “Retinal hemodynamics in early diabetic macular edema,” K. Guan, C. Hudson, T. Wong, M. Kisilevsky, R. K. Nrusimhadavara, W. C. Lam, M. Mandelcorn, R. G. Devenyi, and J. G. Flanagan, March 2006.
  15. “Retinal vessel analysis reproducibility in assessing cardiovascular disease,” A. S. Neubauer, M. Ludtke, C. Haritoglou, S. Priglinger, and A. Kampik, Apr. 2008.
  16. “Automated measurement of the arteriolar-to-venular width ratio in digital color fundus photographs,” M. Niemeijer, X. Xu, A. Dumitrescu, P. Gupta, M. A. B. van Ginneken, and J. Folk, *IEEE Transaction Medical Imag*, November 2011.

## AUTHORS

**S. Maheswari** received her B.E (CSE) in 2009 from Arulmigu Kalasalingam College of engineering and pursuing M.E (CSE) in Dr. Sivanthi Aditanar College of Engineering, Tiruchendur. Her area of interest is Image Processing and she is also an active student member of CSI.

**S.V.Anandhi** received her B.E (CSE) in 2006 and M.E (CSE) in 2010. Her area of interest is in Image Processing.