

Influence of the Interposition of a Nonhollow Probe during Cannula Extraction on Sclerotomy Vitreous Incarceration in Sutureless Vitrectomy

Javier Benitez-Herreros,¹ Lorenzo Lopez-Guajardo,¹ Cristina Camara-Gonzalez,¹ and Agustin Silva-Mato²

PURPOSE. To evaluate the effect of the cannula removal technique on postoperative vitreous incarceration using an experimental model of vitrectomized eye.

METHODS. In a prospective, experimental, randomized, and observer-masked study, 118 cadaveric pig eyes were vitrectomized through 23-gauge transconjunctival sclerotomies. Once vitrectomy was finished, one of the superior cannulas was extracted with the illumination probe inserted through it, and the other cannula was removed with a cannula plug inserted. Postoperative incisional vitreous entrapment was evaluated by direct visualization. No vitreous incarceration was classified as grade 0 (G0), thin vitreous entrapment was classified as grade 1 (G1), and thick vitreous strands as grade 2 (G2).

RESULTS. Considering the sclerotomies whose cannulas were extracted with the light probe inside, vitreous incarceration was detected in 93.2% (73.7% G1, 19.5% G2) of the incisions. In turn, vitreous entrapment was observed in 95.8% (43.2% G1, 52.6% G2) of the entry sites whose cannulas were extracted with the plug inserted. Statistical analysis showed significant differences when comparing postvitrectomy vitreous incarceration grades in sclerotomies according to the cannula extraction technique ($P < 0.0001$).

CONCLUSIONS. Interposing the light probe through the cannula during its removal reduces vitreous incarceration grade in our experimental model. This simple maneuver may decrease complications related to vitreous entrapment, such as peripheral retinal tears and acute endophthalmitis. (*Invest Ophthalmol Vis Sci.* 2012;53:7322–7326) DOI:10.1167/iov.12-10274

Pars plana vitrectomy was first developed by Machemer et al. in 1972.¹ Many advances have since been developed in vitrectomy technique and instrumentation. In recent years, 23- and 25-gauge transconjunctival sutureless vitrectomy (TSV) has progressively been adopted as the first-choice vitrectomy

technique for an increasing number of surgeons.^{2,3} Since the implantation of the TSV, numerous studies have analyzed different aspects of the sclerotomies such as the presence of incisional vitreous incarceration.^{4–11} This vitreous entrapment may work as an incisional plug, favoring postoperative sclerotomy closure; however, it has been also related to some postoperative complications, such as peripheral retinal tears as a result of postoperative vitreous contraction,^{12–14} acute endophthalmitis due to the presence of incisional vitreous wick that may facilitate the entry of bacteria into the vitreous cavity,¹⁵ and fibrovascular proliferation that is considered a major risk factor for recurring vitreous hemorrhage in diabetic patients.¹⁶ Previously, some authors have described different maneuvers aimed to reduce this postoperative vitreous incarceration.^{17,18} Moreover, it has been suggested that interposing a nonhollow element through the cannula when it is extracted may reduce vitreous entrapment.¹⁹ In our study, we analyzed the influence that this cannula extraction technique may exert on postoperative sclerotomy vitreous entrapment. We used direct visualization as the evaluation method, given that it is superior to other indirect viewing techniques, such as ultrasound biomicroscopy (UBM) or anterior segment optical coherence tomography (AS-OCT), in the detection of vitreous entrapment.¹⁹

METHODS

This prospective, experimental, randomized, and observed-masked study included 118 pig eyes (*Sus scrofa domesticus* species). Exclusion criteria were presence of corneal or crystalline lens opacity, conjunctival or scleral alterations, and intraoperative complications. All globes were obtained 3 hours after pigs were killed, and were kept in cold storage at 4°C prior to use, with the aim of preserving the properties of all ocular tissues, including the vitreous gel.²⁰ As the eyes were obtained from pigs killed for human consumption from a regulated slaughter house, no statements for the use of animals in ophthalmic research were applicable.

The 23-gauge sclerotomies (23-gauge TSV system; Alcon Laboratories, Fort Worth, TX) were performed using an oblique incisional technique 4 mm from the limbus.²¹ The first step in this technique was to laterally displace the conjunctiva with the aid of forceps; after that, the globe was penetrated tangentially with the trocar-cannula at an angle of approximately 30 degrees, parallel to the corneal limbus, all the way of the beveled trocar up to the beginning of the cannula; finally, the penetrating direction was modified to a perpendicular orientation (pointing to the center of the globe) for the rest of the trocar up to the collar of the microcannula. One of the authors (L.L.-G.) performed complete vitrectomy (Fig. 1) with the infusion pressure set at 40 mm Hg, until the vitreous cavity was judged optically empty, using the Accurus vitreotome (Alcon Laboratories). This study was not designed to determine if different infusion pressures used to perform

From the ¹Department of Ophthalmology, University Hospital Principe de Asturias, Alcalá de Henares, Madrid, Spain; and the ²Department of Health and Sociomedical Sciences, Biostatistics Unit, Faculty of Medicine, Alcalá University, Madrid, Spain.

Submitted for publication May 27, 2012; revised August 24, 2012; accepted September 26, 2012.

Disclosure: **J. Benitez-Herreros**, None; **L. Lopez-Guajardo**, None; **C. Camara-Gonzalez**, None; **A. Silva-Mato**, None

Corresponding author: Lorenzo Lopez-Guajardo, Department of Ophthalmology, University Hospital Principe de Asturias, Carretera Alcalá-Meco s/n 28805 Alcalá de Henares, Madrid, Spain; llguajardo@icam.es.

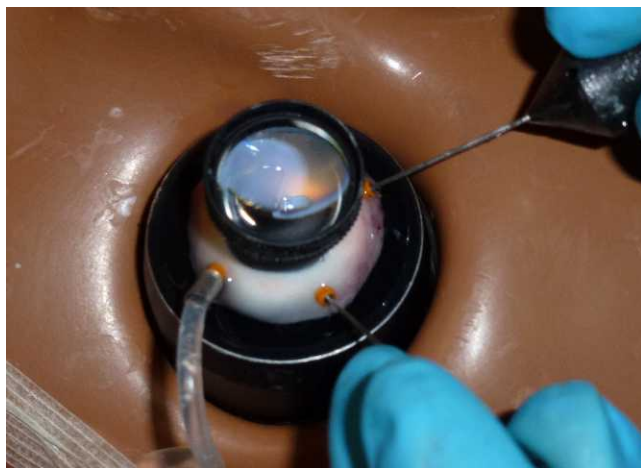

FIGURE 1. A 23-gauge vitrectomy performed in cadaveric pig eyes. Vitreous cutter and illumination probe are introduced through superior cannulas, placed 4 mm from the limbus.

vitrectomy have any influence on the degree of incisional vitreous incarceration, so a fixed pressure value was used. The pressure value was determined as that appropriate for performing vitrectomy in the pig eye. Vitrectomy was also performed inside both superior cannulas, and all around the vitreous cavity next to the inner tip of the cannula; we also reached each perisclerotomy area by inserting the vitreotome probe through the opposite superior cannula. After checking that balanced salt solution (BSS) flowed freely through both superior cannulas, the infusion line was clamped and 1 mL of triamcinolone acetonide 40 mg/mL (TrigonDepot, Bristol-Myers Squibb Company, Princeton, NJ) was slowly injected through the cannula used by the vitreous cutter, with the aim of staining intraocular residual vitreous. The infusion line was opened and all the free triamcinolone that was not adhered to residual vitreous was exchanged for BSS.

After that, infusion pressure was lowered to 5 mm Hg and the superior cannulas were extracted following their oblique incisional pathways. In 59 randomly chosen eyes, the cannula used by the vitreous cutter during the vitrectomy was removed with the light pipe introduced through it (Fig. 2), and the cannula used by the illumination probe was taken out with the cannula plug inserted. In the other 59 eyes, the cannula used by the illumination probe during the vitrectomy

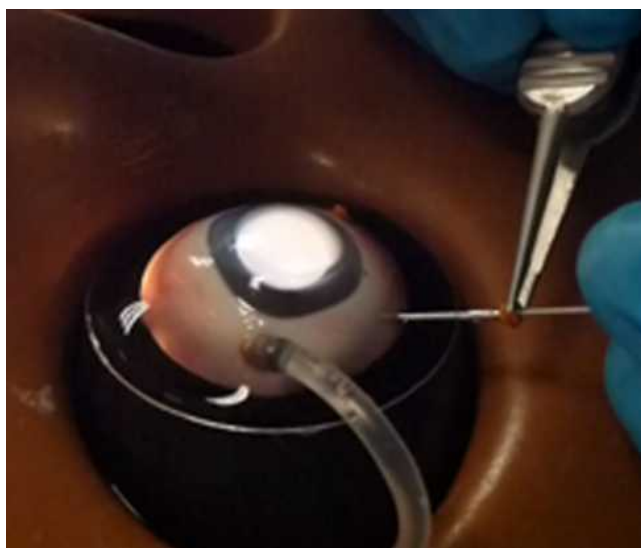

FIGURE 2. Superior cannula removed over the light probe.



FIGURE 3. Slit-lamp photograph. Absence of vitreous strands in sclerotomy was defined as vitreous incarceration grade 0.

was removed with the light pipe introduced, and the one used by the vitreous cutter was extracted with the cannula plug inserted. In this way, we avoided the possible effect that the different manipulations exerted on the sclerotomies by the vitreous cutter or the illumination probe could have on postoperative vitreous incarceration. Finally, intraocular pressure was raised to 10 mm Hg (to slightly “harden” the eye), the infusion line was clamped, and the infusion cannula was taken out with the clamped infusion line inserted.

Eyes were cut and divided in two portions through the posterior third coronal plane of the globe. We first performed a penetrating incision parallel to the limbus with a scalpel, and then we completed the cut 360° around the globe with Wescott scissors. Finally, slit-lamp photographs of the internal side of the sclerotomies were taken.

The image sequences obtained were reviewed, and one snapshot from each sclerotomy was selected for presentation in a masked fashion to one of the authors (J.B.-H.) who classified the sclerotomies according to the grade of vitreous incarceration in the wound, in a similar manner to that previously described.¹⁷ Grade 0 (*G0*) was defined as absence of vitreous incarceration at the sclerotomy site (Fig. 3), grade 1 (*G1*) was considered as the presence of delicate vitreous strands directed to the inner hole of the incision (Fig. 4), and grade 2

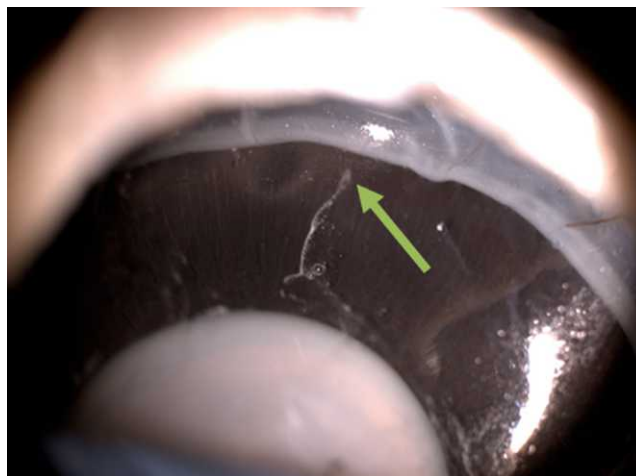

FIGURE 4. Slit-lamp photograph. Presence of delicate vitreous strands into the inner hole of the sclerotomy (arrow) was considered vitreous incarceration grade 1. Triamcinolone acetonide, which stained the intraocular residual vitreous, allowed us to visualize the incisional vitreous strands clearly.

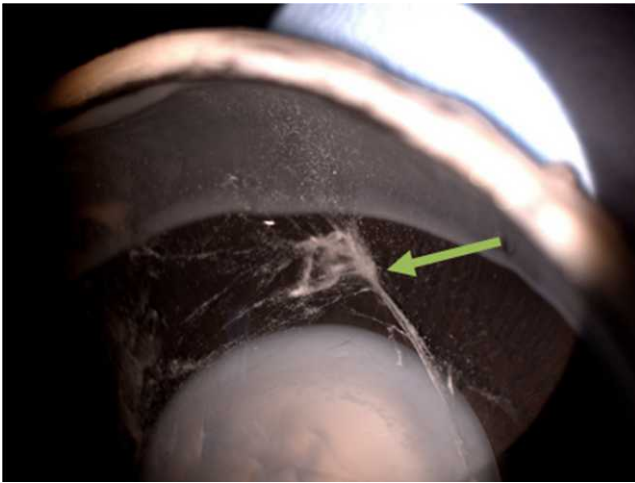


FIGURE 5. Slit-lamp photograph. Presence of thick vitreous strands into the sclerotomy (arrow) was classified as vitreous incarceration grade 2. Triamcinolone acetonide allowed us to visualize the incisional vitreous strands clearly.

(G2) was classified as the existence of thick vitreous strands aimed toward the sclerotomy (Fig. 5). The injection of triamcinolone acetonide, which stained the intraocular residual vitreous, allowed us to visualize the incisional vitreous strands clearly.

Statistics

For all statistical tests, $P < 0.05$ was considered the significance level.

To compare the effect of the different elements (light pipe/cannula plug) inserted through the cannula during its extraction on the presence or absence of vitreous incarceration, without considering the amount of incisional vitreous in grades (G0 versus G1+G2), we used Fisher's exact test. In turn, to compare the vitreous entrapment grade (G0, G1, or G2), according to the element inserted through the cannula during its removal, we used the Mann-Whitney U test. Statistical analysis was performed using Statview+Graphics™ (Abacus Concept, Inc., Cupertino, CA).

RESULTS

Vitrectomies were performed without any incidents. Post mortem vitreous was clear in all globes, and core and cortical vitreous were removed easily. Most eyes did not present posterior vitreous detachment; however, for studying vitreous incarceration in anterior sclerotomies, we did not need to extract posterior hyaloid but just enough core and anterior vitreous to allow BSS to flow freely through the cannulas after removing the instruments. No intraoperative complications, such as retinal breaks or retinal detachments, were detected in any case.

Considering the 118 sclerotomies with cannulas extracted with the light probe inside, 8 had no signs of vitreous entrapment (G0; 6.8%), 87 had minimal vitreous strands incarcerated (G1; 73.7%), and 23 had thick vitreous strands entrapped (G2; 19.5%). In turn, taking into account the 118 sclerotomies whose cannulas were removed with the plug inserted, 5 had no signs of vitreous incarceration (G0; 4.2%), 51 presented minimal vitreous entrapment (G1; 43.2%), and 62 presented important vitreous incarceration (G2; 52.6%) (Fig. 6).

When the presence of incisional vitreous incarceration was analyzed, without considering the amount of vitreous entrapment in grades (G0 versus G1+G2), we did not find significant

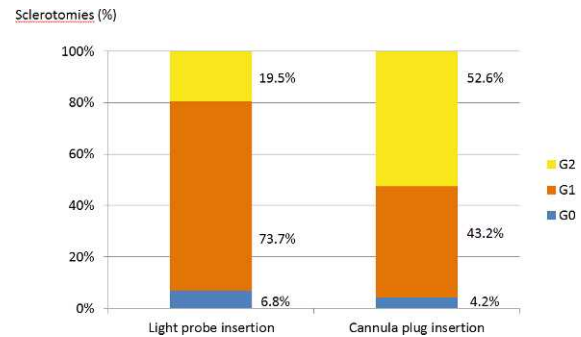


FIGURE 6. Proportion of vitreous incarceration grades (G0, G1, G2) in sclerotomies, according to the cannula removal technique performed (light probe or cannula plug insertion).

differences in the vitreous entrapment rates observed with the two different elements inserted through the cannula (light pipe or cannula plug) during its extraction ($P = 0.768$; Fisher's exact test). However, when we compared the vitreous incarceration grade observed in the superior sclerotomy sites (G0, G1, or G2), we found significantly less G2 vitreous entrapment in the incisions whose cannulas were extracted with the light probe inserted ($P < 0.0001$; Mann-Whitney U test).

DISCUSSION

In recent years, authors have described different maneuvers to reduce the sclerotomy vitreous entrapment rate after vitrectomy. Sabti et al.¹⁷ studied by UBM the effect of performing complete vitreous shaving around the sclerotomy sites under scleral depression, and found that it diminished significantly the incisional vitreous incarceration rate. Later, Chalam et al.¹⁸ described the use of a curved vitrectomy probe, which facilitated extraction of the vitreous around the inner sclerotomy hole and, thus, could reduce the incisional vitreous entrapment rate. Recently, it has been suggested that introducing a nonhollow element through the cannula during its extraction, such as the light probe, may reduce the incisional vitreous entrapment after vitrectomy.¹⁹ However, no studies up to now have demonstrated the effect of this maneuver on the postoperative vitreous incarceration rate detected with direct visualization. This visualization technique might be more sensitive than indirect viewing methods, such as UBM and As-OCT,¹⁹ which may be attenuated by semitransparent media such as the sclera or the pigment epithelium layer.²² Our invasive procedure can be performed only in human cadaveric or animal experimental models. In that sense, it is difficult to obtain human cadaveric eyes as close to the death moment as those coming from animals. Increasing the time gap between death and surgery may alter the dynamic properties of the vitreous tissue, making results less reliable.

Our results suggest that inserting the light pipe into the cannula during its removal reduces significantly the amount (grade) of the postoperative vitreous incarcerated as compared with those sclerotomies in which cannulas were taken out with the plug inserted. This difference may be due to the displacement effect of the vitreous placed inside the cannula by the light pipe insertion. When the cannulas were taken out with the plug inserted, the vitreous situated inside the cannulas was not pushed toward the vitreous cavity, but rather was displaced to the inner face of the sclerotomies, leading to a greater amount (grade) of vitreous incarceration.

When we analyzed the vitreous entrapment rate without distinguishing the amount of vitreous incarceration in grades

(G0 versus G1+G2), we did not find differences between the cannula removal treatments. In fact, we found vitreous strands in practically all the sclerotomies analyzed (93.2% and 95.8%, depending on the incisional subgroup evaluated), as had been previously described by other studies that used an endoscopic video probe¹⁰ or an external video camera system (Miyake-Apple exploration).¹¹ Therefore, regardless of the element inserted through the cannula during its extraction, and in spite of performing intense vitreous shaving around the incision sites during the operation, it was not possible to leave the perisclerotomy region free of vitreous in almost any sclerotomy after the vitrectomy. This high rate of vitreous incarceration may be caused by the inserted cannulas, which protrude 2 to 3 mm into the vitreous cavity, possibly impeding complete clearing of the vitreous that surrounds the cannula.¹⁰ When the cannulas are taken out, this pericannular residual vitreous may be displaced to the inner side of the sclerotomy, favoring vitreous entrapment. Therefore, pulling out the cannula over the fiber light may favor the displacement of the vitreous placed inside the cannula, reducing the amount (grade) of vitreous incarceration but not the total incarceration rate.

The fact that more than 90% of the sclerotomy sites had vitreous incarceration in our study, while it is expected that less than 3% of vitrectomized eyes will develop retinal detachment,²³ means that not all vitreous incarceration might result in retinal break formation and subsequent retinal detachment. Of 23 TSV procedures, 8% developed entry-site retinal breaks (within 1 clock hour of an entry site)¹³ and in 177 consecutive TSVs, 40% of detected breaks were sclerotomy related.¹⁴ These data could justify a role of entrapped vitreous in sclerotomy sites as a possible pathogenic mechanism of retinal break formation. Trying to diminish vitreous sclerotomy incarceration could well reduce the postvitrectomy retinal detachment rate.

Because porcine vitreous composition²⁴ and porcine scleral thickness²⁵⁻²⁷ differ slightly from human eyes, absolute incarceration rates obtained here should not be considered the main conclusion of our study. Nevertheless, our results are similar to those observed in human research.^{10,11} The important outcome of our study is the relative difference in vitreous entrapment grade detected in sclerotomies whose cannulas were extracted with the light pipe or the plug inserted.

In conclusion, to diminish the risk of suffering complications related to vitreous incarceration, we propose to insert a nonhollow element through the cannula during its extraction (interposing maneuver), such as the light pipe, given that this procedure may allow us to empty the cannula of residual vitreous. This technique has been used previously by other authors^{4,28}; however, none of them had analyzed its influence on postoperative vitreous incarceration. It is almost impossible to clear all perisclerotomy vitreous by the vitrectomy and, thus, practically all entry sites present vitreous incarceration after vitrectomy. However, this does not diminish the value of the interposing maneuver, which at least allows us to reduce the amount of this vitreous entrapment significantly.

Our animal model may become the basis for future studies to analyze the influence that other modifiable factors may exert on incisional vitreous incarceration after vitrectomy, such as the length and angle of the scleral tunnels, the shape of the sclerotomies (lineal or V-“shaped” incisions), the presence of gas tamponade inside the vitreous cavity, and the intraocular pressure value during the cannula extraction.

Acknowledgments

Tim Corson, PhD, from the IOVS Volunteer Editor Program, has reviewed the manuscript.

References

1. Machemer R, Parel JM, Norton EW. Vitrectomy: a pars plana approach. Technical improvements and further results. *Trans Am Acad Ophthalmol Otolaryngol.* 1972;76:462-466.
2. Fujii GY, De Juan E Jr, Humayun MS, et al. A new 25-gauge instrument system for transconjunctival sutureless vitrectomy surgery. *Ophthalmology.* 2002;109:1807-1812.
3. Eckardt C. Transconjunctival sutureless 23-gauge vitrectomy. *Retina.* 2005;25:208-211.
4. Chen D, Lian Y, Cui L, Lu F, Ke Z, Song Z. Sutureless vitrectomy incision architecture in the immediate postoperative period evaluated in vivo using optical coherence tomography. *Ophthalmology.* 2010;117:2003-2009.
5. López-Guajardo L, Vleming-Pinilla E, Pareja-Esteban J, Teus-Guezala MA. Ultrasound biomicroscopy study of direct and oblique 25-gauge vitrectomy sclerotomies. *Am J Ophthalmol.* 2007;143:881-883.
6. Zhengyu S, Fang W, Ying F, Qinghua Q. The experimental research of rabbit's sclerotomy sites undergoing transconjunctival sutureless vitrectomy. *Curr Eye Res.* 2007;32:647-652.
7. Gutfleisch M, Dietzel M, Heimes B, Spital G, Pauleikhoff D, Lommatzsch A. Ultrasound biomicroscopic findings of conventional and sutureless sclerotomy sites after 20-, 23-, and 25-G pars plana vitrectomy. *Eye (Lond).* 2010;24:1268-1272.
8. Avitabile T, Castiglione F, Bonfiglio V, Castiglione F. Transconjunctival sutureless 25-gauge versus 20-gauge standard vitrectomy: correlation between corneal topography and ultrasound biomicroscopy measurements of sclerotomy sites. *Cornea.* 2010;29:19-25.
9. Ahmadabadi MN, Azaripour E, Movassat M, et al. Ultrasound biomicroscopy of conventional and sutureless (23, 25-gauge) sclerotomy sites after pars plana vitrectomy. *Iran J Ophthalmol.* 2010;22:17-22.
10. Nagpal M, Wartikar S, Nagpal K. Comparison of clinical outcomes and wound dynamics of sclerotomy ports of 20, 25, and 23 gauge vitrectomy. *Retina.* 2009;29:225-231.
11. Inoue M, Ota I, Taniuchi S, Nagamoto T, Miyake K, Hirakata A. Miyake-Apple view of inner side of sclerotomy during microincision vitrectomy surgery. *Acta Ophthalmol.* 2011;89:412-416.
12. Buettner H, Machemer R. Histopathologic findings in human eyes after pars plana vitrectomy and lensectomy. *Arch Ophthalmol.* 1977;95:2029-2033.
13. Gosse E, Newsom R, Lochhead J. The incidence and distribution of iatrogenic retinal tears in 20-gauge and 23-gauge vitrectomy. *Eye.* 2012;26:140-143.
14. Tan HS, Mura M, de Smet MD. Iatrogenic retinal breaks in 25-gauge macular surgery. *Am J Ophthalmol.* 2009;148:427-430.
15. Chen SD, Mohammed Q, Bowling B, Patel CK. Vitreous wick syndrome—a potential cause of endophthalmitis after intravitreal injection of triamcinolone through the pars plana. *Am J Ophthalmol.* 2004;137:1159-1160; author reply 1160-1161.
16. Hotta K, Hirakata A, Ohi Y, et al. Ultrasound biomicroscopy for examination of the sclerotomy site in eyes with proliferative diabetic retinopathy after vitrectomy. *Retina.* 2000;20:52-58.
17. Sabti K, Kapusta M, Mansour M, Overbury O, Chow D. Ultrasound biomicroscopy of sclerotomy sites: the effect of vitreous shaving around sclerotomy sites during pars plana vitrectomy. *Retina.* 2001;21:464-468.
18. Chalam KV, Shah GY, Agarwal S, Gupta SK. Illuminated curved 25-gauge vitrectomy probe for removal of subsclerotomy vitreous in vitreoretinal surgery. *Indian J Ophthalmol.* 2008;56:331-334.
19. López-Guajardo L, Benítez-Herreros J. Vitreous incarceration in sclerotomies. *Ophthalmology.* 2012;119:204-205.

20. Mihailovic Z, Atanasijevic T, Popovic V, Milosevic MB. Could lactates in vitreous humour be used to estimate the time since death. *Med Sci Law*. 2011;51:156-160.
21. López-Guajardo L, Pareja-Esteban J, Teus-Guezala MA. Oblique sclerotomy technique for prevention of incompetent wound closure in transconjunctival 25-gauge vitrectomy. *Am J Ophthalmol*. 2006;141:1154-1156.
22. Pavlin CJ, Vásquez LM, Lee R, Simpson ER, Ahmed II. Anterior segment optical coherence tomography and ultrasound biomicroscopy in the imaging of anterior segment tumors. *Am J Ophthalmol*. 2009;147:214-219.
23. Covert DJ, Henry CR, Bhatia SK, Croskrey J, Sanchez CR, Han DP. Intraoperative retinal tear formation and postoperative rhegmatogenous retinal detachment in transconjunctival cannulated vitrectomy systems compared with the standard 20-gauge system. *Arch Ophthalmol*. 2012;130:186-189.
24. Lee B, Litt M, Buchsbaum G. Rheology of the vitreous body: part 3. Concentration of electrolytes, collagen and hyaluronic acid. *Biorheology*. 1994;31:339-351.
25. Olsen TW, Sanderson S, Feng X, Hubbard WC. Porcine sclera: thickness and surface area. *Invest Ophthalmol Vis Sci*. 2002;43:2529-2532.
26. Olsen TW, Aaberg SY, Geroski DH, Edelhauser HF. Human sclera: thickness and surface area. *Am J Ophthalmol*. 1998;125:237-241.
27. Nicoli S, Ferrari G, Quarta M, et al. Porcine sclera as a model of human sclera for in vitro transport experiments: histology, SEM, and comparative permeability. *Mol Vis*. 2009;15:259-266.
28. Taban M, Sharma S, Ventura AA, Kaiser PK. Evaluation of wound closure in oblique 23-gauge sutureless sclerotomies with visante optical coherence tomography. *Am J Ophthalmol*. 2009;147:101-107.