

Bedside Sonographic Measurement of Optic Nerve Sheath Diameter as a Predictor of Increased Intracranial Pressure in Children

Audrey Le, MD

Mary Ellen Hoehn, MD

Mary E. Smith, MPH, RDMS

Thomas Spentzas, MD

David Schlappy, BS

Jay Pershad, MD

From the Departments of Pediatrics (Le, Spentzas, Schlappy, Pershad) and Ophthalmology (Hoehn, Smith), University of Tennessee Health Sciences Center, Le Bonheur Children's Medical Center, Memphis, TN.

Study objective: We investigate the test performance of emergency physician-performed sonographic measurement of optic nerve sheath diameter for diagnosis of increased intracranial pressure.

Methods: Children between the ages of 0 and 18 years with suspected increased intracranial pressure were prospectively recruited from the emergency department and ICU of an urban, tertiary-level, freestanding pediatric facility. Pediatric emergency physicians with goal-directed training in ophthalmic sonography measured optic nerve sheath diameter. Images were recorded and subsequently reviewed by a pediatric ophthalmologist and an ophthalmic sonographer, both of whom were blind to the patient's clinical condition. Measurements obtained by the ophthalmic sonographer were considered the criterion standard. An optic nerve sheath diameter greater than 4.0 mm in subjects younger than 1 year and greater than 4.5 mm in older children was considered abnormal. The diagnosis of increased intracranial pressure was based on results of cranial imaging or direct measurement of intracranial pressure.

Results: Sixty-four patients were recruited, of whom 24 (37%) had a confirmed diagnosis of increased intracranial pressure. The sensitivity of optic nerve sheath diameter as a screening test for increased intracranial pressure was 83% (95% confidence interval [CI] 0.60 to 0.94); specificity was 38% (95% CI 0.23 to 0.54); positive likelihood ratio was 1.32 (95% CI 0.97 to 1.79) and negative likelihood ratio was 0.46 (95% CI 0.18 to 1.23). There was fair to good interobserver agreement between the pediatric emergency physician and ophthalmic sonographer (κ 0.52) and pediatric ophthalmologist (κ 0.64).

Conclusion: The sensitivity and specificity of bedside sonographic measurement of optic nerve sheath diameter is inadequate to aid medical decisionmaking in children with suspected increased intracranial pressure. Pediatric emergency physicians with focused training by a pediatric ophthalmologist familiar with ophthalmic sonography can measure optic nerve sheath diameter accurately. [Ann Emerg Med. 2009;53:785-791.]

Provide [feedback](#) on this article at the journal's Web site, www.annemergmed.com.

0196-0644/\$-see front matter

Copyright © 2008 by the American College of Emergency Physicians.

doi:10.1016/j.annemergmed.2008.11.025

INTRODUCTION

Acute increases in intracranial pressure can be difficult to diagnose in pediatric patients because the signs and symptoms are often nonspecific. Although funduscopic examination is helpful, its accuracy in the acute setting is limited and visualization of the optic discs can be difficult in the young child. Confirmation of increased intracranial pressure requires direct measurement of intracranial pressure, which is invasive and not always feasible in the emergency department (ED). Cranial computed tomography (CT) and magnetic resonance

imaging are surrogate tests to diagnose increased intracranial pressure. In a busy ED, neuroimaging may involve delays in patient care, need for sedation, additional costs, or exposure to ionizing radiation. Bedside ophthalmic ultrasonography offers several advantages. It is portable, rapid, low cost, noninvasive, and widely available, and it does not involve exposure to ionizing radiation.

Increased intracranial pressure forces the inflow of cerebrospinal fluid into the perineural space between the dura and the optic nerve, leading to the development of

Editor's Capsule Summary*What is already known on this topic*

Increased intracranial pressure can cause papilledema, and edema of the optic nerve can be measured sonographically.

What question this study addressed

Can emergency physician–performed ultrasonography of the optic nerve identify increased intracranial pressure in children?

What this study adds to our knowledge

Sixty-four children with suspected increase of intracranial pressure had optic sonography by a pediatric emergency physician, and the results showed limited accuracy (83% sensitivity, 38% specificity) in predicting increased intracranial pressure relative to a criterion standard of cranial imaging or intracranial pressure monitoring.

How this might change clinical practice

This will not change practice and suggests that a promising technique for the noninvasive evaluation of intracranial pressure is not sufficiently reliable for clinical use.

papilledema on fundoscopic examination and to the sonographic appearance of increased diameter of the nerve. Postmortem studies have shown that the optic nerve sheath diameter is sensitive to changes in intracranial pressure, and that the sheath starts to become “normally” distensible 3 mm posterior to the globe.^{1,2} Any closer to the globe near the sheath attachment point and its distensibility becomes limited. An *in vivo* study conducted with subjects undergoing intrathecal infusion tests has validated the response of the optic nerve sheath diameter to changes in intracranial pressure.³ Subsequently, data from the ophthalmology and radiology literature have established norms for optic nerve sheath diameter in pediatric subjects.⁴⁻⁶ Increased intracranial pressure is associated with an optic nerve sheath diameter that exceeds 4 mm in patients younger than 1 year and 4.5 to 5 mm in older children, measured 3 mm posterior to the papilla in the axial transbulbar view.⁵⁻⁷

Pediatric data on the accuracy and role of sonographic measurements of optic nerve sheath diameter are limited to studies performed by radiologists or ophthalmologists.^{2,4,5,7} Most of the studies from the ED setting have excluded pediatric subjects.⁸⁻¹⁰ We are not aware of any prospective trial evaluating the accuracy of bedside pediatric emergency physician–performed optic nerve sheath diameter measurements as a screening test for increased intracranial pressure in the acute care setting.

MATERIALS AND METHODS

The objective of our study was to evaluate the test characteristics of bedside ultrasonography of the optic nerve sheath for the diagnosis of increased intracranial pressure. This was a prospective, single-masked cohort study of patients aged 0 to 18 years, with suspected or confirmed increased intracranial pressure, presenting to the ED or ICU of an urban, academic, freestanding, tertiary-level children's hospital with an annual ED census of 67,000. We included patients with severe traumatic brain injury (Glasgow Coma Scale score less than 8), suspected ventriculoperitoneal shunt malfunction, suspected meningitis, clinical signs of suspected increased intracranial pressure, including altered mentation (not attributable to medications, seizures, or metabolic causes) or evidence of uncal herniation, and diabetic ketoacidosis with suspected cerebral edema. Patients with facial (including ocular) trauma were excluded. Before initiation of the study, 2 pediatric emergency physicians (A.L., J.P.) underwent 2 hours of didactic and goal-directed training by a pediatric ophthalmologist (M.E.H.) in ophthalmic sonography. Bilateral optic nerve sheath diameter measurements were recorded on 30 healthy volunteers and reviewed by an ophthalmic sonographer (M.E.S.) to refine their image acquisition technique.

With the patients in a supine position and eyelids closed, axial transbulbar images were obtained by the pediatric emergency physicians, using a Sonosite Titan ultrasound machine (Sonosite, Inc., Bothell, WA) and an 8- to 5-MHz 11-mm broadband curved array. When possible, the subjects were instructed to direct their gaze at the midline so that the optic nerve was aligned opposite to the probe. If the patient was not cooperative, the ultrasonographic probe was manipulated until an adequate image of the optic nerve sheath was obtained. When the optic nerve was aligned opposite the probe and centered, the image was captured and saved. We recruited the help of the parent in stabilizing the head of the infants during the examination. Once the probe was placed on the eyelid, the natural tendency was to close the eye. Some infants did not seem to mind the probe at all and were still. We did not have to exclude any patients because of inability to tolerate the probe.

Measurements were performed on the saved images. Bilateral optic nerve sheath diameters were measured 3 mm posterior to the globe (Figure 1). The average of the 2 measurements was used for statistical analysis. Images were recorded and uploaded to the hospital picture archiving and communication system and subsequently reviewed by the pediatric ophthalmologist and an ophthalmic sonographer, both of whom were unaware of the patient's clinical condition. Measurements of optic nerve sheath diameter obtained by the ophthalmic sonographer were considered the criterion standard.

Because Sonosite Titan does not incorporate Digital Image Communication and Conversion in Medicine software, direct measurements of optic nerve sheath diameter on the saved ocular images were not feasible. Therefore, a hard copy of the “clean” (without the measurement cursors) ocular image

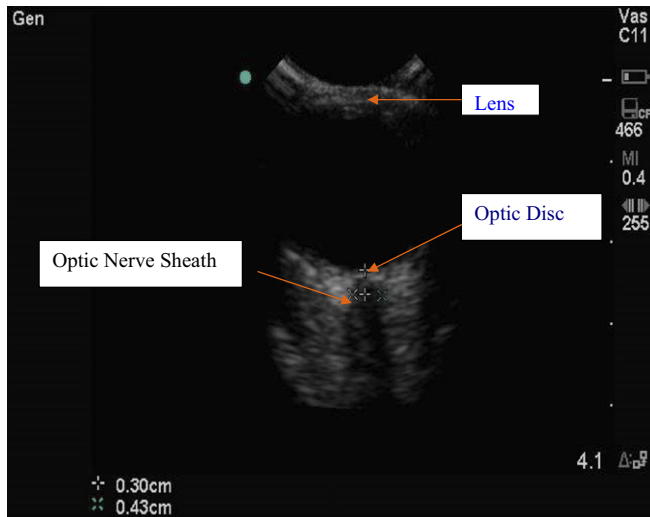


Figure 1. Ultrasonographic image of optic nerve sheath. The 2 “x” marks represent the point at which the diameter of the optic nerve sheath was measured.

demonstrating the optic nerve was scanned at 200-dots-per-inch resolution with a Kodak i40 scanner. These digital copies were then sent to the GE Centricity picture archiving and communication system. The images in the picture archiving and communication system were then assigned to an arbitrary orderable, marked as a “reference only,” and categorized by date. Measurements were then made on these digital copies after calibration of the image to a known scale, corresponding to the scale on the Sonosite machine. Calibration was performed to take into account the magnification effect introduced by the scanner. Calibration of pixels/unit remained constant with respect to time. Using a mouse-driven cursor, the pediatric emergency physician, ophthalmic sonographer, and pediatric ophthalmologist recorded measurement of the area of interest (ie, optic nerve sheath diameter). Images were logged and accessed by the raters separately. They were masked to each other’s evaluation. A convenience sample of subjects was recruited from the population presenting to the ED or from those admitted directly to the ICU at Le Bonheur. The emergency physician and critical care fellow were asked to contact the principal investigator when an eligible patient with suspected increased ICP was in their department. This request was reinforced by periodic electronic reminders and at our monthly staff meetings. If the patient met study inclusion criteria, and depending on the availability of the principal investigator, patients were approached for consent. Because the principal investigator was a pediatric emergency fellow, her availability was limited to months that she was not scheduled for a dedicated “away” rotation.

Subjects were determined to have increased intracranial pressure on satisfying at least 1 of the following criteria: (1) cranial CT findings suggestive of increased intracranial pressure (midline shift >3 mm, hydrocephalus, collapsed third ventricle,

effacement of sulci with significant edema or abnormal mesencephalic cistern), or (2) an opening pressure of greater than 20 cm of cerebrospinal fluid, as measured by ventriculostomy or lumbar puncture.¹¹ Each patient was dichotomized as “increased intracranial pressure present” or “increased intracranial pressure absent” and “normal optic nerve sheath diameter” or “increased optic nerve sheath diameter” according to established norms (<4.0 mm in infants younger than 1 year; <4.5 mm in children older than 1 year).⁵

Sensitivity, specificity, and likelihood ratios of increased intracranial pressure were calculated. Significance tests and *P* values were set at a type 1 error of .05. Interobserver agreement between the pediatric emergency physician and ophthalmic sonographer and that between the pediatric emergency physician and ophthalmologist were measured using the unweighted Cohen’s κ statistic on the postprocessed images. Comparison of actual measurements by the pediatric emergency physician and ophthalmic providers was conducted using the Wilcoxon signed rank test.

Our institutional review board approved the study.

RESULTS

Sixty-eight patients were approached for consent and 3 declined participation. One patient was excluded because the process of informed consent was deemed inadequate due to a language barrier. Sixty-four patients were included in the final analysis, yielding 128 images. An image from the left eye of one subject was deemed suboptimal for review after being uploaded to the hospital picture archiving and communication system and was excluded. For this particular subject, a single optic nerve sheath diameter measurement was included in the analysis.

The mean age of subjects recruited in our study was 8.8 years, median of 9.7 years, and a range of 1 month to 18 years. The frequency distribution is shown in Figure 2. Forty of the 64 were male patients. The average time for image acquisition ranged from 1 to 3 minutes. A majority (57/64) of the patients were recruited from the ED. Tables 1 and 2 list the diagnoses of patients with and without increased intracranial pressure, respectively. The timing of presentation relative to onset of symptoms (or precipitant injury) is shown in Table 3. The majority of the patients had their bedside sonographic measurement of optic nerve sheath diameter within 3 hours of the confirmatory test for increased intracranial pressure (Table 4).

The test characteristics of optic nerve sheath diameter measurements obtained by the emergency physicians, who were aware of the clinical details, and of the ophthalmic providers, who were masked to the clinical details, are reported alongside one another in Table 5. Optic nerve sheath diameter had a sensitivity of 83% (95% confidence interval [CI] 0.60 to 0.94) and specificity of 38% (95% CI 0.23 to 0.54) for detection of increased intracranial pressure. The negative likelihood ratio for normal optic nerve sheath diameter measurement was 0.47.

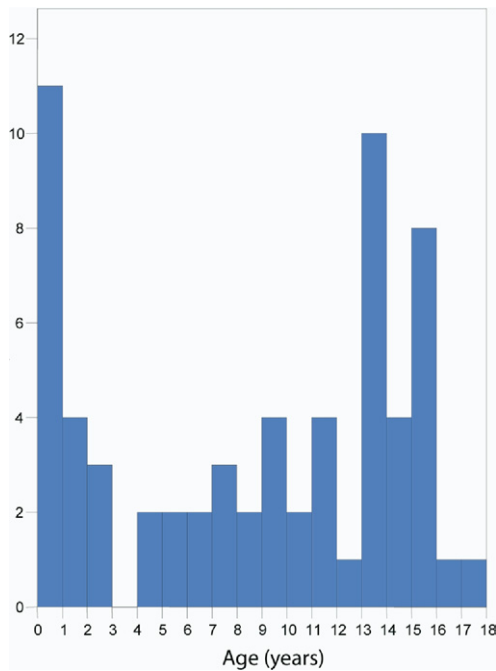


Figure 2. Age distribution.

Table 1. Diagnoses of patients with increased intracranial pressure

Diagnosis	Number of Patients
Ventriculoperitoneal shunt malfunction	9
Traumatic brain injury	4
Pseudotumor cerebri	4
Posterior fossa mass	3
Cerebral infarction with edema	1
Aqueductal stenosis	1
Bacterial meningitis	1
Chiari 1 malformation	1

We had used the cutoff optic nerve sheath diameter of 4.5 mm in children older than 1 year a priori, according to previously published norms in pediatrics.^{5,6} However, our review of the literature suggests that increased intracranial pressure was associated with an optic nerve sheath diameter range between 4.5 and 5 mm in older children. In a study of children older than 4 years and admitted to the ICU with increased intracranial pressure, an optic nerve sheath diameter measurement between 4.5 and 5.0 mm was considered “borderline,” whereas an optic nerve sheath diameter exceeding 5.0 mm was regarded as “definitely” enlarged.² The reason cited by the authors of this study was that clinical interpretation of optic nerve sheath diameter must take into consideration an error of 0.35 mm with repeated measurements. Similarly, in the Newman et al⁴ study that had published normative data and cited the 4.5-mm cutoff for children older than 1 year, the mean optic nerve sheath diameter in the group with increased ICP was 4.6 mm. Previous studies in adult subjects have also

Table 2. Diagnoses for patients without increased intracranial pressure

Diagnosis	Number of Patients
Undifferentiated headache, ventriculoperitoneal shunt	12
Closed head injury with mental status change	8
Undifferentiated headache with neurologic symptoms	6
Seizure, ventriculoperitoneal shunt	3
Meningitis	2
Acute febrile illness	2
Diabetic ketoacidosis	2
History of clumsiness, ventriculoperitoneal shunt	1
Syncope	1
Undifferentiated vomiting, ventriculoperitoneal shunt	1
S/P blunt head trauma, scalp laceration	1
Hyperammonemia	1

used an optic nerve sheath diameter cutoff of 5 mm.^{8,9} Hence, we also calculated the test characteristics of optic nerve sheath diameter with the higher threshold of 5 mm in older children. By increasing this cutoff, the specificity of optic nerve sheath diameter increased to 68%, whereas the sensitivity decreased to 78% (Table 6). A receiver operator characteristic curve at various thresholds of optic nerve sheath diameter measurement by the pediatric emergency physician is shown in Figure 3.

A comparison of the median and range of difference in measurements of optic nerve sheath diameter between the ophthalmic sonographer and pediatric emergency physician has been graphically represented in a Bland-Altman plot (Figure 4). The median difference of 0.01 mm between optic nerve sheath diameter measurements obtained by the pediatric emergency physician and ophthalmic sonographer was not statistically significant ($P=.341$).

There was good interobserver agreement between the pediatric emergency physician and ophthalmic sonographer (κ 0.52) and pediatric ophthalmologist (κ 0.64). The agreement statistic between the ophthalmic sonographer and pediatric ophthalmologist was fair (κ 0.36).

LIMITATIONS

There are several limitations that the reader needs to be aware of when interpreting the results of our study. In the majority of our patients, results of the cranial CT scan were used as a surrogate marker of increased intracranial pressure. Because direct invasive intracranial pressure monitoring is infrequently performed, restricting recruitment to subjects with an intracranial pressure monitor was not feasible. In addition, although we attempted to minimize bias by using the measurements of the blinded ophthalmic sonographer as the criterion standard, it was not feasible to blind the pediatric emergency physician to the clinical state of the patient. Hence, operator bias may have influenced image acquisition by the pediatric emergency physician. Every effort was made during the training phase to standardize the image acquisition process,

Table 3. Timing of presentation relative to the onset of symptoms or precipitant injury.

Number	<6 h	6–12 h	>12–24 h	>24–72 h	>72 h
Number of patients with suspected increased intracranial pressure (N=64)	14	4	14	10	22
Number of patients with confirmed increased intracranial pressure (N=24)	4	1	5	3	11

Table 4. Timing of bedside ultrasonography in relation to the criterion standard.

Number	Contemporaneously	0–3 h	>3–7 h
Number of patients with suspected increased intracranial pressure (N=64)	6	41	17
Number of patients with confirmed increased intracranial pressure (N=24)	1	12	11
Confirmatory test	Intracranial pressure monitor	Cranial CT scan or lumbar puncture	

Table 5. Test characteristics of bedside sonographic measurement of optic nerve sheath diameter.

Image Reviewer	Positive Likelihood Ratio (95% CI)	Negative Likelihood Ratio (95% CI)	Sensitivity (95% CI)	Specificity (95% CI)
Ophthalmic sonographer	1.32 (0.97–1.79)	0.46 (0.18–1.23)	0.83 (0.60–0.94)	0.38 (0.23–0.54)
Pediatric ophthalmologist	2.39 (1.45–3.93)	0.28 (0.11–0.69)	0.82 (0.59–0.94)	0.66 (0.48–0.80)
Pediatric emergency physician	1.83 (1.34–2.48)	0.09 (0.01–0.63)	0.96 (0.77–0.998)	0.48 (0.32–0.64)

Optic nerve sheath diameter was considered increased when it was >4 mm in infants <1 year or >4.5 mm in children >1 year.

Table 6. Test characteristics of bedside sonographic measurement of optic nerve sheath diameter.

Image Reviewer	Positive Likelihood Ratio (95% CI)	Negative Likelihood Ratio (95% CI)	Sensitivity (95% CI)	Specificity (95% CI)
Ophthalmic sonographer	2.41 (1.47–3.95)	0.32 (0.14–0.72)	0.78 (0.56–0.92)	0.68 (0.51–0.81)
Pediatric ophthalmologist	2.47 (1.30–4.72)	0.49 (0.28–0.87)	0.64 (0.41–0.82)	0.74 (0.56–0.87)
Pediatric emergency physician	2.73 (1.57–4.74)	0.34 (0.17–0.70)	0.75 (0.53–0.89)	0.73 (0.56–0.85)

Optic nerve sheath diameter was considered increased when it was >4 mm in infants <1 year or >5.0 mm in children >1 year.

ensuring that the nerve was centered and measurements were made 3 mm posterior to the globe.

In our study, 2 pediatric emergency physicians who had received goal-directed training in ophthalmic sonography recorded all optic nerve sheath diameter measurements. These results may not be generalized to pediatric physicians in other settings. However, because our results demonstrated fair to good interobserver agreement, we believe that this training model can be expanded to training other physicians. During the independent review by the ophthalmic sonographer, the quality of all images included in the analysis was deemed adequate to obtain accurate measurements.

With respect to actual measurement of optic nerve sheath diameter, there is usually a subjective judgment in assigning the boundary of the optic nerve sheath. Because ultrasonography is a highly operator-dependent technology, reproducibility of computer-aided measurements on postprocessed ocular images depends on the ease of demarcating the boundary of the region of interest and the accuracy of the user in guiding a mouse-driven cursor around this transition. This may have resulted in an inherent interobserver error that is inevitable but not unique

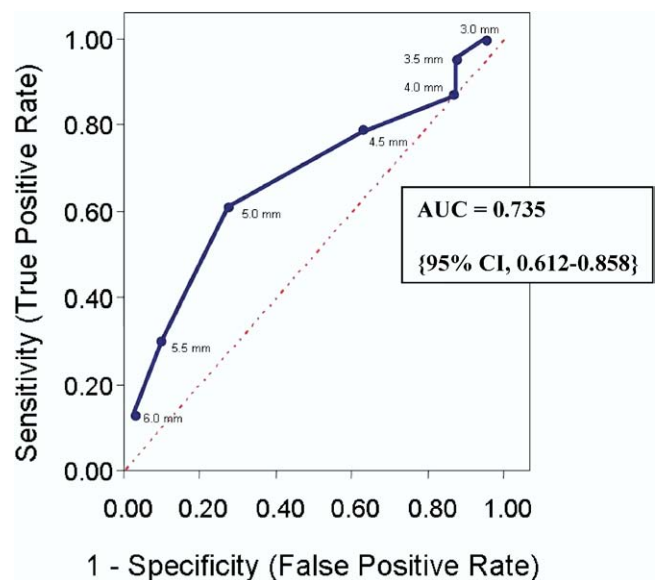


Figure 3. Receiver operator characteristic curve at different thresholds of optic nerve sheath diameter.

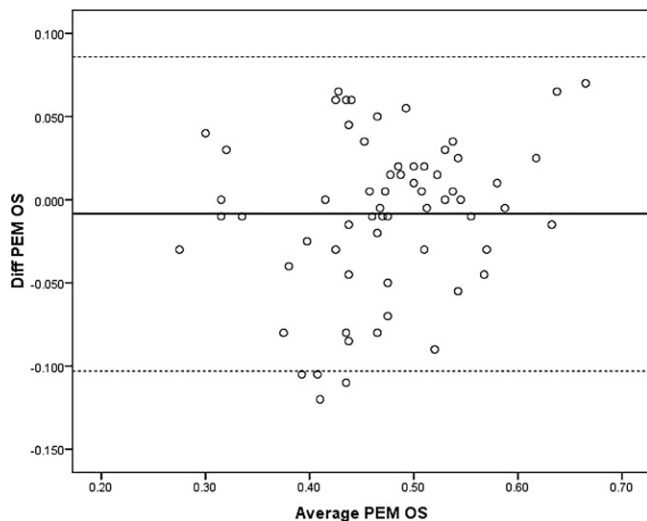


Figure 4. The x-axis represents the average of optic nerve sheath diameter measurement by the pediatric emergency physician (PEM) and ophthalmic sonographer (OS). The y-axis represents the actual difference in optic nerve sheath diameter measurement in millimeters between the pediatric emergency physician and the ophthalmic sonographer.

to ocular measurements. Previous data from computer-aided measurements of areas of interest on the fundus suggest that the average error for well-defined areas of interest is 6%.¹² We had recalculated the test performance of optic nerve sheath diameter as a predictor of increased ICP after factoring a measurement error of $\pm 6\%$ and observed that it did not change the overall test characteristics of optic nerve sheath diameter.

The sample size in our study was small and included a convenience sample of patients presenting to our ED or ICU. A larger, consecutive prospective cohort of pediatric patients representing the full spectrum of diseases associated with increased intracranial pressure would be needed to establish accuracy of sonographic measurement of optic nerve sheath diameter as a reliable screening tool for diagnosis of increased intracranial pressure.

DISCUSSION

The results of our study suggest that bedside sonographic measurement of optic nerve sheath diameter may not serve as an adequate screening tool for diagnosis of increased intracranial pressure. A sensitivity of 83% may not be sufficient to guide medical decisionmaking in a disease process with high potential for morbidity and mortality. The poor specificity suggests that many patients would be misclassified as having increased intracranial pressure. Furthermore, with goal-directed training by a pediatric ophthalmologist familiar with ophthalmic sonography, pediatric emergency physicians can measure optic nerve sheath diameter accurately.

We are not aware of any previous data from prospective trials addressing the role of sonographic measurement of optic nerve

sheath diameter by pediatric emergency physicians. The previous literature on optic nerve sheath diameter in pediatric subjects was from an outpatient specialty clinic or inpatient unit, and measurements were performed by pediatric radiologists or ophthalmologists.⁴⁻⁷ The results of these studies may not be extrapolated to the ED setting.

Previous investigations conducted in an ED population were limited to adult subjects with suspected or confirmed increased intracranial pressure.^{8,9} Blaivas et al⁹ conducted a prospective, observational study measuring optic nerve sheath diameter on 35 adult subjects presenting to an ED with suspected increased intracranial pressure.⁹ In their study, the sensitivity and specificity of ocular sonography compared with CT evidence of increased intracranial pressure were 100% and 95%, respectively. More recently, results of one small study by Kimberly et al¹⁰ on a cohort of 15 adult subjects in the neuro-ICU showed high sensitivity and negative predictive value for detection of increased intracranial pressure. Subjects in this study had an intracranial pressure monitor in place and received repeated measurements of optic nerve sheath diameter.¹⁰ In these studies, although investigators performing sonography were masked to the results of confirmatory tests, they were presumably aware of the clinical condition of the subjects. Because these results are similar to the test characteristics for optic nerve sheath diameter obtained by the pediatric emergency physicians in our study, we speculate that the investigators' knowledge of the patients' clinical conditions may have improved the overall test performance of optic nerve sheath diameter for diagnosis of increased intracranial pressure. Alternatively, these investigators may have benefited from better training, technique, or equipment.

Although we had anticipated difficulty in obtaining adequate images for measurement of optic nerve sheath diameter in young infants, we did not have to sedate any infant or young child for ocular sonography. This was consistent with a previous report on orbital sonography from the department of pediatric imaging that did not find it necessary to sedate any child, except when precise Doppler quantification was needed.¹³

In summary, although it is a rapid and noninvasive test, the sensitivity and specificity of bedside sonographic measurement of the mean binocular diameter of the optic nerve sheath are not adequate for medical decisionmaking in children with suspected increased intracranial pressure. The technique could play a role in triage and patient evaluation when CT imaging is not readily available. With goal-directed training and oversight by pediatric ophthalmology, pediatric emergency physicians can measure optic nerve sheath diameter accurately.

Supervising editor: Steven M. Green, MD

Author contributions: AL and JP conceived the study and designed the trial. AL was responsible for patient recruitment and data management. MEH and MES provided training in ophthalmic sonography and served as independent reviewers of all images. TS assisted with recruiting. DS provided

statistical advice and analyzed the data. AL and JP drafted the article, and all authors contributed substantially to its revision. AL takes responsibility for the paper as a whole.

Funding and support: By *Annals* policy, all authors are required to disclose any and all commercial, financial, and other relationships in any way related to the subject of this article that might create any potential conflict of interest. The authors have stated that no such relationships exist. See the Manuscript Submission Agreement in this issue for examples of specific conflicts covered by this statement.

Publication dates: Received for publication July 29, 2008. Revision received October 21, 2008. Accepted for publication November 25, 2008. Available online January 23, 2009.

Reprints not available from the authors.

Address for correspondence: Audrey Le, MD, Le Bonheur Children's Medical Center, Emergency Department, 50 North Dunlap Street, Memphis, TN 38104; E-mail ahlegory@gmail.com.

REFERENCES

1. Liu D, Kahn M. Measurement and relationship of subarachnoid pressure of the optic nerve to intracranial pressures in fresh cadavers. *Am J Ophthalmol*. 1993;116:548-556.
2. Helmke K, Hansen HC. Fundamentals of transorbital sonographic evaluation of optic nerve sheath expansion under intracranial hypertension II. Patient study. *Pediatr Radiol*. 1996;26:706-710.
3. Hansen HC, Helmke K. Validation of the optic nerve sheath response to changing cerebrospinal fluid pressure: ultrasound findings during intrathecal infusion tests. *J Neurosurg*. 1997;87:34-40.
4. Newman WD, Hollman AS, Dutton GN, et al. Measurement of optic nerve sheath diameter by ultrasound: a means of detecting acute raised intracranial pressure in hydrocephalus. *Br J Ophthalmol*. 2002;86:1109-1113.
5. Korber F, Scharf M, Moritz J, et al. [Sonography of the optical nerve—experience in 483 children]. *Rofo*. 2005;177:229-235.
6. Ballantyne J, Hollmas AS, Hamilton R, et al. Transorbital optic nerve sheath ultrasonography in normal children. *Clin Radiol*. 1999;54:740-742.
7. Malayeri AA, Bavarian S, Mehdizadeh M. Sonographic evaluation of optic nerve diameter in children with raised intracranial pressure. *J Ultrasound Med*. 2005;24:143-147.
8. Tayal VS, Neulander M, Norton HJ, et al. Emergency department sonographic measurement of optic nerve sheath diameter to detect findings of increased intracranial pressure in adult head injury patients. *Ann Emerg Med*. 2007;49:508-514.
9. Blaivas M, Theodoro D, Sierzenski PR. Elevated intracranial pressure detected by bedside emergency ultrasonography of the optic nerve sheath. *Acad Emerg Med*. 2003;10:376-381.
10. Kimberly HH, Shah S, Marill K, et al. Correlation of optic nerve sheath diameter with direct measurement of intracranial pressure. *Acad Emerg Med*. 2008;15:201-204.
11. Biros M. Head trauma. In: Rosen P, Barkin R, eds. *Emergency Medicine*. St. Louis, MO: Mosby-Year Book; 1998:416-447.
12. Gosbell AD, Barry WR, Favilla I, et al. Computer aided area measurement of ocular images. *Australian New Zealand J Ophthalmol*. 1987;15:341-348.
13. Ramji FG, Slovis TL, Baker JD. Orbital sonography in children. *Pediatr Radiol*. 1996;26:245-258.

Request for Abstracts for ACEP's Research Forum (non-moderated)

Researchers have a unique opportunity to showcase emergency medicine research published or presented in other specialties' journals or meetings in the past year. This is an excellent venue to share outstanding emergency medicine research from competing meetings or journals.

ACEP's *Research Forum* is providing emergency medicine researchers with another opportunity this year to present scientific emergency medicine research at the 2009 conference, which will be held October 5-6 in conjunction with *Scientific Assembly* in Boston, MA.

Abstracts from emergency physicians who have presented or published in non-emergency medicine specialty meetings or journals within the past 12 months will be considered. Case reports or subject reviews are not considered original research. These abstracts will be accepted on a space available basis as non-moderated posters. If accepted the presenter is obligated to be available to discuss their poster(s) with *Research Forum* attendees.

Please submit your research abstract(s) to the academic affairs department by Friday, August 21, 2009 at academicaffairs@acep.org, or by fax at 972-580-2816. Notifications will be sent by August 31, 2009. For questions, please call 800-798-1822, ext. 3291.