



June Parker. *After the Storm*. Pastel. From the collection of the artist.

*Several new systemic therapies  
for refractory meningiomas  
are now being studied.*

# New Approaches for the Treatment of Refractory Meningiomas

*Brian Ragel, MD, and Randy L. Jensen, MD, PhD*

**Background:** Complete surgical resection is the first-line therapy for meningiomas. However, tumor location and biological aggressiveness can make surgical cure impossible. Treatment options for these refractory meningiomas include further surgery, conventional external beam irradiation, stereotactic radiosurgery, and systemic therapies. In this paper, we discuss new and emerging systemic therapies when these "local" treatment options are not successful.

**Methods:** We reviewed predictors of refractory meningiomas and novel systemic therapies in the treatment of refractory meningiomas.

**Results:** Tumor location, atypical or malignant histologic subtypes, and staining for the Ki-67 protein (MIB-1 antibody) with a high labeling index are the best predictors of tumor recurrence. Novel systemic treatment options include angiogenesis inhibition, meningioma cell growth inhibition, blockade of growth factor effects, inhibition of intracellular secondary pathways, and gene therapies.

**Conclusions:** MIB-1 labeling index staining is a good predictor for refractory meningiomas. Currently, the best-studied systemic treatment for patients with refractory meningiomas is hydroxyurea. Blockade of the growth hormone receptor by pegvisomant is promising because *in vivo* and *in vitro* studies have shown good results and the drug has a known side effect profile.

## Introduction

Meningiomas are the second most common central nervous system tumor, accounting for approximately 20% of all primary adult intracranial tumors. The vast majority of meningiomas occur in patients between 50 and 60 years of age, with a twofold higher incidence in women.<sup>1</sup> The biological behavior of meningiomas is one of continued growth, ultimately leading to compression of neuronal structures. The

---

From the Department of Neurosurgery (BR, RLJ) and the Department of Veterans Affairs, Salt Lake City Health Care System and Huntsman Cancer Institute (RLJ) at the University of Utah, Salt Lake City, Utah.

Submitted October 7, 2002; accepted December 24, 2002.

Address reprint requests to Randy Jensen, MD, PhD, Department of Neurosurgery, University of Utah, 3B-409 SOM, 30 North 1900 East, Salt Lake City, UT 84132-2303.

No significant relationship exists between the authors and the companies/organizations whose products or services may be referenced in this article.

Table 1. — Pathologic Classification of Meningiomas\*

Grade	Designation	Meningioma
I	Typical	Meningothelial, fibrous, transitional, psammomatous, angiomatous, microcystic, secretory, clear cell, choroid, lymphoplasmacyte-rich, metaplastic
II	Atypical	Papillary
III	Anaplastic	Malignant

\* Based on WHO classification 1993. Sekhar LN, Levine ZT, Sarma S. Grading of meningiomas. *J Clin Neurosci.* 2001;8(suppl 1):1-7.

treatment of choice is surgery, which is frequently successful in treating these tumors. There are usually two reasons that surgery is ineffective. First, tumor location or proximity to neurovascular structures may make complete resection impossible. Second, the inherent biology of the tumor may give a particular meningioma a greater propensity for recurrence despite seemingly complete resection (Table 1). Fortunately, histologically atypical or malignant tumors comprise less than 10% of meningiomas. These two types of tumors are especially disposed to recurrence.<sup>2</sup>

Surgery is the treatment of choice for symptomatic meningiomas, although asymptomatic meningiomas may be followed with serial imaging. The Simpson classification is the most well known for prediction of tumor recurrence after surgical resection. The extent of surgical resection, according to the Simpson classification system (Table 2), ranges from grade 1 (complete resection) to grade 5 (decompression only).<sup>3</sup> Following a macroscopically complete resection, the 5-, 10-, and 15-year recurrence-free rates were 93%, 80%, and 68%, respectively. For incompletely resected lesions, the progression-free rates at the same postoperative intervals were expectedly lower, at 63%, 45%, and 9%.<sup>4</sup>

Atypical and malignant meningiomas comprised 6.3% and 1.7% in one retrospective series of 319 intracranial meningiomas.<sup>5</sup> Atypical and malignant meningiomas have an earlier peak incidence compared with their benign counterparts. Curiously, there is an almost equal distribution between sexes, with a male:female ratio of 1:0.9 for the more aggressive meningiomas vs 1:2.3 for the histologically benign.<sup>5</sup> Mahmood et al<sup>5</sup> noted that radiographically, all these tumors showed moderate to severe peritumoral edema. At 5 years after complete removal, recurrence rates for benign meningiomas range from only 2% to 3%, but the recurrence rates range from 38% to 50% for atypical ones and 33% to 78% for anaplastic ones. The median times to recurrence are 3.1 to 7.5 years, 2.4 to 3.3

Table 2. — Resection-Based Classification of Meningiomas\*

Grade	Tumor Resection	Recurrence Rate
I	Macroscopically complete removal of dura, bone	9%
II	Macroscopically complete removal, dural coagulation	19%
III	Complete tumor resection, dura not coagulated	29%
IV	Partial removal	44%
V	Simple decompression	

\* Based on Simpson grade.<sup>3</sup>

years, and 3.5 to 7.7 years, respectively.<sup>5,6</sup> Overall, atypical and malignant meningiomas show a much greater propensity to recur.

Treatment options for recurrence or incomplete resection include further surgery, conventional external beam irradiation, stereotactic radiosurgery, and systemic therapies.<sup>7,9</sup> Most patients with malignant meningiomas will receive radiation therapy after surgery.<sup>6,10</sup> However, radiation therapy or stereotactic radiosurgery is limited by radiation neurotoxicity, tumor size, and injury to adjacent vascular or cranial nerves.<sup>8,11</sup> The most promising antineoplastic agent, hydroxyurea, has proven to be an effective treatment for recurrent or unresectable meningiomas.<sup>9,12,13</sup> Hormonal therapy has been attempted using agents that block estrogen or progesterone receptors, but trials with tamoxifen, medroxyprogesterone acetate, megestrol acetate, and the progesterone receptor antagonist RU486 also have been disappointing.<sup>14</sup> To date, these adjuvant therapies have been ineffective in controlling recurrent meningiomas, and new treatments should be explored. In this paper, we discuss emerging or novel therapeutic options that may become available for meningiomas that are unresponsive to the conventional treatments.

## Case Illustration

A 54-year-old man began to have "shoulder problems" and was seen by a physical therapist. The therapist believed that the symptoms were more consistent with a stroke since they included right hemiparesis and cognitive changes. The patient was returned to his internist, and magnetic resonance imaging (MRI) demonstrated a posterior left parasagittal meningioma (Fig 1A-C). He was then admitted to the hospital and underwent a cerebral angiogram with subsequent embolization. The following day, a frameless stereotactic-guided craniotomy and resection were performed. The postoperative MRI was read as "no evidence of residual tumor" (Fig 1D-E) but the tumor pathology showed a number of mitotic

figures and an MIB index of 30%, with a diagnosis of atypical meningioma (Fig 1F-G).

The patient made a full recovery and returned to his prior occupation of construction work. His follow-up imaging studies at 6 months were without residual tumor. However, 15 months after his original surgery, he experienced a recurrence of his original symptoms. An MRI was performed and revealed large recurrence of tumor (Fig 2A-C). Repeat angiogram, embolization, and surgery were performed, with sacrifice of the superior sagittal sinus. Histopathologically, the tumor was unchanged, with at least 5 mitotic figures per high power field and an MIB index of 50%. His symptoms again resolved and radiation therapy was performed to

54 Gy. He returned to work and was mostly asymptomatic. Surveillance imaging revealed some extracranial nodularity (Fig 3A-B), and these were followed with serial imaging. However, 24 months after his initial surgery, they had grown considerably (Fig 3C).

A third resection performed in conjunction with plastic surgery. This required duraplasty, cranioplasty, resection of the invaded scalp, and a latissimus dorsi muscle flap. The pathology was unchanged but showed extensive invasion of the overlying scalp, bone, and dura (Fig 3D-F). Initially, postoperative films demonstrated no evidence of tumor recurrence (Fig 3G-H), but at 9 months from the last surgery, the films showed small enhancing skin nodules consistent with

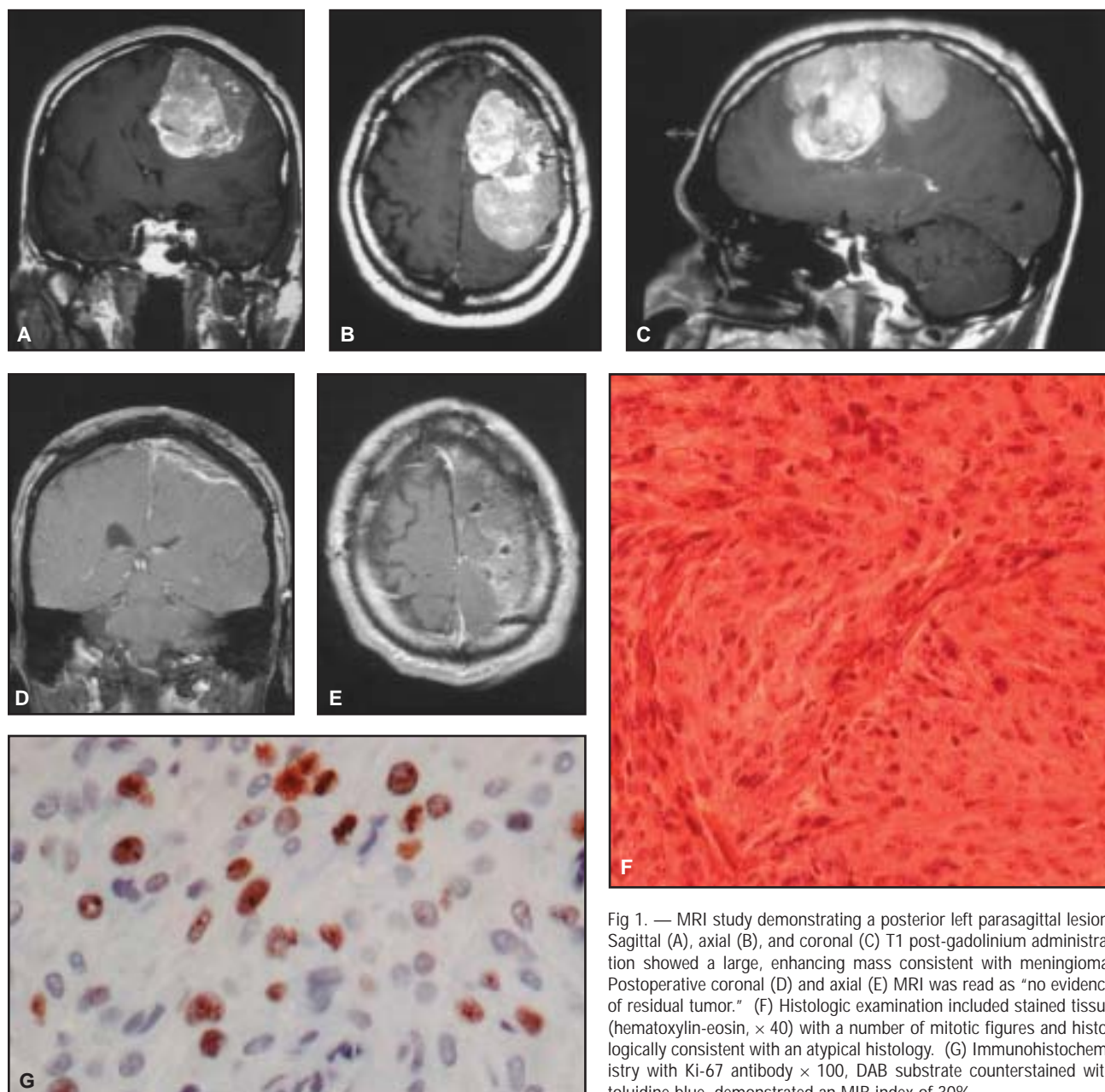


Fig 1. — MRI study demonstrating a posterior left parasagittal lesion. Sagittal (A), axial (B), and coronal (C) T1 post-gadolinium administration showed a large, enhancing mass consistent with meningioma. Postoperative coronal (D) and axial (E) MRI was read as “no evidence of residual tumor.” (F) Histologic examination included stained tissue (hematoxylin-eosin,  $\times 40$ ) with a number of mitotic figures and histologically consistent with an atypical histology. (G) Immunohistochemistry with Ki-67 antibody  $\times 100$ , DAB substrate counterstained with toluidine blue, demonstrated an MIB index of 30%.

tumor recurrence. The patient required intensive rehabilitation after this last surgery and is only now back to a functional status. He has been counseled on possibly needing stereotactic radiosurgery, chemotherapy with RU486 or hydroxyurea, and/or repeat surgery.

## Predictors of Refractory Meningiomas

There are predictors of meningiomas that may prove difficult to treat surgically or may respond poorly to radiation therapy. Location at the skull base, espe-

cially in the cavernous sinus, has a much higher recurrence rate than a tumor at the convexity. Other predictors of "difficult-to-treat" meningiomas include atomic bomb survivors, chromosome aberrations, and various histopathologic markers (Table 3). Patients at increased risk for meningiomas include those who have had radiation exposure and those with neurofibromatosis type 2.<sup>15-17</sup> Chromosome aberrations associated with higher-grade meningiomas include 1p, 6q, 10p, 10q, 14q, and 18q.<sup>18-20</sup> Current histopathologic research centers on identifying specific markers (intracellular, cellular wall, or extracellular) that would iden-

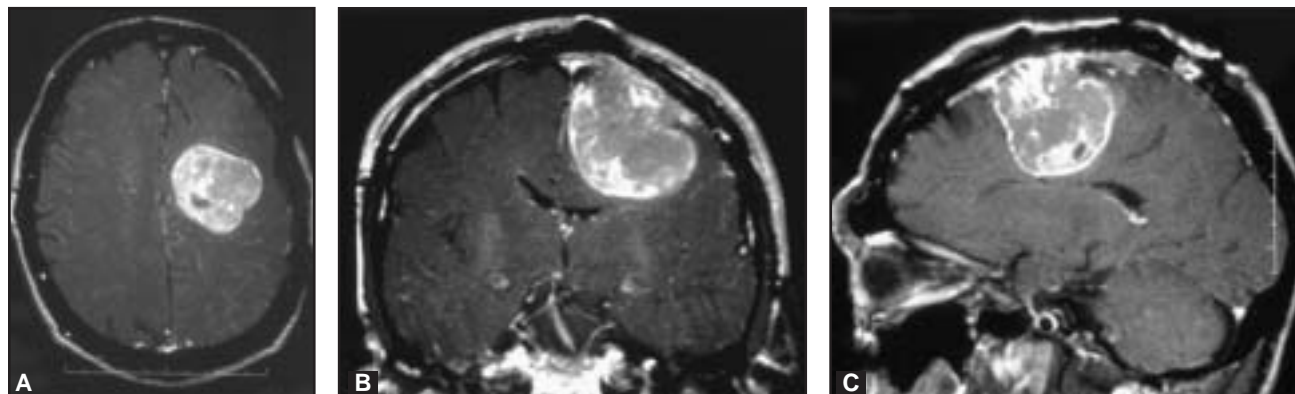


Fig 2. — MRI study 15 months after the patient's original surgery with evidence of a recurrent posterior left parasagittal lesion. Axial (A), coronal (B), and sagittal (C) T1 post-gadolinium administration demonstrated a large, enhancing mass consistent with meningioma.

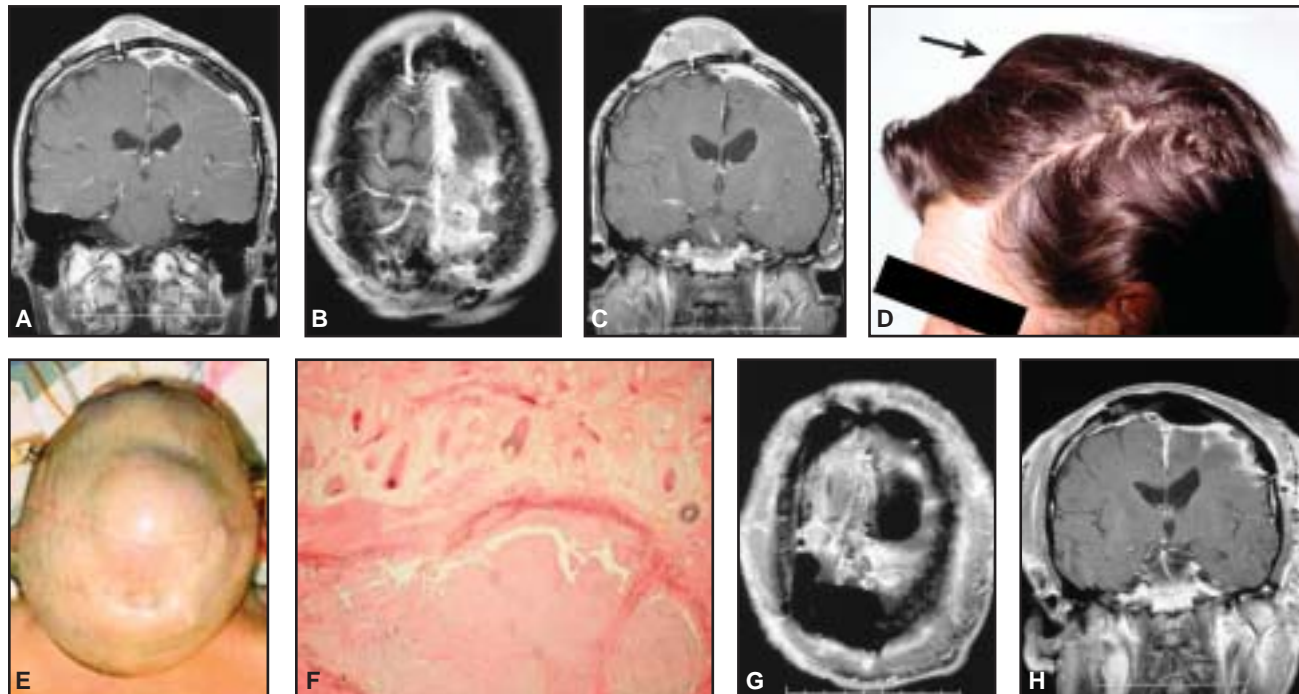


Fig 3. — MRI study 5 months after the patient's second surgery, 20 months after the original surgery with evidence of an extracranial nodularity and possible recurrence of his tumor. Coronal (A) and axial (B) T1 post-gadolinium administration demonstrated a small amount of enhancement consistent with possible recurrent meningioma. Three months later this had progressed, demonstrating tumor recurrence. (C) Coronal T1 post-gadolinium-enhanced lesion appeared largely extracranial. (D) Lateral photograph of the patient's head showed a bump at the site of prior surgery. (E) Intraoperative photograph of the patient's head after shaving showed a visible tumor mass subcutaneously below the prior skin incision. (F) Hematoxylin-eosin stained tissue ( $\times 40$ ) demonstrated extensive invasion of the overlying scalp, bone, and dura. Immediate postoperative axial MRI (G) and coronal MRI (H) once again were believed to show no residual tumor.

Table 3. — Predictors of Refractory Meningiomas

<b>Radiation-Induced Tumors:</b>
Secondary CNS tumors in childhood cancers treated with radiation
Atomic bomb survivors
<b>Chromosome Abnormalities:</b>
Chromosome 22 - neurofibromatosis type 2
Chromosome 1p deletion
Chromosome aberrations (1p, 6q, 10p, 10q, 14q, and 18q)
<b>Immunohistochemical Markers:</b>
MIB-1 antibody (targets the Ki-67 intranuclear, nonhistone protein)
bcl-2
p53
p51
FAS-APO1 (CD95) (cell wall marker)
Tenascin (extracellular matrix component)
Alterations in tumor suppressor genes
Meningioma-expressed antigens

tify recurrent meningiomas; of these, the MIB-1 antibody appears most promising.

Immunohistochemical staining with the MIB-1 antibody (Ki-67) has consistently correlated with meningioma recurrence.<sup>21-23</sup> Ki-67 is a nuclear, non-histone protein expressed during the proliferation phases of the cell cycle (G<sub>1</sub>, S, G<sub>2</sub>, M) and not expressed in the resting phase (G<sub>0</sub>). Staining with MIB-1 gives a labeling index (LI) that allows for quantification of the number of cells dividing. Ho and colleagues<sup>22</sup> recently studied 83 meningioma patients with total resections who were followed for a minimum of 10 years. They report that 52 tumors had an MIB-1 LI <10%, and none of these recurred in 10 years. Of the 31 tumors with an LI >10%, 97% recurred within 10 years. Korshunov et al<sup>24</sup> retrospectively stained 263 meningioma patients with the Ki-67 antibody and noted a significantly decreased recurrence-free survival in patients with an LI <4.4%. Variations between MIB-1 LI center around

differences in tissue processing and the method of counting stained cells. An absolute value for the MIB-1 LI is difficult to ascertain because of the variability in immunohistochemical staining among laboratories. Nakasu et al<sup>21</sup> compared two methods of calculating the MIB-1 LI (area of highest labeling vs randomly selected) and concluded that a randomly selected method correlated better with meningioma recurrence (Table 4).

Other markers that have been reported to correlate with higher-grade meningiomas include the *bcl2* proto-oncogene, p53, p51, alterations in tumor suppressor genes, Fas-APO1 (CD95) transmembrane protein, the extracellular matrix protein tenascin, and five novel meningioma-expressed antigens.<sup>19,23,26-30</sup> In the future, these markers may provide both identification of refractory meningiomas and “novel” therapeutic targets.

## Current Treatments for Refractory Meningiomas

The role of radiation therapy for the treatment of meningiomas is still being defined. Irradiation of meningiomas is frequently used for high-grade histology (atypical and malignant), high-risk locations (eg, cavernous sinus), residual tumor, and patients who are poor surgical candidates. Studies have shown 5-year progression-free survival rates of 77% to 89% when fractionated external beam irradiation was used after subtotal resections in meningiomas with typical histology.<sup>8,31,32</sup> Lee et al<sup>33</sup> advocates the use of stereotactic radiosurgery in the treatment of cavernous sinus meningiomas and reported a 5-year tumor control rate for typical meningiomas of 93%. Overall, both conventional radiation therapy and focused stereotactic therapy have been shown to prolong the time until recurrence. Atypical and malignant meningiomas continue

Table 4. — Comparison of Cut-Off Points for MIB-1 Labeling Indices in Predicting Recurrence Free Survival of Meningiomas Managed With Initial Gross Total Resection

Study	MIB-1 LI Cut-Off Point	MIB-1 LI < Cut-Off	MIB-1 LI > Cut-Off
Korshunov <sup>24</sup> (2002)	4.4% (263 patients)	82% RFS at 6 yrs*	32% at 6 yrs*
Ho <sup>22</sup> (2002)	10% (83 patients)	100% RFS at 10 yrs (ie, no recurrence at 10 yrs [0/52])	3% RFS at 10 yrs (ie, 97% recurred within 10 yrs [30/31])
Nakasu <sup>21</sup> (2001)	2% (112 patients)	97% RFS at 10 yrs (ie, 3% recurred within 10 yrs [3/93])	57% RFS at 10 yrs (ie, 53% recurred within 10 yrs [10/19])
Perry <sup>25</sup> (1998)	4.2% (425 patients)	85% RFS at 7 yrs*	62% RFS at 7 yrs*

\* Kaplan-Meier method  
RFS = recurrence-free survival  
LI = labeling indices

to be difficult to treat with any modality, including radiotherapy and stereotactic radiosurgery.

Hydroxyurea is a ribonucleotide reductase inhibitor commonly used in the treatment of hematologic malignancies.<sup>9</sup> It diffuses into cells and inhibits DNA synthesis without interfering with RNA or protein synthesis by blocking the conversion of ribonucleotides to deoxyribonucleotides. Hydroxyurea was first reported to inhibit primary human meningioma cell growth in culture and in xenograft transplantation models.<sup>12</sup> This drug was believed to be a powerful inhibitor of meningioma cell growth, most likely by causing apoptosis in the tumor cells. Recently, Rosenthal et al<sup>9</sup> reported on 15 meningioma patients with residual tumor postresection and progressive growth, showing that 11 achieved stable disease with hydroxyurea. Mason et al<sup>13</sup> treated 20 documented enlarging meningiomas (16 benign, 3 atypical, and 1 malignant) with hydroxyurea. Twelve of the 16 benign tumors stabilized at a median duration of therapy of 122 weeks. The 4 remaining patients with benign tumors, as well as all of those who had atypical and malignant meningiomas, had progression of their disease. It appears that complete tumor regression is not a realistic goal with this drug. However, a reasonable number of patients have experienced tumor stabilization with minimal incidence of side effects after treatment with hydroxyurea. A current Southwestern Oncology Group protocol (SWOG-S9811) is currently enrolling patients to further answer this question.

## Mifepristone (RU486)

A discussion of the rationale of why hormone therapies are disappointing is beyond the scope of this paper. Briefly stated, numerous studies document that meningiomas are more common in women than men; also, the disease is exacerbated during pregnancy and menstruation, and both estrogen and progesterone receptors are found on meningiomas.<sup>34</sup> In 1986, Olson and colleagues<sup>35</sup> reported the initial activity of mifepristone (RU486) in tissue culture. Meningioma cell lines were derived from 3 patients, and all cells expressed estrogen and progesterone receptors. The use of RU486 inhibited growth of all 3 cell lines. These findings were confirmed by both in vitro and in vivo studies.<sup>36-38</sup> A clinical trial that was conducted to capitalize on these findings demonstrated that 8 of 28 patients with meningiomas treated with RU486 experienced a "suggestion of response."<sup>39,40</sup> In a separate clinical trial, 10 patients with 12 progressive recurrent and/or inoperable meningiomas were treated with a similar therapeutic regimen. Four tumors in 3 patients demonstrated tumor regression, 3 patients had "stable disease," and

4 patients with 5 tumors had progressive disease.<sup>41</sup> Prospective trials have been started, but there are no published results available. There appears to be secondary to little response to treatment in the few patients studied.

## Novel Treatments for Refractory Meningiomas

Novel treatments for refractory meningiomas can be divided into several categories based on the underlying mechanism of action: angiogenesis inhibitors, inhibition of meningioma cell growth, blockade of growth hormone pathways, blockade of growth factor receptors, disruption of intracellular secondary pathways, and gene therapy (Table 5).

### Angiogenesis Inhibitors

Tumors need to promote angiogenesis if they are to survive and grow.<sup>42</sup> Inhibition of neovascularization is one potential strategy for treating hypervascular tumors. Interferon alpha (IFN- $\alpha$ ), a leukocyte-produced cytokine, is a glycoprotein that is related to transforming growth factor beta (TGF- $\beta$ ) and tumor necrosis factor. The IFNs work mainly by their antiangiogenesis effect as well as by direct tumor cell inhibition.<sup>43,44</sup> Interferon has been reported to have an effect on

Table 5. — Novel Treatments for Recurrent Meningiomas

<b>Angiogenesis Inhibitors:</b>
Interferon alpha
TNP-470 (synthetic analog of fumagillin)
Tumor necrosis factor
PD156707
Verotoxin
<b>Inhibition of Tumor Cell Growth:</b>
Interferon alpha
Hydroxyurea
<b>Growth Hormone Blockade:</b>
Pegvisomant
Octreotide
Bromocriptine
<b>Growth Factor Blockade:</b>
Trapidil
Suramin
Bromocriptine
<b>Signal Pathway Inhibition:</b>
Calcium channel blockers
Mitogen-activated protein kinases
<b>Gene Therapy:</b>
Herpes simplex virus for transduction of merlin gene
Adenovirus

meningiomas in vivo and in vitro.<sup>44-48</sup> Kaba et al<sup>44</sup> reported on 6 patients with recurrent or malignant meningiomas treated with IFN- $\alpha$ -2B. Five of the 6 patients had stabilization of disease progression, with the duration of tumor stabilization ranging from 6 to 14 months. Muhr et al<sup>48</sup> looked at meningioma metabolism in 12 patients treated with IFN- $\alpha$ . This group followed patients with serial [C]-L-methionine uptake positron emission tomography (PET) studies, and they showed stabilization of disease in 9 patients. They concluded that PET was a useful tool in determining responders to IFN treatment. In both reports, IFN treatment toxicities were tolerable, with patients complaining mostly of flu-like symptoms and leukopenia. Yazaki et al<sup>49</sup> looked at TNP-470, a synthetic analog of fumagillin, and showed that it significantly inhibited tumor neovascularization and tumor growth of both non-malignant and malignant meningiomas.

Endothelin (ET) is a peptide composed of 21 amino acids with three identified isoforms (ET-1, ET-2, and ET-3). They exert their effects via two receptor subtypes: ET-A and ET-B. Endothelins are angiogenic, potent vasoconstrictors (ET-A R) and vasodilators (ET-B R), and they also incite mitogenesis and c-Fos expression of neuronal cell types in vivo.<sup>50,51</sup> Thus, ET has been hypothesized to promote angiogenesis and to act as an autocrine/paracrine growth factor in cerebral tumors. Harland et al<sup>51</sup> found that meningiomas expressed a higher level of ET-A receptors compared with normal cortex, and they concluded that the high-affinity ET-A receptor antagonist PD156707 may be of therapeutic value in treating these lesions.

Verotoxin has recently been studied as a new anti-neoplastic agent that targets the globotriaosylceramide (Gb3) glycolipid on tumor cells and tumor neovascularity. Verotoxins, or Shiga-like toxins, are produced by *Escherichia coli* and are associated with the pathogenesis of hemolytic uremia syndrome, hemorrhagic colitis, and microangiopathies. Verotoxin is a type II ribosome-inactivating protein produced by pathogenic strains of *E coli* and targets only cells that express glycolipid, Gb3 (CD77). Gb3 has been noted to be unregulated in many human cancers. The toxin consists of an A-subunit (enzyme) and B-subunit (antigen). The B-subunit recognizes specific glycolipids in particular cells, which are known to be elevated in several human cancers. Salhai et al<sup>52</sup> recently showed that the verotoxin receptor was present in 9 (82%) of 11 malignant meningiomas and that intratumoral injection of verotoxin in a mouse xenograft model resulted in increased survival of seeded animals. Microscopically, the verotoxin-treated animals showed decreased microvascular density, increased apoptosis, and a decrease in meningioma cell proliferation.

## Growth Hormone Inhibitors

Interest in the roles that growth hormone and insulin-like growth factor I (IGF-I) play in meningiomas tumorigenesis stems first from observations that patients with acromegaly have a high incidence of meningiomas (1.5% in one large series), and second from studies showing involvement of IGF-I in meningioma growth in cultures.<sup>53,54</sup> Growth hormone is produced and secreted from the anterior pituitary and stimulates the synthesis of IGF-I in the liver, the combined effects of which result in normal growth. In vivo and in vitro studies have shown that the growth hormone receptor is ubiquitous in meningiomas and that blockade results in decreased tumor growth.<sup>55,56</sup> Pegvisomant is a genetically engineered protein designed to be structurally similar to the natural human growth hormone. It is capable of binding to the growth hormone receptor, acting as a competitive antagonist. Friend et al<sup>55</sup> looked at 14 human meningioma specimens that were grown in primary culture. They found the ubiquitous expression of meningioma receptor mRNA in all 14 specimens, regardless of tumor grade (benign, anaplastic, or malignant). Blockade of the growth hormone receptor with pegvisomant reduced serum-induced DNA synthesis as measured by thymidine incorporation by 8% to 33% (mean 20%). IGF-I increased thymidine incorporation in primary meningioma cultures in a dose-dependent manner: 1 ng/mL, 5 ng/mL, and 10 ng/mL resulted in 21%, 43%, and 176%, respectively, above baseline.

Based on the above study, McCutcheon et al<sup>56</sup> took 15 human meningioma tumors and implanted them into the flanks of nude mice. They showed that after 8 weeks, the mean tumor volume of the pegvisomant group was  $198.3 \pm 18.9 \text{ mm}^3$  vs  $350.1 \pm 23.5 \text{ mm}^3$  for the control group ( $P < .001$ ). The serum IGF-I concentration in the control group was  $319 \pm 12.9 \mu\text{g/L}$  compared with  $257 \pm 9.7 \mu\text{g/L}$  in the pegvisomant group ( $P < .02$ ). The effects noted in this in vivo tumor model were most likely due to both the decrease in circulating IGF-I and the direct blockade of meningioma tumor growth hormone receptors. Furthermore, clinical trials have studied the treatment of acromegaly with pegvisomant and have shown that this drug is well tolerated by patients.<sup>57,58</sup>

## Somatostatin Agonist

Somatostatin receptors are present on meningiomas in high density, and the addition of somatostatin in vitro inhibits meningioma cell proliferation.<sup>59,60</sup> Schulz et al<sup>60</sup> developed a panel of somatostatin receptor subtype-specific antibodies that showed a high expression of the sst2A subtype on 40 randomly select-

ed meningiomas (29 [70%] of 40 meningiomas were sst2A positive). In contrast, all other somatostatin receptors were noted to stain weakly and sporadically. Based on these data, a prospective study of 16 surgically resected meningiomas was undertaken, and the level of sst2A expression was determined using Western blot analysis. The somatostatin sst2A subtype was readily detectable as a broad band migrating at Mr 70,000 in 12 (75%) of these 16 tumors; 8 tumors (50%) showed particularly high levels of immunoreactive sst2A receptors. There was an excellent correlation ( $P < .001$ ) between the level of sst2A protein expression detected in Western blots and the sst2A-immunoreactive staining seen in tissue sections. The authors suggested that this immunohistochemical method could prove useful in identifying recurrent meningiomas that may respond to therapy with sst2-selective agonists.

Garcia-Luna et al<sup>59</sup> reported on the clinical use of octreotide, a long-acting somatostatin agonist, in 3 patients with unresectable meningiomas. Doses used were gradually increased up to 1000, 900, and 1500  $\mu\text{g}/24$  hours during 16, 6, and 7 weeks, respectively. Patient tolerance to the drug was excellent, with abdominal discomfort and diarrhea observed in only 1 patient. Findings included the subjective improvement of headache in 2 patients and objective transient improvement in ocular movements in 1 patient. In all cases, computed tomography scans observed no change in meningioma size. This report confirms the safety of octreotide but is too small to draw any meaningful conclusions.

### *Growth Factor Receptor Inhibitors*

The growth of human cerebral meningiomas in culture is increased by various growth factors, including epidermal growth factor (EGF), TGF- $\alpha$  and TGF- $\beta$ , platelet-derived growth factor (PDGF)-BB, IGF-I and -II, and acidic and basic fibroblast growth factors. These factors may act in a paracrine and/or autocrine fashion to incite cell proliferation. Several studies have looked at disruption of growth-hormone-induced meningioma cell growth, including the growth hormone scavenger suramin, the PDGF antagonist trapidil, and inhibition of EGF-induced proliferation by bromocriptine.

Suramin scavenges exogenous growth factor, preventing the binding of a variety of growth factors to their receptors and inhibiting paracrine- and/or autocrine-mediated cell growth. Schrell et al<sup>61</sup> tested the ability of suramin to inhibit growth-factor-induced meningioma proliferation in cell culture. They noted a 40% to 70% reduction in cellular proliferation and abolishment of growth factor-induced proliferation (EGF, IGF-I, and PDGF-BB) with the addition of

suramin. Five tumor samples were studied using DNA flow cytometry. Suramin-arrested cells were observed in the S and G<sub>2</sub>/M phases of the cell cycle. Western blot analysis of 3 tumors showed a significant decrease in the amount of intracellular content of PDGF-BB after suramin treatment. Suramin also prevented the binding of iodinated growth factors (ie, <sup>125</sup>I-EGF, <sup>125</sup>I-IGF-I, and <sup>125</sup>I-PDGF-BB) to their respective receptors. These findings prove that suramin has the ability to inhibit autocrine loops (ie, lowering of intracellular PDGF-BB) and paracrine loops (ie, inhibiting cell growth). Suramin may control meningioma proliferation in patients with recurrent meningiomas.

Meningioma cells secrete PDGF, which stimulates their own growth in an autocrine manner. Based on this finding, trapidil, a drug known to have an antagonistic action against PDGF, was used to show a dose-dependent inhibition of cultured meningioma cell proliferation in the absence of any exogenous mitogenic stimulation. The maximum effect was observed at a concentration of 100  $\mu\text{g}/\text{mL}$ , with the decrease in cell growth ranging from 16% to 54% compared with control samples. Trapidil similarly inhibited the basal DNA synthesis assessed by [<sup>3</sup>H]-thymidine incorporation in 3 of 7 meningiomas. While the conditioned medium generated from meningioma cells remarkably stimulated the proliferation of meningioma cells (166% to 277% of control), this effect was strikingly inhibited by the addition of trapidil. Trapidil also inhibited conditioned medium-stimulated DNA synthesis, even when there was no effect on basal DNA synthesis. Furthermore, trapidil significantly inhibited the EGF-stimulated proliferation of meningioma cells. This inhibitory effect on EGF-stimulated cell demonstrates that trapidil is not an antagonist specific to PDGF. The addition of trapidil (30  $\mu\text{g}/\text{mL}$ ) in combination with bromocriptine (1  $\mu\text{m}$ ) showed an additive inhibitory effect on the meningioma cell growth compared with trapidil or bromocriptine alone. The overall results suggest that trapidil exhibits an inhibitory effect on meningioma cell proliferation by blocking the mitogenic stimulation induced by autocrine or exogenous growth factors, and it may be considered as a possible new approach to the medical treatment of meningiomas.<sup>62</sup>

### *Signal Transduction Pathway Inhibition*

The growth of meningiomas in culture and the potent growth stimulation of meningioma cells by EGF and PDGF are inhibited by calcium channel antagonists.<sup>63,64</sup> These studies arose out of the observation that calcium is an integral component of the intracellular signaling pathways. It was hypothesized that calcium channel antagonists might interrupt this signaling with subsequent growth inhibition. Inter-



estingly, these studies and others concluded that the activity of the calcium channel antagonist agents had nothing to do with calcium signaling.<sup>65,66</sup> Nevertheless, these studies were expanded into animal studies. A protocol was developed to allow for the growth of meningiomas in a xenograft model.<sup>67</sup> Animals with subcutaneous flank meningiomas were treated with verapamil and diltiazem. Serum drug levels of these medications verified that the drugs were reaching concentrations that would be found in patients being treated for hypertension. Growth inhibition was observed, but the results were modest. No long-term "cures" were found.<sup>68</sup> There is evidence that calcium channel antagonists can potentiate the effects of chemotherapeutic drugs. Human glioma tumor growth is inhibited by verapamil alone and more dramatically in combination with the chemotherapeutic agent 1,3-bis(2-chloroethyl)-1-nitrosourea (BCNU) both in vitro and in vivo.<sup>69</sup> In fact, the cytotoxicity of many different standard anticancer agents is augmented by calcium channel antagonists in a number of tumor cell types.<sup>66,70-74</sup> Currently, we are investigating whether calcium channel antagonists coupled with the two chemotherapeutic agents most commonly used for the treatment of meningioma (hydroxyurea and RU486) might comprise a more effective treatment for growth inhibition of meningiomas.

### *Mitogen-Associated Protein Kinase Inhibition*

Platelet-derived growth factor may act as an autocrine/paracrine stimulator of meningioma growth. PDGF-BB has been shown to stimulate DNA synthesis in human meningioma cell lines.<sup>75</sup> Johnson et al<sup>75</sup> explored the intracellular pathways by which PDGF exerts its mitogenic effects by performing Western blot analysis for mitogen-associated protein kinase (MAPK). MAPKs are a family of serine/threonine kinases implicated in the regulation of cell proliferation and are thought to be part of the kinase cascade that transduces receptor signals. Activation by growth factor tyrosine kinases phosphorylates and activates MAPK, which enters the cell nucleus to phosphorylate numerous proteins including transcription factors, RNA polymerase II, and cytoskeletal proteins. These investigators performed Western blot analysis on cultured human meningioma cells to show that MAPK and phosphorylated (activated) MAPK were present. The authors found that treatment with PD098059 (a selective inhibitor of MAPK phosphorylation/activation) on proliferating meningioma cells stimulated with 10% fetal bovine serum produced a 52% to 84% loss in [<sup>3</sup>H]-thymidine incorporation. Also, PD098059-treated meningioma cells showed partial or complete loss of phosphorylated MAPK after 3 days of treatment. The addition of PDGF-BB to meningioma cell cultures resulted in

an increase in [<sup>3</sup>H]-thymidine incorporation and phosphorylation of MAPK. Coadministration of PD098059 completely blocked PDGF-BB's stimulation of [<sup>3</sup>H]-thymidine incorporation and cell proliferation along with reduced MAPK phosphorylation. These findings indicate that MAPK is expressed in meningioma cells and transduces mitogenic signals of PDGF, thereby contributing to the growth of human meningiomas.

### *Gene Therapy*

Gene therapy is an emerging technology that offers a therapeutic option for incurable brain tumors. Chauvet et al<sup>76</sup> successfully infected a canine meningioma with a recombinant adenovirus vector via selective intra-arterial injection. Specific targets for gene therapies in patients afflicted with meningiomas associated with neurofibromatosis type 2 (NF2) is transfection with merlin, the wild-type NF2 gene. Ikeda et al<sup>77</sup> showed the feasibility of gene transfer by infecting the wild-type NF2 transgene into human meningioma tumors excised from patients with and without NF2, using a herpes simplex virus. Western blot analysis confirmed that vector-mediated gene transfer mediated the expression of the NF2-encoded polypeptide merlin and that overexpression of merlin significantly inhibited the growth of both NF2-negative and NF2-positive human meningioma cells when compared with controls. Dirven et al<sup>78</sup> proved that the adenovirus viral vector could be altered to target specific tumor receptors on meningiomas, thus enhancing gene transfer.

### *Conclusions*

Complete surgical resection is the first-line therapy for meningiomas. However, tumor location and biological aggressiveness can make a "surgical cure" impossible. Treatment options for these refractory meningiomas include further surgery, conventional external beam irradiation, stereotactic radiosurgery, and systemic therapies. Tumor location, atypical or malignant histologic subtypes, and staining for the Ki-67 protein (MIB-1 antibody) with a high labeling index are the best predictors of tumor recurrence. Novel systemic treatment options include angiogenesis inhibition, meningioma cell growth inhibition, blockade of growth factor effects, inhibition of intracellular secondary pathways, and gene therapies. Currently, the best-studied systemic treatment for patients with refractory meningiomas is hydroxyurea. Blockade of the growth hormone receptor by pegvisomant may soon hold a role because in vivo and in vitro studies have shown good results and pegvisomant has a known side effect profile. Long-term therapies holding promise include calcium channel blockers and gene therapies.

## References

1. Carroll RS, Zhang J, Black PM. Expression of estrogen receptors alpha and beta in human meningiomas. *J Neurooncol*. 1999;42:109-116.
2. Gonzales ME. Classification of brain tumors. In: Kaye AH, Laws ER, eds. *Brain Tumors: An Encyclopedic Approach*. Edinburgh, New York: Churchill Livingstone; 1995:675.
3. Simpson D. The recurrence of intracranial meningiomas after surgical treatment. *J Neurol Neurosurg Psychiatry*. 1957;20:22-39.
4. Mirmanoff RO, Dosoretz DE, Linggood RM, et al. Meningioma: analysis of recurrence and progression following neurosurgical resection. *J Neurosurg*. 1985;62:18-24.
5. Mahmood A, Caccamo DV, Tomecek FJ, et al. Atypical and malignant meningiomas: a clinicopathological review. *Neurosurgery*. 1993;33:955-963.
6. Jaaskelainen J, Haltia M, Servo A. Atypical and anaplastic meningiomas: radiology, surgery, radiotherapy, and outcome. *Surg Neurol*. 1986;25:233-242.
7. Milosevic ME, Frost PJ, Laperriere NJ, et al. Radiotherapy for atypical or malignant intracranial meningioma. *Int J Radiat Oncol Biol Phys*. 1996;34:817-822.
8. Goldsmith BJ, Wara WM, Wilson CB, et al. Postoperative irradiation for subtotally resected meningiomas: a retrospective analysis of 140 patients treated from 1967 to 1990. *J Neurosurg*. 1994;80:195-201.
9. Rosenthal MA, Ashley DL, Cher L. Treatment of high risk or recurrent meningiomas with hydroxyurea. *J Clin Neurosci*. 2002;9:156-158.
10. Hug EB, Devries A, Thornton AF, et al. Management of atypical and malignant meningiomas: role of high-dose, 3D-conformal radiation therapy. *J Neurooncol*. 2000;48:151-160.
11. Barnett GH, Suh JH, Crownover RL. Recent advances in the treatment of skull base tumors using radiation. *Neurosurg Clin N Am*. 2000;11:587-596.
12. Schrell UM, Rittig MG, Anders M. Hydroxyurea for treatment of unresectable and recurrent meningiomas. II. Decrease in the size of meningiomas in patients treated with hydroxyurea. *J Neurosurg*. 1997;86:840-844.
13. Mason WP, Gentili F, Macdonald DR, et al. Stabilization of disease progression by hydroxyurea in patients with recurrent or unresectable meningioma. *J Neurosurg*. 2002;97:341-346.
14. Blankenstein MA, Verheijen FM, Jacobs JM, et al. Occurrence, regulation, and significance of progesterone receptors in human meningioma. *Steroids*. 2000;65:795-800.
15. Cohen ME, Duffner PK. Long-term consequences of CNS treatment for childhood cancer, Part I: Pathologic consequences and potential for oncogenesis. *Pediatr Neurol*. 1991;7:157-163.
16. Shintani T, Hayakawa N, Hoshi M, et al. High incidence of meningioma among Hiroshima atomic bomb survivors. *Radiat Res (Tokyo)*. 1999;40:49-57.
17. Evans DG, Sainio M, Baser ME. Neurofibromatosis type 2. *J Med Genet*. 2000;37:897-904.
18. Cai DX, Banerjee R, Scheithauer BW, et al. Chromosome 1p and 14q FISH analysis in clinicopathologic subsets of meningioma: diagnostic and prognostic implications. *J Neuropathol Exp Neurol*. 2001;60:628-636.
19. Bostrom J, Meyer-Puttlitz B, Wolter M, et al. Alterations of the tumor suppressor genes CDKN2A (p16(INK4a)), p14(ARF), CDKN2B (p15(INK4b)), and CDKN2C (p18(INK4c)) in atypical and anaplastic meningiomas. *Am J Pathol*. 2001;159:661-669.
20. Lopez-Gines C, Cerda-Nicolas M, Gil-Benso R, et al. Loss of 1p in recurrent meningiomas. A comparative study in successive recurrences by cytogenetics and fluorescence in situ hybridization. *Cancer Genet Cytogenet*. 2001;125:119-124.
21. Nakasu S, Li DH, Okabe H, et al. Significance of MIB-1 staining indices in meningiomas: comparison of two counting methods. *Am J Surg Pathol*. 2001;25:472-478.
22. Ho DM, Hsu CY, Ting LT, et al. Histopathology and MIB-1 labeling index predicted recurrence of meningiomas: a proposal of diagnostic criteria for patients with atypical meningioma. *Cancer*. 2002;94:1538-1547.
23. Lanzafame S, Torrisi A, Barbagallo G, et al. Correlation between histological grade, MIB-1, p53, and recurrence in 69 completely resected primary intracranial meningiomas with a 6 year mean follow-up. *Pathol Res Pract*. 2000;196:483-488.
24. Korshunov A, Shishkina L, Golanov A. DNA topoisomerase II-alpha and cyclin A immunoreactivity in meningiomas and its prognostic significance: an analysis of 263 cases. *Arch Pathol Lab Med*. 2002;126:1079-1086.
25. Perry A, Stafford SL, Scheithauer BW, et al. The prognostic significance of MIB-1, p53, and DNA flow cytometry in completely resected primary meningiomas. *Cancer*. 1998;82:2262-2269.
26. Kamei Y, Watanabe M, Nakayama K, et al. Prognostic significance of p53 and p21WAF1/CIP1 immunoreactivity and tumor micronecrosis for recurrence of meningiomas. *J Neurooncol*. 2000;46:205-213.
27. Abramovich CM, Prayson RA. Apoptotic activity and bcl-2 immunoreactivity in meningiomas. Association with grade and outcome. *Am J Clin Pathol*. 2000;114:84-92.
28. Comtesse N, Heckel D, Racz A, et al. Five novel immunogenic antigens in meningioma: cloning, expression analysis, and chromosomal mapping. *Clin Cancer Res*. 1999;5:3560-3568.
29. Weisberg S, Ashkenazi E, Israel Z, et al. Anaplastic and atypical meningiomas express high levels of Fas and undergo apoptosis in response to Fas ligation. *Am J Pathol*. 2001;159:1193-1197.
30. Kilic T, Bayri Y, Ozduman K, et al. Tenascin in meningioma: expression is correlated with anaplasia, vascular endothelial growth factor expression, and peritumoral edema but not with tumor border shape. *Neurosurgery*. 2002;51:183-193.
31. Miralbell R, Linggood RM, de la Monte S, et al. The role of radiotherapy in the treatment of subtotally resected benign meningiomas. *J Neurooncol*. 1992;13:157-164.
32. Barbaro NM, Gutin PH, Wilson CB, et al. Radiation therapy in the treatment of partially resected meningiomas. *Neurosurgery*. 1987;20:525-528.
33. Lee JY, Niranjan A, McInerney J, et al. Stereotactic radiosurgery providing long-term tumor control of cavernous sinus meningiomas. *J Neurosurg*. 2002;97:65-72.
34. Sartor O, Figg WD. Mifepristone: antineoplastic studies. *Clin Obstet Gynecol*. 1996;39:498-505.
35. Olson JJ, Beck DW, Schlechte J, et al. Hormonal manipulation of meningiomas in vitro. *J Neurosurg*. 1986;65:99-107.
36. Matsuda Y, Kawamoto K, Kiya K, et al. Antitumor effects of antiprogesterones on human meningioma cells in vitro and in vivo. *J Neurosurg*. 1994;80:527-534.
37. Olson JJ, Beck DW, Schlechte JA, et al. Effect of the antiprogesterone RU-38486 on meningioma implanted into nude mice. *J Neurosurg*. 1987;66:584-587.
38. Koper JW, Foekens JA, Braakman R, et al. Effects of progesterone on the response to epidermal growth factor and other growth factors in cultured human meningioma cells. *Cancer Res*. 1990;50:2604-2607.
39. Grunberg SM, Weiss MH, Spitz IM, et al. Treatment of unresectable meningiomas with the antiprogesterone agent mifepristone. *J Neurosurg*. 1991;74:861-866.
40. Grunberg SM. Role of antiprogesterone therapy for meningiomas. *Human Reprod*. 1994;9(suppl 1):202-207.
41. Lamberts SW, Tanghe HL, Avezaat CJ, et al. Mifepristone (RU 486) treatment of meningiomas. *J Neurol Neurosurg Psychiatry*. 1992;55:486-490.
42. Hanahan D, Folkman J. Patterns and emerging mechanisms of the angiogenic switch during tumorigenesis. *Cell*. 1996;86:353-364.
43. Folkman J, Ingber D. Inhibition of angiogenesis. *Semin Cancer Biol*. 1992;3:89-96.
44. Kaba SE, De Monte F, Bruner JM, et al. The treatment of recurrent unresectable and malignant meningiomas with interferon alpha-2B. *Neurosurgery*. 1997;40:271-275.
45. Koper JW, Zwarthoff EC, Hagemeyer A, et al. Inhibition of the growth of cultured human meningioma cells by recombinant interferon-alpha. *Eur J Cancer*. 1991;27:416-419.
46. Zhang ZI, Muhr C, Wang JL. Interferon-alpha inhibits the DNA synthesis induced by PDGF and EGF in cultured meningioma cells. *Anticancer Res*. 1996;16:717-723.
47. Wober-Bingol C, Wober C, Marosi C, et al. Interferon-alfa-2b for meningioma. *Lancet*. 1995;345:331.
48. Muhr C, Gudjonsson O, Lilja A, et al. Meningioma treated with interferon-alpha, evaluated with [(11)C]-L-methionine positron emis-

sion tomography. *Clin Cancer Res.* 2001;7:2269-2276.

49. Yazaki T, Takamiya Y, Castello PC, et al. Inhibition of angiogenesis and growth of human non-malignant and malignant meningiomas by TNP-470. *J Neurooncol.* 1995;23:23-29.

50. Bek EL, McMillen MA. Endothelins are angiogenic. *J Cardiovasc Pharmacol.* 2000;36(5 suppl 1):S135-S139.

51. Harland SP, Kuc RE, Pickard JD, et al. Expression of endothelin(A) receptors in human gliomas and meningiomas, with high affinity for the selective antagonist PD156707. *Neurosurgery.* 1998;43:890-899.

52. Salthia B, Rutka JT, Lingwood C, et al. The treatment of malignant meningioma with verotoxin. *Neoplasia.* 2002;4:304-311.

53. Lawrence JH, Tobias CA, Linfoot JA, et al. Successful treatment of acromegaly: metabolic and clinical studies in 145 patients. *J Clin Endocrinol Metab.* 1970;31:180-198.

54. Khandwala HM, McCutcheon IE, Flyvbjerg A, et al. The effects of insulin-like growth factors on tumorigenesis and neoplastic growth. *Endocr Rev.* 2000;21:215-244.

55. Friend KE. Cancer and the potential place for growth hormone receptor antagonist therapy. *Growth Horm IGF Res.* 2001;11(suppl A):S121-S123.

56. McCutcheon IE, Flyvbjerg A, Hill H, et al. Antitumor activity of the growth hormone receptor antagonist pegvisomant against human meningiomas in nude mice. *J Neurosurg.* 2001;94:487-492.

57. Trainer PJ, Drake WM, Katznelson L, et al. Treatment of acromegaly with the growth hormone receptor antagonist pegvisomant. *N Engl J Med.* 2000;342:1171-1177.

58. van der Lely AJ, Hutson RK, Trainer PJ, et al. Long-term treatment of acromegaly with pegvisomant, a growth hormone receptor antagonist. *Lancet.* 2001;358:1754-1759.

59. Garcia-Luna PP, Relimpio F, Pumar A, et al. Clinical use of octreotide in unresectable meningiomas: a report of three cases. *J Neurosurg Sci.* 1993;37:237-241.

60. Schulz S, Pauli SU, Schulz S, et al. Immunohistochemical determination of five somatostatin receptors in meningioma reveals frequent overexpression of somatostatin receptor subtype sst2A. *Clin Cancer Res.* 2000;6:1865-1874.

61. Schrell UM, Gauer S, Kieswetter F et al. Inhibition of proliferation of human cerebral meningioma cells by suramin: effects on cell growth, cell cycle phases, extracellular growth factors, and PDGF-BB autocrine growth loop. *J Neurosurg.* 1995;82:600-607.

62. Todo T E, Adams F, Fahlbusch R. Inhibitory effect of trapidil on human meningioma cell proliferation via interruption of autocrine growth stimulation. *J Neurosurg.* 1993;78:463-469.

63. Jensen RL, Lee YS, Guijtrati M, et al. Inhibition of in vitro meningioma proliferation after growth factor stimulation by calcium channel antagonists. Part II: Additional growth factors, growth factor receptor immunohistochemistry, and intracellular calcium measurements. *Neurosurgery.* 1995;37:937-947.

64. Jensen RL, Origitano TC, Lee YS, et al. In vitro growth inhibition of growth factor-stimulated meningioma cells by calcium channel antagonists. *Neurosurgery.* 1995;36:365-374.

65. Jensen RL, Petr M, Wurster RD. Calcium channel antagonist effect on in vitro meningioma signal transduction pathways after growth factor stimulation. *Neurosurgery.* 2000;46:692-703.

66. Merry S, Fetherston CA, Kaye SB, et al. Resistance of human glioma to adriamycin in vitro: the role of membrane transport and its circumvention with verapamil. *Br J Cancer.* 1986;53:129-135.

67. Jensen RL, Leppla D, Rokosz N, et al. Matrigel augments xenograft transplantation of meningioma cells into athymic mice. *Neurosurgery.* 1998;42:130-136.

68. Jensen RL, Wurster RD. Calcium channel antagonists inhibit growth of subcutaneous xenograft meningiomas in nude mice. *Surg Neurol.* 2001;55:275-283.

69. Bowles AP Jr, Pantazis CG, Wansley W. Use of verapamil to enhance the antiproliferative activity of BCNU in human glioma cells: an in vitro and in vivo study. *J Neurosurg.* 1990;73:248-253.

70. Cano-Gauci DF, Riordan JR. Action of calcium antagonists on multidrug resistant cells: specific cytotoxicity independent of increased cancer drug accumulation. *Biochem Pharmacol.* 1987;36: 2115-2123.

71. Helson L. Calcium channel blocker enhancement of anti-cancer drug cytotoxicity: a review. *Cancer Drug Deliv.* 1984;1:353-361.

72. Ince P, Appleton DR, Finney KH, et al. Verapamil increases the sensitivity of primary human colorectal carcinoma tissue to vincristine. *Br J Cancer.* 1986;53:137-139.

73. Robinson BA, Clutterbuck RD, Millar JL, et al. Verapamil potentiation of melphalan cytotoxicity and cellular uptake in murine fibrosarcoma and bone marrow. *Br J Cancer.* 1985;52:813-822.

74. Tsuruo T, Iida H, Tsukagoshi S, et al. Overcoming of vincristine resistance in P388 leukemia in vivo and in vitro through enhanced cytotoxicity of vincristine and vinblastine by verapamil. *Cancer Res.* 1981;41:1967-1972.

75. Johnson MD, Woodard A, Kim P, et al. Evidence for mitogen-associated protein kinase activation and transduction of mitogenic signals by platelet-derived growth factor in human meningioma cells. *J Neurosurg.* 2001;94:293-300.

76. Chauvet AE, Kesava PP, Goh CS, et al. Selective intraarterial gene delivery into a canine meningioma. *J Neurosurg.* 1998;88:870-873.

77. Ikeda K, Saeki Y, Gonzalez-Agosti C, et al. Inhibition of NF2-negative and NF2-positive primary human meningioma cell proliferation by overexpression of merlin due to vector-mediated gene transfer. *J Neurosurg.* 1999;91:85-92.

78. Dirven CM, Grill J, Lamfers ML, et al. Gene therapy for meningioma: improved gene delivery with targeted adenoviruses. *J Neurosurg.* 2002;97:441-449.