

## Mechanisms of deaths in captive juvenile New Zealand fur seals (*Arctocephalus forsteri*)

Roger W. Byard · Aaron Machado ·  
Kerry Braun · Lucian B. Solomon ·  
Wayne Boardman

Accepted: 11 May 2010 / Published online: 25 May 2010  
© Springer Science+Business Media, LLC 2010

**Abstract** Juvenile seals are sometimes encountered in waters around South Australia with injuries and/or diseases that require veterinary treatment. Two cases are reported where apparently stable animals died soon after being rescued due to quite disparate conditions. In Case 1 a juvenile male New Zealand fur seal (*Arctocephalus forsteri*) was found unexpectedly dead in its enclosure. A necropsy examination revealed an emaciated juvenile male with no injuries. The intestine was filled throughout its length with melena stool that was due to heavy infestation of the stomach with roundworms with adjacent gastritis. Death was due to shock from upper gastrointestinal blood loss secondary to parasitosis. In Case 2 a second juvenile male New Zealand fur seal (*Arctocephalus forsteri*) also died unexpectedly in its enclosure. It had been

listless with loud respirations since capture. At necropsy there was no blood around the head, neck or mouth, and no acute external injuries were identified. An area of induration was, however, present over the snout with fragmentation of underlying bones. The maxilla was freely mobile and CT scanning revealed multiple comminuted fractures of the adjacent facial skeleton. Examination of the defleshed skull showed fragmentation of the facial skeleton with roughening of bones in keeping with osteomyelitis. Death was attributed to sepsis from osteomyelitis of a comminuted midfacial fracture. These cases demonstrate two unusual and occult conditions that may be present in recently retrieved juvenile fur seals. Failure to establish the correct diagnosis rapidly may result in death soon after capture. The usefulness of imaging techniques such as CT scanning in delineating underlying injuries prior to necropsy is clearly demonstrated.

R. W. Byard (✉) · L. B. Solomon  
Discipline of Anatomy and Pathology, The University of  
Adelaide, Level 3 Medical School North Building, Frome Road,  
Adelaide, SA 5005, Australia  
e-mail: roger.byard@sa.gov.au

R. W. Byard  
Forensic Science SA, 21 Divett Place, Adelaide, SA 5000,  
Australia

A. Machado · K. Braun  
Australian Marine Wildlife Research and Rescue Organization,  
Port Adelaide, SA, Australia

L. B. Solomon  
Discipline of Orthopaedics and Trauma, The University of  
Adelaide, Royal Adelaide Hospital, North Terrace, Adelaide,  
SA 5000, Australia

W. Boardman  
Royal Zoological Society of South Australia, Adelaide,  
SA, Australia

**Keywords** New Zealand fur seal · Death · Parasitosis · Hemorrhage · Osteomyelitis · Fracture · Blunt trauma

### Introduction

Sudden and unexpected death in all species may result from a variety of natural diseases and inflicted or non-inflicted injuries. Unfortunately the symptoms and signs of many of these conditions may be quite nonspecific. A problem, therefore, with recently rescued animals is in establishing the underlying cause of clinical manifestations rapidly, so that appropriate treatment can be initiated. Two cases of sudden death in juvenile male New Zealand fur seals (*Arctocephalus forsteri*) are reported to demonstrate the range of occult conditions that may be present in recently retrieved animals, and the usefulness of imaging

with necropsy assessment in establishing the cause and mechanism of death.

## Case reports

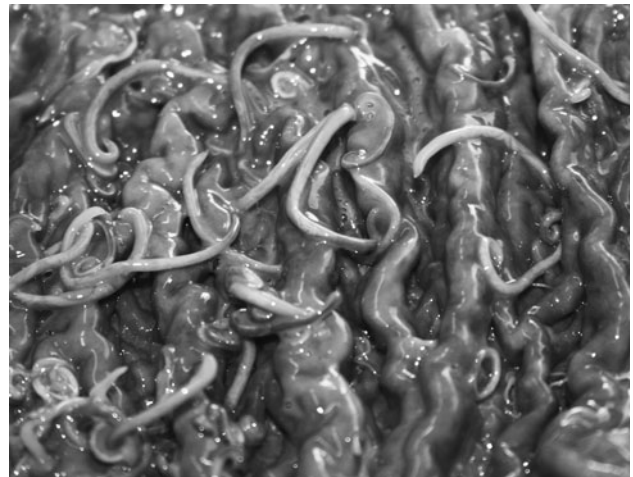
### Case 1

A juvenile male New Zealand fur seal (*Arctocephalus forsteri*) was found in an emaciated condition at a beach south of Adelaide, South Australia. He was taken to the Australian Marine Wildlife Research and Rescue Organization for assessment and treatment. On admission he was dehydrated, weighing 10.5 kg, and was administered 400 ml of subcutaneous normal saline. Around 1,400 h during the second day of captivity he was found unexpectedly dead at the waters edge of his enclosure, having been responsive and feeding that morning. Melena stool was noted.

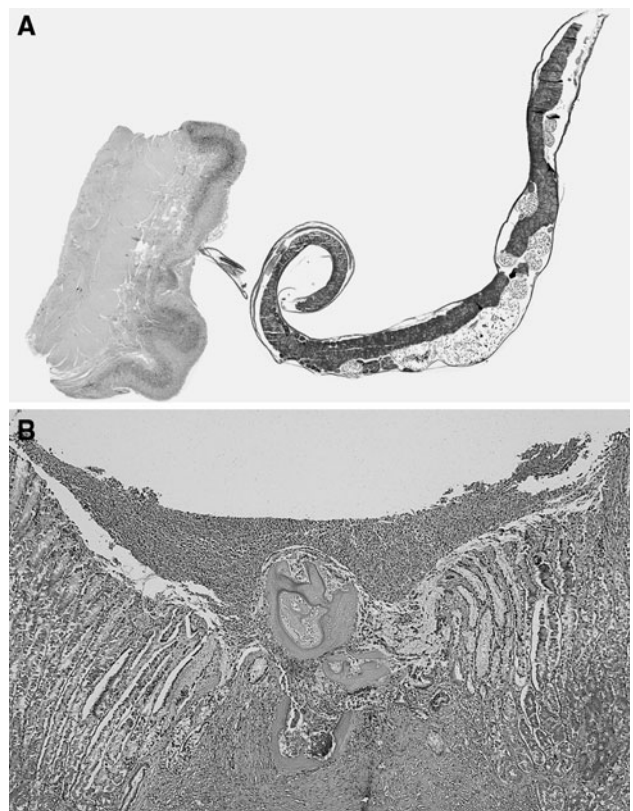At necropsy the body was that of a thin juvenile New Zealand fur seal. The only evidence of trauma consisted of superficial lacerations of the webbing of both hind flippers. Melena stool was noted around the anus. Internal examination revealed minimal subcutaneous fat with normal positioning of internal organs. The peritoneal cavity was unremarkable with normal appearing intestines. Specifically there was no ischemic necrosis, internal herniation, volvulus or intussusception. The colon and small intestine were opened in their entirety revealing normal intestinal mucosa with no colitis. Melena stool was present extending from the duodenum to the rectum. The major findings involved the stomach that was filled with hundreds of roundworms (*Anisakis spp.*), many of which were still attached to the gastric mucosa (Fig. 1). The mucosa appeared reddened and there were numerous punctate erosions where worms had detached. Granular material was present within the submucosa and mucosa that represented shed material from the nematodes. Occasional nematodes were also present attached to the lower esophageal mucosa. The chest cavity and organs were unremarkable and there was no evidence of intracerebral hemorrhage. Histology confirmed attachment of worms to the gastric mucosa with adjacent acute gastritis and superficial ulceration (Fig. 2). Death was, therefore, due to upper gastrointestinal hemorrhage complicating gastric parasitosis.

### Case 2

A second juvenile male New Zealand fur seal (*Arctocephalus forsteri*) was found in an emaciated condition in the Port River Estuary, northwest of Adelaide, South Australia. He was taken to the Australian Marine Wildlife Research and Rescue Organization for assessment and

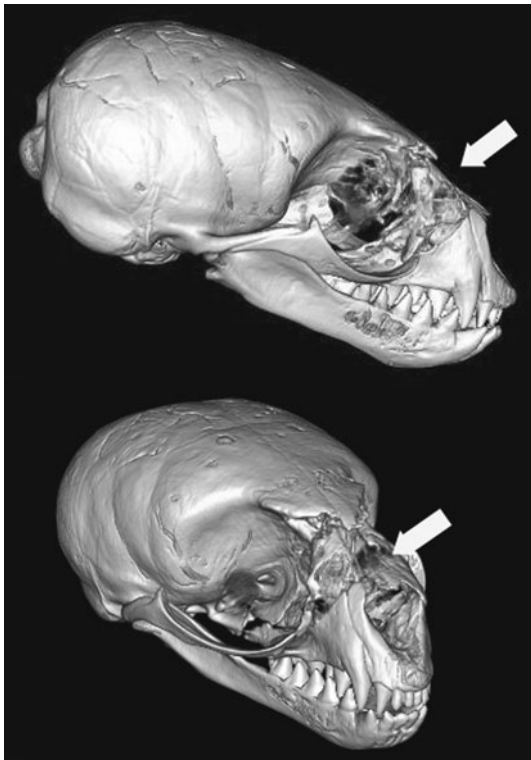


**Fig. 1** Close up view of roundworms in the stomach of a juvenile male New Zealand fur seal (*Arctocephalus forsteri*) associated with significant hemorrhage (case 1)



**Fig. 2** Whole mount view of a single attached roundworm in the stomach in case 1 (a). Histology of the gastric mucosa demonstrating remnants of a roundworm with surrounding ulceration and erosion into superficial blood vessels (b). (Hematoxylin & eosin,  $\times 100$ )

treatment. On admission he weighed 6.1 kg and was administered 400 ml of subcutaneous normal saline. The animal was noted to be breathing heavily through his mouth and making unusual sounds. In addition he



**Fig. 3** Two CT views of the skull from case 2 showing extensive comminuted fracturing of the midfacial skeleton (*arrows*)

occasionally would bite at the cage and his rear flank. He died soon after admission.

At necropsy the body was that of a thin juvenile New Zealand fur seal with no external evidence of trauma except a possible healed laceration over an indurated and unusually mobile area of the snout. Specifically, the anterior facial skeleton appeared separate from the remainder of the skull. A head CT was performed before necropsy. One mm transverse scans were taken on an Aquilion 64 slice CT scanner (Toshiba Medical System Corporation, Japan), and reconstructions were performed on a Vitrea 4.0 workstation (Minnetonka, Minnesota, USA). The scans demonstrated a comminuted fracture of the facial skeleton involving the nasal bones, the maxilla and zygomas in a cranio-caudal and supero-inferior direction from the face, and crossing the nasal cavities, inferior orbital floors and maxillary sinuses to exit through the palate (Fig. 3). The lower jaw was intact.

Dissection of soft tissues from the facial skeleton confirmed the presence of the facial fractures including fragments of shattered bone without evidence of recent hemorrhage. After defleshing the central facial skeleton collapsed. Irregular areas of reactive bone around the edges of the fractures were in keeping with osteomyelitis (Fig. 4). Death was therefore attributed to sepsis complicating



**Fig. 4** Defleshed skull from case 2 showing loss of the mid facial skeleton due to comminuted fracturing

osteomyelitis arising from an extensive open fracture of the mid facial skeleton following blunt trauma.

## Discussion

Causes of hemorrhage from gastrointestinal lesions in humans vary with age, with diverticulitis and angiodysplasia occurring in older individuals, compared to Meckel diverticulum and intussusception in the young [1]. Parasites are usually not encountered as a cause of significant hemorrhage in human forensic practice, although *Strongyloides stercoralis* has been reported as a cause of life threatening duodenal hemorrhage [2], and the roundworm *Ascaris lumbricoides* has caused massive hematemesis in infancy due to duodenal ulceration and volvulus [3]. While hydatid disease often remains clinically occult, very rare cases have presented with massive lower gastrointestinal hemorrhage from splenic colic fistula [4, 5].

Seals are known to harbour intestinal parasites with the species of nematode varying depending on the species of seal. For example, 60% of Juan Fernandez fur seal pups (*Arctocephalus philippii*) in one study had hookworms (*Uncinaria sp.*) [6], with 100% of grey seals (*Halichoerus grypus*) in another study revealing the small intestinal helminth *Corynosoma strumosum* [7].

In the reported case the stomach was filled with hundreds of attached roundworms with superficial ulceration and acute gastritis. In a study of the gastric mucosa of a seal infested with *Contacaecum osculatum*, *Pseudoterranova decipiens* and *Anisakis simplex* the findings were similar, with congestion and hemorrhage, in addition to cellular infiltration and fibrosis [8]. The fact that the current case was under direct observation at the time of death

enabled the rapid nature of the terminal event to be accurately documented. It appeared that roundworm infestation had resulted in considerable emaciation of the young animal with evidence of continued hemorrhage in the form of melena throughout the small and large intestines. As in humans it is likely that terminal cardiovascular collapse was due to acute cardiac failure complicating acute chronic blood loss.

In the second case, the seal had sustained an injury to the facial skeleton from significant blunt trauma, but had managed to survive for some time, despite breathing and feeding difficulties, and likely considerable pain. The unhealed maxillary fracture would have prevented the animal from effectively biting and chewing and would have explained the emaciated state. It is likely that generalized sepsis from subsequent osteomyelitis initiated the terminal event, as there was no airway obstruction or underlying diseases identified at autopsy. The absence of oronasal hemorrhage, with healing of the skin over the maxillary fractures, in addition to the presence of reactive bone, were all in keeping with prolonged survival following trauma. The odd behaviour of the animal in captivity could be explained by pain associated with such a major injury. The nature of the trauma remains uncertain, however blunt impact would appear likely. If the injury occurred while the animal was in the water, the direction of the fracture and focal nature of the induration suggests that it occurred with the head in an upright position, and thus could have been due to a collision with a boat or the fins of a wind or kite surf. If the injury occurred while the animal was on the beach or in shallow water it could have been the result of impact with a blunt object. The use of CT scanning in this case provided an excellent method for identifying the precise nature of the facial skeletal fracture prior to formal necropsy dissection.

These cases demonstrate a variety of points. In the first case the significant effect that a large gastrointestinal parasite population may have on a juvenile animal was shown. While parasite load varies considerably among studies, the possibility of sudden and unexpected death must be considered when apparently stable but emaciated animals are being assessed. The very early administration of anti-helminth medication may be indicated. The second case demonstrates that juvenile seals may survive significant

facial trauma and still maintain feeding. The absence of evidence of acute trauma in a captured animal does not, therefore, exclude significant occult injury.

### Key points

1. Gastrointestinal parasitosis may cause significant hemorrhage in juvenile New Zealand fur seals (*Arctocephalus forsteri*) and result in sudden death.
2. Juvenile New Zealand fur seals (*Arctocephalus forsteri*) may survive significant facial trauma and still maintain feeding.
3. The absence of evidence of acute trauma in a captured seal does not exclude significant occult injury.
4. CT scanning is an excellent method for the identification of occult skeletal injury prior to necropsy.

### References

1. Byard RW, Simpson A. Sudden death and intussusception in infancy and childhood -autopsy considerations. *Med Sci Law*. 2001;41:41–5.
2. Bhatt BD, Cappell MS, Smilow PC, Das KM. Recurrent massive upper gastrointestinal hemorrhage due to *Strongyloides stercoralis* infection. *Am J Gastroenterol*. 1990;85:1034–6.
3. Sangkhathat S, Patrapinyokul S, Wudhisuthimethawee P, Chedphaopan J, Mitamun W. Massive gastrointestinal bleeding in infants with ascariasis. *J Pediatr Surg*. 2003;38:1696–8.
4. Byard RW. An analysis of possible mechanisms of unexpected death occurring in hydatid disease (echinococcosis). *J Forensic Sci*. 2009;54:919–22.
5. Teke Z, Yagci AB, Atalay AO, Kabay B. Splenic hydatid cyst perforating into the colon manifesting as acute massive lower gastrointestinal bleeding: an unusual presentation of disseminated abdominal echinococcosis. *Singapore Med J*. 2008;49:e113–6.
6. Sepúlveda MS. Hookworms (*Uncinaria* sp.) in Juan Fernandez fur seal pups (*Arctocephalus philippii*) from Alejandro Selkirk Island, Chile. *J Parasitol*. 1998;84:1305–7.
7. O'Neill G, Whelan J. The occurrence of *Corynosoma strumosum* in the grey seal *Halichoerus grypus*, caught off the Atlantic coast of Ireland. *J Helminthol*. 2002;76:231–4.
8. Ito M, Sato T, Shirai W, Kikuchi S. Parasites and related pathological lesions in the gastrointestinal tract of a seal (*Phoca vitulina* Linnaeus). *J Vet Med Sci*. 1998;60:1025–8.