

Contrast Sensitivity and Foveal Microstructure Following Vitrectomy for Epiretinal Membrane

Yoshimi Sugiura, Fumiki Okamoto, Yoshifumi Okamoto, Takahiro Hiraoka, and Tetsuro Oshika

Department of Ophthalmology, Faculty of Medicine, University of Tsukuba, Ibaraki, Japan

Correspondence: Yoshimi Sugiura, Department of Ophthalmology, Faculty of Medicine, University of Tsukuba, 1-1-1 Tennoudai, Tsukuba, Ibaraki, 305-8575 Japan; sugi_yoshimi@hotmail.com.

Submitted: January 26, 2014

Accepted: June 2, 2014

Citation: Sugiura Y, Okamoto F, Okamoto Y, Hiraoka T, Oshika T. Contrast sensitivity and foveal microstructure following vitrectomy for epiretinal membrane. *Invest Ophthalmol Vis Sci*. 2014;55:7594-7600. DOI: 10.1167/iovs.14-14035

PURPOSE. To evaluate contrast sensitivity (CS) in patients with epiretinal membrane (ERM) following vitrectomy and to investigate the relationship between CS and foveal microstructures with spectral-domain optical coherence tomography (SD-OCT).

METHODS. Thirty-one eyes of 31 patients with ERM were included. We examined CS with a CSV-1000E chart, a logMAR best-corrected visual acuity (BCVA), and foveal microstructure by using SD-OCT before and at 6 months after surgery. From the CS data, the area under the log contrast sensitivity function (AULCSF) was calculated. Based on the OCT images, we quantified the mean thickness of the ganglion cell layer (GCL), the inner nuclear layer (INL), and the outer retinal layer (outer nuclear layer and outer plexiform layer [ONL+OPL]). The status of the photoreceptor inner and outer segment junction (IS/OS) and external limiting membrane (ELM) was also evaluated.

RESULTS. Vitrectomy significantly improved logMAR BCVA and AULCSF. Even in patients with poor improvement of visual acuity (changes in logMAR BCVA by surgery was ≤ 0.2), postoperative AULCSF significantly increased by treatment ($P < 0.05$). Postoperative AULCSF showed a significant correlation with preoperative ($P < 0.05$) and postoperative ($P < 0.05$) ONL+OPL thickness, whereas other parameters were not relevant. Postoperative logMAR BCVA significantly correlated with postoperative status of IS/OS ($P < 0.05$) and preoperative ONL+OPL thickness ($P < 0.05$).

CONCLUSIONS. In patients with ERM, CS improved even though their visual acuity did not recover significantly by vitrectomy. CS was associated with the thickness of outer retinal layer.

Keywords: contrast sensitivity, epiretinal membrane, optical coherence tomography

Idiopathic epiretinal membrane (ERM) is a common disorder that occurs in 5.3% to 18.5% of the population.¹⁻⁴ The formation of ERM on the normal retinal surface and traction forces affect all retinal layers in various ways, resulting in a disturbed visual function.⁵ Those changes present significant symptoms including metamorphopsia, reduced visual acuity, and monocular diplopia. For patients with such symptoms, vitrectomy with ERM removal is performed as a standard treatment.

Favorable visual outcomes have been achieved in most ERM cases postoperatively.⁶⁻¹⁰ However, the conventional measures of visual acuity may be insufficient to analyze detailed changes in visual function that may be vital in patients' daily activities, because preoperative and postoperative visual acuity in patients with ERM is relatively good.

Contrast sensitivity (CS) is an index capable of assessing visual function more sensitively than visual acuity. There are some reports of patients with good visual acuity but poor CS such as in cases of keratoconus,¹¹ after laser in situ keratomileusis (LASIK),¹² and in cataract.¹³ CS is known to decrease in various retinal disorders such as age-related macular degeneration,^{14,15} rhegmatogenous retinal detachment,¹⁶ and diabetic macular edema.^{17,18} Previous studies reported that vision-related quality of life was associated with CS but not with visual acuity in patients after surgery for rhegmatogenous retinal detachment,¹⁹ diabetic macular edema,¹⁷ and proliferative diabetic retinopathy.²⁰

In recent years, critical insights have been obtained into various retinal conditions due to advances in optical coherence tomography (OCT) technology. Layer-by-layer evaluation of the retina has been made possible by spectral-domain OCT (SD-OCT) with its higher resolution and greater scanning speed. OCT can enhance the resolution so that retinal architectural morphology is seen more clearly than ever.²¹⁻²⁴ Studies using SD-OCT have revealed that visual acuity in ERM patients deteriorated due to thickening of the central macula, thickening of the outer retina, disruption of the photoreceptor inner and outer segment junction (IS/OS), external limiting membrane (ELM), and disruption of the cone outer segment tip.²⁵⁻²⁷ Similarly, inner nuclear layer (INL) thickness in ERM patients has been demonstrated to be associated with metamorphopsia.²⁸⁻³⁰ No reports so far, however, have addressed associations between CS and SD-OCT findings in patients with ERM. The purpose of this study was to investigate the relationship between CS and the foveal microstructure in patients with ERM before and after surgery.

METHODS

We included 31 eyes of 31 patients with unilateral, idiopathic ERM who were referred to Tsukuba University Hospital between January 2011 and June 2012 and were followed for 6 months after surgical treatment. The subjects were 17 males and 14 females, at a mean \pm SD average of 64.3 ± 11.1 years of

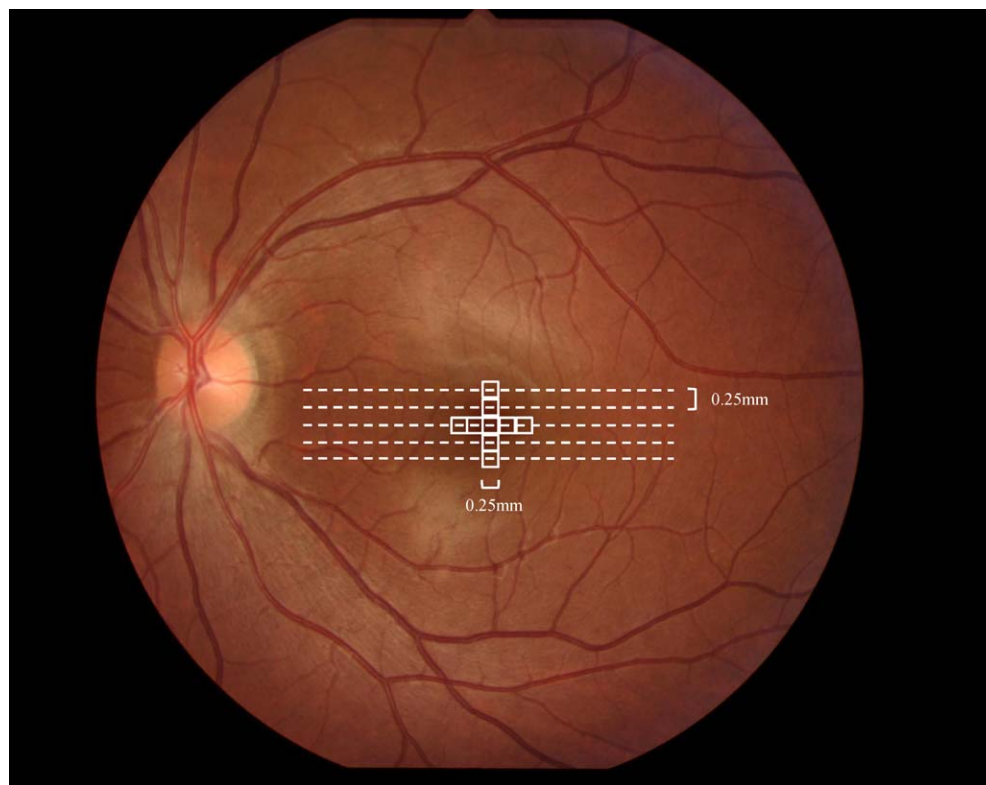


FIGURE 1. Schematic shows the measurement position of the thickness of each retinal layer and the degree of IS/OS and ELM disruption. Five *horizontal broken lines* represent scanning lines of five-line raster scans with SD-OCT. The 1.0- × 1.0-mm area centered on the fovea was divided into 9 sections at 0.25-mm intervals. Each retinal layer and degree of IS/OS and ELM disruption were measured at each section.

age. This study was approved by the Institutional Review Board at the Tsukuba University Hospital and was in compliance with the tenets of the Declaration of Helsinki. Signed informed consent was obtained from all study subjects.

ERM was defined as macular thickening involving the fovea, with or without subjective distortion, and wrinkling of the inner retinal surface on biomicroscopy and SD-OCT. Exclusion criteria included patients with a history of vitreoretinal surgery and ophthalmic disorders, except for mild refractive errors and mild cataract, best-corrected visual acuity (BCVA) of <20/100, and high myopia with more than -10 diopters. Eyes with secondary ERM due to retinal vascular disease, uveitis, trauma, and retinal breaks were also excluded from the study.

We examined BCVA, CS, and retinal microstructure using SD-OCT preoperatively and at 6 postoperative months. Best-corrected visual acuity was measured using the Landolt chart and was expressed as the logarithm of minimum angle of resolution (logMAR). We obtained CS data by using a CSV-1000E chart (Vector Vision, Greenville, OH, USA) with the best spectacle correction. The CSV-1000E chart, used to test CS, provides a fluorescent luminance source that retroilluminates a translucent chart and is automatically calibrated to 85 cd/m². The reliability of the instrument has been demonstrated.³¹ There were 4 spatial frequencies, namely, 3, 6, 12, and 18 cycles per degree (cyc/degree), in which each frequency included 8 different levels of contrast. The patient was tested monocularly with the best spectacle correction in an undilated state at 2.5 m. With the patients' manifest refraction in place, we asked them to identify the rows and eight columns of patches. Next, they were asked to identify the grating pattern in each column. The contrast level of the last correct response was recorded as the contrast threshold in logarithmic values.

From the data obtained with CSV-1000E chart, the area under the log contrast sensitivity function (AULCSF) was calculated.³²

Retinal images were obtained with SD-OCT (Cirrus high-definition OCT; Carl Zeiss, Dublin, CA, USA). Five-line raster scans of each eye were performed by using a commercial analysis software (Cirrus version 3.0 analysis software; Carl Zeiss) with a signal strength of more than 8/10. Based on the image obtained with SD-OCT, the following six parameters were measured: central foveal thickness (CFT), ganglion cell layer (GCL) thickness, inner nuclear layer (INL), outer retinal layer (outer nuclear layer and outer plexiform layer [ONL+OPL]), degree of the photoreceptor inner and outer segment junction (IS/OS) disruption, and degree of ELM disruption. Based on images obtained by 5-line raster scans, we divided the 1.0- × 1.0-mm area centered on the fovea into 9 sections at 0.25-mm intervals and quantified the parameters listed (Fig. 1). An image-processing program (ImageJ software; National Institutes of Health, Bethesda, MD, USA) was used to quantify the thickness of each retinal layer (Fig. 2A). We measured the thickness of each retinal layer at nine sections and used averaged data. To quantify the degree of IS/OS disruption, we assessed whether IS/OS was disrupted in each of the above nine sections and defined the number of disrupted sections as the degree of IS/OS disruption.²⁷ We also assessed the degree of ELM disruption using a similar process (Fig. 2B). Clinical data were collected, including patient age and sex.

Surgery consisted of 23- or 25-gauge transconjunctival sutureless vitrectomy performed by two experienced vitreoretinal surgeons (F.O. and Y.O.). A core vitrectomy was performed with induction of posterior vitreous detachment if not already present. ERM peeling and internal limiting membrane (ILM) peeling were performed in all cases, using

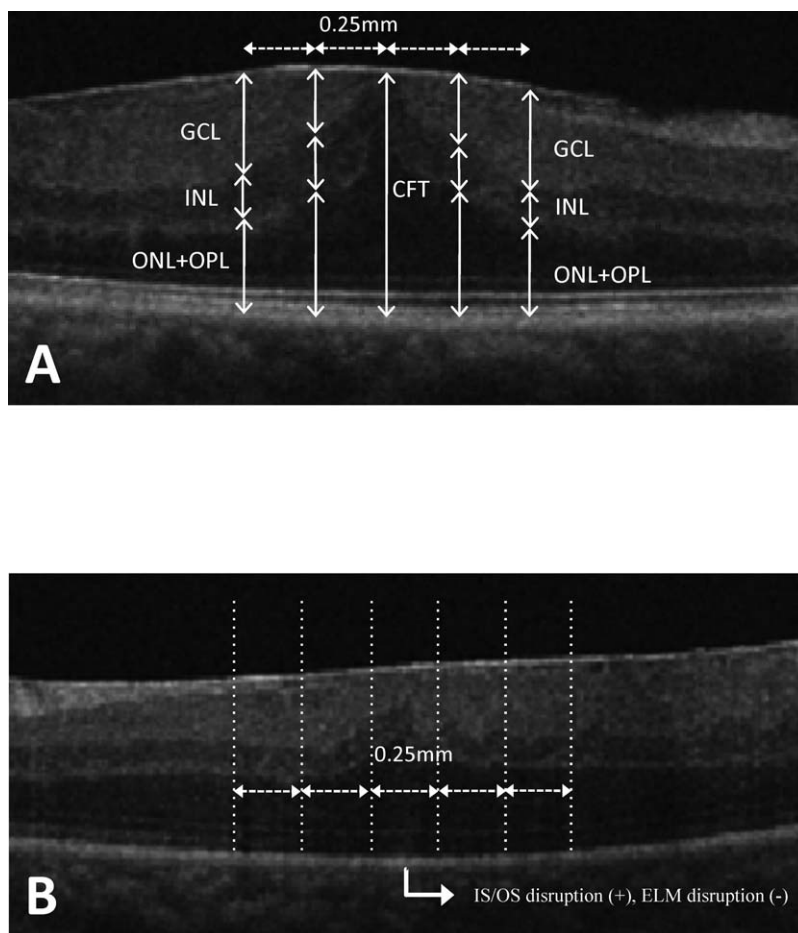


FIGURE 2. (A) We measured central foveal thickness (CFT), thickness of the ganglion cell layer (GCL), inner nuclear layer (INL), outer retinal layer (outer nuclear layer and outer plexiform layer [ONL+OPL]). (B) In each of the sections, we assessed whether the photoreceptor inner segment and outer segment junction (IS/OS) and external limiting membrane (ELM) were disrupted and defined the number of disrupted sections as the degree of IS/OS and ELM disruption.

0.025% Brilliant Blue G dye (Sigma-Aldrich, St. Louis, MO, USA). Phacoemulsification and aspiration with intraocular lens implantation were conducted simultaneously if a clinically significant cataract was present.

Mean scores were compared and standard deviations were calculated for each parameter of visual function and OCT measurement. A Wilcoxon signed-ranks test was used to compare each factor before and after surgery. A Mann-Whitney *U* test was performed to compare visual function of patients who underwent combined surgery and vitrectomy with that of patients who underwent vitrectomy alone. The associations among BCVA, AULCSF, and OCT parameters were analyzed with the Pearson's correlation coefficient test. Multiple regression analysis was performed to investigate the relationship between postoperative AULCSF and OCT parameters. All statistical analyses were performed using commercial software (StatView version 5.0; SAS, Inc., Cary, NC, USA). All tests of associations were considered statistically significant at a *P* value of <0.05.

RESULTS

Combined pars plana vitrectomy and phacoemulsification were performed in 16 eyes (51.6%), and vitrectomy alone were performed in 15 eyes (48.4%). There were no significant

differences between preoperative BCVA ($P = 0.16$) and postoperative BCVA ($P = 0.36$) nor between preoperative AULCSF ($P = 0.43$) and postoperative AULCSF ($P = 0.33$) in the combined surgery group and the vitrectomy alone group, respectively (Fig. 3). No significant intraoperative or postoperative complications were observed, including vitreous hemorrhage, subretinal hemorrhage, choroidal detachment, and persistent elevation of intraocular pressure for more than 7 days.

Table 1 shows visual functions and OCT parameters of patients following ERM surgery. Before surgery, mean \pm SD central foveal thickness was $403 \pm 148 \mu\text{m}$ (range: 142–658 μm). Vitrectomy significantly improved AULCSF ($P < 0.0001$). Postoperative CS was significantly better than the preoperative level at spatial frequencies of 3, 6, 12, and 18 cyc/degree ($P < 0.0005$). Thickness of GCL ($P < 0.0001$), INL ($P < 0.0001$), and ONL+OPL ($P < 0.0005$) significantly decreased. Vitrectomy significantly improved the degree of ELM disruption ($P < 0.005$), whereas the degree of IS/OS disruption remained unchanged ($P = 0.17$). logMAR BCVA significantly improved following surgery ($P < 0.0001$), with 14 patients (45.2%) gaining 0.2 log units or more. No change was observed in 15 eyes (48.4%), whereas vision decreased by 0.1 or more in 2 patients (6.5%).

We divided ERM patients into two groups: patients who exhibited good improvement in visual acuity following surgery,

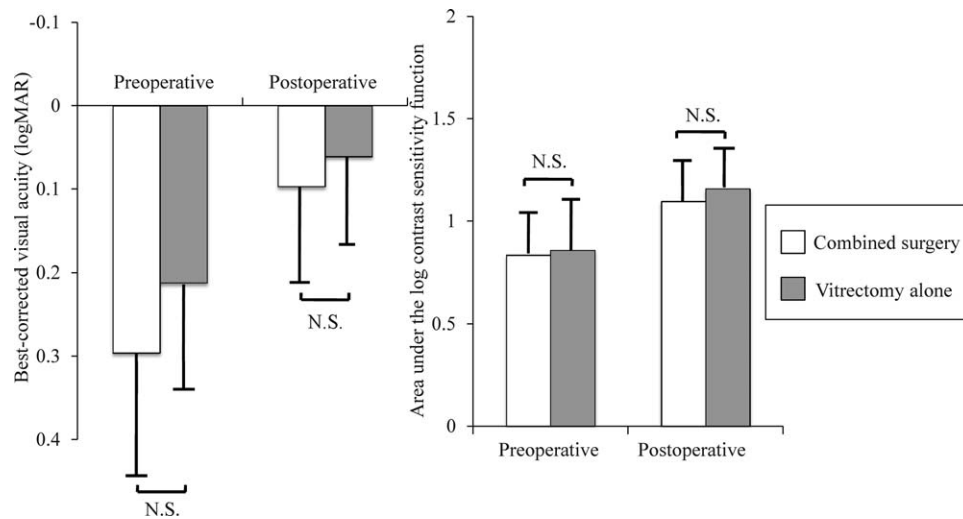


FIGURE 3. Pre- and postoperative best-corrected visual acuity and the area under the log contrast sensitivity function between combined surgery group and vitrectomy-alone group. No significant differences were observed between the two groups.

TABLE 1. Visual Function and Optical Coherence Tomography Parameters of Patients After Epiretinal Membrane Surgery

Parameter	Before Surgery	After Surgery	P Value
logMAR BCVA	0.23 ± 0.17	0.07 ± 0.12	<0.0001*
Contrast sensitivity (cycles per degree)			
3	1.35 ± 0.29	1.59 ± 0.21	<0.0001*
6	1.40 ± 0.40	1.74 ± 0.22	<0.0001*
12	0.90 ± 0.39	1.26 ± 0.31	<0.0005*
18	0.43 ± 0.44	0.79 ± 0.35	<0.0005*
AULCSF	0.88 ± 0.25	1.13 ± 0.16	<0.0001*
Central foveal thickness, μm	403 ± 148	304 ± 99	<0.0001*
GCL thickness, (μm)	137 ± 47	94 ± 19	<0.0001*
INL thickness, μm	95 ± 33	70 ± 21	<0.0001*
ONL+OPL thickness, μm	190 ± 25	171 ± 23	<0.0005*
Degree of IS/OS disruption	1.0 ± 1.7	0.6 ± 1.4	0.17
Degree of ELM disruption	2.6 ± 2.7	0.8 ± 1.1	<0.005*

Values are means ± standard deviations. AULCSF area under the log contrast sensitivity function; BCVA, best-corrected visual acuity; ELM, external limiting membrane; GCL, ganglion cell layer; INL, inner nuclear layer; IS/OS, photoreceptor inner segment/outer segment junction; ONL, outer nuclear layer; OPL, outer plexiform layer.

*Significantly different between groups (Wilcoxon signed-ranks test).

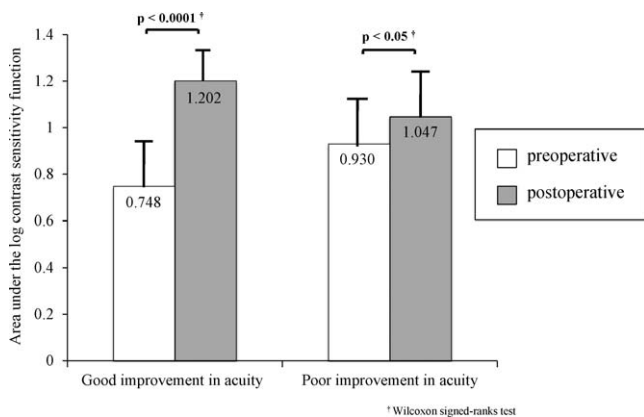


FIGURE 4. ERM patients were divided into two groups: patients who exhibited good improvement in visual acuity following surgery with the change in logMAR of ≥ 0.2 and patients with poor improvement in logMAR of < 0.2 . In both groups, the area under the log contrast sensitivity function (AULCSF) was increased significantly by surgery ($P < 0.05$).

with a change in logMAR of 0.2 or more; and patients with poor improvement of less than 0.2. In the good improvement group, the mean BCVA change was -0.34 ± 0.11 . On the other hand, the mean BCVA change in the poor improvement group was -0.03 ± 0.11 . AULCSF was significantly increased by surgery in the good improvement group ($P < 0.0001$) and in the poor improvement group ($P < 0.05$) (Fig. 4).

Table 2 shows correlations between visual functions and OCT parameters. Postoperative AULCSF showed a significant correlation with preoperative thickness of ONL+OPL ($P < 0.05$, Fig. 5A) and postoperative thickness of ONL+OPL ($P < 0.05$) (Fig. 5B). Multiple regression analysis revealed that postoperative AULCSF was significantly related to postoperative thickness of ONL+OPL ($P < 0.05$) and preoperative thickness of ONL+OPL ($P < 0.05$), whereas other variables were not relevant. Postoperative logMAR BCVA was significantly correlated with preoperative thickness of GCL ($P < 0.05$, Fig. 5C), preoperative thickness of ONL+OPL ($P < 0.05$) (Fig. 5D), and postoperative degree of IS/OS disruption ($P < 0.05$) (Fig. 5E).

TABLE 2. *P* Values of Correlation Between Visual Functions and Optical Coherence Tomography Parameters with Epiretinal Membrane

Timing	Parameter	Postoperative BCVA	Postoperative AULCSF
Preoperatively	Central foveal thickness	0.745	0.937
	GCL thickness	<0.05*	0.154
	INL thickness	0.241	0.841
	ONL+OPL thickness	<0.05*	<0.05*
	Degree of IS/OS disruption	0.443	0.624
	Degree of ELM disruption	0.493	0.174
Postoperatively	Central foveal thickness	0.810	0.088
	GCL thickness	0.185	0.565
	INL thickness	0.392	0.432
	ONL+OPL thickness	0.055	<0.05*
	Degree of IS/OS disruption	<0.05*	0.335
	Degree of ELM disruption	0.680	0.961

AULCSF, area under the log contrast sensitivity function; BCVA, best-corrected visual acuity; ELM, external limiting membrane; GCL, ganglion cell layer; INL, inner nuclear layer; IS/OS, photoreceptor inner segment/outer segment junction; ONL, outer nuclear layer; OPL, outer plexiform layer.

*Significant correlation between parameters (Pearson's correlation coefficient test).

DISCUSSION

There have been many previous studies of visual acuity in ERM patients following surgery.⁶⁻¹⁰ In the present study, we found that not only visual acuity but also CS was improved by surgery. CS is known to be correlated with various aspects of visual function that are vital in patients' daily activities. Okamoto et al.¹⁶ reported that postoperative CS in eyes with macula-on rhegmatogenous retinal detachment was better than that in preoperative eyes, whereas no significant differences were observed between preoperative and postoperative logMAR BCVA.¹⁶ Sabour-Pickett et al.³⁵ assessed visual function in patients with neovascular age-related macular degeneration

who were given serial doses of intravitreal ranibizumab. Although the patients' corrected distance visual acuity exhibited no change, their other visual function parameters, including mesopic and photopic CS, demonstrated significant improvement. Ghazi-Nouri et al.³⁴ and Okamoto et al.³⁵ investigated CS in patients with ERM to clarify the relationship between visual function and vision-related quality of life. These studies suggested that CS can be used as a more sensitive indicator than visual acuity. CS therefore may be useful for evaluating visual function in patients with diseases with relatively better visual acuity such as ERM.

CS significantly improved even in patients with poor improvement in visual acuity. However, the improvement of

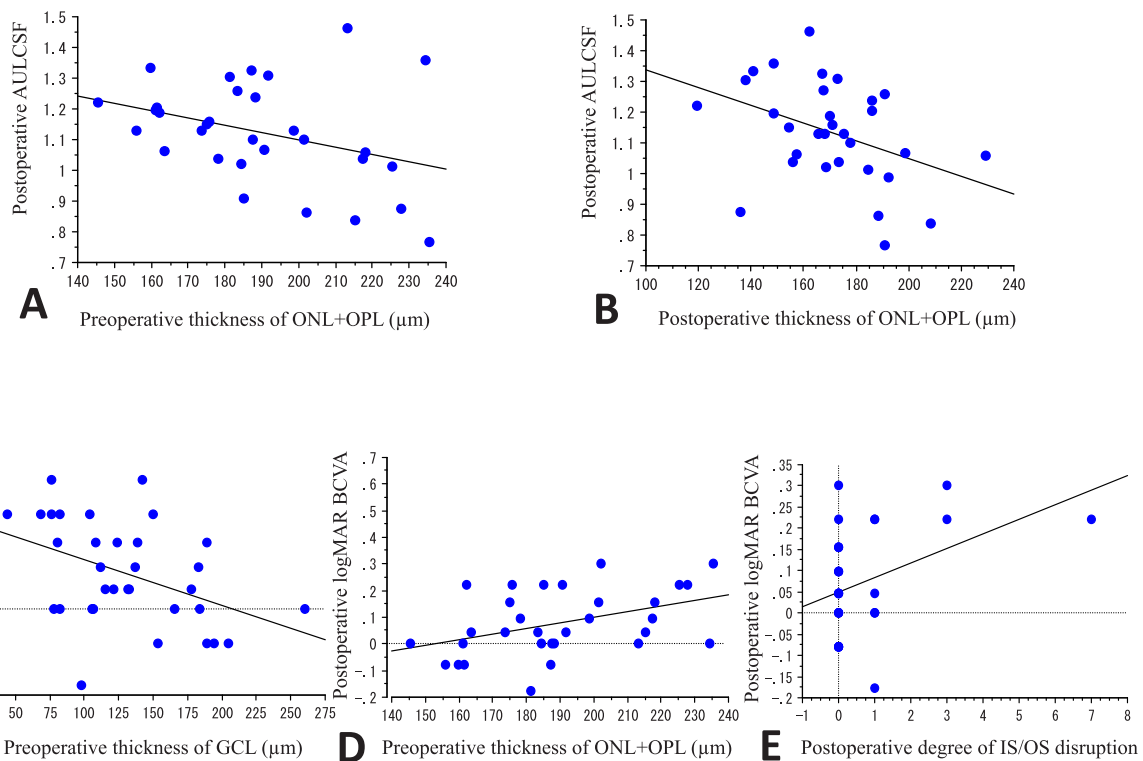


FIGURE 5. Postoperative area under the log contrast sensitivity function (AULCSF) was significantly correlated with preoperative thickness of outer nuclear layer (ONL) plus outer plexiform layer (OPL) (A) and postoperative thickness of ONL+OPL (B). Postoperative logMAR best-corrected visual acuity (BCVA) showed significant correlation with preoperative thickness of ganglion cell layer (GCL) (C), preoperative thickness of ONL+OPL (D), and postoperative degree of photoreceptor inner and outer segment junction (IS/OS) disruption (E).

AULCSF was 0.117 (from 0.930 to 1.047), and it was relatively small. Hiraoka et al.³⁶ showed a mean decrease in AULCSF of 0.16 from the baseline value 3 months after overnight orthokeratology. Yamane et al.¹² examined the impact of CS loss after LASIK. The authors showed a mean decline in AULCSF of 0.08 after LASIK. The changing amount of CS observed in our present study is comparable with previous results and are clinically meaningful.

In our present study, preoperative impairment, as well as postoperative improvement, in CS was seen at all spatial frequencies in eyes undergoing vitrectomy for ERM. On the other hand, previous studies have demonstrated that CS was reduced from middle to high spatial frequencies in eyes with retinal disorders such as macula-on rhegmatogenous retinal detachment,¹⁶ early stage age-related macular degeneration,³⁷ and birdshot chorioretinopathy.³⁸ These discrepancies seem to be due to the different background of patients and characteristics of retinal diseases. The previous studies included cases with almost normal visual acuity, whereas visual acuity in patients with ERM in the current study was relatively poor (logMAR: 0.23) compared with those of previous studies. In our study, CS was more severely deteriorated preoperatively, which was successfully recovered by surgery in eyes with ERM.

As shown in these results, postoperative CS demonstrated a significant correlation with pre- and postoperative ONL+OPL thickness. No reports so far have discussed a correlation between CS and the retinal microstructure in patients with ERM. This is the first report showing that postoperative BCVA is associated with a postoperative degree of IS/OS disruption and preoperative ONL+OPL and GCL thickness.

It was indicated that preoperative central retinal thickness and integrity of the IS/OS junction might predict visual acuity after ERM surgery.^{25,39,40} Inoue et al.²⁵ reported that preoperative integrity of the IS/OS junction can be an important prognostic factor for better BCVA after ERM surgery. Other reports found that the integrity of the ELM, IS/OS line, and cone outer segment tip line was a major factor that could predict final visual acuity after ERM surgery.^{26,41} In our study, postoperative BCVA was significantly associated with postoperative integrity of the IS/OS junction but not with preoperative integrity of the IS/OS junction. This discrepancy may be due to the different status of preoperative IS/OS junction, that is, the IS/OS junction was not severely damaged in many of our patients before surgery.

Postoperative CS showed a significant correlation with pre- and postoperative ONL+OPL (outer retina) thickness. Arichika et al.⁴² reported that outer retinal thickening, not inner retinal thickening, was significantly correlated with visual function in patients with ERM. ERM-induced retinal damage associated with visual function deterioration seems to be located in outer retina. In outer retinal layer, a large number of photoreceptors line up. The change in outer retinal microstructure may affect deterioration or improvement of CS. It is suggested that CS can be a more sensitive indicator than visual acuity and can detect even minute structural changes in outer retinal layer before IS/OS defect appears.

Postoperative BCVA was associated with preoperative thickness of GCL. Koo et al.³⁰ investigated differential thickening of retinal layers in patients with ERM and found that inner retina (including ILM, nerve fiber layer, and GCL) had the largest variability of thickness compared with INL and outer retina, and inner retina was strongly associated with visual acuity changes. These findings are consistent with our results.

Our study has several limitations. First, the sample size was small. Second, postoperative follow-up was short. We evaluated the patients at 6 months postoperatively. Further studies with a larger sample size and longer follow-up period are

warranted. Third, we included patients with phakic eyes and pseudophakic eyes, but the influence of lens was not taken into account properly.

In conclusion, CS in ERM patients improved even when visual acuity did not recover significantly by vitrectomy. CS was associated with the thickness of outer retinal layer, whereas visual acuity was associated with the status of IS/OS.

Acknowledgments

The authors alone are responsible for the content and writing of the paper.

Disclosure: **Y. Sugiura**, None; **F. Okamoto**, None; **Y. Okamoto**, None; **T. Hiraoka**, None; **T. Oshika**, None

References

- Fraser-Bell S, Ying-Lai M, Klein R, Varma R; Los Angeles Latino Eye Study. Prevalence and associations of epiretinal membranes in Latinos: the Los Angeles Latino Eye Study. *Invest Ophthalmol Vis Sci.* 2004;45:1732-1736.
- Fraser-Bell S, Guzowski M, Rochtchina E, Wang JJ, Mitchell P. Five-year cumulative incidence and progression of epiretinal membranes: the Blue Mountains Eye Study. *Ophthalmology.* 2003;110:34-40.
- Klein R, Klein BE, Wang Q, Moss SE. The epidemiology of epiretinal membranes. *Trans Am Ophthalmol Soc.* 1994;92:403-425.
- Pearlstone AD. The incidence of idiopathic preretinal macular gliosis. *Ann Ophthalmol.* 1985;17:378-80.
- Gupta P, Sadun AA, Sebag J. Multifocal retinal contraction in macular pucker analyzed by combined optical coherence tomography/scanning laser ophthalmoscopy. *Retina.* 2008;28:447-452.
- Michels RG. Vitreous surgery for macular pucker. *Am J Ophthalmol.* 1981;92:628-639.
- Margherio RR, Cox MS Jr, Trese MT, et al. Removal of epimacular membranes. *Ophthalmology.* 1985;92:1075-1083.
- Rice TA, De Bustros S, Michels RG, et al. Prognostic factors in vitrectomy for epiretinal membranes of the macula. *Ophthalmology.* 1986;93:602-610.
- Grewing R, Mester U. Results of surgery for epiretinal membranes and their recurrences. *Br J Ophthalmol.* 1996;80:323-326.
- Pesin SR, Olk RJ, Grand MG, et al. Vitrectomy for premacular fibroplasia. Prognostic factors, long-term follow-up, and time course of visual improvement. *Ophthalmology.* 1991;98:1109-1114.
- Maeda N, Sato S, Watanabe H, et al. Prediction of letter contrast sensitivity using videokeratographic indices. *Am J Ophthalmol.* 2000;129:759-763.
- Yamane N, Miyata K, Samejima T, et al. Ocular higher-order aberrations and contrast sensitivity after conventional laser in situ keratomileusis. *Invest Ophthalmol Vis Sci.* 2004;45:3986-3990.
- Chylack LT Jr, Jakubicz G, Rosner B, et al. Contrast sensitivity and visual acuity in patients with early cataracts. *J Cataract Refract Surg.* 1993;19:399-404.
- Keane PA, Patel PJ, Ouyang Y, et al. Effects of retinal morphology on contrast sensitivity and reading ability in neovascular age-related macular degeneration. *Invest Ophthalmol Vis Sci.* 2010;51:5431-5437.
- Ortiz C, Jiménez JR, Pérez-Ocón F, Castro JJ, González-Anera R. Retinal-image quality and contrast-sensitivity function in age-related macular degeneration. *Curr Eye Res.* 2010;35:757-761.
- Okamoto F, Sugiura Y, Okamoto Y, Hiraoka T, Oshika T. Changes in contrast sensitivity after surgery for macula-on

- rhegmatogenous retinal detachment. *Am J Ophthalmol*. 2013;156:667-672.
17. Okamoto F, Okamoto Y, Fukuda S, Hiraoka T, Oshika T. Vision-related quality of life and visual function after vitrectomy for various vitreoretinal disorders. *Invest Ophthalmol Vis Sci*. 2010;51:744-751.
 18. Higuchi H, Fukuda T, Ukai K, Miyata M. Visual function analysis of diabetic retinopathy using a contrast sensitivity analyser and usefulness of nicardipine hydrochloride. *Nihon Ganka Gakkai Zasshi*. 1995;99:914-919.
 19. Okamoto F, Okamoto Y, Hiraoka T, Oshika T. Vision-related quality of life and visual function after retinal detachment surgery. *Am J Ophthalmol*. 2008;146:85-90.
 20. Okamoto F, Okamoto Y, Fukuda S, Hiraoka T, Oshika T. Vision-related quality of life and visual function following vitrectomy for proliferative diabetic retinopathy. *Am J Ophthalmol*. 2008;145:1031-1036.
 21. Ko TH, Fujimoto JG, Schuman JS, et al. Comparison of ultrahigh- and standard-resolution optical coherence tomography for imaging macular pathology. *Ophthalmology*. 2005;112:1922.e1-15.
 22. Drexler W, Sattmann H, Hermann B, et al. Enhanced visualization of macular pathology with the use of ultrahigh-resolution optical coherence tomography. *Arch Ophthalmol*. 2003;121:695-706.
 23. Puliafito CA, Hee MR, Lin CP, et al. Imaging of macular diseases with optical coherence tomography. *Ophthalmology*. 1995;102:217-229.
 24. Wilkins JR, Puliafito CA, Hee MR, et al. Characterization of epiretinal membranes using optical coherence tomography. *Ophthalmology*. 1996;103:2142-2151.
 25. Inoue M, Morita S, Watanabe Y, et al. Inner segment/outer segment junction assessed by spectral-domain optical coherence tomography in patients with idiopathic epiretinal membrane. *Am J Ophthalmol*. 2010;150:834-839.
 26. Watanabe K, Tsunoda K, Mizuno Y, Akiyama K, Noda T. Outer retinal morphology and visual function in patients with idiopathic epiretinal membrane. *JAMA Ophthalmol*. 2013;131:172-177.
 27. Shimozono M, Oishi A, Hata M, et al. The significance of cone outer segment tips as a prognostic factor in epiretinal membrane surgery. *Am J Ophthalmol*. 2012;153:698-704.
 28. Okamoto F, Sugiura Y, Okamoto Y, Hiraoka T, Oshika T. Associations between metamorphopsia and foveal microstructure in patients with epiretinal membrane. *Invest Ophthalmol Vis Sci*. 2012;53:6770-6775.
 29. Watanabe A, Arimoto S, Nishi O. Correlation between metamorphopsia and epiretinal membrane optical coherence tomography findings. *Ophthalmology*. 2009;116:1788-1793.
 30. Koo HC, Rhim WI, Lee EK. Morphologic and functional association of retinal layers beneath the epiretinal membrane with spectral-domain optical coherence tomography in eyes without photoreceptor abnormality. *Graefes Arch Clin Exp Ophthalmol*. 2012;250:491-498.
 31. Pomerance GN, Evans DW. Test-retest reliability of the CSV-1000 contrast test and its relationship to glaucoma therapy. *Invest Ophthalmol Vis Sci*. 1994;35:3357-3361.
 32. Applegate RA, Howland HC, Sharp RP, Cottingham AJ, Yee RW. Corneal aberrations and visual performance after radial keratotomy. *J Refract Surg*. 1998;14:397-407.
 33. Sabour-Pickett S, Loughman J, Nolan JM, et al. Visual performance in patients with neovascular age-related macular degeneration undergoing treatment with intravitreal ranibizumab. *J Ophthalmol*. 2013;2013:268438.
 34. Ghazi-Nouri SM, Tranos PG, Rubin GS, Adams ZC, Charteris DG. Visual function and quality of life following vitrectomy and epiretinal membrane peel surgery. *Br J Ophthalmol*. 2006;90:559-62.
 35. Okamoto F, Okamoto Y, Hiraoka T, Oshika T. Effect of vitrectomy for epiretinal membrane on visual function and vision-related quality of life. *Am J Ophthalmol*. 2009;147:869-874.
 36. Hiraoka T, Mihashi T, Okamoto C, et al. Influence of induced decentered orthokeratology lens on ocular higher-order wavefront aberrations and contrast sensitivity function. *J Cataract Refract Surg*. 2009;35:1918-26.
 37. Stangos N, Voutas S, Topouzis F, Karampatakis V. Contrast sensitivity evaluation in eyes predisposed to age-related macular degeneration and presenting normal visual acuity. *Ophthalmologica*. 1995;209:194-198.
 38. Kappel PJ, Monnet D, Yu F, et al. Contrast sensitivity among patients with birdshot chorioretinopathy. *Am J Ophthalmol*. 2009;147:351-356.
 39. Falkner-Radler CI, Glittenberg C, Hagen S, Benesch T, Binder S. Spectral-domain optical coherence tomography for monitoring epiretinal membrane surgery. *Ophthalmology*. 2010;117:798-805.
 40. Kim J, Rhee KM, Woo SJ, et al. Long-term temporal changes of macular thickness and visual outcome after vitrectomy for idiopathic epiretinal membrane. *Am J Ophthalmol*. 2010;150:701-709.
 41. Theodossiadi PG, Theodossiadi GP, Charonis A, et al. The photoreceptor layer as a prognostic factor for visual acuity in the secondary epiretinal membrane after retinal detachment surgery: imaging analysis by spectral-domain optical coherence tomography. *Am J Ophthalmol*. 2011;151:973-980.
 42. Arichika S, Hangai M, Yoshimura N. Correlation between thickening of the inner and outer retina and visual acuity in patients with epiretinal membrane. *Retina*. 2010;30:503-508.