

Treatment of a hip capsular injury in a professional soccer player with platelet-rich plasma and bone marrow aspirate concentrate therapy

Kevin J. Campbell · Robert E. Boykin ·
Coen A. Wijdicks · J. Erik Giphart ·
Robert F. LaPrade · Marc J. Philippon

Received: 9 August 2012 / Accepted: 24 September 2012
© Springer-Verlag Berlin Heidelberg 2012

Abstract This report presents a 27-year-old male professional soccer player who developed heterotopic ossification of his hip capsule and gluteus minimus tendon after an arthroscopic hip procedure. After removal of the heterotopic bone, the patient had a symptomatic deficiency of his hip capsule and gluteus minimus tendon. A series of orthobiologic treatments with platelet-rich plasma and bone marrow aspirate concentrate improved the patient's pain and strength as well as the morphologic appearance of the hip capsule and gluteus minimus tendon on magnetic resonance imaging. A series of motion analyses demonstrated significant improvement in his stance-leg ground reaction force and hip abduction, as well as linear foot velocity at ball strike and maximum hip flexion following ball strike in his kicking leg.

Level of evidence IV.

Keywords Platelet-rich plasma · Bone marrow aspirate concentrate · Hip capsular injury · Gluteus minimus tendon tear · Motion analysis

Introduction

The hip capsule is a fibrous and highly vascular soft tissue stabilizer of the joint [2]. Injury to the capsule occurs

infrequently but may be associated with traumatic dislocations of the hip in addition to iatrogenic injury during hip arthroscopy or total hip arthroplasty [11, 15, 20, 23]. Capsular deficiency may result in hip instability and/or pain. Classically, hip capsule tears are treated with surgical repair; however, there may be a role for less invasive therapies in select patients with certain occult hip capsular injuries. Recently, orthobiologics have shown promise in the treatment of musculoskeletal soft tissue injuries and may have the potential to treat soft tissue injuries around the hip [14, 18, 22, 24, 25, 27, 28]. Bone marrow aspiration concentrate (BMAC) and platelet-rich plasma (PRP) are two such therapies.

Bone marrow aspirate concentrate contains mesenchymal stem cells which have anti-inflammatory, anti-apoptotic and multipotent capabilities [6, 21]. They have the potential to differentiate into several cell lineages including tenocytes and chondrocytes in the appropriate hematopoietic-inducing microenvironment [6, 7, 19, 32]. Platelet-rich plasma contains a high concentration of platelets, growth factors and cytokines necessary for cell differentiation and tissue healing [9, 29]. Independent use of these biologic therapies has been reported to result in improvement in the mechanical properties and histologic appearance of some musculoskeletal tissues [1, 4, 5, 8, 14, 16, 25–28].

Case report

A 27-year-old male professional soccer player with a preference for kicking with his left leg developed heterotopic ossification of his right hip capsule and gluteus minimus tendon after an arthroscopic hip procedure. The heterotopic ossification was active on a bone scan and classified as Brooker stage II. Subsequently, the patient

K. J. Campbell · R. E. Boykin · C. A. Wijdicks ·
J. Erik Giphart · R. F. LaPrade · M. J. Philippon (✉)
Department of Biomedical Engineering, Steadman Philippon
Research Institute, 181 W. Meadow Drive,
Suite 1000, Vail, CO 81657, USA
e-mail: MJP@sprivaail.org

R. F. LaPrade · M. J. Philippon
The Steadman Clinic, 181 W. Meadow Drive,
Suite 400, Vail, CO 81657, USA

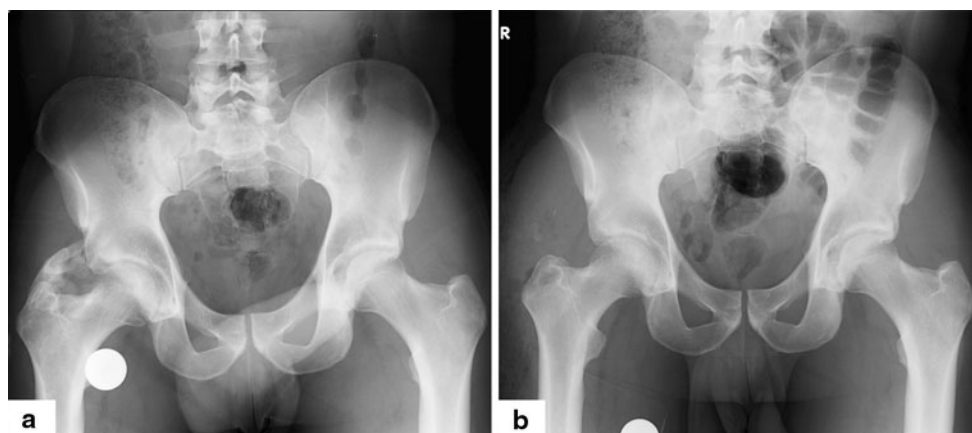


Fig. 1 **a** Pre-operative radiograph demonstrating heterotopic ossification in the right hip capsule. **b** Post-operative radiograph after removal of the heterotopic ossification

underwent a combination of arthroscopic and open excision of the heterotopic ossification, a lysis of adhesions and capsular closure of the right hip. The heterotopic ossification was located in the anterior and anterolateral hip capsule and the gluteus minimus tendon (Fig. 1). He was placed on 6 weeks of indomethacin post-operatively for heterotopic ossification prophylaxis.

The patient was progressing well with his rehabilitation until 3 months after his procedure when he developed recurrent right hip pain after a cross kick during a scrimmage. A motion analysis evaluation was undertaken to analyse the mechanics of his limb during a kicking motion which demonstrated the apprehension of weight acceptance of the involved limb and significantly decreased the kicking performance. An MRI demonstrated a tear of the gluteus minimus tendon and a defect in the anterolateral hip capsule. It was believed that a revision arthroscopy may not be beneficial for the patient to treat his gluteus minimus tendon and capsular deficiencies, especially in the setting of his history of heterotopic ossification, and the patient elected to proceed with biologic injection therapy to aid in the potential healing of his tendon and capsule tears.

In the operative suite, he underwent an examination under anaesthesia, which demonstrated no evidence of macroinstability of the hip. An ultrasound revealed a 3 cm defect in the capsule immediately lateral to the iliofemoral ligament and fluid in the gluteus minimus tendon consistent with tearing. Over the next 16 weeks, he received 3 total PRP and 2 total BMAC injections. Platelet-rich plasma injections were of 10 cc and injected under ultrasound guidance. A total of 60 cc of bone marrow aspirate was obtained by using the OnControl Automated Bone Marrow Harvest System (Vidacare, San Antonio, TX) from the left posterior superior iliac spine region and was prepared and concentrated to 6 cc. The bone marrow aspirate was also injected under ultrasound guidance. Post-injection, he was

limited in hyperextension and external rotation to allow his capsule to heal.

His therapy post-injection was gradually increased to include global hip strengthening. Eight weeks after the final injection, he reported no pain. He was able to kick pain free with either leg. On examination, his right hip range of motion was symmetric to his contralateral hip and pain free. He had grade 5/5 strength throughout all major muscle groups with the exception of internal rotation which was grade 4/5. Radiographs demonstrated a well-preserved joint space with a normal femoral head/neck offset, no evidence of pincer impingement and a minor area of mature heterotopic ossification. A repeat MRI showed improvement in the appearance of the capsule and gluteus minimus tendon with increased scarring and fibrosis in the previous defect. The labrum was healed at the site of the repair. He was cleared to return to sport 8 weeks following his final injection and returned to full activities with his team.

Performance analysis

A 10-camera infra-red motion capture system (Eagle, Motion Analysis Corp, Santa Clara, CA) with two force plates (Bertec Corporation, Columbus, OH) and using 54 reflective markers recorded the patient completing a cross soccer pass with his preferred leg which was the motion that caused the capsular injury. Multiple trials were recorded at six time points (1, 22, 35, 60, 81 and 114 days) throughout the treatment. Kinematic analysis of the passing motion was completed using Cortex (Motion Analysis Corporation, Santa Rosa, CA) and The MotionMonitor software (Innovative Sports Training, Chicago, IL). Pain during each kick was rated on a scale from 1 to 10. A one-way analysis of variance (ANOVA) was used to determine

Fig. 2 Mean peak ground reaction force of the stance leg and mean linear foot velocity at ball strike of the kicking leg of the six evaluation sessions throughout treatment. Time points for PRP/BMAC injection are displayed on horizontal axis. A significant increase ($p < 0.01$) in peak GRF and linear foot velocity at ball strike was observed between pre-treatment and 4 months post-treatment. *Error bars* represent 1 standard deviation

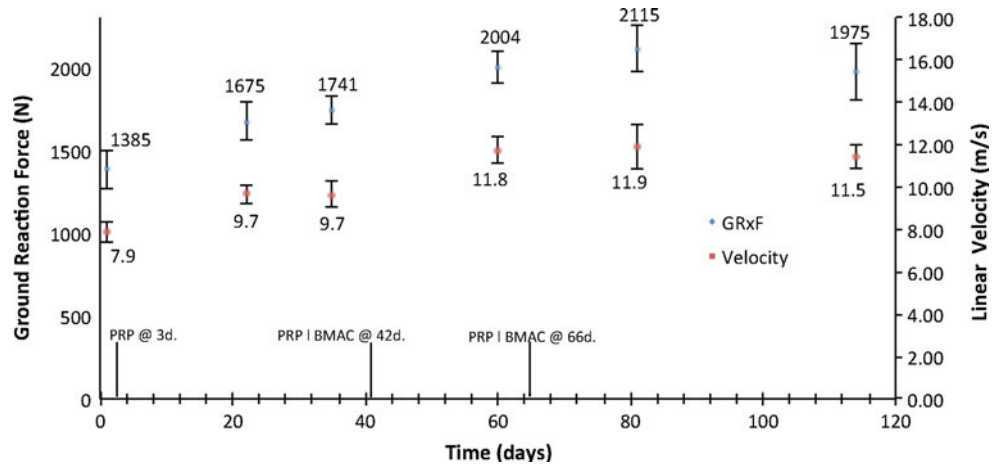
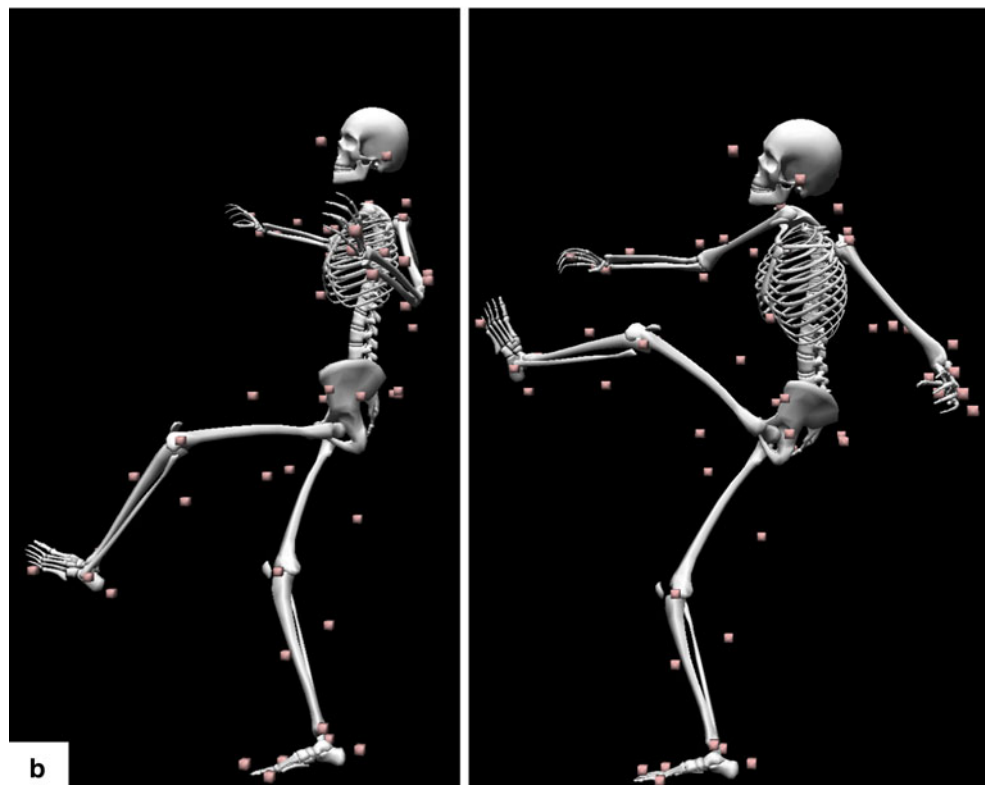
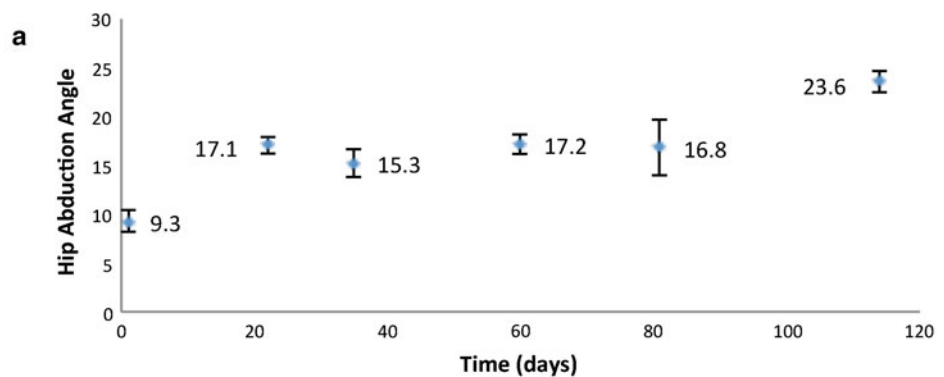


Fig. 3 a Mean peak hip abduction of the stance leg. A significant increase ($p < 0.05$) in peak hip abduction was observed between pre-treatment and 4 months post-treatment. *Error bars* represent 1 standard deviation. **b** Maximum hip flexion of the kicking leg following ball strike with 54 reflective markers significantly increased between pre-treatment (*left*) and 4 months post-treatment (*right*; $p < 0.05$)



the statistical significance of the improvements ($p < 0.005$; SPSS, IBM Corp, Armonk, NY).

The motion analysis results demonstrated continuous improvement in kicking performance while his subjective pain score consistently decreased over the treatment time period. The mean magnitude of the ground reaction force of his stance leg demonstrated a significant increase from $1,385 \text{ N} \pm 115$ before therapy, to a maximum of $2,115 \text{ N} \pm 141$ at treatment day 81 ($p < 0.01$, Fig. 2). Additionally, the mean peak hip abduction angle of his stance leg increased over the treatment period from $9.3^\circ \pm 1.1$ to $23.6^\circ \pm 1.1$ ($p < 0.05$, Fig. 3a). Both these results suggest an increase in confidence and performance of his involved hip to withstand the high impact load of planting his stance leg during the cross kick. His kicking performance also improved as the linear foot velocity of his kicking leg at the time of ball strike significantly increased from $7.9 \text{ m/s} \pm 0.5$ to a maximum of $11.9 \text{ m/s} \pm 1.1$ over the same time period ($p < 0.01$, Fig. 2). And finally, maximum hip flexion after ball strike in his kicking limb significantly increased over the treatment period ($p < 0.05$, Fig. 3b).

Discussion

The most important finding of the present study is that a professional soccer player with a hip capsular soft tissue injury experienced improvement in pain, range of motion and strength in his affected extremity with the combination use of PRP and BMAC injections. In addition, he demonstrated marked improvement in the kinematic and kinetic performance measures of a cross soccer pass, and his torn hip capsule and gluteus minimus tendon on MRI appeared more morphologically similar to native low-signal tendon tissue.

It is theorized that the proliferation and differentiation of the mesenchymal stem cells contained in BMAC into functional tenocytes and chondrocytes may be augmented by the growth factors and peptides within PRP and potentially allow for healing of soft tissue injuries in vivo. However, there is a paucity of data in the current literature in regard to the efficacy of these biologics used in combination. The limited data available does suggest that their effects may potentiate each other [3, 10, 12, 13, 17, 30, 31]. Specifically, Wang et al. reported that treatment of mesenchymal stem cells derivatives, tenocytes (human tendon precursor cells), with activated PRP accelerated cell replication and collagen production [31]. In a separate study, PRP was reported to induce a significantly higher expansion rate of mesenchymal stromal cells in vitro compared to the widely used foetal calf serum [10]. These studies suggest that the combination of BMAC and PRP may potentiate the differentiation of mesenchymal stem cells

into functional tenocytes as compared to either biologic agent used in isolation and may ultimately expedite soft tissue repair in vivo.

The present report provides an example of the combination use of PRP and BMAC to heal a hip capsular defect and gluteus minimus tendon tear in a high-demand athlete. This case highlights the therapeutic potential that may be derived from the use of PRP and BMAC in the treatment of soft tissue injuries of the hip capsule. Although more studies need to be completed to confirm the therapeutic benefits of these agents used in combination, it seems they may offer a plausible alternative to invasive surgical capsule repair in select patients.

Acknowledgments We would like to thank Kerry Costello, Kelly Newman and Sean Garvey for their contributions to this study

Conflict of interest The Steadman-Philippon Research Institute is a 501(c)(3) non-profit institution supported financially by private donations and corporate support from the following entities: Smith & Nephew Endoscopy, Arthrex, Inc., Siemens Medical Solutions USA, Inc., OrthoRehab, Conmed Linvatec, Össur Americas, Small Bone Innovations, Inc., and Opedix.

References

- Aspenberg P, Virchenko O (2004) Platelet concentrate injection improves Achilles tendon repair in rats. *Acta Orthop Scand* 75:93–99
- Bedi A, Galano G, Walsh C, Kelly BT (2011) Capsular management during hip arthroscopy: from femoroacetabular impingement to instability. *Arthroscopy* 27:1720–1731
- Cho HS, Song IH, Park SY, Sung MC, Ahn MW, Song KE (2011) Individual variation in growth factor concentrations in platelet-rich plasma and its influence on human mesenchymal stem cells. *Korean J Lab Med* 31:212–218
- Ellis B, Briggs K, Philippon M (2011) Innovation in hip arthroscopy: is hip arthritis preventable in the athlete? *Br J Sports Med* 45:253–258
- Engelbrechtsen L, Steffen K, Alsousou J, Anitua E, Bachl N, Devilee R, Everts P, Hamilton B, Huard J, Jenouire P, Kelberine F, Kon E, Maffulli N, Matheson G, Mei-Dan O, Menetrey J, Philippon M, Randelli P, Schamasch P, Schweltnus M, Vernece A, Verrall G (2010) IOC consensus paper on the use of platelet-rich plasma in sports medicine. *Br J Sports Med* 44:1072–1081
- Fortier LA, Barker JU, Strauss EJ, McCarrel TM, Cole BJ (2011) The role of growth factors in cartilage repair. *Clin Orthop Relat Res* 469:2706–2715
- Fortier LA, Nixon AJ, Williams J, Cable CS (1998) Isolation and chondrocytic differentiation of equine bone marrow-derived mesenchymal stem cells. *Am J Vet Res* 59:1182–1187
- Fortier LA, Potter HG, Rickey EJ, Schnabel LV, Foo LF, Chong LR, Stokol T, Cheatham J, Nixon AJ (2010) Concentrated bone marrow aspirate improves full-thickness cartilage repair compared with microfracture in the equine model. *J Bone Jt Surg Am* 92:1927–1937
- Foster TE, Puskas BL, Mandelbaum BR, Gerhardt MB, Rodeo SA (2009) Platelet-rich plasma from basic science to clinical applications. *Am J Sports Med* 37:2259–2272

10. Goedecke A, Wobus M, Krech M, Munch N, Richter K, Holig K, Bornhauser M (2011) Differential effect of platelet-rich plasma and fetal calf serum on bone marrow-derived human mesenchymal stromal cells expanded in vitro. *J Tissue Eng Regen Med* 5:648–654
11. Greenberg E, Wells L (2010) Hip joint capsule disruption in a young gymnast. *J Orthop Sports Phys Ther* 40:761
12. Kasten P, Vogel J, Beyen I, Weiss S, Niemyer P, Leo A, Lüginbuhl R (2008) Effect of platelet-rich plasma on the in vitro proliferation and osteogenic differentiation of human mesenchymal stem cells on distinct calcium phosphate scaffolds: the specific surface area makes a difference. *J Biomater Appl* 23:169–188
13. Krüger JP, Hondke S, Endres M, Pruss A, Siclari A, Kaps C (2012) Human platelet-rich plasma stimulates migration and chondrogenic differentiation of human subchondral progenitor cells. *J Orthop Res* 30:845–852
14. Longo UG, Lamberti A, Maffulli N, Denaro V (2011) Tissue engineered biological augmentation for tendon healing: a systematic review. *Br Med Bull* 98:31–59
15. Mei-Dan O, McConkey MO, Brick M (2012) Catastrophic failure of his arthroscopy due to iatrogenic instability: can partial divisions of the ligamentum teres and iliofemoral ligament cause subluxation? *Arthroscopy* 28:440–445
16. Menetrey J, Kasemkijwattana C, Day CS, Bosch P, Vogt M, Fu FH, Moreland MS, Huard J (2000) Growth factors improve muscle healing in vivo. *J Bone Jt Surg Br* 82:131–137
17. Mishra A, Tummala P, King A, Lee B, Kraus M, Tse V, Jacobs CR (2009) Buffered platelet-rich plasma enhances mesenchymal stem cell proliferation and chondrogenic differentiation. *Tissue Eng Part C Methods* 15:431–435
18. Monto RR (2012) Platelet rich plasma treatment for chronic Achilles tendinosis. *Foot Ankle Int* 33:379–385
19. Nixon AJ, Watts AE, Schnabel LV (2012) Cell- and gene-based approaches to tendon regeneration. *J Shoulder Elbow Surg* 21:278–294
20. Philippon MJ, Kuppersmith DA, Wolff AB, Briggs KK (2009) Arthroscopic findings following traumatic hip dislocation in 14 professional athletes. *Arthroscopy* 25:169–174
21. Pittenger MF, Mackay AM, Beck SC, Jaiswal RK, Douglas R, Mosca JD, Moorman MA, Simonetti DW, Craig S, Marshak DR (1999) Multilineage potential of adult human mesenchymal stem cells. *Science* 284:143–147
22. Ragab EM, Othman AM (2012) Platelets rich plasma for treatment of chronic plantar fasciitis. *Arch Orthop Trauma Surg* 132:1065–1070
23. Reggion A, Brugo G (2008) Traumatic anterior hip dislocation associated with anterior and inferior iliac spines avulsions and a capsular-labral lesion. *Strateg Trauma Limb Reconstr* 3:39–43
24. Sánchez M, Guadilla J, Fiz N, Andia I (2012) Ultrasound-guided platelet-rich plasma injections for the treatment of osteoarthritis of the hip. *Rheumatology (Oxford)* 51:144–150
25. Satija NK, Singh VK, Verma YK, Gupta P, Sharma S, Afrin F, Sharma M, Sharma P, Tripathi RP, Gurudutta GU (2009) Mesenchymal stem cell-based therapy: a new paradigm in regenerative medicine. *J Cell Mol Med* 13:4385–4402
26. Saw KY, Hussin P, Loke SC, Azam M, Chen HC, Tay YG, Low S, Wallin KL, Ragavanaidu K (2009) Articular cartilage regeneration with autologous marrow aspirate and hyaluronic Acid: an experimental study in a goat model. *Arthroscopy* 25:1391–1400
27. Schnabel LV, Mohammed HO, Miller BJ, McDermott WG, Jacobson MS, Santangelo KS, Fortier LA (2007) Platelet rich plasma (PRP) enhances anabolic gene expression patterns in flexor digitorum superficialis tendons. *J Orthop Res* 25:230–240
28. Sharma P, Maffulli N (2005) Tendon injury and tendinopathy: healing and repair. *J Bone Jt Surg Am* 87:187–202
29. Smyth NA, Murawski CD, Haleem AM, Hannon CP, Savage-Elliott I, Kennedy JG (2012) Establishing proof of concept: platelet-rich plasma and bone marrow aspirate concentrate may improve cartilage repair following surgical treatment of osteochondral lesions of the talus. *World J Orthop* 3:101–108
30. Vogel JP, Szalay K, Geiger F, Kramer M, Richter W, Kasten P (2006) Platelet-rich plasma improves expansion of human mesenchymal stem cells and retains differentiation capacity and in vivo bone formation in calcium phosphate ceramics. *Platelets* 17:462–469
31. Wang X, Qiu Y, Triffitt J, Carr A, Xia Z, Sabokbar A (2012) Proliferation and differentiation of human tenocytes in response to platelet rich plasma: an in vitro and in vivo study. *J Orthop Res* 30:982–990
32. Wilke MM, Nydam DV, Nixon AJ (2007) Enhanced early chondrogenesis in articular defects following arthroscopic mesenchymal stem cell implantation in an equine model. *J Orthop Res* 25:913–925