

Chirurgia (2013) 108: 563-567
No. 4, July - August
Copyright © Celsius

Arterio-Venous Fistula Using Nonpenetrating Titanium Clips (VCS)

S. Pantea¹, L. Jiga², M. Ionac², F. Lazar¹

¹Second Surgery Department, "V. Babeş" University of Medicine and Pharmacy, Timișoara

²Vascular Surgery Department, "V. Babeş" University of Medicine and Pharmacy, Timișoara

Rezumat

Fistulă arterio-venoasă cu clipuri metalice nepenetrante

Accesul vascular la hemodializă este însoțit în continuare de o morbiditate foarte mare. Tromboza datorată hiperplaziei neo-intimale este una din principalele cauze de nefuncționalitate a accesului vascular. Scopul lucrării este de a prezenta tehnica realizării anastomozei arterio-venoase folosind clipurile de titan nepenetrante (VCS) și rezultatul acesteia.

Material și metodă: Pacientului K.L. de 47 ani aflat în evidența Clinicii de Nefrologie din 2005 pentru insuficiență renală cronică i s-a efectuat în octombrie 2006 o fistulă arterio-venoasă clasică între artera radial și vena cefalică a antebrăului. Această fistulă nu a funcționat motiv pentru care în ianuarie 2007 s-a efectuat anastomoza arterio-venoasă cu clipuri de titan nepenetrante între artera brahială și vena mediană a antebrăului.

Rezultate: Anastomoza a fost realizată în 17 minute. După declamparea arterelor s-a obținut puls și tril la nivelul venei mediane a antebrăului și la nivelul venei cefalice. Nu au fost complicații intraoperatorii și postoperatorii imediate. La 5 săptămâni postoperator s-a efectuat prima hemodializă. Fistula este funcțională la 58 de luni de la efectuarea ei.

Concluzii: Realizarea anastomozelor arterio-venoase pentru acces la hemodializă cronică cu material nepenetrant poate fi o soluție de reducere a complicațiilor postoperatorii și de prelungire a patenței fistulelor.

Cuvinte cheie: hemodializă, fistulă arterio-venoasă, clipuri de titan nepenetrante

Abstract

Vascular access in haemodialysis is still accompanied by a high morbidity rate. Neointimal hyperplasia due to thrombosis is one of the main causes of vascular access failure. The purpose of this paper is to present the use of non-penetrating titanium clips (VCS) for the creation of an arteriovenous fistula and its outcome.

Materials and Methods: A male patient, 47 years old, with end-stage renal disease - ESRD - (2005) was addressed to our service, for a vascular access reintervention, after a failed forearm radio-cephalic fistula performed 3 months before. In January 2007, an arteriovenous fistula between the brachial artery and the median cubital vein using non-penetrating titanium clips (Anastoclip VCS) was created.

Results: The vascular anastomosis was performed in 17 min. After unclamping the artery, a solid pulse and consistent thrill were obtained at the level of the cubital fossa. The postoperative course was uneventful. The arteriovenous fistula remains functional 60 months post-surgery.

Conclusions: The Anastoclip VCS system is versatile, safe to manipulate and enables fast anastomosis. Arteriovenous anastomosis performed with non-penetrating clips may be a solution with the potential to reduce postoperative complications and extend arteriovenous fistula patency in ESRD.

Key words: haemodialysis, arterio-venous fistula, titanium non-penetrating clips

Corresponding author: Assistant Lecturer Doctor Stelian Pantea
"V. Babeş" University of Medicine and
Pharmacy Timișoara
No. 54 Batania Street
E-mail: stepan62@yahoo.com

Introduction

The interventions required to gain vascular access for haemodialysis are accompanied by immediate and late complications that can lead to the loss of vascular access. Postoperative morbidity rates present an increase in the number of procedures/fistulas, of the number of in-hospital days, and, implicitly, a significant increase in costs. These costs have been estimated in the USA to over 1 billion dollars in 2001 (1,2,3).

One of the most redoubtable complications of arteriovenous fistula procedures is the stenosis of the anastomosis, which can determine thrombosis of the fistula. The main cause of the stenosis is represented by the hyperplasia of the intimal layer located especially at the level of the anastomosis (2,4). The causes for hyperplasia are numerous and the production mechanisms complex. Suturing materials determine certain lesions of the vascular endothelium that will aid platelet aggregation and neointimal hyperplasia. Additionally, there is a decrease in vascular wall compliance through an increase of focal constriction and haemodynamic changes such as turbulence (3).

The surgical methods employed so far (collars around the vein, diverting the angle of the fistula) in order to reduce the frequency of postoperative complications of arteriovenous fistulas have shown no results.

During the last decade, metallic nonpenetrating clips have been used in order to create suture-free arteriovenous fistulas to gain vascular access for haemodialysis, with the main purpose of improving their patency (5,6,7).

Case report

Patient K.F., 47 years old, has been under the care of the Nephrology Clinic in Timisoara since 2005, suffering from chronic renal failure due to a neglected chronic glomerulonephritis. Until October 2005 the patient responded to conservative treatment of the chronic renal disease. In October 2006, the patient was included in a program for chronic haemodialysis and required an arteriovenous anastomosis, which was performed in a classic manner, between the radial artery and the cephalic vein of the forearm; the fistula did not progress as expected and developed thrombosis 3 months later. Under these conditions, the chronic haemodialysis was performed by means of a catheter set in the right internal jugular vein.

A suture-free arteriovenous fistula using nonpenetrating titanium clips was performed on this patient on the 17th of January 2007. The anastomosis was created in 17 minutes. There were no significant intraoperative incidents.

The fistula had a positive development and presented good flow. Postoperative evolution was good, with no complications. 5 weeks after the intervention the patient was submitted to the first haemodialysis session, by puncturing of the cephalic vein.

Up until the date of elaboration of this paper, 58 months after the operation, the arteriovenous fistula remains functional and the patient is still under a chronic haemodialysis regimen.

Technique. Necessary materials

Vascular surgery kit.

Titanium clip application kit, containing:

- *Clip applicator;*
- *Forceps for compact everting of the 2 walls;*
- *Clip extraction forceps;*
- *Nonpenetrating titanium clips.*

The patient's position

The patient was placed on the operating table in dorsal decubitus position, with his left superior limb in abduction and external rotation, supported by an instrument table.

Anaesthesia

The procedure can be performed under local anaesthesia (xylene 1%) or locoregional.

Surgical technique

A 5-6 cm transversal incision is performed approximately 3 cm below the cubital fossa. (Fig. 1) The median antebrachial vein and its 2 branches, the median cephalic vein and the median basilica vein, are identified. The median vein is dissected along approximately 2 cm in length, and the median basilica vein is removed from its emergence point. Thus, the venous outflow is ensured by the median cephalic and the cephalic vein. (Fig. 2)

The median antebrachial vein is distally ligated, and its distal end is sectioned; an incision is made on the posterior wall of the proximal end of the median antebrachial vein along 0.7 cm.

The brachial artery and its 2 branches (the radial and the cubital arteries) are identified and dissected. This arterial complex is circumferentially dissected to a length of approximately 4 cm, treated with heparin and clamped. A 0.5 cm longitudinal arteriotomy is performed on the anterior surface of the brachial artery. The procedure continues with the creation of the latero-terminal (terminal on the vein) arteriovenous anastomosis. The median antebrachial vein is applied to the arteriotomy, to which it is fixed with 4 suture threads (Prolene 6-0) passed through the arterial and venous walls at the level of the 2 ends of the anastomosis, and at the middle of the 2 anastomosis sections, the medial and the lateral one. (Fig. 3)

One proceeds to performing the posterior section of the anastomosis using the forceps for everting vascular walls and the clip applicator; metallic (titanium) nonpenetrating clips are applied with a 2 mm distance between them. The same is performed on the anterior section of the anastomosis. (Fig. 4, 5, 6)

After the metallic clips have been applied the radial and cubital arteries are unclamped and the suture is checked for leaks; the prolene threads are joined and the brachial artery is unclamped. The quality of the anastomosis in terms of leakage was good, no bleeding was observed from the anastomosis site. Good pulse and thrill were obtained at the level of the anastomosis and of the cephalic vein of the arm.

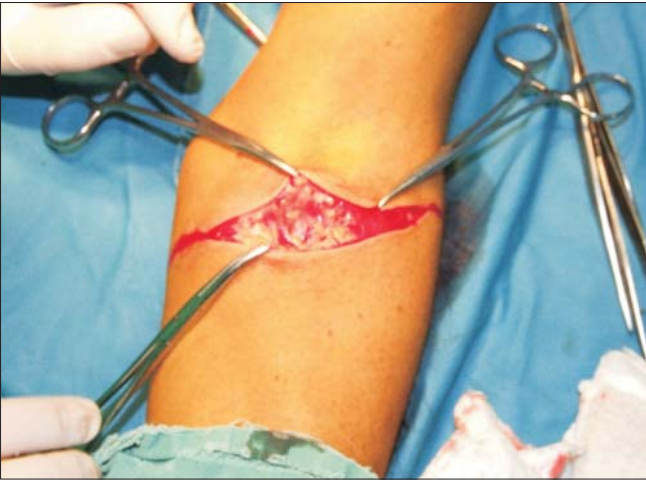

Figure 1. Transversal incision 2-3 cm below the elbow pit

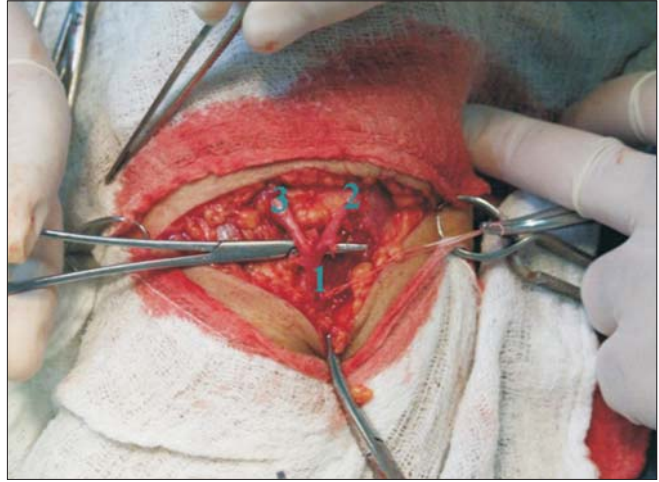


Figure 2. The median antebrachial vein (1); the median cephalic vein (2) and the median basilic vein(3)

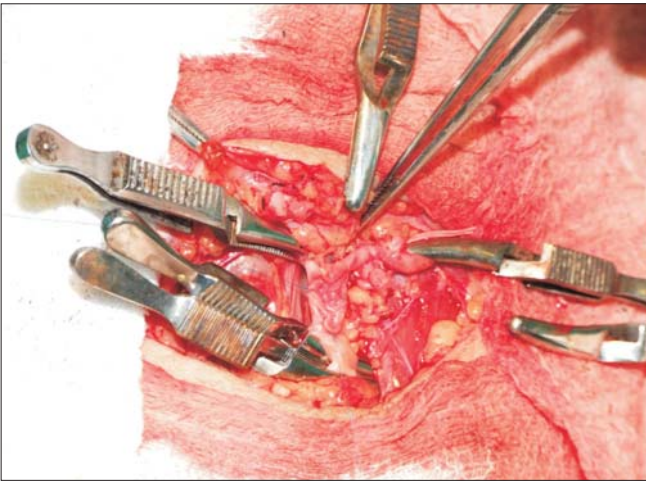


Figure 3. The median antebrachial vein fixed in 4 points at the level of the arteriotomy. The brachial artery and its 2 clamped branches

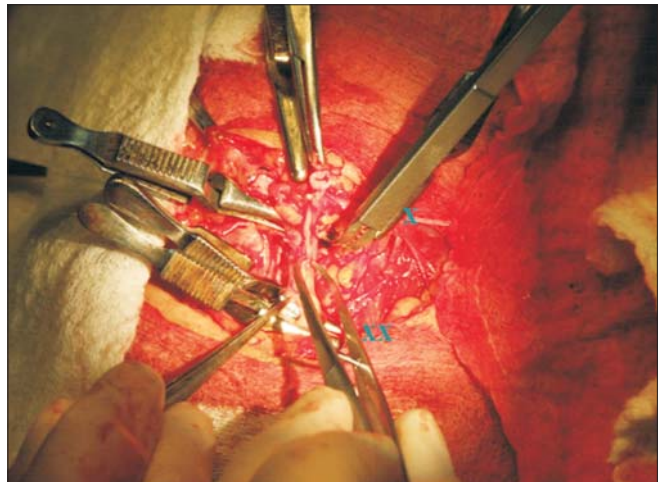


Figure 4. X clip applicator; XX eversion forceps

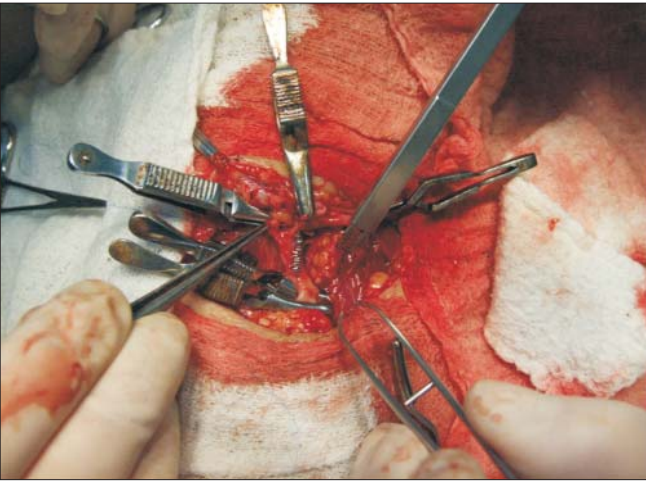


Figure 5. Posterior section of the anastomosis.

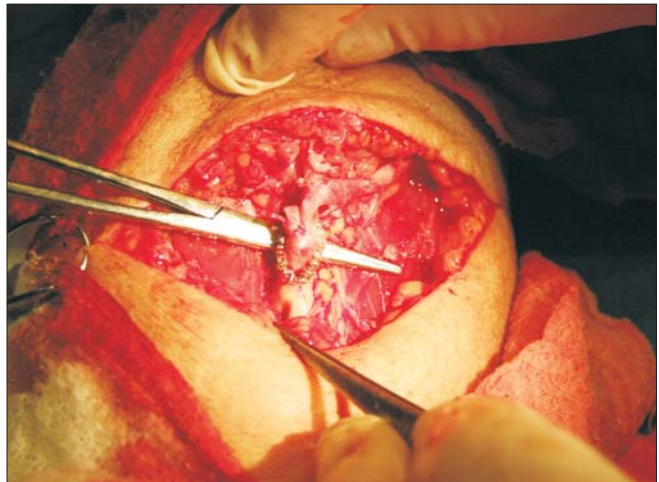


Figure 6. Arterial-venous anastomoses performed with nonpenetrating clips. In the superior aspect, the dilated median cephalic vein. Inferiorly, the 2 unclamped arterial branches

Haemostasis is once again checked and the surgical wound is sutured in anatomic layers.

Discussions

Vascular access for haemodialysis is accompanied by a number of complications, out of which stenoses are the most redoubtable, as they can compromise vascular access for haemodialysis through lack of fistula maturation and thrombosis of the anastomosis.

It was experimentally demonstrated that vascular sutures, arteriovenous fitting and turbulence aid intimal microlesions, platelet aggregation and neointimal proliferation; these factors can determine the stenosis of the arteriovenous anastomosis. Attempts to prevent the stenosis of the anastomosis by diverting the anastomosis angle, creating a collar on the vein, or adjusting the anastomosis with a venous "patch" have not provided satisfactory results.

Experimental and clinical studies conducted in the last 2 decades suggest the use of nonpenetrating metallic clips in the creation of arteriovenous anastomoses, in order to reduce anastomosis stenosis frequency and prolong the functional time of the fistula. Metallic clips provide for an everted latero-terminal arteriovenous anastomosis, nonpenetrating, elastic and impermeable. Kirsch W.M. et al. (1992) published the first experimental study referring to the use of nonpenetrating metallic clips to create vascular anastomoses (8). The author makes his first reference to the clinical implementation of this vascular anastomosis technique in 1998 (5). Mital D. et al. report using metallic (titanium) clips in performing vascular anastomoses in renal transplantation in 1996(9). Papalois V.E. et al. publish in 1998 a paper mentioning for the first time the use of metallic nonpenetrating clips in performing arteriovenous fistulas to gain access for haemodialysis (10). Over the following years, vascular anastomoses with nonpenetrating metallic clips have been employed more frequently, and in a wide range of surgeries: to gain access for haemodialysis, in renal and pancreatic transplants (10). Experimental studies highlight the advantages of metallic clip anastomosis compared to one performed with classic sutures. Dal Ponte et al. observed in an electronic microscopy and histology study on arteriovenous fistulas that this type of discontinuous and nonpenetrating suture does not affect in a major way the endothelium of the vessels involved. At the level of the anastomosis a smooth surface with no major endothelial lesions was obtained, as well as an important reduction of vascular wall lesions (11). Another studied parameter was the compliance of the anastomosis and of the post-anastomotic area. Loss of compliance at the level of the anastomosis leads to a greater compliance gap between the anastomotic and the post-anastomotic areas, and results in an increase of aggression against the venous wall, with the development of vascular wall lesions. In the case of metallic clip sutures it was observed that the decrease in compliance at the anastomosis level and the compliance gap between the two areas are lower than in the case of thread suture anastomoses (12,13,14).

Modifying the elasticity of the vascular wall affects the

laminar flow profile, through the development of a blood separation area, which leads to vortex flow. This increases the incidence of endothelial lesions, lesions that initiate an uncontrolled cellular proliferation (15).

The all but unexpected next step to these experimental studies was the introduction of the nonpenetrating metallic clip anastomosis technique into common practice. S. Shenoy et al. followed approximately 600 arteriovenous fistulas performed with metallic clips and 543 arteriovenous fistulas created the classic way in a multicentre study. Average function time for an autologous fistula performed using metallic clips was 34 months, and in the case of suture fistulas 29 months. The same difference was observed in the case of arteriovenous fistulas performed with synthetic grafts (fistula patency 31 months versus 24 months). Patients in which the fistula was created using metallic clips required a smaller number of reinterventions than those with sutures: a 0.22 rate, compared to 0.37 reinterventions/fistula/year in the case of autologous fistula, and 0.86 versus 1.73 reinterventions/fistula/year in the case of heterologous fistulas (16).

There are however authors who do not report such promising results in terms of fistula functionality when using mechanic sutures with metallic clips. Cook et al. have noticed no significant differences between patients with classic sutures and those with metallic clips in terms of functionality and complication rate (6). Similar results have been reported by Cooper et al. and Schild et al. (7,17). These authors concluded that the use of metallic clips significantly reduces the procedure time for creating the fistula, as well as intra-operative blood loss.

Conclusions

Performing arteriovenous anastomoses to gain vascular access for haemodialysis with nonpenetrating materials may represent a solution which would reduce postoperative complication rates and prolong fistula patency. Arteriovenous fistula patency is an essential element in the evolution of these patients, seeing how their survival is around 10-20 years. At the moment, this technique is unavailable to us due to the high costs of the devices and clips required to create the anastomosis. In the future, implementing therapeutic guides and appropriate clinic equipment may change this situation.

References

1. System USRD. URDS 2001 Annual Report: Atlas of end-stage renal disease in the United States. Bethesda, Md: National Institute of Diabetes and Digestive and Kidney Diseases; 2001.
2. Hakim R, Himmelfarb J. Hemodialysis access failure: a call to action. *Kidney Int.* 1998;54(4):1029-40.
3. Henderson LW. Future developments in the treatment of end-stage renal disease (a North American perspective). *Am J Kidney Dis.* 2000;35(1 suppl):106-16.
4. Roy-Chaudhury P, Kelly BS, Miller MA, Reaves A, Armstrong J, Nanayakkara N, et al. Venous neointimal hyperplasia in polytetrafluoroethylene dialysis grafts. *Kidney Int.* 2001;

- 59(6):2325-34.
5. Kirsch WM, Zhu YH, Wahlstrom E, Wang ZG, Hardesty R, Oberg K. Vascular reconstructions with nonpenetrating arcuate-legged clips. In: Yao JST, Pearce WH editors. *Techniques in vascular and endovascular surgery*. New York:Appleton & Lange; 1998. p. 67-89.
 6. Cook JW, Schuman ES, Standage BA, Heintz P. Patency and flow characteristics using stapled vascular anastomoses in dialysis grafts. *Am J Surg*. 2001;181(1):24-7.
 7. Cooper BZ, Flores L, Ramirez JA, Najjar JG, Abir F, Rayham R, et al. Analysis of nonpenetrating clips versus sutures for arterial venous graft anastomosis. *Ann Vasc Surg*. 2001; 15(1):7-12.
 8. Kirsch WM, Zhu YH, Hardesty RA, Chapolini R. A new method for micro-vascular anastomosis: report of experimental and clinical research. *Am Surg*. 1992;58(12):722-7.
 9. Mital D, Foster PF, Jensik SC, del Rio JV, Sankary HN, McChesney LP, et al. Renal transplantation without sutures using the vascular clipping system for renal artery and vein anastomosis - a new technique. *Transplantation*. 1996;62(8): 1171-3.
 10. Papalois VE, Romagnoli J, Hakim NS. Use of vascular closure staples in vascular access for dialysis, kidney and pancreas transplantation. *Int Surg*. 1998;83(2):177-80.
 11. Dal Ponte DB, Berman SS, Patula VB, Kleinert LB, Williams SK. Anastomotic tissue response associated with expanded polytetrafluoroethylene access grafts constructed by using non-penetrating clips. *J Vasc Surg*. 1999;30(2):325-33.
 12. Hasson JE, Megerman J, Abbott WM. Suture technique and para-anastomotic compliance. *J Vasc Surg*. 1986;3(4):591-8.
 13. Tai NR, Salacinski HJ, Edwards A, Hamilton G, Seifalian AM. Compliance properties of conduits used in vascular reconstruction. *Br J Surg*. 2000;87(11):1516-24.
 14. Salacinski H, Goldner S, Giudiceandrea A, Edwards A, Carson RJ, Hamilton G, et al. The mechanical behaviour of vascular grafts: a review. *J Biomater Appl*. 2001;15(3):241-78.
 15. Seifalian AM, Giudiceandrea A, Schmitz-Rixen T, Hamilton G. Noncompliance: the silent acceptance of a villain. In: Zilla P, Greisler HP editors. *Tissue engineering of vascular prosthetic grafts*. Austin (TX): R. G. Landes Company; 1999. p. 45-58.
 16. Shenoy S, Miller A, Petersen F, Kirsch WM, Konkin T, Kim P, et al. A multicenter study of permanent hemodialysis access patency: beneficial effect of clipped vascular anastomotic technique. *J Vasc Surg*. 2003;38(2):229-35.
 17. Schild AF, Pruett CS, Newman MI, Raines J, Petersen F, Konkin T, et al. The utility of the VCS clip for creation of vascular access for hemodialysis: long-term results and intra-operative benefits. *Cardiovasc Surg*. 2001;9(6):526-30.