

REVIEW ARTICLE

CURRENT CONCEPTS

Community-Acquired Bacterial Meningitis
in AdultsDiederik van de Beek, M.D., Ph.D., Jan de Gans, M.D., Ph.D.,
Allan R. Tunkel, M.D., Ph.D., and Eelco F.M. Wijdicks, M.D., Ph.D.

From the Department of Neurology, Center of Infection and Immunity Amsterdam, Academic Medical Center, University of Amsterdam, Amsterdam (D.B., J.G.); the Department of Medicine, Monmouth Medical Center, Long Branch, N.J. (A.R.T.); and the Department of Neurology, Division of Critical Care Neurology, Mayo Clinic College of Medicine, Rochester, Minn. (E.F.M.W.). Address reprint requests to Dr. van de Beek at the Department of Neurology H2, Academic Medical Center, University of Amsterdam, P.O. Box 22660, 1100 DD Amsterdam, the Netherlands, or at d.vandebeek@amc.uva.nl.

N Engl J Med 2006;354:44-53.
Copyright © 2006 Massachusetts Medical Society.

BACTERIAL MENINGITIS IS A MEDICAL, NEUROLOGIC, AND SOMETIMES neurosurgical emergency that requires a multidisciplinary approach. Bacterial meningitis has an annual incidence of 4 to 6 cases per 100,000 adults (defined as patients older than 16 years of age), and *Streptococcus pneumoniae* and *Neisseria meningitidis* are responsible for 80 percent of all cases.^{1,2} A diagnosis of bacterial meningitis is often considered, but the disease can be difficult to recognize.¹⁻⁸ Recommendations for antimicrobial therapy are changing as a result of the emergence of antimicrobial resistance. In this review we summarize the current concepts of the initial approach to the treatment of adults with bacterial meningitis, highlighting adjunctive dexamethasone therapy and focusing on the management of neurologic complications.

INITIAL APPROACH

In adults presenting with community-acquired acute bacterial meningitis, the sensitivity of the classic triad of fever, neck stiffness, and altered mental status is low (44 percent), but almost all such patients present with at least two of four symptoms — headache, fever, neck stiffness, and altered mental status (as defined by a score below 14 on the Glasgow Coma Scale).¹ Lumbar puncture is mandatory in any patient in whom bacterial meningitis is suspected, although the procedure can be hazardous (Fig. 1 in the Supplementary Appendix, available with the full text of this article at www.nejm.org). Reports have emphasized the risk of brain herniation as a complication of diagnostic lumbar puncture in patients with meningitis.⁹⁻¹³ Patients with expanding masses (e.g., subdural empyema, brain abscess, or necrotic temporal lobe in herpes simplex encephalitis) may present with symptoms that appear to be identical with those of bacterial meningitis, and in these patients as well, lumbar puncture may be complicated by brain herniation.^{5,9} The withdrawal of cerebrospinal fluid reduces counterpressure from below, thereby adding to the effect of compression from above, increasing the brain shift that may already be present (Fig. 1).⁹ Neuroimaging — either cranial computed tomography (CT) or magnetic resonance imaging (MRI) — to detect brain shift is recommended as a precaution in selected patients before lumbar puncture.^{9,10} A prospective study involving 301 adults with suspected meningitis confirmed that clinical features can be used to identify patients who are unlikely to have abnormal findings on cranial CT (41 percent of the patients in this study).¹⁰ Of 235 patients who underwent cranial CT, in only 5 patients (2 percent) was bacterial meningitis confirmed, reflecting the heterogeneity of the study group with clinically suspected bacterial meningitis. Cranial imaging should precede lumbar puncture in patients who have new-onset seizures, an immunocompromised state, signs that are suspicious for space-occupying lesions, or moderate-to-severe impairment of consciousness.^{9,10,13} When these

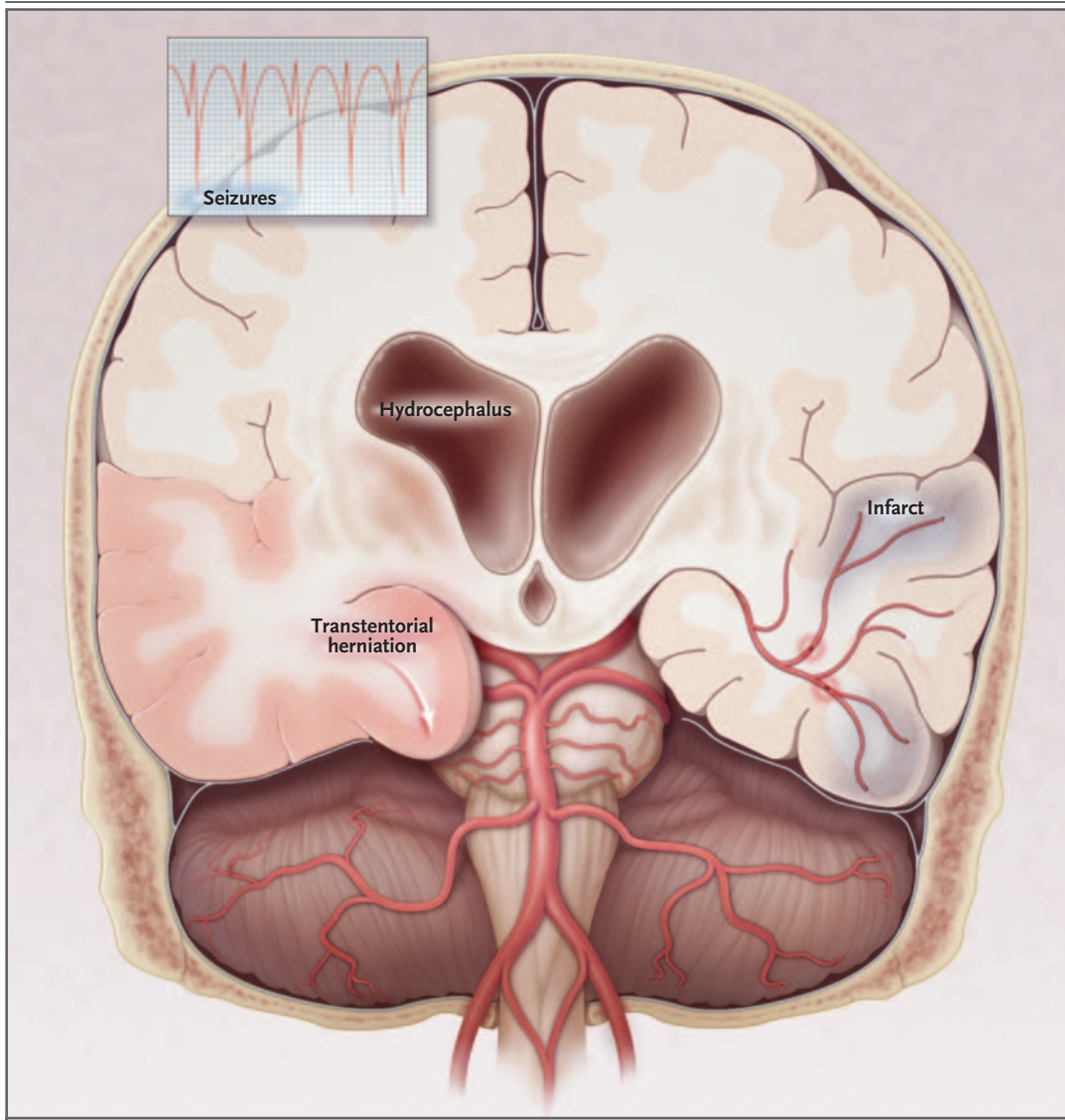


Figure 1. Major Intracranial Complications in Bacterial Meningitis in Adults.

Transtentorial herniation is caused by diffuse swelling of the brain, or hydrocephalus; the herniation may be asymmetrical when lateral focal lesions are present. Hydrocephalus results from basal obstruction of the cerebrospinal fluid. Infarcts are caused by inflammatory occlusion of the basal arteries. Seizures, as indicated on encephalograms, are caused by cortical inflammation.

criteria are met, indications for cranial imaging before lumbar puncture are present in about 45 percent of patients with bacterial meningitis confirmed by cerebrospinal fluid culture.¹ Lumbar puncture may also be harmful in patients with coagulopathy, because of the chance of needle-induced subarachnoid hemorrhage or of the development of spinal subdural and epidural hematomas.¹⁴ When a diagnosis of bacterial meningitis is probable but neuroimaging is not available, lumbar puncture should be given preference in patients

with moderate-to-severe impairment of consciousness or in an immunocompromised state. However, when warning signs of a space-occupying lesion (e.g., new-onset seizure, papilledema, or evolving signs of brain tissue shift) are present, lumbar puncture should not be performed until after neuroimaging has been performed.

Delay in the initiation of antimicrobial therapy can result in poor outcome in this disease. In a retrospective study, patients were stratified as having a low, intermediate, or high risk of adverse

outcome, according to baseline prognostic factors.¹⁵ The median delay between the time of arrival at the emergency department and the administration of antibiotics was four hours. Among patients whose condition worsened while they were in the emergency department to a category with a higher risk of having an adverse outcome, an association was found between the time of the start of antimicrobial therapy and outcome. Another retrospective study found an association between delays in administering antibiotics longer than six hours after arrival in the emergency department and death.¹⁶ Delay was most frequently due to the performance of cranial imaging before diagnostic lumbar puncture and the transfer of patients to another hospital. If imaging is performed before lumbar puncture, therapy should be initiated before the patient is sent for neuroimaging (Fig. 1 in the Supplementary Appendix). In patients who have not undergone prior imaging and in whom disease progression is apparent, therapy should be started directly after lumbar puncture, as well as in all patients with cloudy cerebrospinal fluid (suggesting the diagnosis of bacterial meningitis).¹⁴

The opening pressure of the cerebrospinal fluid is elevated in most patients with bacterial meningitis.^{1,5} In a prospective cohort study, 40 percent of the patients had very high opening pressures (>400 mm, as measured with the use of a water manometer), which were associated

with lower levels of consciousness but not with adverse outcome.¹ Cerebrospinal fluid findings are important in the differential diagnosis of patients with suspected meningitis.¹⁷ In this disease, pleocytosis (100 to 10,000 white cells per cubic millimeter), elevated protein levels (>50 mg per deciliter [0.5 g per liter]), and decreased cerebrospinal fluid glucose levels (<40 percent of simultaneously measured serum glucose) are usually present.^{1,4-8,17} There is usually a predominance of neutrophils (range, 80 to 95 percent) in the cerebrospinal fluid, but a predominance of lymphocytes can occur.^{1,4-8} Normal or marginally elevated cerebrospinal fluid white-cell counts occur in 5 to 10 percent of patients and are associated with an adverse outcome.¹

Gram's staining of cerebrospinal fluid permits the rapid identification of the causative organism (sensitivity, 60 to 90 percent; specificity, ≥97 percent).^{1,8} Bacterial antigen tests have a limited sensitivity, but they may be helpful in patients with findings consistent with bacterial meningitis and negative Gram's staining and cultures of cerebrospinal fluid.⁸ New molecular techniques for detecting bacteria in the cerebrospinal fluid by polymerase chain reaction (PCR) have emerged as powerful tools in the diagnosis of patients with negative cultures of cerebrospinal fluid; such tools have high sensitivity and specificity, although further refinements are needed before PCR can be routinely recommended.^{18,19}

Predisposing Factor	Common Bacterial Pathogen	Antimicrobial Therapy
Age		
16–50 yr	<i>Neisseria meningitidis</i> , <i>Streptococcus pneumoniae</i>	Vancomycin plus a third-generation cephalosporin†‡
>50 yr	<i>S. pneumoniae</i> , <i>N. meningitidis</i> , <i>Listeria monocytogenes</i> , aerobic gram-negative bacilli	Vancomycin plus a third-generation cephalosporin plus ampicillin‡§
Presence of a risk factor¶	<i>S. pneumoniae</i> , <i>L. monocytogenes</i> , <i>Haemophilus influenzae</i>	Vancomycin plus a third-generation cephalosporin plus ampicillin‡§

* For additional information, including alternative antimicrobial therapies, see Table 1 in the Supplementary Appendix, available with the full text of this article at www.nejm.org.

† Only in regions with very low rates of penicillin resistance (<1 percent), monotherapy with penicillin may be considered, although many experts recommend combination therapy for all patients until the results of in vitro susceptibility testing are available.

‡ Cefotaxime and ceftriaxone are the third-generation cephalosporins recommended.

§ Only in regions with very low rates of penicillin resistance and cephalosporin resistance, combination therapy with amoxicillin (ampicillin) and a third-generation cephalosporin may be considered.

¶ Risk factors include alcoholism and altered immune status.

The choice of initial antimicrobial therapy is based on the most common bacteria causing the disease according to the patient's age and the clinical setting and on patterns of antimicrobial susceptibility (Table 1).^{20,21} After the results of culture and susceptibility testing are available, antimicrobial therapy can be modified for optimal treatment (Table 1 in the Supplementary Appendix).^{20,21} With the worldwide increase in the prevalence of penicillin-resistant pneumococci, combination therapy with vancomycin plus a third-generation cephalosporin (either ceftriaxone or cefotaxime) has become the standard approach to empirical antimicrobial therapy.^{22,23} Although clinical data on the efficacy of rifampin in patients with pneumococcal meningitis are lacking, some authorities would use this agent in combination with a third-generation cephalosporin, with or without vancomycin, in patients with pneumococcal meningitis caused by bacterial strains that, on the basis of local epidemiology, are likely to be highly resistant to penicillin or cephalosporin. Such patients should also receive adjunctive dexamethasone therapy.

Respiratory isolation for 24 hours is indicated for patients with suspected meningococcal infection. Isolation is not required for those with signs of pneumococcal infection (otitis or pneumonia) or with bacteria other than *N. meningitidis* identified by Gram's staining. Persons who have close contact with the patient must receive chemoprophylaxis to eradicate meningococcal carriage (Table 1 in the Supplementary Appendix).^{8,23}

ADJUNCTIVE DEXAMETHASONE THERAPY

A recent randomized, placebo-controlled trial involving 301 adults with suspected meningitis in combination with cloudy cerebrospinal fluid, bacteria in the cerebrospinal fluid on Gram's staining, or a cerebrospinal fluid leukocyte count of more than 1000 per cubic millimeter showed that adjunctive treatment with dexamethasone before or with the first dose of antimicrobial therapy reduced the risk of unfavorable outcome from 25 percent to 15 percent (number needed to treat, 10 patients).²⁴ Mortality was reduced from 15 percent to 7 percent. The benefit was greatest in patients with intermediate disease severity, as defined by a score on the Glasgow Coma Scale on admission of 8 to 11 (scores can range from 3 to 15, with

15 indicating a normal level of consciousness), and in those with pneumococcal meningitis, in whom unfavorable outcomes declined from 52 percent to 26 percent (number needed to treat, four). In patients with pneumococcal meningitis, mortality was reduced from 34 percent to 14 percent. This benefit was a result of reduced mortality from systemic causes.²⁵ In addition, the benefits of dexamethasone were not offset by any apparent side effects of treatment with dexamethasone.

What are the practical implications of the results of this study?²⁴ First, in all patients whose condition fulfills the inclusion criteria of the study, dexamethasone (at a dose of 10 mg) should be initiated before or with the first dose of antibiotics and continued for four days (at a dose of 10 mg every six hours). Second, in patients with suspected meningitis, the results of the study support the administration of adjunctive dexamethasone with or before the first dose of empirical antibiotics, although the study did not specifically address this issue. This course may result in the unnecessary treatment of patients who do not have bacterial meningitis, but the potential benefits outweigh any potential risks associated with dexamethasone therapy. Therapy should be discontinued if the patient is found not to have bacterial meningitis. Third, dexamethasone should be continued for four days in patients with bacterial meningitis, regardless of microbial cause or clinical severity. The absence of a significant clinical benefit in some subgroups of patients does not rule out a beneficial effect of dexamethasone in these subgroups, because the study was not powered to analyze all subgroups of interest. Some experts, however, would discontinue dexamethasone if the meningitis is found to be caused by a bacterium other than *S. pneumoniae*.²¹

In a recent quantitative review of this topic that included the results of five clinical trials,²⁶ treatment with corticosteroids was associated with a significant reduction in mortality and neurologic sequelae. In the subgroup of patients with meningococcal meningitis, mortality (relative risk, 0.9; 95 percent confidence interval, 0.3 to 2.1) and neurologic sequelae (relative risk, 0.5; 95 percent confidence interval, 0.1 to 1.7) were both reduced, although the results were not statistically significant.

For some adults with suspected meningitis, however, adjunctive dexamethasone can be harmful (Fig. 1 in the Supplementary Appendix). Pa-

tients with septic shock and adrenal insufficiency benefit from corticosteroid therapy in physiologic doses and for longer than four days; however, when there is no evidence of relative adrenal insufficiency, therapy with corticosteroids may be detrimental.^{27,28} There are no controlled studies of the effects of corticosteroid therapy in a substantial number of patients with both meningitis and septic shock, and therefore corticosteroid therapy cannot be unequivocally recommended for such patients, although the use of low doses, as used by Annane et al.²⁷ (hydrocortisone, 50 mg every 6 hours, and fludrocortisone, 50 μ g daily), seems reasonable at present. Starting corticosteroids before or with the first dose of parenteral antimicrobial therapy appears to be more effective than starting corticosteroids after the first dose of antimicrobial therapy.²⁹ In experimentally induced pneumococcal meningitis in animals, bacterial concentrations in the cerebrospinal fluid at the start of therapy appeared to be a more important factor influencing the antimicrobial-induced inflammatory response than the time dexamethasone therapy was initiated.³⁰ There is a point after the first (parenteral) administration of an antimicrobial agent beyond which dexamethasone loses its effectiveness, but this point has not been clearly defined.

INTENSIVE CARE MANAGEMENT

Monitoring in a neurologic–neurosurgical intensive care unit is recommended in order to recognize changes in the patient's consciousness and the development of new neurologic signs, monitor for subtle seizures, and treat severe agitation effectively.³¹ Practical recommendations and admission criteria are given in Table 2 (and Fig. 1 in the Supplementary Appendix). Bacterial meningitis is often associated with septic shock, which is an important predictor of outcome.^{1,32} Patients with meningitis and septic shock may require insertion of a Swan–Ganz catheter, to measure cardiac output, the cardiac index, systemic vascular resistance, and pulmonary wedge pressures in order to assess intravascular volume and cardiac function.³¹ Adrenocorticoid insufficiency in patients with septic shock must be treated with low doses of corticosteroids.²⁷ Care should be taken to estimate and replace imperceptible fluid loss through the skin and lungs in patients who are febrile.³¹

Patients with bacterial meningitis are at risk of acute hyponatremia, although most cases are mild.^{1,8,32} Hyponatremia may be a result of cerebral salt wasting, the syndrome of inappropriate antidiuretic hormone secretion, or exacerbation by aggressive fluid resuscitation.^{31,33,34} This lack of clarity about the mechanism has resulted in the clinical dilemma with regard to whether intravenous fluids should be restricted in bacterial meningitis.³⁴ In children with bacterial meningitis, fluid restriction does not improve either brain edema or outcome.^{33,35} Therefore, adult patients with meningitis should be treated with the goal of a normovolemic state. A core body temperature of more than 40°C probably would need to be treated with techniques of cooling by conduction or antipyretic agents to avoid excessive fluid loss. In experimentally induced meningitis in animals, moderate hypothermia ameliorates inflammatory changes, although no clinical studies have been performed.^{36,37}

DECLINE IN CONSCIOUSNESS

For patients with a decline in consciousness, or those whose condition fails to improve after the initiation of appropriate antimicrobial therapy, brain imaging is indicated. The indication for repeated imaging is often arbitrarily based on the clinical status of the patient, the time between the decline in consciousness and the initiation of adequate therapy, and the results of previous imaging studies.

A common cause of a decline in consciousness in bacterial meningitis is clinical evidence of meningoencephalitis (Table 3). The release of proinflammatory mediators in the subarachnoid space leads to an inflammatory response in the central nervous system that contributes to an increased permeability of the blood–brain barrier, cerebral edema, and increased intracranial pressure.³⁸ On neuroimaging, early signs of brain edema are the disappearance of sylvian fissures and a narrowing of ventricular size. In patients with an advanced stage of brain edema and raised intracranial pressure, basal cisterns and sulci may become obliterated. Several supportive therapies have been described, although no therapy has been proved to have clinical efficacy.^{8,39–43}

A recent study in Sweden reported findings on the use of measurements of continuous intracranial pressure and cerebral perfusion pressure

Table 2. Management of Bacterial Meningitis in Adults in the Intensive Care Unit.**Neurocritical care**

In patients with a high risk of brain herniation, consider monitoring intracranial pressure and intermittent administration of osmotic diuretics (mannitol [25%] or hypertonic [3%] saline) to maintain an intracranial pressure of <15 mm Hg and a cerebral perfusion pressure of \geq 60 mm Hg

Initiate repeated lumbar puncture, lumbar drain, or ventriculostomy in patients with acute hydrocephalus

Electroencephalographic monitoring in patients with a history of seizures and fluctuating scores on the Glasgow Coma Scale*

Airway and respiratory care

Intubate or provide noninvasive ventilation in patients with worsening consciousness (clinical and laboratory indicators for intubation include poor cough and pooling secretions, a respiratory rate of >35 per minute, arterial oxygen saturation of <90% or arterial partial pressure of oxygen of <60 mm Hg, and arterial partial pressure of carbon dioxide of >60 mm Hg)

Maintain ventilatory support with intermittent mandatory ventilation, pressure-support ventilation, or continuous positive airway pressure

Circulatory care

In patients with septic shock, administer low doses of corticosteroids (if there is a poor response on corticotropin testing, indicating adrenocorticoid insufficiency, corticosteroids should be continued)

Initiate inotropic agents (dopamine or milrinone) to maintain blood pressure (mean arterial pressure, 70–100 mm Hg)

Initiate crystalloids or albumin (5%) to maintain adequate fluid balance

Consider the use of a Swan–Ganz catheter to monitor hemodynamic measurements

Gastrointestinal care

Initiate nasogastric tube feeding of a standard nutrition formula

Initiate prophylaxis with proton-pump inhibitors

Other supportive care

Administer subcutaneous heparin as prophylaxis against deep venous thrombosis

Maintain normoglycemic state (serum glucose level, <150 mg per deciliter), with the use of sliding-scale regimens of insulin or continuous intravenous administration of insulin

In patients with a body temperature of >40°C, use cooling by conduction or antipyretic agents

* Scores on the Glasgow Coma Scale can range from 3 to 15, with 15 indicating a normal level of consciousness.

in the treatment of patients with severe bacterial meningitis.⁴³ In this observational study, intracranial pressure was successfully lowered in most patients by a broad range of measures and with the use of an unconventional volume-targeted (“Lund concept”⁴³) intracranial pressure management protocol. The mean intracranial pressure was significantly higher and cerebral perfusion pressure was markedly decreased in patients who did not survive (in spite of treatment). Management of intracranial pressure is not routine in bacterial meningitis, and randomized comparative studies of various treatment regimens should be performed. Nevertheless, in patients with impending cerebral herniation, monitoring of intracranial pressure may be considered, but the outcome is expected to be poor. The use of osmotic diuretics

to control intracranial pressure may be an option, although there are no definitive data on the efficacy of this approach.^{31,43}

Seizures and acute hydrocephalus are other frequent causes of deteriorating consciousness.^{1,4,5} Patients with seizures or a clinical suspicion of prior seizure should receive anticonvulsant therapy, but the low incidence of this complication does not justify prophylaxis.¹ A rare cause of the deterioration of consciousness in meningitis is nonconvulsive status epilepticus.⁴⁴ If seizures have occurred and the patient does not awaken or consciousness waxes and wanes, an electroencephalogram is indicated. In patients with acute hydrocephalus, a lumbar puncture can allow the measurement of cerebrospinal fluid pressure.¹⁴ Repeated lumbar puncture or the placement of a

Table 3. Complications during the Clinical Course and Outcomes in Adults with Bacterial Meningitis.*

Complications	Frequency (%)	Outcome	Frequency (%)
Systemic complications		Score on Glasgow Outcome Scale	
Cardiorespiratory failure	29	1 (death)	21
Hyponatremia	26	2 (vegetative state)	<1
Disseminated intravascular coagulation	8	3 (severe disability)	3
Arthritis	2–6	4 (moderate disability)	10
Endocarditis/myocarditis	<1	5 (mild or no disability)	66
Deterioration of consciousness		Focal neurologic abnormalities	
Clinical evidence of meningoencephalitis	15–20	Cranial-nerve palsies	
Seizures	15–23	Third nerve	1
Brain edema	6–10	Sixth nerve	3
Hydrocephalus	3–8	Seventh nerve	1
Focal neurologic abnormalities		Eighth nerve	14
Cerebrovascular complications	15–20	Aphasia	2
Arterial infarction or vasculitis	10–15	Hemiparesis	4
Venous infarction	3–5	Quadriparesis	1
Hemorrhage	<1	Late effects	
Hearing loss	14–20	Cognitive impairment	10
Subdural empyema	<1		
Brain abscess	<1		
Myelitis	<1		

* Frequencies are for patients who are not routinely treated with early dexamethasone therapy; if routine dexamethasone therapy is provided, complications and the sequelae are expected to decline.

temporary lumbar drain may effectively reduce intracranial pressure; performing a ventriculostomy may also be considered.³¹ In patients with mild enlargement of the ventricular system with no clinical deterioration, a spontaneous resolution may occur, and invasive procedures are therefore withheld. Cerebral infarcts may involve large vascular territories and may cause brain swelling and a mass effect, which may result in a decline in consciousness.^{1,31}

FOCAL NEUROLOGIC ABNORMALITIES

In meningitis, focal cerebral abnormalities (hemiparesis, monoparesis, or aphasia) are most commonly caused by stroke, seizures, or a combination of the two (Table 3).^{1,4,32,45,46} Signs of cerebral infarction and cytotoxic edema on cranial imaging suggest septic arteritis or endarteritis obliterans, venous thrombophlebitis, or throm-

boembolic events (Fig. 2).^{4,45-47} Activation of inflammation and coagulation are closely related and interdependent.⁴⁸ The possibility of cerebral venous thrombophlebitis should be considered in patients with deterioration of consciousness, seizures, fluctuating focal neurologic abnormalities, and stroke with nonarterial distribution^{31,49}; MRI with venous-phase studies confirms the diagnosis.⁴⁹ Treatment of cerebral thrombophlebitis in bacterial meningitis is directed toward the infection.

In a patient with rapid deterioration, subdural empyema should be considered.⁵⁰ Clues to the diagnosis are the presence of sinusitis and mastoiditis (and recent surgery for either of these disorders). Seizures and *epilepsia partialis continua* are relatively common in patients with subdural empyema.⁵⁰ In most patients with subdural empyema, contrast-enhanced CT shows hypodense collections.^{31,50} However, MRI may be needed to image the localization of the subdural empyema

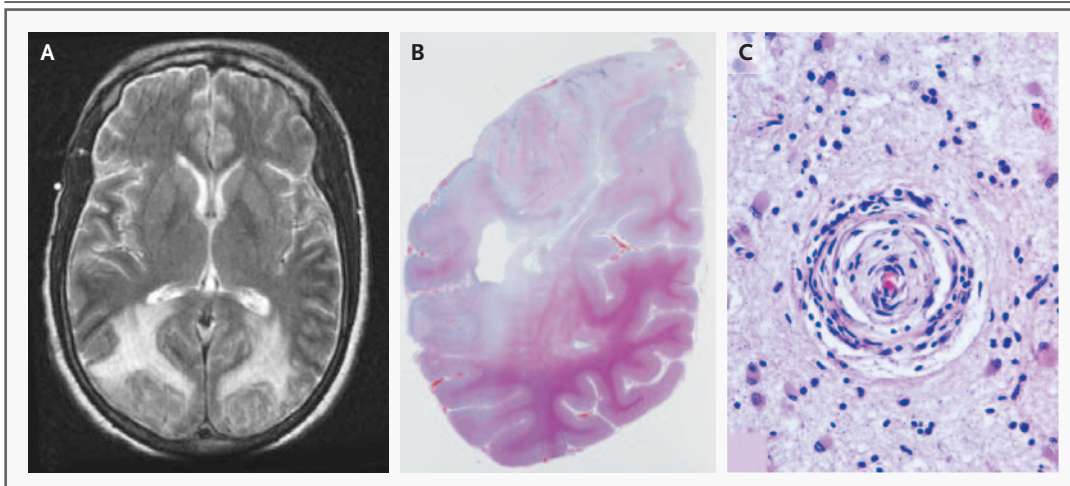


Figure 2. Cerebrovascular Complications in Bacterial Meningitis.

In Panel A, T₂-proton-density-weighted magnetic resonance imaging of the brain shows a transverse view of a hyperintense signal of the posterior lobes that indicates cerebral edema. In Panel B, a postmortem coronal view of the left posterior lobe of the same patient shows large areas of confluent necrosis involving the upper part of the hemisphere, as indicated by the loss of staining for hematoxylin and eosin. In Panel C, the microscopic substrate in the posterior lobe of this patient shows a small, almost completely obstructed vessel in the cortex with perivascular lymphocytic infiltration (endarteritis obliterans) that is surrounded by gliosis.

at the convexity.³¹ In the majority of patients with subdural empyema, surgical drainage by craniotomy is indicated.⁵⁰

Abnormalities of the cranial nerves are caused by the meningeal inflammatory process or by an increase in cerebrospinal fluid pressure.⁸ The most frequent cranial-nerve abnormality is the involvement of the eighth cranial nerve, which is reflected in a hearing loss in 14 percent of patients.¹ A cochlear implant may eventually be needed by some severely affected patients.⁵¹

REPEATED LUMBAR PUNCTURE

The analysis of the cerebrospinal fluid should be repeated only in patients whose condition has not responded clinically after 48 hours of appropriate antimicrobial therapy. Repeated lumbar puncture is especially essential in the treatment of patients with pneumococcal meningitis caused by penicillin-resistant or cephalosporin-resistant strains and who receive adjunctive dexamethasone therapy and vancomycin.^{21,26} Dexamethasone reduces inflammation of the cerebrospinal fluid and therefore may decrease the permeability of selected antimicrobial agents across the blood-brain barrier and, as a consequence, impede the penetration of vancomycin into the sub-

arachnoid space.^{26,52} Treatment failures have been reported in adults who received vancomycin and adjunctive dexamethasone.⁵³ If lumbar puncture is repeated, Gram's staining and culture of the cerebrospinal fluid should be negative after 24 hours of appropriate antimicrobial therapy.

OUTCOME

Community-acquired meningitis caused by *S. pneumoniae* has high case fatality rates, reported as from 19 to 37 percent.^{1,4-8,31,46} In up to 30 percent of survivors, long-term neurologic sequelae develop, including hearing loss and other focal neurologic deficits.^{1,4-8,32,46} The mortality and morbidity for meningococcal meningitis are lower than those for pneumococcal meningitis, with case fatality rates of 3 to 13 percent and morbidity rates of 3 to 7 percent.^{1,4-6} The strongest risk factors for an unfavorable outcome are those indicative of systemic compromise, impaired consciousness, low white-cell count in the cerebrospinal fluid, and infection with *S. pneumoniae*.¹ All cohort studies were performed before dexamethasone was routinely administered; now that routine dexamethasone therapy has been implemented, complications and sequelae are expected to decline.^{1,24,26} Cognitive impairment occurs fre-

quently after bacterial meningitis.⁵⁴ In one prospective study, cognitive impairment was detected in 27 percent of adults who had a good recovery from pneumococcal meningitis. Cognitive impairment consisted mainly of cognitive slowness, which was related to lower scores on questionnaires measuring the quality of life.⁵⁴

FUTURE DIRECTIONS

Recent advances in experimentally induced bacterial meningitis in animals include the role of oxygen–glucose deprivation of hippocampal neurons as a complication of meningitis, the role of cytokines, and the protective roles of nuclear factor- κ B1 and brain-derived neurotrophic factor.^{37,54-58} Although such advances are promising, it is unlikely that additional adjunctive therapies will be studied in controlled trials in patients with bacte-

rial meningitis. Progress is more likely to come from investigations into preventive measures, especially the use of available vaccines and the development of new vaccines.⁵⁹ Meningitis caused by *Haemophilus influenzae* type B has been nearly eliminated in the Western world since routine vaccination with the *H. influenzae* type B conjugate vaccine was initiated.⁵⁹ The introduction of conjugate vaccines against *S. pneumoniae* may substantially reduce the burden of childhood pneumococcal meningitis and may even produce herd immunity among adults.⁶⁰ The approval in 2005 of a conjugate meningococcal vaccine against serogroups A, C, Y, and W135 is also an important advance that may decrease the incidence of this devastating infection.⁶¹

No potential conflict of interest relevant to this article was reported.

We are indebted to Albert Hijdra, Dirk Troost, and Antonella Witmer.

REFERENCES

- van de Beek D, de Gans J, Spanjaard L, Weisfelt M, Reitsma JB, Vermeulen M. Clinical features and prognostic factors in adults with bacterial meningitis. *N Engl J Med* 2004;351:1849-59. [Erratum, *N Engl J Med* 2005;352:950.]
- Schuchat A, Robinson K, Wenger JD, et al. Bacterial meningitis in the United States in 1995. *N Engl J Med* 1997;337:970-6.
- Attia J, Hatala R, Cook DJ, Wong JG. The rational clinical examination: does this adult patient have acute meningitis? *JAMA* 1999;282:175-81.
- Dodge PR, Swartz MN. Bacterial meningitis — a review of selected aspects. II. Special neurologic problems, postmeningitic complications and clinicopathological correlations. *N Engl J Med* 1965;272:954-60.
- Durand ML, Calderwood SB, Weber DJ, et al. Acute bacterial meningitis in adults: a review of 493 episodes. *N Engl J Med* 1993;328:21-8.
- Sigurdardottir B, Bjornsson OM, Jonsson KE, Erlendsdottir H, Gudmundsson S. Acute bacterial meningitis in adults: a 20-year overview. *Arch Intern Med* 1997;157:425-30.
- Hussein AS, Shafran SD. Acute bacterial meningitis in adults: a 12-year review. *Medicine (Baltimore)* 2000;79:360-8.
- Tunkel AR. Bacterial meningitis. Philadelphia: Lippincott Williams & Wilkins, 2001.
- van Crevel H, Hijdra A, de Gans J. Lumbar puncture and the risk of herniation: when should we first perform CT? *J Neurol* 2002;249:129-37.
- Hasbun R, Abrahams J, Jekel J, Quagliarello VJ. Computed tomography of the head before lumbar puncture in adults with suspected meningitis. *N Engl J Med* 2001;345:1727-33.
- Oliver WJ, Shope TC, Kuhns LR. Fatal lumbar puncture: fact versus fiction — an approach to a clinical dilemma. *Pediatrics* 2003;112:174-6.
- Winkler F, Kastenbauer S, Yousry TA, Maerz U, Pfister HW. Discrepancies between brain CT imaging and severely raised intracranial pressure proven by ventriculostomy in adults with pneumococcal meningitis. *J Neurol* 2002;249:1292-7.
- van de Beek D, de Gans J. Prognostic factors in adults with bacterial meningitis. *N Engl J Med* 2005;352:514.
- Fishman RA. Cerebrospinal fluid in diseases of the nervous system. Philadelphia: Saunders, 1992.
- Aronin SI, Peduzzi P, Quagliarello VJ. Community-acquired bacterial meningitis: risk stratification for adverse clinical outcome and effect of antibiotic timing. *Ann Intern Med* 1998;129:862-9.
- Proulx N, Frechette D, Toye B, Chan J, Kravcik S. Delays in the administration of antibiotics are associated with mortality from adult acute bacterial meningitis. *QJM* 2005;98:291-8.
- Spanos A, Harrell FE Jr, Durack DT. Differential diagnosis of acute meningitis: an analysis of the predictive value of initial observations. *JAMA* 1989;262:2700-7.
- Rådström P, Bäckman A, Qian N, Kraggsbjerg P, Pålsson C, Olcén P. Detection of bacterial DNA in cerebrospinal fluid by an assay for simultaneous detection of *Neisseria meningitidis*, *Haemophilus influenzae*, and streptococci using a seminested PCR strategy. *J Clin Microbiol* 1994;32:2738-44.
- Schuurman T, de Boer RF, Kooistra-Smid AM, van Zwet AA. Prospective study of use of PCR amplification and sequencing of 16S ribosomal DNA from cerebrospinal fluid for diagnosis of bacterial meningitis in a clinical setting. *J Clin Microbiol* 2004;42:734-40.
- van de Beek D, de Gans J, Spanjaard L, Vermeulen M, Dankert J. Antibiotic guidelines and antibiotic use in adult bacterial meningitis in The Netherlands. *J Antimicrob Chemother* 2002;49:661-6.
- Tunkel AR, Hartman BJ, Kaplan SL, et al. Practice guidelines for the management of bacterial meningitis. *Clin Infect Dis* 2004;39:1267-84.
- Whitney CG, Farley MM, Hadler J, et al. Increasing prevalence of multidrug-resistant *Streptococcus pneumoniae* in the United States. *N Engl J Med* 2000;343:1917-24.
- Fraser A, Gafter-Gvili A, Paul M, Leibovici L. Antibiotics for preventing meningococcal infections. *Cochrane Database Syst Rev* 2005;1:CD004785.
- de Gans J, van de Beek D. Dexamethasone in adults with bacterial meningitis. *N Engl J Med* 2002;347:1549-56.
- van de Beek D, de Gans J. Dexamethasone and pneumococcal meningitis. *Ann Intern Med* 2004;141:327.
- van de Beek D, de Gans J, McIntyre P, Prasad K. Steroids in adults with bacterial meningitis: a systematic review. *Lancet Infect Dis* 2004;4:139-43.
- Annane D, Sebille V, Charpentier C,

- et al. Effect of treatment with low doses of hydrocortisone and fludrocortisone on mortality in patients with septic shock. *JAMA* 2002;288:862-71.
28. Cooper MS, Stewart PM. Corticosteroid insufficiency in acutely ill patients. *N Engl J Med* 2003;348:727-34.
29. van de Beek D, de Gans J, McIntyre P, Prasad K. Corticosteroids in acute bacterial meningitis. *Cochrane Database Syst Rev* 2003;3:CD004305.
30. Lutsar I, Friedland IR, Jafri HS, et al. Factors influencing the anti-inflammatory effect of dexamethasone therapy in experimental pneumococcal meningitis. *J Antimicrob Chemother* 2003;52:651-5.
31. Wijdicks EFM. *The clinical practice of critical care neurology*. 2nd ed. New York: Oxford University Press, 2003.
32. Pfister HW, Feiden W, Einhaupl KM. Spectrum of complications during bacterial meningitis in adults: results of a prospective clinical study. *Arch Neurol* 1993;50:575-81.
33. Oates-Whitehead R, Maconochie I, Baumer H, Stewart M. Fluid therapy for acute bacterial meningitis. *Cochrane Database Syst Rev* 2005;3:CD004786.
34. Harrigan MR. Cerebral salt wasting syndrome: a review. *Neurosurgery* 1996;38:152-60.
35. Täuber MG, Sande E, Fournier MA, Tureen JH, Sande MA. Fluid administration, brain edema, and cerebrospinal fluid lactate and glucose concentrations in experimental *Escherichia coli* meningitis. *J Infect Dis* 1993;168:473-6.
36. Angstwurm K, Reuss S, Freyer D, et al. Induced hypothermia in experimental pneumococcal meningitis. *J Cereb Blood Flow Metab* 2000;20:834-8.
37. Deng H, Han HS, Cheng D, Sun GH, Yenari MA. Mild hypothermia inhibits inflammation after experimental stroke and brain inflammation. *Stroke* 2003;34:2495-501.
38. Koedel U, Scheld WM, Pfister HW. Pathogenesis and pathophysiology of pneumococcal meningitis. *Lancet Infect Dis* 2002;2:721-36.
39. Lorenzl S, Koedel U, Pfister HW. Mannitol, but not allopurinol, modulates changes in cerebral blood flow, intracranial pressure, and brain water content during pneumococcal meningitis in the rat. *Crit Care Med* 1996;24:1874-80.
40. Möller K, Skinhoj P, Knudsen GM, Larsen FS. Effect of short-term hyperventilation on cerebral blood flow autoregulation in patients with acute bacterial meningitis. *Stroke* 2000;31:1116-22.
41. Paul R, Koedel U, Pfister HW. Reduction of intracranial pressure by nimodipine in experimental pneumococcal meningitis. *Crit Care Med* 2000;28:2552-6.
42. Grande PO, Myhre EB, Nordstrom CH, Schliamser S. Treatment of intracranial hypertension and aspects on lumbar dural puncture in severe bacterial meningitis. *Acta Anaesthesiol Scand* 2002;46:264-70.
43. Lindvall P, Ahlm C, Ericsson M, Gothefors L, Naredi S, Koskinen IO. Reducing intracranial pressure may increase survival among patients with bacterial meningitis. *Clin Infect Dis* 2004;38:384-90.
44. Mitchell WG. Status epilepticus and acute repetitive seizures in children, adolescents, and young adults: etiology, outcome, and treatment. *Epilepsia* 1996;37:Suppl 1:S74-S80.
45. Weststrate W, Hijdra A, de Gans J. Brain infarcts in adults with bacterial meningitis. *Lancet* 1996;347:399.
46. Kastenbauer S, Pfister HW. Pneumococcal meningitis in adults — spectrum of complications and prognostic factors in a series of 87 cases. *Brain* 2003;126:1015-25.
47. DiNubile MJ, Boom WH, Southwick FS. Septic cortical thrombophlebitis. *J Infect Dis* 1990;161:1216-20.
48. Levi M, van der Poll T, Buller HR. Bidirectional relation between inflammation and coagulation. *Circulation* 2004;109:2698-704.
49. Stam J. Thrombosis of the cerebral veins and sinuses. *N Engl J Med* 2005;352:1791-8.
50. Dill SR, Cobbs CG, McDonald CK. Subdural empyema: analysis of 32 cases and review. *Clin Infect Dis* 1995;20:372-86.
51. Gates GA, Miyamoto RT. Cochlear implants. *N Engl J Med* 2003;349:421-3.
52. Klugman KP, Friedland IR, Bradley JS. Bactericidal activity against cephalosporin-resistant *Streptococcus pneumoniae* in cerebrospinal fluid of children with acute bacterial meningitis. *Antimicrob Agents Chemother* 1995;39:1988-92.
53. Viladrich PF, Gudiol F, Linares J, et al. Evaluation of vancomycin for therapy of adult pneumococcal meningitis. *Antimicrob Agents Chemother* 1991;35:2467-72.
54. van de Beek D, Schmand B, de Gans J, et al. Cognitive impairment in adults with good recovery after bacterial meningitis. *J Infect Dis* 2002;186:1047-52.
55. Jiang X, Mu D, Manabat C, et al. Differential vulnerability of immature murine neurons to oxygen-glucose deprivation. *Exp Neurol* 2004;190:224-32.
56. Kastenbauer S, Koedel U, Weih F, Ziegler-Heitbrock L, Pfister HW. Protective role of NF-kappaB1 (p50) in experimental pneumococcal meningitis. *Eur J Pharmacol* 2004;498:315-8. [Erratum, *Eur J Pharmacol* 2004;504:235.]
57. Bifrare YD, Kummer J, Joss P, Tauber MG, Leib SL. Brain-derived neurotrophic factor protects against multiple forms of brain injury in bacterial meningitis. *J Infect Dis* 2005;191:40-5.
58. Kim KS. Pathogenesis of bacterial meningitis: from bacteraemia to neuronal injury. *Nat Rev Neurosci* 2003;4:376-85.
59. Swartz MN. Bacterial meningitis — a view of the past 90 years. *N Engl J Med* 2004;351:1826-8.
60. Whitney CG, Farley MM, Hadler J, et al. Decline in invasive pneumococcal disease after the introduction of protein-polysaccharide conjugate vaccine. *N Engl J Med* 2003;348:1737-46.
61. Prevention and control of meningococcal disease: recommendations of the Advisory Committee on Immunization Practices (ACIP). *MMWR Recomm Rep* 2005;54(RR-7):1-21.

Copyright © 2006 Massachusetts Medical Society.

JOURNAL INDEX

The index to volume 353 of the *Journal* will be available on February 23, 2006. At that time, it can be downloaded free in PDF format from www.nejm.org.