

Laser-Induced Changes in Intraretinal Oxygen Distribution in Pigmented Rabbits

Dao-Yi Yu,¹ Stephen J. Cringle,¹ Erning Su,¹ Paula K. Yu,¹ Mark S. Humayun,² and Giorgio Dorin³

PURPOSE. To make the first measurements of intraretinal oxygen distribution and consumption after laser photocoagulation of the retina and to compare the efficiency of micropulsed (MP) and continuous wave (CW) laser delivery in achieving an oxygen benefit in the treated area.

METHODS. Oxygen-sensitive microelectrodes were used to measure oxygen tension as a function of retinal depth before and after laser treatment in anesthetized, mechanically ventilated, Dutch Belted rabbits ($n = 11$). Laser lesions were created by using a range of power levels from an 810-nm diode laser coupled with an operating microscope delivery system. MP duty cycles of 5%, 10%, and 15% were compared with CW delivery in each eye.

RESULTS. Sufficient power levels of both the CW and MP laser reduced outer retinal oxygen consumption and increased oxygen level within the retina. At these power levels, which correlated with funduscopically visible lesions, there was histologically visible damage to the RPE and photoreceptors. Retinal damage was energy dependent but short-duty-cycle MP delivery was more selective in terms of retinal cell damage, with a wider safety range in comparison with CW delivery.

CONCLUSIONS. The relationship between laser power level and mode of delivery and the resultant changes in oxygen metabolism and oxygen level in the retina was determined. Only partial destruction of RPE and photoreceptors is necessary, to produce a measurable oxygen benefit in the treated area of retina. (*Invest Ophthalmol Vis Sci.* 2005;46:988-999) DOI: 10.1167/iovs.04-0767

Diabetic retinopathy and ischemic retinal diseases are major causes of blindness in the Western world. The sequelae of diabetic retinopathy are predominantly due to the microangiopathy of the retina, which leads to ischemia. Ischemia, through a number of mechanisms, leads to blood-ocular barrier breakdown and abnormal new vessel growth. Scatter pan-retinal photocoagulation (PRP) therapy has been used for >30 years and is currently the mainstay of therapy for diabetic retinopathy.^{1,2} Laser photocoagulation has been shown to be effective in the treatment of diabetic retinopathy in a series of

major studies.³⁻⁷ Conventional laser application, however, is destructive to the retina and is not without side effects. Extensive damage to photoreceptors results in loss of night vision, reduced visual field, and decreased contrast sensitivity in a substantial number of patients.^{8,9}

Serial observations of patients with nonproliferative diabetic retinopathy have shown that the appearance, or worsening, of certain intraretinal lesions is a crucial risk factor for the development of ocular neovascularization on the surface of the retina.¹⁰ Such intraretinal lesions include: extensive retinal hemorrhages and/or microaneurysms, cotton-wool spots, and intraretinal microvascular abnormalities. Thus, it appears that intraretinal changes are the initiating factors in the sight-threatening complications of proliferative diabetic retinopathy. It is essential to develop a new therapeutic strategy to target treatment to the critical cell layers responsible for producing these intraretinal lesions. Better-targeted therapy has the potential to create the required therapeutic outcome, yet reduce the extent of retinal damage and visual loss. If such a strategy were to be equally efficacious with fewer deleterious side effects, it would be a significant advance and of great value to patients.

Although there is a strong case for the importance of improved retinal oxygenation benefit after laser therapy,¹¹⁻¹³ the degree to which oxygenation is necessary to produce the desired therapeutic outcome is unknown. Current understanding is that the laser-induced destruction of oxygen-consuming cells in the outer retina leads to an improved delivery of oxygen from the choroid to the ischemic inner retina and vitreous.¹⁴ However, this effect has been surprisingly difficult to demonstrate experimentally. Remarkably, there have been no previous studies of the changes in retinal oxygen consumption after laser photocoagulation treatment. The rabbit is a particularly suitable animal model for such work. The retina is predominantly avascular,¹⁵ and, in the avascular regions, any confounding influence of retinal vasculature can be avoided. In the avascular region, the oxygen supply to the entire thickness of retina is derived from the choroid.¹⁶ Consequently, any changes in outer retinal oxygen consumption may be expected to produce a relatively simple modulation of oxygen supply to the inner retina.

The primary effect of laser treatment is thermal damage, mainly induced at the level of the RPE. However, concurrent damage to adjacent retinal layers, such as the photoreceptors and choriocapillaris may occur as a consequence of heat transmission. Current photocoagulation techniques, when performed with conventional continuous wave (CW) lasers, cause significant damage to the neural retina by thermal spread from the RPE. Micropulse techniques are now available and are reported to produce more localized photocoagulation of the RPE and photoreceptors.^{17,18} This is thought to be achievable because the short duration of micropulse laser energy limits the degree of thermal spread, thus concentrating the effects of the laser at the absorption site.¹⁹ The difference in the reaction of the tissue to these two modes of delivery can be marked.^{18,20,21} Choosing longer wavelengths (810 nm) can also provide more selective targeting of the RPE. The primary site of absorption of 810-nm laser energy is the highly pig-

From the ¹Centre for Ophthalmology and Visual Science, The University of Western Australia, Perth, Australia; the ²Doheny Eye Institute, University of Southern California, Los Angeles, California; and ³Iridex Corporation, Mountain View, California.

Supported by the National Health and Medical Research Council of Australia.

Submitted for publication June 30, 2004; revised September 16 and November 15, 2004; accepted November 20, 2004.

Disclosure: **D.-Y. Yu**, None; **S.J. Cringle**, None; **E. Su**, None; **P.K. Yu**, None; **M. Humayun**, None; **G. Dorin**, Iridex Corporation (E)

The publication costs of this article were defrayed in part by page charge payment. This article must therefore be marked "advertisement" in accordance with 18 U.S.C. §1734 solely to indicate this fact.

Corresponding author: Dao-Yi Yu, Centre for Ophthalmology and Visual Science, The University of Western Australia, Nedlands, Perth, Western Australia 6009, Australia; dyyu@cylene.uwa.edu.au.

mented RPE. The photoreceptors absorb a lower percentage of incident light at this wavelength, when compared with the more-conventional green lasers. Further studies are needed to determine the optimal micropulse parameters that create the minimum damage to retinal cells necessary to produce the required oxygenation benefit to ameliorate the stimulus of vasoproliferation in the ischemic or diabetic retina. As a first step in this process, it is critical that we better understand the relationship between different forms of laser treatment and their influence on the intraretinal oxygen environment. The present study in the rabbit retina provides perhaps the simplest model in which the immediate effects of laser photocoagulation on the intraretinal oxygen environment can be determined.

METHODS

General

Eleven Dutch Belted (pigmented) rabbits were used in the study. The experimental techniques were similar to those reported in our earlier publications in rabbits^{16,22,23} and other species.^{24–26} Anesthesia was induced by an intramuscular injection of ketamine (50 mg/kg) and xylazine (3 mg/kg) and was followed by an intravenous infusion of ketamine (10 mg/kg) and xylazine (3 mg/kg) infused at a rate sufficient to maintain anesthesia throughout the experiment. The animals were ventilated with air at 30 breaths per minute, using a tidal volume sufficient to produce blood gas levels within the normal range. Arterial blood pressure was monitored continuously throughout the experiment. Experiments usually lasted 5 hours, after which the rabbit was killed with an anesthetic overdose and the treated eye harvested for histologic study. All procedures conformed to the ARVO Statement for the Use of Animals in Ophthalmic and Vision Research.

Intraretinal Oxygen Profiles

Oxygen-sensitive microelectrodes were used to measure the oxygen level as a function of retinal depth in the same retinal location before and after laser treatment. All measurements were made in the inferior retina of the left eye. Oxygen-sensing microelectrodes were manufactured in our laboratory using techniques developed by Whalen et al.²⁷ The electrodes were calibrated before and after the experiment. In each experiment, the head of the animal was immobilized in a stereotaxic frame and the eye stabilized by suturing to an eye ring at the limbus. The oxygen-sensitive microelectrode entered the eye through a small hole at the pars plana and was visualized inside the eye by an operating microscope via a plano-concave contact lens. The electrode was oriented with a stereotaxic apparatus.²⁸ The small size of the electrode tip (1 μm) coupled with a high-acceleration piezoelectric translation of the electrode through the retina produced highly reproducible measurements of intraretinal oxygen distribution. Under microscope observation, the electrode tip was placed just anterior to the chosen area of retina. The electrode was then stepped through the retina (10- μm steps), under computer control, until a peak oxygen level was reached within the choroid. The measurement was then repeated during stepwise withdrawal of the electrode. Although very close agreement between the insertion and withdrawal profiles was routinely achieved, the withdrawal profiles were used for data analysis, as they tended to be less influenced by artifacts associated with mechanical stress on the electrode tip during penetration.²⁴ Only artifact-free withdrawal profiles were included in the subsequent oxygen-consumption analysis. All measurements were performed under photopic conditions.

Laser Applications

An 810-nm infrared laser (OcuLight SLx; Iridex Medical Instruments Inc, Mountain View, CA) was used. Laser exposures were centered on the area of retina most recently measured. Spot size was always 300

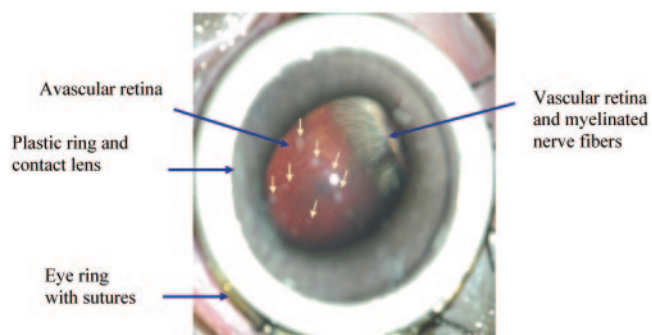


FIGURE 1. Fundus photograph of the inferior retina of the rabbit at the conclusion of the experiment. Several laser lesions are visible (arrows), along with an eye ring at the limbus and a plano-concave contact lens with a supporting plastic ring.

μm , but the power, duration, duty cycle, and mode of delivery (MP/CW) were manipulated. Spacing between treatment sites was no less than 500 μm . Intraretinal oxygen distribution was measured before and after laser application. The visual appearance of the laser-induced lesions (Fig. 1) was monitored with the operating microscope.

The choice of laser parameters was designed to span the range producing no visible lesion up to a clearly visible "gray spot" lesion in the treated area. CW delivery and three duty cycles of MP delivery (15%, 10%, and 5%) were compared in each eye. The modulation envelope of a CW laser pulse is rectangular, with the laser power reaching the selected peak virtually instantaneously and then being maintained for the duration of the pulse. However, with the micropulse mode enabled, the laser energy is delivered in a burst of short pulses. The duty cycle represents the percentage of time the laser energy is delivered during the pulse burst. Individual micropulses were delivered every 2 ms, and so duty cycles of 15%, 10%, and 5% were produced by micropulse durations of 0.3, 0.2, and 0.1 ms, respectively. CW delivery was used at power levels of 100, 150, 200, and 250 mW, all with a pulse duration of 200 ms. With 15% MP delivery, the chosen power levels were 500, 750, 1000, and 1500 mW. For 10% MP delivery the powers were 750, 1000, 1250, and 1500 mW. Pulse duration for both 15% and 10% MP delivery was 200 ms. Because of the lesser degree of tissue reaction to 5% MP delivery and the maximum power setting available of 1500 mW, the varied parameter for 5% MP delivery was the duration of exposure. Exposure times of 500, 1000, and 2000 ms were used. Because of the limited area of fundus that was accessible for both microelectrode positioning and laser delivery, a maximum of 10 treatment sites were used in each eye.

Mathematical Models

For the oxygen-consumption analysis a modified form of the model of Haugh et al.²⁹ was used. The model was expanded to include five layers, which allowed us to separate the oxygen-consumption rates of the outer and inner retina, along with the oxygen gradients in diffusion zones at the boundaries with the choroid and vitreous and between the outer and inner retina. The boundaries between each of the five layers were not fixed; rather, the position of the boundaries was determined by the best fit to the experimental data. The model has been used to determine the oxygen-consumption rates in the avascular region of the normal rabbit retina.^{16,23} The oxygen-consumption analysis is based on a multilayer solution to Fick's law of diffusion, but the essence of the analysis is that the oxygen consumption is greatest where the oxygen gradient changes most rapidly. In common with earlier work, the model was simplified by assuming that all the oxygen consumption was concentrated into layers Q_2 and Q_4 , with Q_2 being located in the outer retina and Q_4 located in the inner retina.^{16,23} A full description of the principles for the derivation of similar models of retinal oxygen consumption are presented elsewhere.^{25,30} A least-means-squared fit between the mathematical models and the intraretinal oxygen distri-

bution was performed to extract the oxygen-consumption parameters. No correction was made for the nonperpendicular electrode track through the retina. Although this angle varies slightly at different retinal locations, we were primarily interested in the before and after treatment conditions, and the penetration angle, although not precisely known, was the same in both instances. In some profiles the electrode track in the innermost retina may have been influenced by adjacent "untreated" retina. However, in the deeper retina, great care was taken to ensure that the electrode track passed through as close to the center of the lesion as possible. To avoid any influence of such edge effects in the inner retina, no attempt was made to extract oxygen-consumption values for the inner retina. Our analysis considers only outer retinal oxygen consumption, which was assumed to take place no more than 125- μ m track distance from the outer retinal boundary with the choroid.

Because the oxygen profiles were measured within minutes after laser application, we believe that retinal swelling and edema would have been far less than was indicated by the subsequent histologic examinations, which were performed on eyes fixed several hours after initial laser application.

Retinal Histology

At the completion of the acute experiment, the eyes were enucleated and used for histologic studies to characterize the retinal structure after laser treatment. The whole eye was immersed in phosphate-buffered 2.5% glutaraldehyde for a minimum of 24 hours. The anterior segment and vitreous were removed, and full-thickness pieces of the eye wall were dissected from the treated regions of the inferior retina, postfixed in phosphate-buffered 2% osmium tetroxide, dehydrated in graded ethanols, and embedded in epoxy resin for light microscopy. Retinal sections (2 μ m thick) from the center of the lesion were stained with toluidine blue for light microscopy.

Statistics

All statistical testing was performed on computer (SigmaStat; SPSS Scientific; Chicago, IL). To allow a comparison of oxygen tension changes in different regions of the retina after laser treatment, the oxygen tension profiles were divided into three equal zones: the inner, the middle, and the outer retina. The outer retinal boundary was chosen to be coincident with Bruch's membrane, so the plateau region within the choroid was not included in the analysis. Two-way ANOVA with an acceptance level of $P < 0.05$ was then used to determine any significant differences in the average oxygen tension in the inner, middle, and outer retina before and after laser treatment. A paired t -test was used to determine any significant differences in outer retinal oxygen consumption before and after laser treatment. All mean data are expressed as the mean \pm SE, and all error bars on graphs are also standard errors.

RESULTS

Intraretinal Oxygen Distribution before Laser Treatment

Figure 2 shows the average oxygen level as a function of track distance through the retina and choroid in a total of 98 locations in 11 rabbit eyes immediately before laser treatment. The intraretinal oxygen distribution reflects the fact that the choroid is the only source of retinal oxygenation in the avascular area of the rabbit retina. The peak choroidal P_{O_2} was 72.8 ± 1.7 mm Hg. P_{O_2} declines with increasing distance from the choroid, reaching an average value of 4.9 ± 0.4 mm Hg at the retinal surface. Oxygen consumption of the outer retina was calculated from the best fit of the mathematical model to each of the 98 oxygen profiles. The average value for outer retinal oxygen consumption was 243.3 ± 9.2 nL O_2/cm^2 per minute.

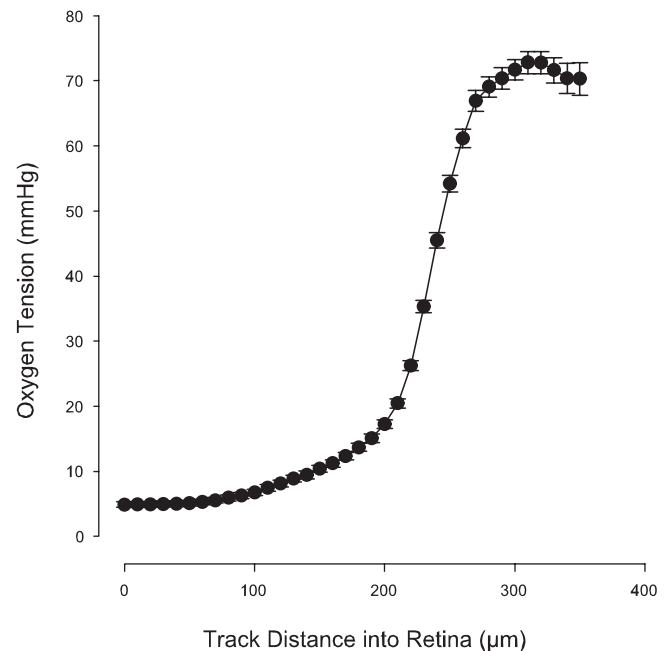


FIGURE 2. Average oxygen profile as a function of retinal track distance for all locations before laser application. The intraretinal oxygen distribution reflects the fact that the choroid is the only source of retinal oxygenation in the avascular region of the rabbit retina.

Effects of CW Laser on Intraretinal Oxygen Distribution

Figure 3 shows the average intraretinal oxygen distribution before and after delivery of CW laser at four different power levels. At a CW power level of 100 mW ($n = 8$) there was no significant difference in the oxygen-consumption rate in the outer retina ($P = 0.234$) and no significant increase in the inner, middle, or outer retinal oxygen tension ($P = 0.918$, 0.945 , and 0.933 , respectively). At a power level of 150 mW ($n = 6$) there was a significant (80.4%) reduction in the oxygen consumption in the outer retina ($P < 0.05$) and a significant increase in average oxygen tension across the inner, middle, and outer retina (86.5%, 174.2%, and 62.0%, respectively, all $P < 0.001$). At a power level of 200 mW ($n = 8$) outer retinal oxygen consumption was significantly reduced (88.3%; $P < 0.001$). Average oxygen levels across the inner, middle, and outer retina were increased by 86.5%, 108.6%, and 36.5%, respectively. Peak choroidal oxygen level was reduced from 64.4 ± 7.0 to 53.9 ± 4.9 mm Hg ($P < 0.05$). At a power level of 250 mW ($n = 7$) outer retinal oxygen consumption was significantly reduced (96.9%; $P < 0.001$). Average oxygen levels across the inner, middle, and outer retina were increased by 103.6%, 146.0%, and 53.7%, respectively. Peak choroidal oxygen level was reduced from 74.2 ± 6.4 to 59.6 ± 5.7 mm Hg ($P < 0.05$).

Effects of MP Laser on Intraretinal Oxygen Distribution

Fifteen Percent Duty Cycle. Figure 4 shows the average intraretinal oxygen distribution before and after delivery of MP laser at a duty cycle of 15% at four different power levels. At a power level of 500 mW ($n = 5$) there was no significant difference in the oxygen-consumption rate in the outer retina ($P = 0.85$) and no significant increase in retinal oxygen tension in the inner, middle, or outer retina ($P = 0.513$, 0.933 , and 0.732 , respectively). At a power level of 750 mW ($n = 5$) there was a reduction in the oxygen consumption in the outer retina

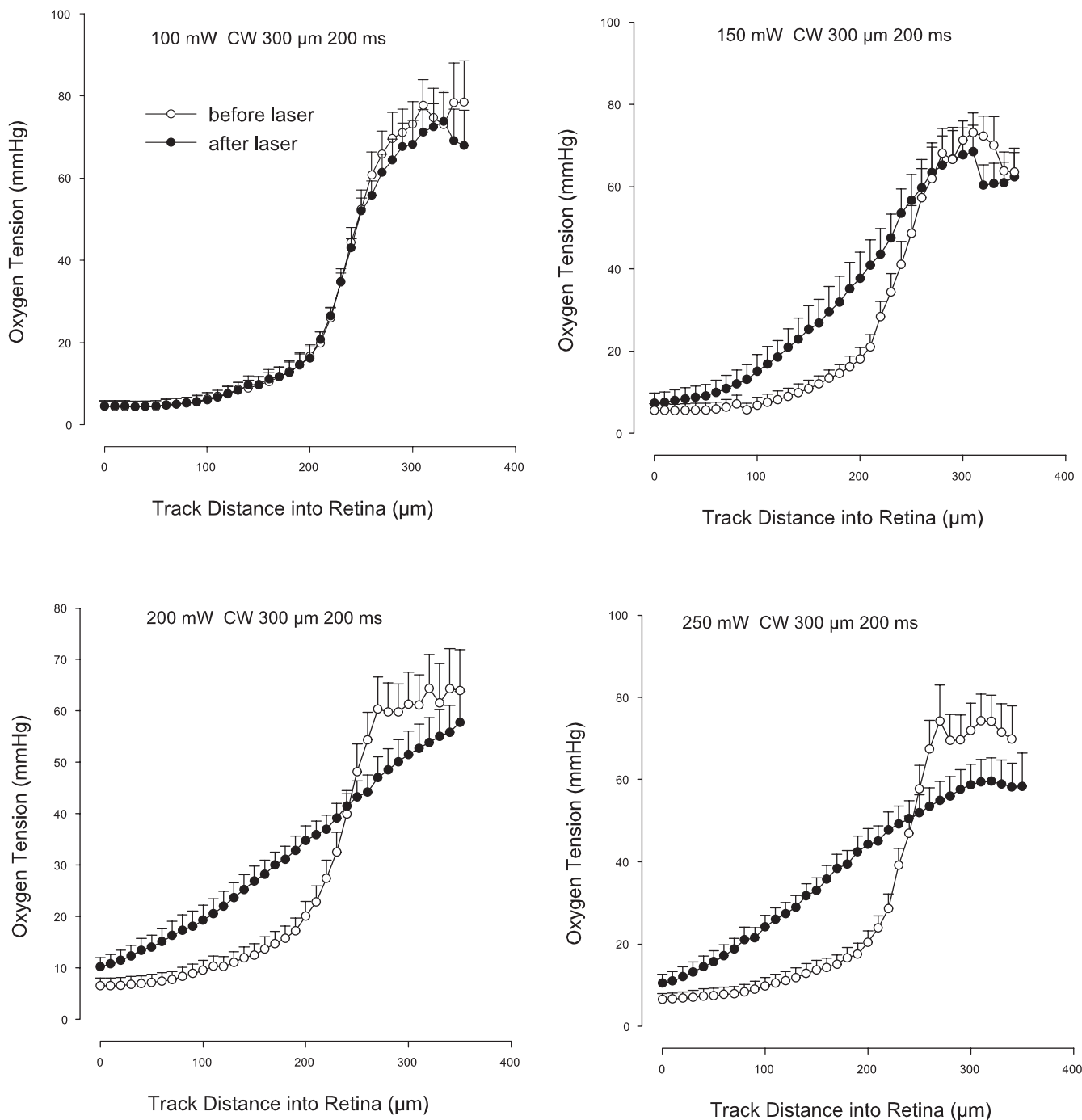


FIGURE 3. Average levels of intraretinal oxygen tension as a function of track length into the retina and choroid before and after CW laser treatment at power levels shown.

that did not reach statistical significance ($P = 0.087$). The increase in retinal oxygen level in the inner, middle, and outer retina (52.3%, 83.8%, and 40.0%, respectively) was significant ($P < 0.05$, <0.001 , and <0.001 respectively). At a power level of 1000 mW ($n = 6$), outer retinal oxygen consumption was significantly reduced (74.4%, $P < 0.05$). Average retinal oxygen levels in the inner, middle, and outer retina were significantly increased (63.6%, $P < 0.05$; 123.7%, $P < 0.001$; and 76.6%, $P < 0.001$, respectively).

At a power level of 1500 mW ($n = 7$), outer retinal oxygen consumption was significantly reduced (92.6%, $P < 0.001$). Average retinal oxygen levels in the inner, middle, and outer

retina were significantly increased (72.7%, 123.9%, and 41.9%, all $P < 0.001$, respectively). With 15% MP at 1500 mW there was a significant reduction ($P < 0.001$) in peak choroidal Po_2 , reducing from 67.9 ± 8.4 to 53.5 ± 4.2 mm Hg after treatment.

Ten Percent Duty Cycle. Figure 5 shows the average intraretinal oxygen distribution before and after delivery of MP laser at a duty cycle of 10% at four different power levels. At a power level of 750 mW ($n = 6$) there was no significant difference in the oxygen-consumption rate in the outer retina ($P = 0.782$) and no significant increase in retinal oxygen tension in the inner, middle, and outer retina ($P = 0.826$, 0.948, and 0.923, respectively). At a power level of 1000 mW

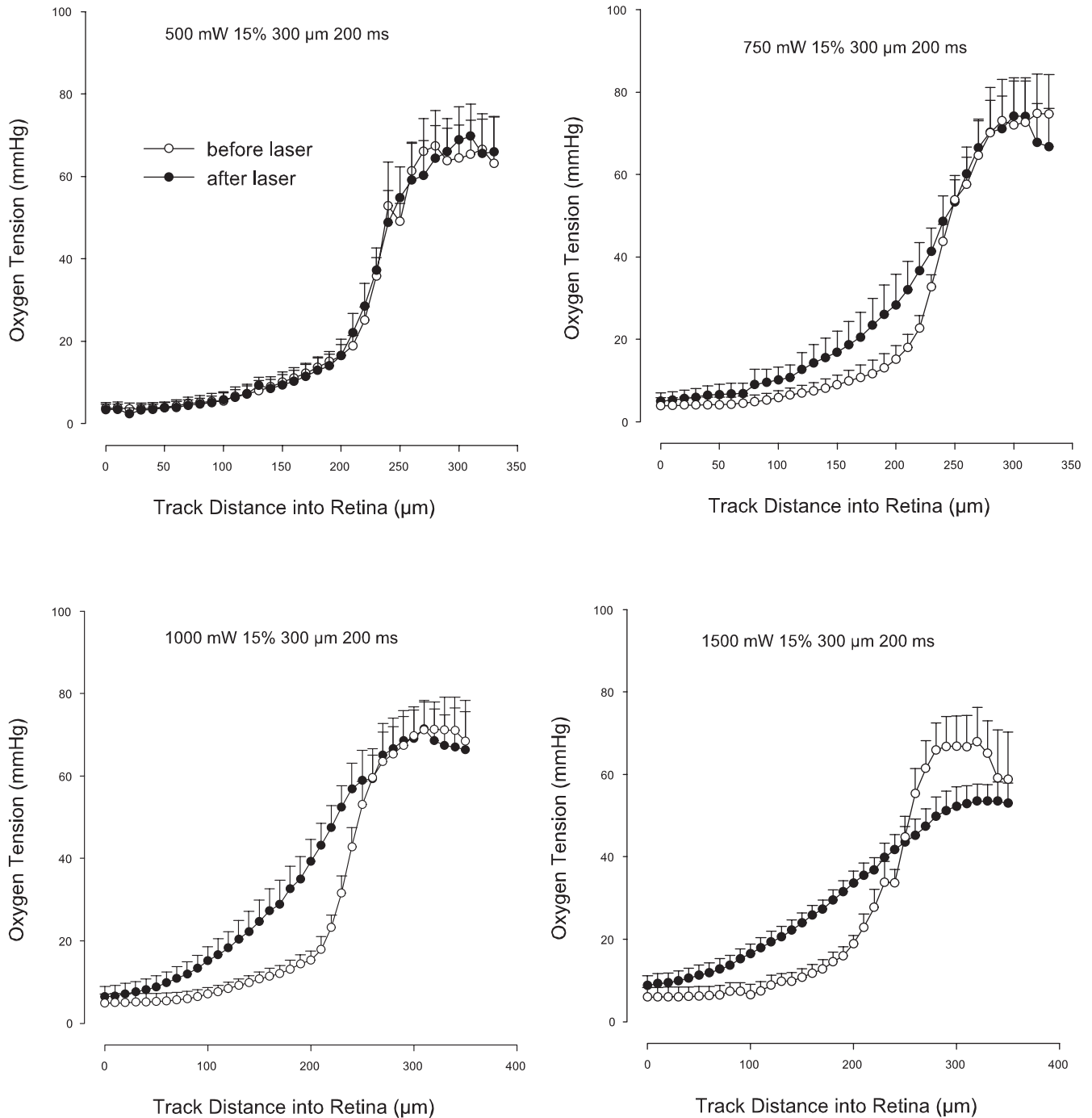


FIGURE 4. Average levels of intraretinal oxygen tension as a function of track length into the retina and choroid before and after 15% duty cycle MP laser treatment at power levels shown.

($n = 8$) the reduction in oxygen consumption (7.5%) in the outer retina was not statistically significant ($P = 0.358$), and the increase in retinal oxygen level in the inner, middle, and outer retina (20.2%, 15.7% and 6.2%, respectively) was not statistically significant ($P = 0.078, 0.103, \text{ and } 0.175$, respectively). At power levels of 1250 ($n = 5$) and 1500 ($n = 9$) mW, outer retinal oxygen consumption was significantly reduced (57.2%, $P < 0.05$ and 86.8%, $P < 0.001$). At a power level of 1250 mW, average retinal oxygen levels in the inner, middle, and outer retina were significantly increased (82.5%, 103.6%, and 36.9%; all $P < 0.001$). At a power level of 1500 mW ($n = 9$), average retinal oxygen levels in the inner, middle, and outer

retina were significantly increased (75.3%, 139.6%, and 46.5%; all $P < 0.001$). Peak choroidal oxygen level was not affected, even at the 1500-mW level with a 10% duty cycle ($P = 0.121$).

Five Percent Duty Cycle. Figure 6 shows the average intraretinal oxygen distribution before and after delivery of MP laser at a duty cycle of 5%, at the maximum power level available in this model of laser machine, and at three different durations. At a duration of 500 ms ($n = 6$) there was no significant difference in the oxygen-consumption rate in the outer retina ($P = 0.939$) and no significant increase in retinal oxygen tension in the inner, middle, and outer retina ($P = 0.251, 0.423, \text{ and } 0.1$, respectively). At a duration of 1000 ms

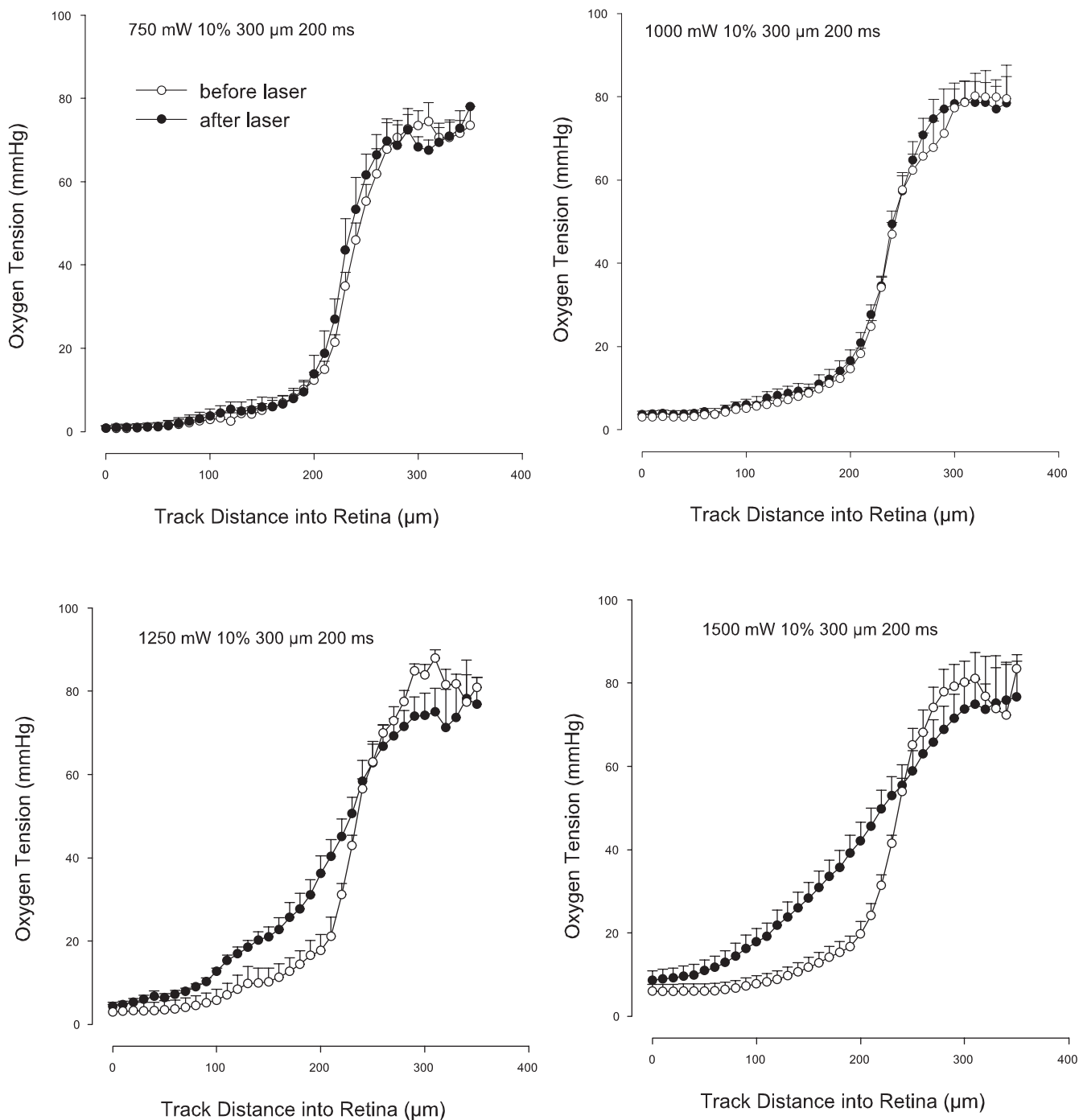


FIGURE 5. Average levels of intraretinal oxygen tension as a function of track length into the retina and choroid before and after 10% duty cycle MP laser treatment at power levels shown.

($n = 6$) the 40.6% reduction in the oxygen consumption in the outer retina was statistically significant ($P = 0.030$). The increase in retinal oxygen level in the inner, middle, and outer retina (60.7%, 64.0%, and 32.3%, respectively) was significant ($P < 0.05$, 0.001, and 0.001, respectively). At a duration of 2000 ms ($n = 6$) outer retinal oxygen consumption was significantly reduced (44.4%, $P < 0.05$) and average retinal oxygen levels were significantly increased in the inner, middle, and outer retina (68.7%, $P < 0.05$; 101.6%, $P < 0.001$; and 44.7%, $P < 0.001$, respectively). Peak choroidal oxygen level was not affected even at 2000 ms exposure at the 1500 mW power level with a 5% duty cycle ($P = 0.578$).

Effects of CW and MP Laser on Retinal Morphology

Figure 7 shows light micrographs of acute retinal lesions produced in pigmented rabbits by CW laser irradiation using power levels of (A) 100, (B) 150, (C) 200, and (D) 250 mW (all with pulse duration 200 ms and spot size 300 μm). Graded retinal damage was produced at increasing power levels. At 100 mW (Fig. 7A), the retina and the pigment epithelium were mildly edematous, the pigment epithelium appeared irregularly pigmented, and the outer segments of the photoreceptor cells were deranged. With 150 mW (Fig. 7B), more extensive swell-

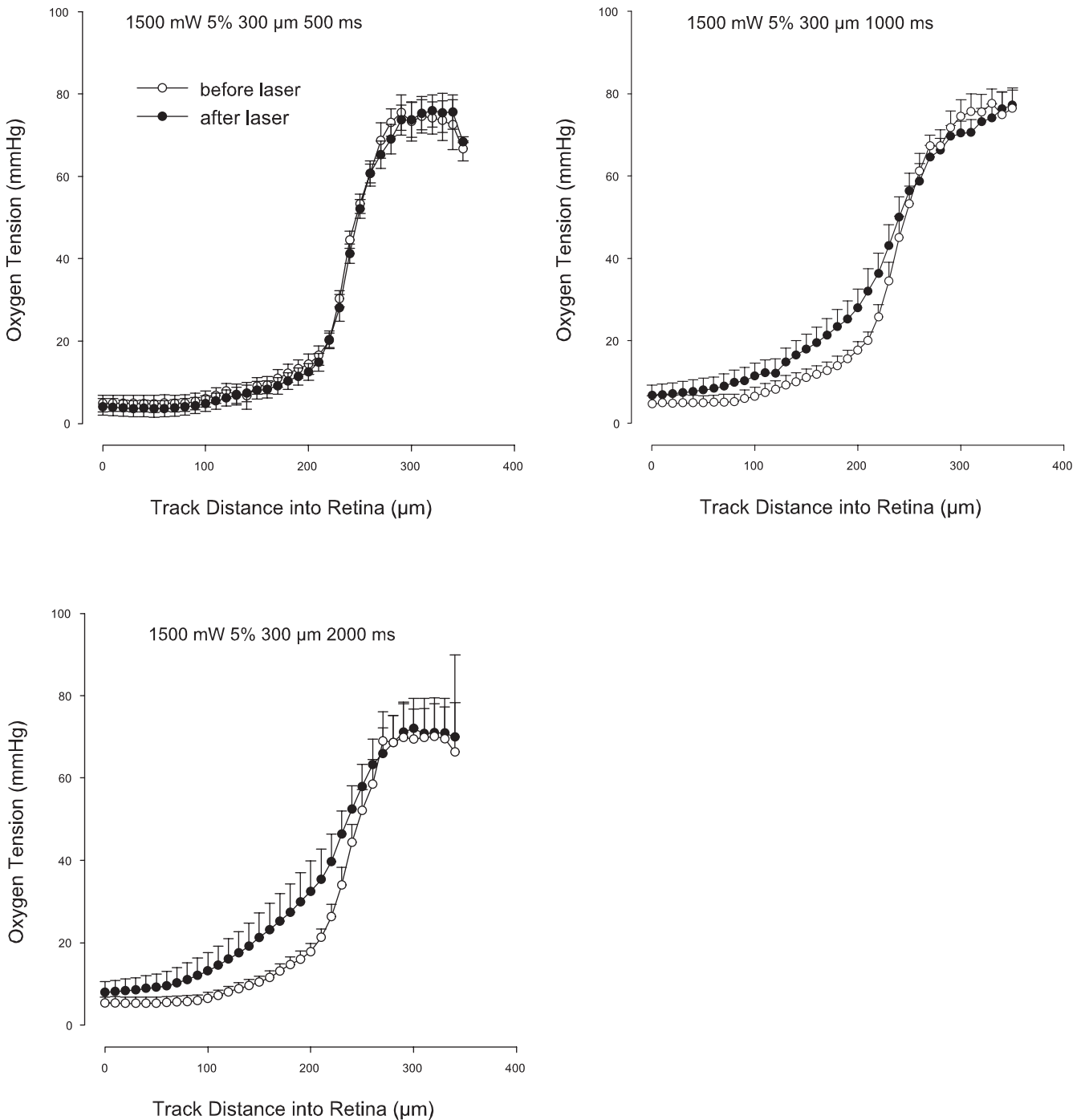


FIGURE 6. Average levels of intraretinal oxygen tension as a function of track length into the retina and choroid before and after 5% duty cycle MP laser treatment at the maximum MP power level for the durations shown.

ing of the retina, particularly in the outer segments of the photoreceptor cells was present. CW irradiation at 200 mW (Fig. 7C) produced swelling of the RPE (arrowheads) and extensive necrosis of photoreceptor outer segments (arrows). The inner retina appeared relatively undamaged. At 250 mW (Fig. 7D), the RPE was severely disrupted (arrowheads). Coagulated necrosis of photoreceptor inner and outer segments (arrows) and extensive pyknotic nuclei in the outer nuclear layer were visible in the central lesion. Significant swelling of the inner nuclear layer with vacuolization was present, and thinning of the inner and outer plexiform layers was also notable.

Figure 8 shows light micrographs of acute retinal lesions produced by a 5% duty cycle of MP laser irradiation with a power level of 1500 mW and increasing pulse durations of (A) 500, (B) 1000, and (C) 2000 ms. With a pulse duration of 500 ms (Fig. 8A), there were no remarkable changes in the irradiation area. With a longer irradiation duration of 1000 ms (Fig. 8B), mildly edematous changes were apparent in the retina and the pigment epithelium. Focal distortion of the RPE and outer segments of the photoreceptors (arrowheads) was apparent. Retinal edema was more evident with irradiation durations of 2000 ms (Fig. 8C). There was localized distortion and necrosis of RPE (arrowheads) in the central laser lesion. The outer retina

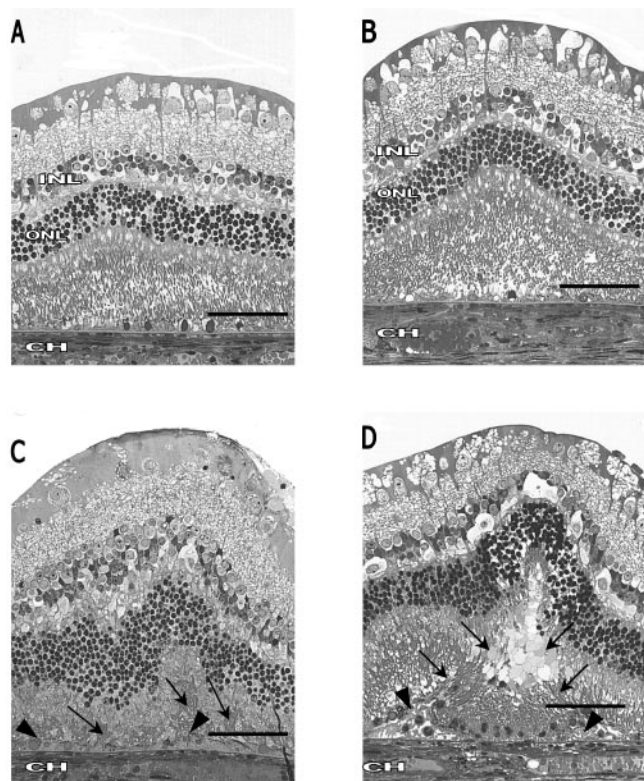


FIGURE 7. Light micrographs of acute retinal lesions produced in pigmented rabbits by CW laser irradiation using power levels of (A) 100 (B) 150, (C) 200, and (D) 250 mW. Graded retinal damage was produced at increasing power levels. At 100 mW (A), the retina and the pigment epithelium were mildly edematous, the pigment epithelium appeared irregularly pigmented, and the outer segments of the photoreceptor cells were deranged. With 150 mW (B), more extensive swelling of the retina, particularly in the outer segments of the photoreceptor cells was present. At 200 mW (C), there was swelling of the RPE (*arrowheads*) and extensive necrosis of photoreceptor outer segments (*arrows*). At 250 mW (D) the RPE was severely disrupted (*arrowheads*). Coagulated necrosis of photoreceptor inner and outer segments (*arrows*) with extensive pyknotic nuclei in the outer nuclear layer was seen in the central lesion. Significant swelling of the inner nuclear layer with vacuolization was present, and thinning of the inner and outer plexiform layers was also noted. Scale bars, 100 μ m.

was more extensively swollen, and there was coagulated necrosis of outer and inner segments of the photoreceptors (*arrows*) and pyknotic nuclei in the outer nuclear layer. With longer duty cycle MP delivery at 10% and 15% duty cycles, the retinal damage became increasingly like that noted with CW delivery.

Effects of CW and MP Laser on Outer Retinal Oxygen Consumption

Figure 9 shows the combined data from all animals showing outer retinal oxygen consumption as a function of total energy applied by each mode of laser delivery. The total energy is calculated from the product of the power level, duty cycle, and pulse duration for each mode of delivery. The reduction in outer retinal oxygen consumption as a function of energy applied was very similar for CW and the 15% and 10% MP laser delivery. Much less suppression of outer retinal oxygen consumption was evident with 5% MP delivery at the equivalent energy level.

Effects of CW and MP Laser on Oxygen Level in the Mid Retina

Figure 10 shows the combined data from all animals for the increase in oxygen tension in the middle retina as a function of total energy applied in each mode of laser delivery. The increase in average oxygen level in the middle retinal layers was clearly dose dependent, with 5% MP delivery producing smaller increases in P_{O_2} for the same dose when compared with longer duty cycles or CW delivery.

DISCUSSION

The successful treatment of the proliferative consequences of diabetic retinopathy by retinal photocoagulation has arisen largely by a sequence of fortuitous discoveries. Initially, the emphasis was on the direct photocoagulation of new vessels in an attempt to induce them to regress. Subsequently, it was noted that those patients who received a larger number of photocoagulation lesions had the best visual outcome.¹³ Although fortuitous discoveries are always welcome in medical research, they can sometimes leave important gaps in our knowledge of the specific mechanisms responsible for the

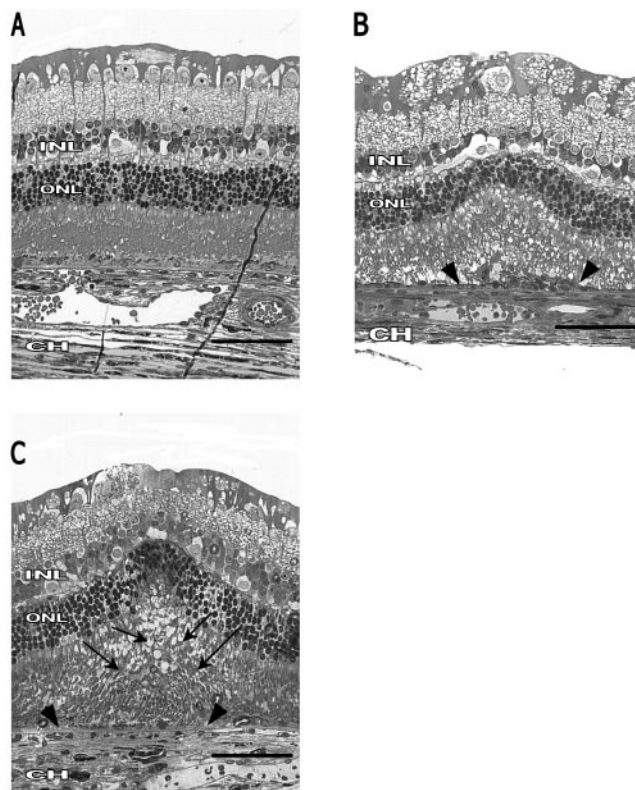


FIGURE 8. Light micrographs of acute retinal lesions produced by the 5% duty cycle of MP laser irradiation with a power level of 1500 mW and increasing pulse durations of (A) 500, (B) 1000, and (C) 2000 ms. With a pulse duration of 500 ms (A), there were no remarkable changes in the irradiation area. With a longer irradiation duration of 1000 ms (B), mildly edematous changes were apparent in the retina and the pigment epithelium. Focal distortion of the RPE and outer segments of the photoreceptors (*arrowheads*) was apparent. Retinal edema was more evident with irradiation durations of 2000 ms (C). Localized distortion and necrosis of RPE (*arrowheads*) was apparent in the central laser lesion in which the outer retina was more extensively swollen and there was coagulated necrosis of outer and inner segments of photoreceptors (*arrows*) and pyknotic nuclei in the outer nuclear layer. Scale bar, 100 μ m.

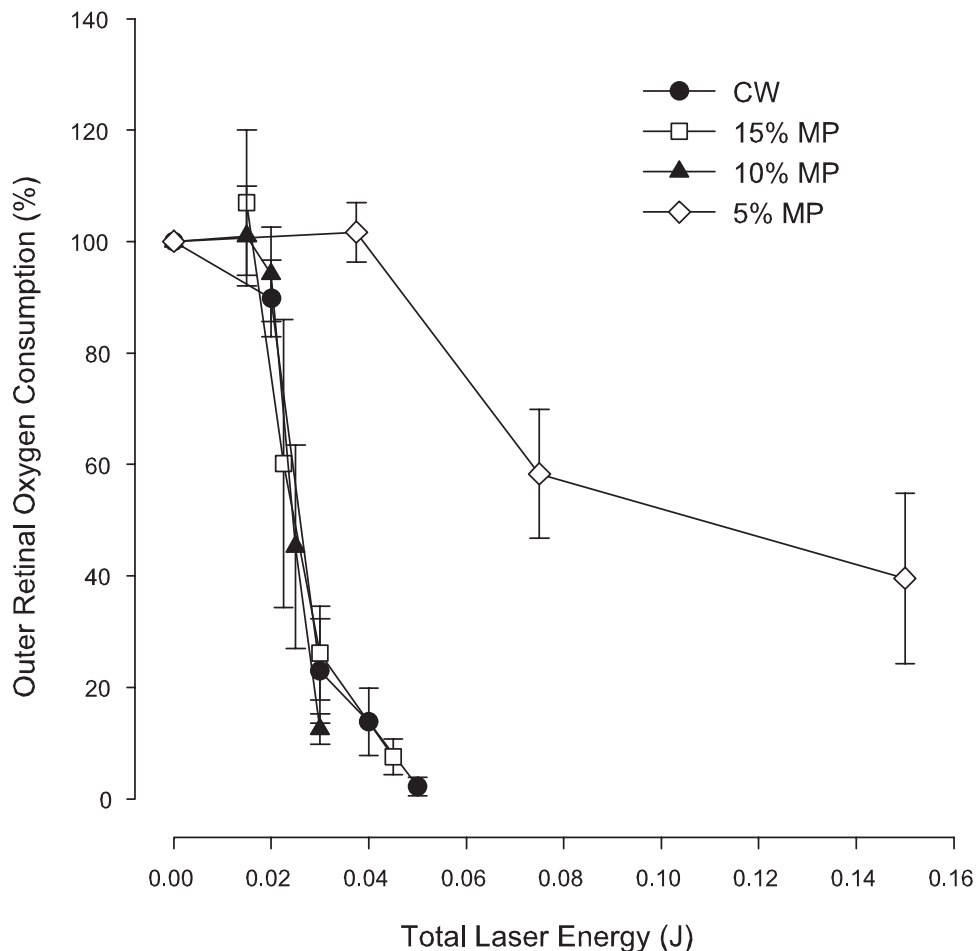


FIGURE 9. Combined data from all animals showing outer retinal oxygen consumption as a function of total energy applied by each mode of laser delivery. The reduction in outer retinal oxygen consumption as a function of energy applied was very similar for CW, 15% MP, and 10% MP delivery; however, much less suppression of outer retinal oxygen consumption was evident with 5% MP delivery for the equivalent energy level.

therapeutic outcome. Despite the great success of PRP therapy, the specific mechanisms by which it causes regression of proliferative lesions remain speculative. A major candidate for the beneficial effect of PRP therapy is the relief of tissue hypoxia due to decreased oxygen consumption of retinal cells in the treated area. However, to our knowledge, there have been no studies to date in which retinal oxygen consumption has been directly quantified or the intraretinal oxygen distribution determined after laser therapy. Indirect evidence of reduced retinal oxygen consumption has been provided by measurements of preretinal oxygen tension increases in the treated area.^{11,31-35} However, at times, no lasting oxygen effect has been found³⁵ or systemic hyperoxia has been necessary to expose an effect.^{33,34} The only clinical study showing an oxygen benefit to the vitreous was also performed with supplemental oxygen ventilation.³⁶ Part of the difficulty of observing an effect in the preretinal vitreous under normal ventilation conditions may be that autoregulation of the retinal vasculature has the potential to mask the influence of changes in outer retinal oxygen consumption. In studies in an ischemic area of the pig retina, Pournaras et al.¹¹ were able to demonstrate significant increases in P_{O_2} in the vitreous in front of a photocoagulated area. Novack et al.³⁷ were the first to exploit the avascular nature of the rabbit retina to avoid such masking effects, and others have also successfully measured increased oxygen levels in the preretinal vitreous in front of photocoagulation lesions in avascular retinas.³⁸ In the present study, we used for the first time intraretinal measurements of oxygen consumption and distribution immediately before and after laser treatment. Because a relatively small (300- μ m) area of retina is treated in each case, we were able to study up to 10

different lesions in each eye. Furthermore, before- and after-treatment comparison at the same retinal location also eliminates any potential effects of regional differences in retinal oxygen metabolism and interanimal variability. In the present study, the average outer retinal oxygen consumption before treatment (243 ± 23 nL O_2/cm^2 per minute) was comparable to that reported in our earlier work in the avascular visual streak of the rabbit retina (284 ± 20 nL O_2/cm^2 per minute). Previously adopted assumptions about true outer retinal thickness¹⁶ allowed conversion to oxygen consumption per unit volume of outer retina, arriving at an estimate of 3.0 mL/min per 100 g for the avascular retina before laser treatment.

To examine the effect on oxygen level across the retina, we divided the retina into three equal zones: the inner, middle, and outer retina. This allowed the relative oxygen changes in these regions to be assessed after laser treatment. It must be noted that due to the nonperpendicular nature of the electrode track through the lesion, some of the inner retina measured may not be within the lesion site. These edge effects would tend to suppress the induced change in inner retinal oxygen tension. This effect is unavoidable, given that we chose to position the lesions so that they were centered on the electrode track in the outermost retina. The nonuniformity of the lesions themselves may also concentrate any oxygen changes to the center of the lesion where the laser effects are typically more severe, thus further contributing to edge effects in the inner retina.

In an earlier study of vitreal P_{O_2} changes after laser photocoagulation in the rabbit, Funatsu et al.,³⁸ demonstrated large P_{O_2} increases in front of confluent lesions 12 days after treatment. However, with more widely spaced lesions, no sustained

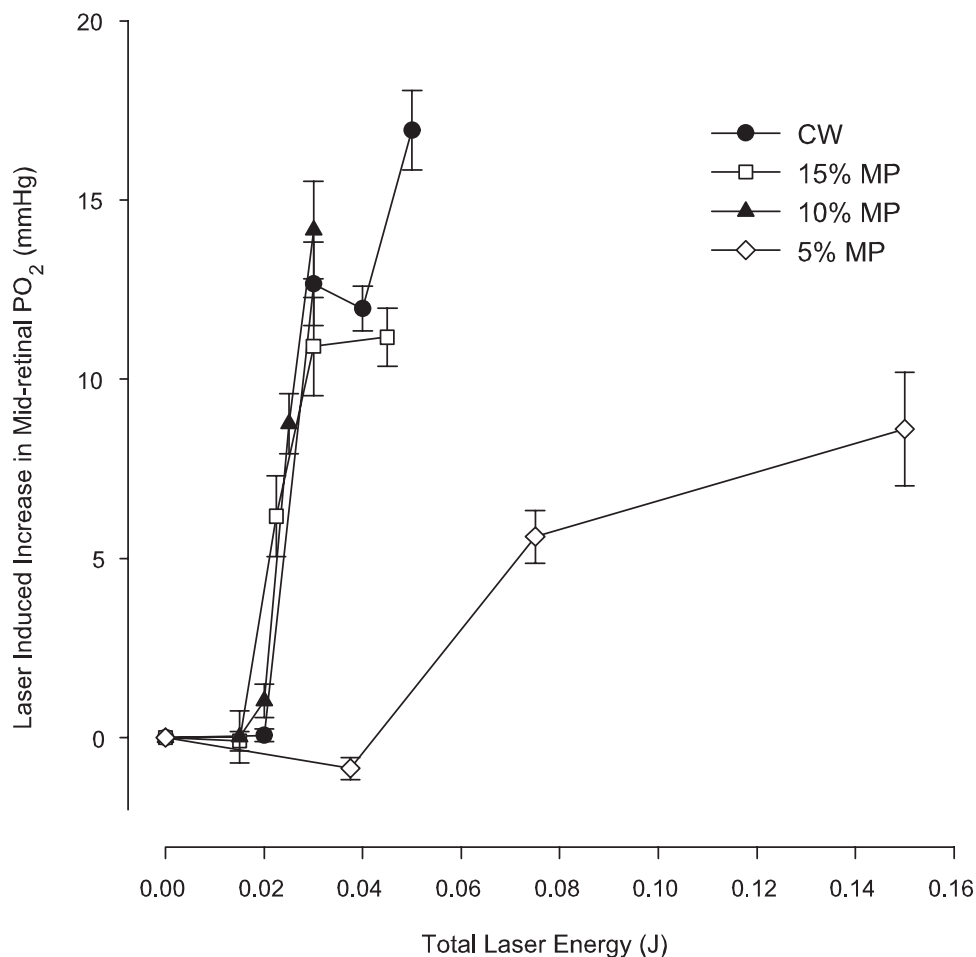


FIGURE 10. Combined data from all animals showing the increase in oxygen level in the middle retina as a function of total energy applied by each mode of laser delivery.

PO_2 increase in the vitreous was observed. Based on the presented fundus photographs, the lesions in the study of Funatsu et al.,³⁸ appear far more severe than those reported in our study. This, together with the chronic nature of their study could easily account for the large changes in vitreal PO_2 reported over 12-day-old confluent lesions. They also reported a higher average baseline PO_2 in the vitreous. However, although not stated, it seems very likely that some oxygen supplementation was used in their study. The quoted arterial PO_2 range included values up to 120 mm Hg, which is not feasible for an air-breathing animal. Furthermore, it is now known that in the rabbit, the preretinal PO_2 is particularly dependent on choroidal PO_2 .²³ Our baseline vitreal PO_2 is in closer agreement with previous microelectrode-based work in the rabbit, where the mean vitreal PO_2 was also below 10 mm Hg.³⁹

Histologic studies of laser lesions are problematic in acute laser lesions in which the effects of the laser injury have not yet stabilized. In addition, it should be noted that although our oxygen measurements were performed only minutes after laser treatment, tissue fixation was performed at the conclusion of the experiment. This was often several hours after laser treatment in many lesions. Funduscopically, the more severe laser lesions become visibly more opaque and increased in size over the first hour or so after treatment. This implies that, at the time of fixation, the degree of edema may have been considerably worse than at the time of the oxygen profile measurement. Others have confirmed that structural changes continue to develop and may be caused by both primary and secondary effects of the laser treatment.⁴⁰

Because all measurements were conducted under light adapted conditions, it seems unlikely that further bleaching of

the photoreceptors after laser treatment contributes to the altered oxygen metabolism of the outer retina. This may be expected, given that the 810-nm wavelength of the laser is on the very edge of the visible wavelength. It is also supported by the experimental results, which indicate no detectable change in oxygen metabolism of the photoreceptors at laser power levels below those necessary to produce thermal damage to the photoreceptors.

Micropulse laser techniques have already been used in the treatment of retinal diseases such as macular edema and proliferative diabetic retinopathy.⁴¹⁻⁴⁴ However, these pilot studies were intended to change the cellular microstructure of the RPE to increase removal of fluid from the retina.⁴¹ This mechanism has yet to be confirmed. Our results demonstrate that reduced outer retinal oxygen consumption after laser therapy results in increased oxygen levels within the treated area of retina. How much oxygenation benefit is needed to ameliorate the vasoproliferative consequences of retinal ischemia is not currently known. There does, however, appear to be room for only partial destruction of the outer retina to be considered a therapeutic outcome. This could allow the treated area of retina to remain functionally viable, thereby lessening the degree of scotoma induced by the treatment. A better understanding of the relationship between the parameters chosen for the laser therapy and the outcome in terms of the induced changes in the intraretinal oxygen environment is the first step in such a process and is particularly important in the chronic case, where retinal metabolism may well be affected in a very different manner than that seen immediately after laser treatment. Our studies have allowed the first quantification of changes in retinal oxygen consumption and intraretinal oxygen

levels after laser photocoagulation therapy. We were able to produce consistent retinal lesions over a range of power levels and modes of delivery. Comparing the effect of total laser energy on the reduction in outer retinal oxygen consumption (Fig. 9) indicates that short (5%) duty cycles of MP delivery produce much milder changes in outer retinal oxygen consumption than equivalent energy levels of higher MP duty cycles and CW delivery, which suggests that there may be some advantages in short-duty-cycle MP laser delivery, in that a flatter dose-response curve may allow more precise production of the required therapeutic benefit under conditions in which precise control of the power level reaching the retina is not possible. This is further confirmed by the data summarizing the induced PO_2 increase in the mid retina (Fig. 10). Better localization of the therapeutic effect and less impact on the choroidal circulation may also be important factors influencing the therapeutic outcome.

In choosing the rabbit model for our study we have sought to create the simplest model in which the oxygen benefits of PRP therapy can be directly assessed. Although the absence of retinal vasculature in the treatment area simplifies the analysis, the inner retina of the rabbit has very different oxygen metabolism requirements compared with vascularized retinas. Inner retinal oxygen metabolism in the rabbit is very low, being only a fraction of that in the outer retina.¹⁶

It is clearly important that, once a set of potentially useful laser parameters is identified, they be tested in a vascularized model, preferably one incorporating a chronic model of retinal ischemia and PRP therapy.

In further work, we will study the chronic effects of laser photocoagulation and determine the parameters that produce an oxygenation benefit to the inner retina, yet preserve useful retinal function in the treated area. Such a technique may offer significant advantages over current treatment regimens for ischemic retinal diseases and diabetic retinopathy.

Acknowledgments

The authors thank Dean Darcey, Judi Granger, and Megan Dallas for their invaluable technical assistance.

References

- Frank RN. Diabetic retinopathy. *Prog Retina Eye Res.* 1995;14:361-392.
- Bailey CC, Sparrow JM, Grey RH, Cheng H. The national diabetic retinopathy laser treatment audit. III. Clinical outcomes. *Eye.* 1999;13:151-159.
- Early Treatment Diabetic Retinopathy Study Research Group. Early photocoagulation for diabetic retinopathy. ETDRS report number 9. *Ophthalmology.* 1991;98:766-785.
- Lovestam-Adrian M, Agardh E. Photocoagulation of diabetic macular oedema: complications and visual outcome. *Acta Ophthalmol Scand.* 2000;78:667-671.
- McCarty CA, McKay R, Keefe JE. Management of diabetic retinopathy by Australian ophthalmologists. Working Group on Evaluation of the NHMRC Retinopathy Guideline Distribution. National Health and Medical Research Council. *Clin Exp Ophthalmol.* 2000;28:107-112.
- Fong DS, Ferris FL III, Davis MD, Chew EY. Causes of severe visual loss in the early treatment diabetic retinopathy study: ETDRS report no. 24. Early Treatment Diabetic Retinopathy Study Research Group. *Am J Ophthalmol.* 1999;127:137-141.
- Dogru M, Nakamura M, Inoue M, Yamamoto M. Long-term visual outcome in proliferative diabetic retinopathy patients after pan-retinal photocoagulation. *Jpn J Ophthalmol.* 1999;43:217-224.
- Pearson AR, Tanner V, Keightley SJ, Casswell AG. What effect does laser photocoagulation have on driving visual fields in diabetics? *Eye.* 1998;12:64-68.
- Ulbig MR, Arden GB, Hamilton AM. Color contrast sensitivity and pattern electroretinographic findings after diode and argon laser photocoagulation in diabetic retinopathy. *Am J Ophthalmol.* 1994;117:583-588.
- The Diabetic Retinopathy Study Research Group. Indications for photocoagulation treatment of diabetic retinopathy: Diabetic Retinopathy Study Report no. 14. *Int Ophthalmol Clin.* 1987;27:239-253.
- Pournaras CJ, Tsacopoulos M, Strommer K, Gilodi N, Leuenberger PM. Scatter photocoagulation restores tissue hypoxia in experimental vasoproliferative microangiopathy in miniature pigs. *Ophthalmology.* 1990;97:1329-1333.
- Arnarsson A, Stefansson E. Laser treatment and the mechanism of edema reduction in branch retinal vein occlusion. *Invest Ophthalmol Vis Sci.* 2000;41:877-879.
- Wolbarsht ML, Landers MB III. The rationale of photocoagulation therapy for proliferative diabetic retinopathy: a review and a model. *Ophthalmic Surg.* 1980;11:235-245.
- Weiter JJ, Zuckerman R. The influence of the photoreceptor-RPE complex on the inner retina: an explanation for the beneficial effects of photocoagulation. *Ophthalmology.* 1980;87:1133-1139.
- Hyvarinen L. Vascular structures of the rabbit retina. *Acta Ophthalmol.* 1967;45:852-861.
- Yu D-Y, Cringle SJ. Low oxygen consumption in the inner retina of the visual streak of the rabbit. *Am J Physiol.* 2004;286:H419-H423.
- Roider J, Brinkmann R, Wirbelauer C, Laqua H, Birngruber R. Retinal sparing by selective retinal pigment epithelial photocoagulation. *Arch Ophthalmol.* 1999;117:1028-1034.
- Pollack JS, Kim JE, Pulido JS, Burke JM. Tissue effects of subclinical diode laser treatment of the retina. *Arch Ophthalmol.* 1998;116:1633-1639.
- Mainster MA. Decreasing retinal photocoagulation damage: principles and techniques. *Semin Ophthalmol.* 1999;14:200-209.
- Friberg TR, Karatza EC. The treatment of macular disease using a micropulsed and continuous wave 810-nm diode laser. *Ophthalmology.* 1997;104:2030-2038.
- Toth CA, Narayan DG, Cain CP et al. Pathology of macular lesions from subnanosecond pulses of visible laser energy. *Invest Ophthalmol Vis Sci.* 1997;38:2204-2213.
- Yu D-Y, Cringle SJ. Oxygen distribution and consumption within the retina in vascularised and avascular retinas and in animal models of retinal disease. *Prog Retina Eye Res.* 2001;20:175-208.
- Cringle SJ, Yu D-Y. Intraretinal oxygenation and oxygen consumption in the rabbit during systemic hyperoxia. *Invest Ophthalmol Vis Sci.* 2004;45:3223-3228.
- Yu D-Y, Cringle SJ, Alder VA, Su EN. Intraretinal oxygen distribution in rats as a function of systemic blood pressure. *Am J Physiol.* 1994;36:H2498-H2507.
- Cringle SJ, Yu D-Y, Yu PK, Su E-N. Intraretinal oxygen consumption in the rat in vivo (published correction appears in *Invest Ophthalmol Vis Sci.* 2003;44:9). *Invest Ophthalmol Vis Sci.* 2002;43:1922-1927.
- Yu D-Y, Cringle SJ, Alder VA, Su EN, Yu PK. Intraretinal oxygen distribution and choroidal regulation in the avascular retina of guinea pigs. *Am J Physiol.* 1996;270:H965-H973.
- Whalen WJ, Riley J, Nair P. A microelectrode for measuring intracellular PO_2 . *J Appl Physiol.* 1967;23:798-801.
- Yu D-Y, Cringle SJ, Constable IJ. Robotic ocular ultramicrosurgery. *Aust NZ J Ophthalmol.* 1998;26:S6-S9.
- Haugh LM, Linsenmeier RA, Goldstick TK. Mathematical models of the spatial distribution of retinal oxygen tension and consumption including changes upon illumination. *Ann Biomed Eng.* 1990;18:19-36.
- Cringle SJ, Yu D-Y. A multi-layer model of retinal oxygen supply and consumption helps explain the muted rise in inner retinal PO_2 during systemic hyperoxia. *Comp Biochem Physiol.* 2002;132:61-66.
- Molnar I, Poitry S, Tsacopoulos M, Gilodi N, Leuenberger PM. Effect of laser photocoagulation oxygenation of the retina in miniature pigs. *Invest Ophthalmol Vis Sci.* 1985;26:1410-1414.

32. Landers MB, Stefansson E, Wolbarsht ML. Panretinal photocoagulation and retinal oxygenation. *Retina*. 1982;2:167-175.
33. Stefansson E, Landers MB, Wolbarsht ML. Increased retinal oxygen supply following pan-retinal photocoagulation and vitrectomy and lensectomy. *Trans Am Ophthalmol Soc*. 1981;79:307-334.
34. Alder VA, Cringle SJ, Brown M. The effect of regional retinal photocoagulation on vitreal oxygen tension. *Invest Ophthalmol Vis Sci*. 1987;28:1078-1085.
35. Diddie KR, Ernest JT. The effect of photocoagulation on the choroidal vasculature and retinal oxygen tension. *Am J Ophthalmol*. 1977;84:62-66.
36. Stefansson E, Macherem R, de Juan E, McCuen BW, Peterson J. Retinal oxygenation and laser treatment in patients with diabetic retinopathy. *Am J Ophthalmol*. 1992;113:36-38.
37. Novack RL, Stefansson E, Hatchell D. The effect of photocoagulation on the oxygenation and ultrastructure of avascular retina. *Exp Eye Res*. 1990;50:289-296.
38. Funatsu H, Wilson CA, Berkowitz BA, Sonkin PL. A comparative study of the effects of argon and diode laser photocoagulation on retinal oxygenation. *Graefes Arch Clin Exp Ophthalmol*. 1997;235:168-175.
39. Tillis TN, Murray DL, Schmidt GJ, Weiter JJ. Preretinal oxygen changes in the rabbit under conditions of light and dark. *Invest Ophthalmol Vis Sci*. 1988;29:988-991.
40. Leibur R, Davila E, Zemel E et al. Development of laser-induced retinal damage in the rabbit. *Graefes Arch Clin Exp Ophthalmol*. 1999;237:991-1000.
41. Moorman CM, Hamilton AMP. Clinical applications of the micropulse diode laser. *Eye*. 1999;13:145-150.
42. Roider J. Laser treatment of retinal diseases by subthreshold laser effects. *Semin Ophthalmol*. 1999;14:19-26.
43. Roider J, Brinkmann R, Wirbelauer C, Laqua H, Birngruber R. Subthreshold (RPE) photocoagulation in macular diseases: a pilot study. *Br J Ophthalmol*. 2000;84:40-47.
44. Stanga PE, Reck AC, Hamilton AM. Micropulse laser in the treatment of diabetic macular edema. *Semin Ophthalmol*. 1999;14:210-213.