

Prenatal Sonographic Diagnosis and Evaluation of Isolated Macroductyly

Hande Yağmur¹, Atıl Yüksel² and Hülya Kayserili³

¹Fulya Acıbadem Hastanesi, İstanbul

²İstanbul Faculty of Medicine, Department of Obstetrics and Gynecology,
Division of Perinatology, İstanbul Üniversitesi

³İstanbul Faculty of Medicine, Department of Medical Genetics, İstanbul Üniversitesi
Turkey

1. Introduction

Macroductyly, defined as enlargement of one or several digits of the hands or feet, is a rare malformation. It may be due tumorous enlargement of a single tissue element, as in hemangioma, lymphangioma or enchondroma or it may be caused by overgrowth of all structures of the digit, including phalanges, subcutaneous tissue, nerves, vessels and skin as in 'true macroductyly' (Barsky, 1967). Furthermore, it may either be isolated or associated with other anomalies such as hemihypertrophy, vascular malformations, lipomas, cutaneous lesions or visceral anomalies as a feature of a syndrome.

There is only one case report of prenatally diagnosed isolated macroductyly till then by Yüksel et al. Macroductyly of the second toe of the left foot was noted on a routine fetal anomaly scan at 24 weeks (Figure 1). The other toes were of normal size and there were no other associated anomalies on serial scans. The fetal karyotype was also normal. The baby was born at term and evaluations carried out at birth, 6 months and 2 years of age revealed no other additional abnormalities; neither hemihypertrophy, macrocephaly, lipomas nor vascular abnormalities were detected. Diagnosis of congenital isolated true macroductyly was confirmed. Distal phalangectomy was performed at 6 months of age and due to progressive enlargement after the first operation, the digit had to be amputated at 9 months of age. Histopathological evaluation of the specimen was consistent with true macroductyly, with enlargement of all mesenchymal tissues, mainly of fibroadipose tissue origin (Yüksel et al., 2009).

Macroductyly is an isolated finding without evidence of other systemic involvement in the majority of cases. However, there is a well-established association of macroductyly with overgrowth syndromes such as Proteus syndrome, Bannayan-Riley-Ruvalcaba syndrome, CLOVES (Congenital Lipomatous Overgrowth, Vascular malformations, Epidermal nevi, and Skeletal/Spinal abnormalities) syndrome, Maffucci syndrome, Ollier's disease, Klippel-Trenaunay-Weber syndrome, neurofibromatosis, tuberous sclerosis and Milroy disease (Alomari, 2009; Norman-Taylor & Mayou, 1994; Yüksel et al., 2009). Therefore, prenatal diagnosis of macroductyly necessitates thorough evaluation of all systems to differentiate between isolated and syndromic macroductyly, which have different prognostic implications.

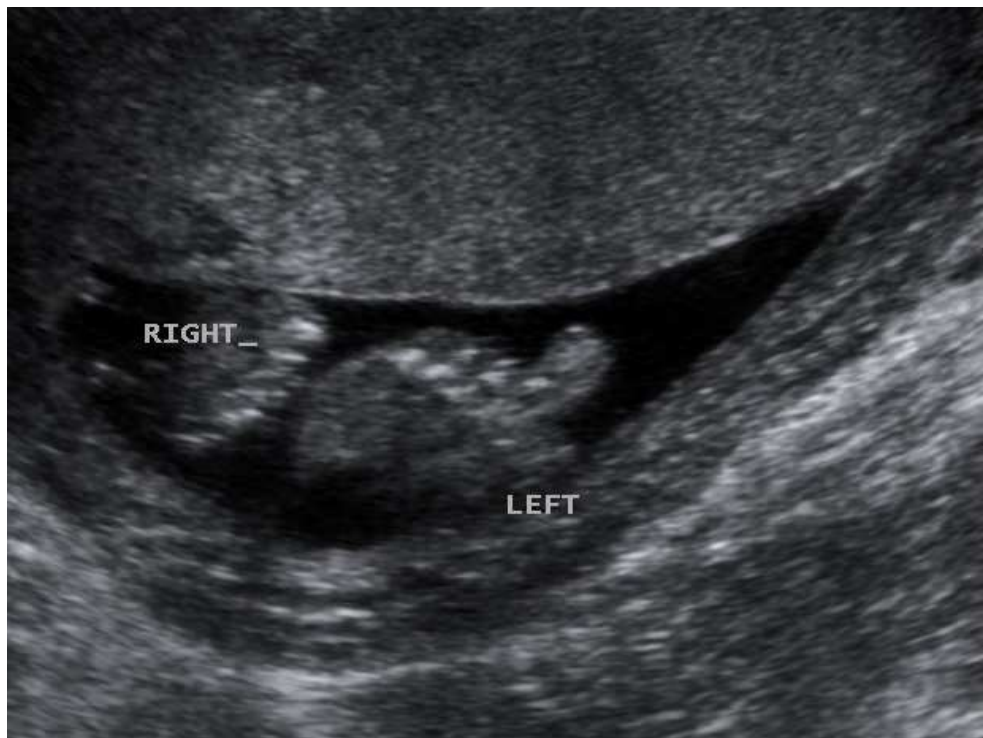

Fig. 1. Ultrasonographic scan of the fetus at 24 gestational weeks demonstrating the difference in size between two second toes. Macroductyly of the left second toe is confirmed by comparable measurements. This is another image of the same case presented in 'Prenatal diagnosis of isolated macroductyly' in *Ultrasound in Obstetrics and Gynecology* 2009; 33: 360-362.

2. Macroductyly

2.1 True macroductyly

Congenital true macroductyly is a rare, nonhereditary malformation and appears to be more common in the hands than in the feet (Barsky, 1967). Overall, it constitutes around 1% of all congenital anomalies of the upper limb (Flatt, 1977, as cited in Kotwal & Farooque, 1998).

The disease is almost always unilateral and a single digit or several, usually adjacent digits may be involved (D'Costa et al., 1996, as cited in Singla et al., 2008; Syed et al., 2005). The second or third digit of the hand or foot are frequently involved in the majority of cases, corresponding to the median nerve and medial plantar nerve distribution (Krengel et al., 2000; Sone et al., 2000). The enlargement is most pronounced at the distal end of the digits on the volar side and therefore causes dorsal angulation (Singla et al., 2008). It may also be associated with syndactyly, polydactyly, or clinodactyly (Goldman & Kaye, 1977).

Two subtypes of true macroductyly, namely, static and progressive types, have been described (Barsky, 1967). In the static type, the growth rate of the involved digit is the same

as the normal digits whereas in the progressive type, growth is accelerated compared to the rest. The progressive type is less common and involvement of the metacarpal and metatarsal bones is more likely in the progressive type (Turkington & Grey, 2005). Abnormal accelerated growth usually ceases at puberty (Singla et al., 2008; Turkington & Grey, 2005).

Marked increase in adipose tissue within a mesh of fibrous tissue that involves the bone marrow, periosteum, muscles, nerve sheaths and subcutaneous tissues is the characteristic pathological finding in true macroductyly (Kelikian, 1974 and Thorne et al., 1968 as cited in Goldman & Kaye, 1977). The most striking difference between macroductyly of the hand and foot is neural involvement. Hypertrophy and tortuosity of the digital nerve is a notable finding in macroductyly of the hand whereas it is rarely seen in the foot (Syed et al., 2005; Dennyson et al., 1977 as cited in Syed et al., 2005). The etiology is unclear and proposed mechanisms include lipomatous degeneration, neurofibromatosis, disturbed fetal circulation and local deficiency of growth inhibiting or overexpression of growth promoting factors (Syed et al., 2005; Gupta et al., 1992, as cited in Singla et al. 2008).

Macroductyly causes cosmetic disfigurement and may also impair function due to secondary degenerative joint disease and nerve entrapment (Turkington & Grey, 2005). Treatment is usually not entirely satisfactory and may require several bulk reducing operations, carpal tunnel release, phalangectomy, and amputation (Kotwal & Farooque, 1998).

2.2 Macroductyly due to tumorous enlargement

In contrast to true macroductyly whereby all the structures of the digit are overgrown as a whole, there is tumorous enlargement of a single tissue element. Most of the tumors (95%) are benign and they may be classified according to the tissue of origin. Abnormal growth of vascular (hemangiomas, glomus tumors), osseous (enchondromas –multiple enchondromas as in Ollier disease-, osteoid osteomas, osteoblastomas, giant cell tumors, aneurysmal and unicameral bone cysts), neural (schwannomas, fibrolipomatous hamartomas, neurofibromas), cutaneous (mucous cysts, nodular fasciitis, pyogenic granulomas) and soft tissue (ganglions, lipomas, nodular tenosynovitis) elements cause localized masses of the hand and digits (Lin SJ et al., 2011).

Fibrolipomatous hamartoma is a rare, intraneural tumor characterized by fibrofatty infiltration around the nerve fascicles (Razzaghi & Anastakis, 2005). It is associated with macroductyly due to overgrowth of bone and subcutaneous fat in more than one-third of the patients and it presents early in childhood with macroductyly or later with a volar forearm mass and compressive neuropathy (Silverman & Enzinger, 1985, as cited in Razzaghi & Anastakis, 2005; Razzaghi & Anastakis, 2005).

Malignant tumors are rare. Primary malignant tumors may be of skin (most common site for malignant tumors), bone or soft tissue origin whereas metastatic tumors are mainly due to lung, kidney or head and neck cancers (Marrero IC et al., 2011).

3. Syndromes associated with macroductyly

3.1 Proteus syndrome

Proteus syndrome (MIM 176920) is a sporadic disorder that may be caused by a somatic alteration in a gene, that probably controls local production or regulation of tissue growth

factor receptors (Cohen MM Jr., 1993 and Samlaska et al., 1989, as cited in Jamis-Dow et al., 2004). The infants affected by the disorder usually appear normal or show only mildly asymmetric development at birth, but progressively develop the characteristic features of the syndrome during childhood. As the manifestations are highly variable, standard diagnostic criteria have been developed to minimise misdiagnosis (Biesecker et al., 1999, as cited in Jamis-Dow et al., 2004). Skeletal abnormalities such as macrodactyly, scoliosis, asymmetric overgrowth and limb length discrepancy, soft tissue abnormalities such as lipomas or regional absence of fat, asymmetric muscle development, connective tissue nevi and vascular malformations are common manifestations of the disease whereas visceral anomalies such as splenomegaly, asymmetric megalencephaly, white matter abnormalities, nephromegaly, and masses other than fatty, muscular or vascular masses are uncommon (Jamis-Dow et al., 2004). Macrodactyly was encountered in 16 of 21 (76%) patients with Proteus syndrome in whom the diagnosis was based on standardized criteria (Jamis-Dow et al., 2004). Isolated macrodactyly has also been proposed as an extremely localized form of Proteus syndrome (van Bever & Hennekam, 1994).

Sigaudy et al. reported a prenatally diagnosed case of Proteus syndrome presenting with a large cystic mass on the right side of the abdomen and thorax and possible syndactyly of the fourth and fifth fingers at 26 weeks. The pregnancy was terminated at 28 weeks due to massive enlargement of the mass and autopsy revealed cystic lymphangioma on the right side, enlargement of the left arm, lateral deviation of the third to fifth fingers of the left hand with a large fixed gap between the second and the third finger, bilateral enlargement of the third toes, a small thymic cyst and left hemimegalencephaly confirming the diagnosis of Proteus syndrome (Sigaudy et al., 1998). Brasseur et al. reported a very similar case with antenatally diagnosed large, cervico-thoraco-brachial cystic lymphangioma at 22 weeks. After birth, macrodactyly of the first and second toes were noted and Proteus syndrome was diagnosed (Brasseur et al., 2009). Another prenatally diagnosed case with Proteus syndrome had a cystic enlargement of one limb and abnormal positioning of the toes (Richards et al., 1991, as cited in Sigaudy et al., 1998). These case reports show that severe cases of Proteus syndrome with early manifestations can be detected in utero. Most of the cases show at least one manifestation at birth and this finding can be either strongly suggestive of Proteus syndrome or more subtle (Sigaudy et al., 1998). Furthermore, as the phenotype develops over time, cases with apparently isolated findings such as macrodactyly may ultimately be diagnosed with Proteus syndrome (Lacombe & Battin, 1996, as cited in Sigaudy et al., 1998).

3.2 Bannayan-Riley-Ruvalcaba syndrome

Bannayan-Riley-Ruvalcaba (MIM 153480) syndrome is an autosomal dominant disorder, associated with mutations of the PTEN gene. Macrocephaly, lipomas, vascular malformations, intestinal polyps, and pigmented macules of the penis are the characteristic features of this syndrome. Macrodactyly of the right index finger along with a hamartoma of the small bowel mesentery with angiomatous, lipomatous and lymphangiomatous components has been reported by Zonana et al (Zonana et al., 1976).

There have been no reports regarding the prenatal diagnosis of Bannayan-Riley-Ruvalcaba syndrome; however, as it is characterized by hamartomatous changes leading to localized overgrowth, it may be included in the differential diagnosis of overgrowth syndromes like Proteus syndrome and macrodactyly (Jamis-Dow et al., 2004).

3.3 CLOVES syndrome

CLOVES syndrome (MIM 612918) is a disorder with complex truncal lipomatous mass, vascular malformations, epidermal nevi, acral deformities including large, wide feet and hands, macroductyly and wide sandal gap and scoliosis and other musculoskeletal, neurologic, renal and cutaneous malformations (Alomari, 2009). Sapp et al. described 7 patients with progressive, primarily truncal vascular malformations, dysregulated adipose tissue, scoliosis and enlarged, but not severely distorted, bony structures without progressive overgrowth and designated the condition as a distinct entity, namely, CLOVE (Congenital Lipomatous Overgrowth, Vascular malformations, Epidermal nevi) syndrome (Sapp et al., 2007). They stated that bony distortion in these patients was limited to areas of the body that had undergone major surgery in contrast to patients with Proteus syndrome. Later in 2009, the acronym CLOVES syndrome was proposed to emphasize the association of Skeletal/Scoliosis and Spinal abnormalities with this syndrome (Alomari, 2009). Spinal-paraspinal fast-flow lesions within or adjacent to the truncal overgrowth or a cutaneous birthmark in 6 patients with CLOVES syndrome were also reported (Alomari et al., 2011).

There is one case report regarding antenatal findings of a multicystic abdominal wall mass, asymmetry of the cerebral hemispheres and face in a fetus, where postnatal clinical and imaging findings led to the diagnosis of CLOVES syndrome (Fernandez-Pineda et al., 2010).

3.4 Klippel-Trenaunay-Weber syndrome

Klippel-Trenaunay-Weber (KTW) (MIM 149000) syndrome is a rare disorder associated with large cutaneous capillary and venous malformations with hypertrophy of the related bones and soft tissues. The cutaneous lesions include one or several port-wine stains over the affected limb and large venous ectatic vessels and vesicular lymphatic lesions. The lower extremity is more commonly involved. The enlargement of the limb is due to muscle hypertrophy, thickened skin, excessive subcutaneous fat, abnormal vascular tissue and occasionally lymphedema (Requena & Sanguenza, 1997, as cited in Gonçalves et al., 2000). Hypoplasia or aplasia of the venous system is also a feature of the syndrome although it is less commonly encountered (Jacob et al., 1998, as cited in Coombs et al., 2009).

The mosaic pattern and occasional familial cases of KTW syndrome have been explained by paradominant inheritance, whereby heterozygous individuals for the single gene defect are phenotypically normal and the trait is expressed when a somatic mutation occurs in the normal allele at an early stage of embryogenesis (Happle, 1993, as cited in Gonçalves et al., 2000).

Peng et al. have reviewed the prenatal findings of 21 cases with Klippel-Trenaunay-Weber syndrome involving the thigh until 2006. Asymmetric limb hypertrophy was the prominent prenatal finding and extensive involvement of other parts of the body such as the pelvis, abdomen, retroperitoneum or thorax was noted in around 70% of cases (Peng et al., 2006). Signs of high cardiac output probably due to the rapid development of numerous arteriovenous fistulas, such as cardiomegaly, polyhydramnios, non-immune hydrops fetalis and thick placenta have also been reported (Paladini et al., 1998; Peng et al., 2006).

There are two case reports demonstrating the association of Klippel-Trenaunay syndrome with macrodactyly. The first one presented antenatally with multiple distorted cystic areas involving the right leg and abdomen and cardiomegaly with early fetal heart failure who was found to have bilateral macrodactyly of the second toe as well after birth (Zoppi et al., 2001). The second one is a fetus with marked lower limb edema, cystic areas in the abdomen/pelvis/lower limbs and abnormal development of the feet demonstrating bilateral hypoplasia of the femoral and popliteal veins in whom postnatal clinical evaluation also revealed right foot hemihypertrophy/syndactyly and left hallux hypertrophy (Coombes et al., 2009).

3.5 Neurofibromatosis type 1

Neurofibromatosis type 1 (NF1) (MIM 162200) is a relatively common, autosomal dominant multisystem disorder that affects around one in 3500 individuals. Nearly half of the cases occur as a result of a new mutation (Freidman, 1998, as cited in McEwing et al., 2006) and expressivity is highly variable even among family members who carry the same mutation (Korf & Rubenstein, 2005, and Riccardi & Lewis, 1998, as cited in Boyd et al., 2009). It is characterized by cafe-au-lait macules, neurofibromas (plexiform neurofibroma being pathognomonic), axillary or inguinal freckling, optic glioma, iris hamartomas (Lisch nodules), and osseous lesions such as sphenoid dysplasia or thinning of long bone cortex. Macrodactyly in patients with neurofibromatosis is due to plexiform neurofibroma; it may be bilateral and involvement of the distal phalanx may not be as prominent as in true macrodactyly (Goldman & Kaye, 1977).

The prenatal diagnosis is very unlikely as the neonatal clinical features are usually solitary and cutaneous such as cafe-au-lait macules (McEwing et al., 2006) and specific clinical findings increase in frequency with age (Freidman, 1998, as cited in McEwing et al., 2006). Nevertheless, there are a few cases with early and severe prenatal manifestations proven to be associated with neurofibromatosis postnatally. McEwing et al. reported a case presenting with a large oropharyngeal tumor, macrocephaly, ventriculomegaly, cardiomegaly, pleural and pericardial effusion, ascites and polyhydramnios. There was a positive paternal history of NF1 and after termination of pregnancy at 32 weeks, postmortem histologic evaluation was consistent with plexiform neurofibroma, confirming the diagnosis (McEwing et al., 2006). Another similar fetus with an oral tumor was also found to have NF1 postnatally (Hoyme et al., 1987, as cited in McEwing et al., 2006). Lastly, Drouin et al. reported a fetus with ambiguous genitalia, macrocephaly, shortened long bones and polyhydramnios in whom postnatal evaluation demonstrated a large abdominopelvic tumor and skeletal abnormalities consistent with NF1 (Drouin et al., 1997, as cited in McEwing et al., 2006).

3.6 Tuberous sclerosis

Tuberous sclerosis (MIM 191100/191092) is an autosomal dominant, hamartomatous disorder with variable expressivity. It affects about 1/6000 to 1/10000 live births and two thirds of the cases are considered to result from *de novo* mutations. It is associated with skin abnormalities such as hypomelanotic macules, facial angiofibromas, shagreen patches,

fibrous facial plaques, and unguis fibromas, brain abnormalities like cortical tubers, subependymal nodules, astrocytomas causing seizures, intellectual disability, and mental retardation, renal anomalies such as angiomyolipomas and cysts, and cardiac rhabdomyomas (Northrup & Au, 1999). Bone changes also occur and macroductyly has been reported in 11 patients with tuberous sclerosis complex (Aldrich et al., 2010; Ghalli, 2001; Norman-Taylor & Mayou, 1994; Sahoo et al., 2000; Sharma et al., 2011; Shin & Garay, 1997; Tung & Shih, 2009; Kousseff, 1989, and Ortonne et al., 1982 and Wallis & Beighton, 1989, and Zaremba, 1968, as cited in Norman-Taylor & Mayou, 1994). Mesodermal dysplasia as a component of tuberous sclerosis complex is postulated to be responsible for the macroductyly (Sahoo et al., 2000) and overgrowth of the tissues and bones of the forearm and wrist has also been reported (Webb et al., 1996, as cited in Sahoo et al., 2000).

The cases of tuberous sclerosis complex with macroductyly were mainly in the infancy and childhood age group and in most of them the diagnosis of tuberous sclerosis was clinically obvious (Norman-Taylor & Mayou, 1994). The case reported by Sharma et al. developed macroductyly of the index and middle finger of the right hand at 9 nine months of age along with a fibrous hamartoma at his right wrist whereas in Ghalli's case macroductyly of the second left toe was present at birth.

Cardiac rhabdomyomas, arrhythmias, cerebral lesions such as cortical tubers and subependymal nodules, hydrops, and stillbirth are the most prevalent findings in the fetus (Isaacs, 2009). Although there are no reports of prenatal diagnosis of macroductyly associated with tuberous sclerosis, regarding the highly variable phenotypic expression of the disease, it may be considered in the differential diagnosis.

3.7 Ollier disease and Maffucci syndrome

Ollier disease and Maffucci syndrome (MIM 166000) are rare, sporadic disorders characterized by multiple enchondromas of primarily small bones of the hands and feet, the long tubular bones, and also the flat bones like the pelvis. Maffucci syndrome is also associated with hemangiomas of the skin, mucosa and internal organs (Casal et al., 2010).

These two entities usually become manifest during childhood and adolescence and prenatal diagnosis has not been reported.

3.8 Milroy disease

Milroy disease (MIM 153100) is a rare, autosomal dominant disorder characterized by lymphedema of the lower extremities, either of the whole leg or limited to the feet or toes (Lev-Sagie et al., 2003). Although the associated localized overgrowth may mimic the clinical picture of macroductyly, it is differentiated easily from true macroductyly since the bony structures are of normal size in Milroy disease.

Prenatal diagnosis of Milroy disease has previously been reported; with edema of the dorsum of both feet in two cases, bilateral leg edema and hydrothorax in one case and bilateral edema of the lower extremities most marked in the calves and feet in another case (Lev-Sagie et al., 2003; Makhoul et al., 2002; Franceschini et al., 2001). Lymphedema has been

Syndrome	Mode of Inheritance	Common manifestations
Proteus syndrome	Sporadic	Macroductyly, asymmetric overgrowth and limb length discrepancy, vertebral abnormalities, soft tissue abnormalities, connective tissue nevi, vascular malformations, visceral anomalies such as splenomegaly, asymmetric megalencephaly, white matter abnormalities and nephromegaly
Bannayan-Riley-Ruvalcaba syndrome	Autosomal dominant/ <i>de novo</i> mutation	Macrocephaly, lipomas, vascular malformations, intestinal polyps, pigmented macules of the penis
CLOVES syndrome	Sporadic	Complex truncal lipomatous mass, vascular malformations, epidermal nevi, acral deformities including large, wide feet and hands, macroductyly, and wide sandal gap, scoliosis and other musculoskeletal, neurologic, renal and cutaneous malformations
Klippel-Trenaunay-Weber syndrome	Paradominant inheritance	Cutaneous capillary and venous malformations with hypertrophy of the related bones and soft tissues, hypoplasia or aplasia of the venous system
Neurofibromatosis type 1	Autosomal dominant/ <i>de novo</i> mutation	Cafe-au-lait macules, neurofibromas, axillary or inguinal freckling, optic glioma, iris hamartomas (Lisch nodules), osseous lesions such as sphenoid dysplasia or thinning of long bone cortex
Tuberous sclerosis	Autosomal dominant/ <i>de novo</i> mutation	Hypomelanotic macules, facial angiofibromas, shagreen patches, fibrous facial plaques, ungual fibromas, brain abnormalities like cortical tubers, subependymal nodules, and astrocytomas, renal anomalies such as angiomyolipomas and cysts, cardiac rhabdomyomas
Ollier disease	Sporadic	Enchondromas, cerebral tumors
Maffucci syndrome	Sporadic	Enchondromas, vascular malformations
Milroy disease	Autosomal dominant/ <i>de novo</i> mutation	Lymphedema of the lower extremities

Table 1. Characteristics of syndromes associated with macroductyly.

associated with several other syndromes in early childhood such as lymphedema-distichiasis, Cholestasis-Lymphedema Syndrome (Agenaes Syndromes) and Hennekam syndrome.

The main features of above named syndromes associated with macroductyly are summarized in Table 1.

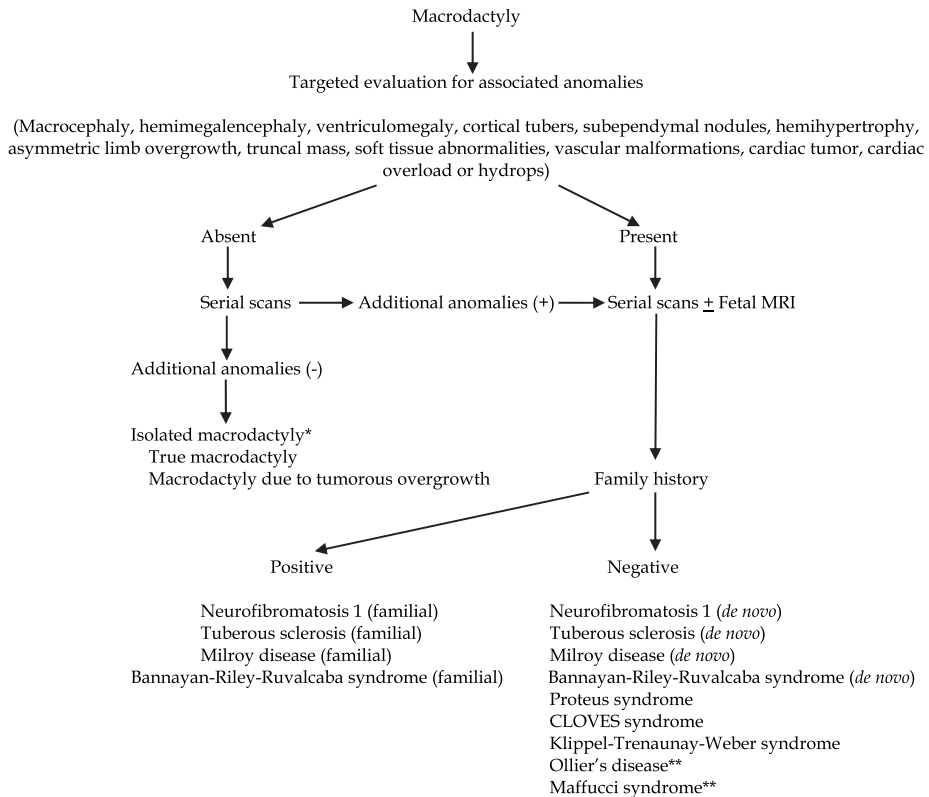
In addition to these syndromes which are well-known and more frequent, macroductyly as a feature of several other rare conditions has also been observed. In this context, macroductyly has been reported in association with minor tibial duplication (Adamsbaum et al., 1991), benign lipoblastomatosis with the relationship of this condition to Proteus syndrome being unclear (Colot et al., 1984), terminal osseous dysplasia with pigmentary defects (Brunetti-Pieri et al., 2010), macrocephaly-capillary malformation syndrome (reported as enlarged hands in one case) (Barnicoat et al., 1996), segmentary fibrous dysplasia (Keymolen et al., 1999) and a lethal skeletal dysplasia associated with ectopic digits (Morton et al., 1998). These conditions have overlapping features such as overgrowth and vascular malformations with well defined syndromes like Proteus syndrome and therefore, they should be kept in mind for the differential diagnosis of syndromic macroductyly.

4. Conclusion

Although the majority of cases with macroductyly are isolated, prenatal recognition of an enlarged digit mandates thorough evaluation of all systems in search for associated anomalies which may indicate syndromic involvement. Moreover, serial scans are recommended as some of the features such as hemihypertrophy may develop over time and indirect signs such as cardiac overload or hydrops fetalis may lead to recognition of an additional finding. In addition, fetal magnetic resonance imaging may be considered in cases with associated anomalies, although its contribution is controversial. As macroductyly can be a clinical finding in several autosomal dominantly inherited disorders such as neurofibromatosis, tuberous sclerosis, Bannayan-Riley-Ruvalcaba syndrome and Milroy disease, family history and examination of further family members, prospect mother and father being the first ones to be evaluated, are mandatory to reveal the familial occurrence of a further case (Yüksel et al., 2009). Amniotic band syndrome, which causes swelling and edema distal to the point of constriction, should also be included in the differential diagnosis of prenatally diagnosed macroductyly (Yüksel et al., 2009).

A practical algorithm for the prenatal evaluation of macroductyly is depicted in Fig. 2. Further case reports/series and information on the outcome of isolated and syndromic macroductyly cases will help to improve the evaluation and management of this entity.

It could be speculated that the most critical aspect in the management of isolated macroductyly is its possible association with a syndrome which could become evident later in childhood, and emphasizing this possibility is mandatory when counselling the parents. Knowing that there is a significant clinical overlap between the overgrowth syndromes and that the phenotype may well develop in time, postnatal follow-up of the newborn during the first decade on a yearly basis by a multidisciplinary team consisting of a geneticist, dermatologist and orthopedic surgeon should be considered and the parents should be counselled accordingly.



* Associated anomalies may become overt postnatally and may ultimately lead to the diagnosis of a specific syndrome associated with macroductyly

** Prenatal diagnosis has not been reported previously.

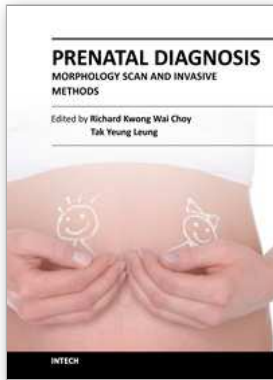
Fig. 2. Algorithym for the management and work-up for differential diagnosis of prenatal finding of macroductyly.

5. References

- Adamsbaum C, Kalifa G, Seringe R & Bonnet JC. Minor tibial duplication: a new cause of congenital bowing of the tibia. *Pediatr Radiol*. 1991;21(3):185-8.
- Aldrich CS, Hong CH, Groves L, Olsen C, Moss J & Darling TN. Acral lesions in tuberous sclerosis complex: insights into pathogenesis. *J Am Acad Dermatol*. 2010 Aug;63(2):244-51.
- Alomari AI. Characterization of a distinct syndrome that associates complex truncal overgrowth, vascular, and acral anomalies: a descriptive study of 18 cases of CLOVES syndrome. *Clin Dysmorphol*. 2009 Jan;18(1):1-7.
- Alomari AI, Chaudry G, Rodesch G, Burrows PE, Mulliken JB, Smith ER, Fishman SJ & Orbach DB. Complex Spinal-Paraspinal Fast-Flow Lesions in CLOVES Syndrome: Analysis of Clinical and Imaging Findings in 6 Patients. *AJNR Am J Neuroradiol*. 2011 Feb 10.
- Barnicoat A, Salman M, Chitty L & Baraitser M. A distinctive overgrowth syndrome with polysyndactyly. *Clin Dysmorphol*. 1996 Oct;5(4):339-46.

- Barsky AJ. Macroductyly. *J Bone Joint Surg Am.* 1967 Oct;49(7):1255-66.
- Boyd KP, Korf BR & Theos A. Neurofibromatosis type 1. *J Am Acad Dermatol.* 2009 Jul;61(1):1-14.
- Brasseur A, Seryer D, Plancq MC, Krim G, Lanta S & Le Blanche A. [Thoraco-brachial cystic lymphangioma and Proteus syndrome: prenatal diagnosis and MR follow-up]. *J Radiol.* 2009 May;90(5 Pt 1):608-11.
- Brunetti-Pierri N, Lachman R, Lee K, Leal SM, Piccolo P, Van Den Veyver IB & Bacino CA. Terminal osseous dysplasia with pigmentary defects (TODPD): Follow-up of the first reported family, characterization of the radiological phenotype, and refinement of the linkage region. *Am J Med Genet A.* 2010 Jul;152A(7):1825-31.
- Casal D, Mavioso C, Mendes MM & Mouzinho MM. Hand involvement in Ollier Disease and Maffucci Syndrome: a case series. *Acta Reumatol Port.* 2010 Jul-Sep;35(3):375-8.
- Colot G, Castermans-Elias S & Philippet G. Macroductyly associated with benign lipoblastomatosis. *Ann Chir Main.* 1984;3(3):262-5.
- Coombs PR, James PA & Edwards AG. Sonographic identification of lower limb venous hypoplasia in the prenatal diagnosis of Klippel-Trénaunay syndrome. *Ultrasound Obstet Gynecol.* 2009 Dec;34(6):727-9.
- Fernandez-Pineda I, Fajardo M, Chaudry G & Alomari AI. Perinatal clinical and imaging features of CLOVES syndrome. *Pediatr Radiol.* 2010 Aug;40(8):1436-9.
- Franceschini P, Licata D, Rapello G, Guala A, Di Cara G & Franceschini D. Prenatal diagnosis of Nonne-Milroy lymphedema. *Ultrasound Obstet Gynecol.* 2001 Aug;18(2):182-3.
- Ghalli FE. Macroductyly in tuberous sclerosis. *Pediatr Dermatol.* 2001 Jul-Aug;18(4):364-5.
- Goldman AB & Kaye JJ. Macroductyly lipomatosa: radiographic diagnosis. *AJR Am J Roentgenol.* 1977 Jan;128(1):101-5.
- Gonçalves LF, Rojas MV, Vitorello D, Pereira ET, Pereira M & Saab Neto JA. Klippel-Trénaunay-Weber syndrome presenting as massive lymphangiohemangioma of the thigh: prenatal diagnosis. *Ultrasound Obstet Gynecol.* 2000 Jun;15(6):537-41. Review.
- Isaacs H. Perinatal (fetal and neonatal) tuberous sclerosis: a review. *Am J Perinatol.* 2009 Nov;26(10):755-60.
- Jamis-Dow CA, Turner J, Biesecker LG & Choyke PL. Radiologic manifestations of Proteus syndrome. *Radiographics.* 2004 Jul-Aug;24(4):1051-68. Review.
- Keymolen K, De Smet L, Kenis H & Fryns JP. Segmentary fibrous dysplasia manifesting as macroductyly. *Genet Couns.* 1999;10(4):373-6.
- Kotwal PP & Farooque M. Macroductyly. *J Bone Joint Surg Br.* 1998 Jul;80(4):651-3.
- Krengel S, Fustes-Morales A, Carrasco D, Vázquez M, Durán-McKinster C & Ruiz-Maldonado R. Macroductyly: report of eight cases and review of the literature. *Pediatr Dermatol.* 2000 Jul-Aug;17(4):270-6.
- Lev-Sagie A, Hamani Y, Raas-Rothschild A, Yagel S & Anteby EY. Prenatal ultrasonographic diagnosis of atypical Nonne-Milroy lymphedema. *Ultrasound Obstet Gynecol.* 2003 Jan;21(1):72-4.
- Lin SJ et al., (updated May 18, 2011). Benign Hand Tumors, In: *Medscape*, January 10, 2012, Available from: <http://emedicine.medscape.com/article/1286448-overview>
- Makhoul IR, Sujov P, Ghanem N & Bronshtein M. Prenatal diagnosis of Milroy's primary congenital lymphedema. *Prenat Diagn.* 2002 Sep;22(9):823-6.
- Marrero IC et al., (updated Nov 17, 2011). Malignant Hand Tumors, In: *Medscape*, January 10, 2012, Available from: <http://emedicine.medscape.com/article/1286560-overview>
- McEwing RL, Joelle R, Mohlo M, Bernard JP, Hillion Y & Ville Y. Prenatal diagnosis of neurofibromatosis type 1: sonographic and MRI findings. *Prenat Diagn.* 2006 Dec;26(12):1110-4.

- Morton JE, Kilby MD & Rushton I. A new lethal autosomal recessive skeletal dysplasia with associated dysmorphic features. *Clin Dysmorphol*. 1998 Apr;7(2):109-14.
- Norman-Taylor F & Mayou BJ. Macroductyly in tuberous sclerosis. *J R Soc Med*. 1994 Jul;87(7):419-20.
- Northrup H & Au KS. Tuberous Sclerosis Complex. 1999 Jul 13 [updated 2009 May 7]. In: Pagon RA, Bird TD, Dolan CR, Stephens K, editors. *GeneReviews* [Internet]. Seattle (WA): University of Washington, Seattle; 1993-.
- Online Mendelian Inheritance in Man, Web-based databases, Available from: www.ncbi.nlm.nih.gov/omim
- Paladini D, Lamberti A, Teodoro A, Liguori M, D'Armiento M, Capuano P & Martinelli P. Prenatal diagnosis and hemodynamic evaluation of Klippel-Trenaunay-Weber syndrome. *Ultrasound Obstet Gynecol*. 1998 Sep;12(3):215-7.
- Peng HH, Wang TH, Chao AS, Chang YL, Shieh SC & Chang SD. Klippel-Trenaunay-Weber syndrome involving fetal thigh: prenatal presentations and outcomes. *Prenat Diagn*. 2006 Sep;26(9):825-30.
- Razzaghi A & Anastakis DJ. Lipofibromatous hamartoma: review of early diagnosis and treatment. *Can J Surg*. 2005 Oct;48(5):394-9.
- Sahoo B, Handa S & Kumar B. Tuberous sclerosis with macroductyly. *Pediatr Dermatol*. 2000 Nov-Dec;17(6):463-5.
- Sapp JC, Turner JT, van de Kamp JM, van Dijk FS, Lowry RB & Biesecker LG. Newly delineated syndrome of congenital lipomatous overgrowth, vascular malformations, and epidermal nevi (CLOVE syndrome) in seven patients. *Am J Med Genet A*. 2007 Dec 15;143A(24):2944-58.
- Sharma S, Sankhyan N, Gulati S, Kumar A, Srinivas M, Shukla B & Mathur SR. Macroductyly and fibrous hamartoma in a child with tuberous sclerosis complex. *J Child Neurol*. 2011 Jan;26(1):95-8.
- Shin AY & Garay AA. Unilateral insensate macroductyly secondary to tuberous sclerosis in a child. *Am J Orthop (Belle Mead NJ)*. 1997 Jan;26(1):30-2.
- Sigaudy S, Fredouille C, Gambarelli D, Potier A, Cassin D, Piquet C & Philip N. Prenatal ultrasonographic findings in Proteus syndrome. *Prenat Diagn*. 1998 Oct;18(10):1091-4.
- Singla V, Virmani V, Tuli P, Singh P & Khandelwal N. Case Report: Macroductyly lipomatosa - Illustration of two cases. *Indian J Radiol Imaging*. 2008 Nov;18(4):298-301.
- Sone M, Ehara S, Tamakawa Y, Nishida J & Honjoh S. Macroductyly lipomatosa: CT and MR findings. *Radiat Med*. 2000 Mar-Apr;18(2):129-32.
- Syed A, Sherwani R, Azam Q, Haque F & Akhter K. Congenital macroductyly: a clinical study. *Acta Orthop Belg*. 2005 Aug;71(4):399-404.
- Tung HE & Shih SL. Tuberous sclerosis with rare presentation of macroductyly. *Pediatr Radiol*. 2009 Aug;39(8):878.
- Turkington JR & Grey AC. MR imaging of macroductyly lipomatosa. *Ulster Med J*. 2005 May;74(1):47-50.
- van Bever Y & Hennekam RC. Isolated macroductyly or extremely localized Proteus syndrome? *Clin Dysmorphol*. 1994 Oct;3(4):351-2.
- Yüksel A, Yagmur H & Kural BS. Prenatal diagnosis of isolated macroductyly. *Ultrasound Obstet Gynecol*. 2009 Mar;33(3):360-2.
- Zonana, J., Rimoin, D. L. & Davis, D. C. Macrocephaly with multiple lipomas and hemangiomas. *J. Pediatr*. 89: 600-603, 1976.
- Zoppi MA, Ibba RM, Floris M, Putzolu M, Crisponi G & Monni G. Prenatal sonographic diagnosis of Klippel-Trénaunay-Weber syndrome with cardiac failure. *J Clin Ultrasound*. 2001 Sep;29(7):422-6.



Prenatal Diagnosis - Morphology Scan and Invasive Methods

Edited by Dr. Richard Choy

ISBN 978-953-51-0614-2

Hard cover, 210 pages

Publisher InTech

Published online 29, June, 2012

Published in print edition June, 2012

This book provides detailed and comprehensive coverage on various aspects of prenatal diagnosis-with particular emphasis on sonographic and molecular diagnostic issues. It features sections dedicated to fundamentals of clinical, ultrasound and genetics diagnosis of human diseases, as well as current and future health strategies related to prenatal diagnosis. This book highlights the importance of utilizing fetal ultrasound/clinical/genetics knowledge to promote and achieve optimal health in fetal medicine. It will be a very useful resource to practitioners and scientists in fetal medicine.

How to reference

In order to correctly reference this scholarly work, feel free to copy and paste the following:

Hande Yağmur, Atıl Yüksel and Hülya Kayserili (2012). Prenatal Sonographic Diagnosis and Evaluation of Isolated Macroductyly, *Prenatal Diagnosis - Morphology Scan and Invasive Methods*, Dr. Richard Choy (Ed.), ISBN: 978-953-51-0614-2, InTech, Available from: <http://www.intechopen.com/books/prenatal-diagnosis-morphology-scan-and-invasive-methods/prenatal-sonographic-diagnosis-and-evaluation-of-isolated-macroductyly>

INTECH

open science | open minds

InTech Europe

University Campus STeP Ri
Slavka Krautzeka 83/A
51000 Rijeka, Croatia
Phone: +385 (51) 770 447
Fax: +385 (51) 686 166
www.intechopen.com

InTech China

Unit 405, Office Block, Hotel Equatorial Shanghai
No.65, Yan An Road (West), Shanghai, 200040, China
中国上海市延安西路65号上海国际贵都大饭店办公楼405单元
Phone: +86-21-62489820
Fax: +86-21-62489821

© 2012 The Author(s). Licensee IntechOpen. This is an open access article distributed under the terms of the [Creative Commons Attribution 3.0 License](#), which permits unrestricted use, distribution, and reproduction in any medium, provided the original work is properly cited.