

Current Trends in Urinary Diversion in Men

S. Siracusano, S. Ciciliato, F. Visalli, N. Lampropoulou and L. Toffoli
*Department of Urology – Trieste University
Italy*

1. Introduction

Prior to the introduction of the ileal conduit more than four decades ago, the options for urinary diversion after cystectomy were extremely limited. Direct cutaneous anastomoses of the collecting system (cutaneous pyelostomies, ureterostomies) offered patients a short-term diversion, but the benefits were outweighed by significant complications: recession or stenosis of the stoma. The first choice of diversion was the ureterosigmoidostomy with or without antireflux technique. Then it fell in popularity and was replaced with continent/non-continent uretero-ileo-cutaneous diversions. Only in the last years the continent orthotopic neobladder has been widely employed as first procedure choice. At present, patients can be offered a non-continent cutaneous diversion, a continent cutaneous diversion or an orthotopic neobladder urinary reconstruction (ONR).

2. Surgical indications

Urinary diversion is necessary in patients who undergo cystectomy.

The choice of a specific urinary diversion should be performed on the basis of the mental status of the patient, renal function and overall health (Table1).

The main surgical indications to perform a urinary diversion or a bladder replacement using transposed intestinal segments are bladder cancer, neurogenic bladder dysfunction, idiopathic detrusor overactivity and chronic inflammatory conditions (such as interstitial cystitis, tuberculosis, schistosomiasis and postradiation bladder contraction) [1].

If surgical cystectomy is indicated due to invasive bladder cancer the choice for replacing the lower urinary tract function rests between conduit diversion, bladder replacement or continent diversion [2].

In patients affected by neurogenic bladder dysfunction due to congenital or acquired disorders (e.g. Neural tube defect or spinal cord injured patients) the main indications for such surgery is represented by intractable incontinence, deteriorating renal function and high bladder pressures. The choices would include either bladder reconstruction, replacement or continent diversion [3].

Equally in subjects with severe idiopathic detrusor overactivity, if conservative measures fail the surgical therapy which may involve transposition of intestinal segments into the urinary tract (e.g. Clam enterocystoplasty) can provide effective treatment for some patients [4].

Finally in patients affected by idiopathic interstitial cystitis with a failure of all conservative treatments the surgical choices range from ileal conduit diversion to orthotopic neobladder reconstruction (ONR). In this context in case of bladder tuberculosis resulting in intolerable frequency, pain, urgency and haematuria with a small and incapable bladder the surgical therapy ranges from ileal conduit diversion to augmentation cystoplasty [5].

Choice of urinary diversion

At present urologists have a variety of urinary diversions using different types of bowel segments based on an individual patient's need and desire. In the past the ureterosigmoidostomy and the rectal neobladder as described by Mouclaire were the earliest forms of continent urinary diversion however, due to the rate of complications, these surgical solutions are at present abandoned. The ileal conduit remains the most common form of non-continent urinary diversion practiced worldwide today and it is the standard to which all other urinary diversions are compared [6]. Continent cutaneous diversions using detubularized colonic segments requiring timed intermittent self-catheterization. These diversions gained popularity in the 1980s and are still applied today in patients for whom an ONR is not indicated. In this way the ONR represents the most innovative surgical solution of the last thirty years because it seems to offer a satisfactory quality of life.

Urinary diversions used today in patients undergoing radical cystectomy can be categorized into three basic categories as follows : I) bowel conduits II) continent cutaneous stomal reservoirs using colonic segments III) orthotopic neobladder reconstruction (ONR) [7]. On the basis of the above reported classification we will restrict our focus on the ileal conduit, on the continent cutaneous diversions and the ONR by the use of ileal bowel.

The ileal conduit is the simplest and most commonly performed urinary diversion for which the longest follow-up is available and due to the short operative time it is often applied in patients with significant medical comorbidities in an attempt to minimize postoperative complications and the need for reoperation [8].

The continent urinary diversion involves the creation of a low pressure reservoir of good capacity using a detubularised intestinal segments as described by Kock [9]. In this setting several techniques can be used to maintain continence adopting the principle of the nipple valve and one of the most popular type is the flap valve by the use of the appendix implanted into the reservoir as described by Mitrofanoff [10]. In this surgical technique the distal end of the continence channel is brought out as a stoma through the abdominal wall for clean intermittent self-catheterisation, thus avoiding the use of a stoma bag but requiring the ability of the patient to catheterize the stoma.

In ONR the most used intestinal segment is the ileum due to its easy and ductile use while colonic segments although they had already been employed at the beginning of the "ONR era" they showed a higher number of late complications in comparison with ileum segments [11].

Patients selection criteria: Absolute and relative contraindications

The primary goals of urinary diversion are to provide the best local cancer control, to reduce the potential range of complications and to guarantee the best quality of life for the patient. The decision process is complex and involves consideration of issues related to cancer stage and location, medical comorbidities, technical surgical issues, treatment needs, and patient desires related to quality-of-life and lifestyle (Table 2). In this setting, patients should be

aware that intraoperative pathological findings could modify the type of urinary diversion planned, as in the case of a short mesentery or cancer-related issues such as positive urethral margin, or gross extravesical disease precluding a negative surgical margin. For this reason, all patients planned for an ONR should have a stoma site marked preoperatively by an enterostomal therapist and at the same time have read and accepted the informed consent for an alternative urinary diversion [7,12,13].

In this way an absolute contraindication to continent diversion of any type is compromised renal function that results from long-standing obstruction or chronic renal failure, with serum creatinine levels above 150 to 200 mol/L.

In patients with borderline renal function, creatinine clearance should be evaluated because at least a creatinine clearance of 60 mL/min is recommended for continent diversions [14]. A severe hepatic dysfunction is also a contraindication for continent diversion [15] because the reabsorption and recirculation of urinary metabolites require normal liver function [16-17-20]. In fact the interposition of intestine in the urinary tract results in a marked increase in the absorption of urinary ammonia into the portal circulation resulting in a metabolic adaptation in a normal functioning liver without a hyperammonemia with a consequent altered mental status [19].

Regarding related contraindications, we know that these are steadily decreasing. However some, such as mental impairment, external sphincter dysfunction or recurrent urethral stricture, deserve serious consideration.

Notably, old age is not a contraindication for ONR. Older patients, as part of the informed consent, need to be aware that they have a greater incidence of enuresis or nocturnal incontinence than do younger men, but age by itself should not be a contraindication. In this context, physiologic rather than chronologic age must be taken into consideration [20]. Although urinary continence rates are somewhat lower in patients over 70 years of age, satisfactory continence rates and functional outcomes can be obtained. [21,22].

Obesity does not preclude orthotopic diversion and in some cases an orthotopic diversion may be advantageous because of the difficulty of constructing an optimal stoma for a urostomy appliance with conduits and the difficulty in negotiating a catheter through a thick abdominal wall for catheterization of a continent cutaneous pouch. In addition, large fluctuations in patient weight can change the angle of the originally constructed pouch making it difficult to catheterize [23].

Satisfactory functional outcomes with ONR after cystectomy have been reported in carefully selected patients who have received previous definitive, full dose pelvic irradiation [24,25]. However, these are technically complex and demanding procedures with a high risk for perioperative complications [26]. Common complications reported in post-radiation surgical series include ureteral stricture in up to 32% of patients, prolonged incontinence in up to 44%, stomal problems in up to 39%, and fistulas in up to 7%. Reoperations to address these complications occur in 8% to 69% of patients and the most common reasons for reoperation include stomal revisions, ureteral anastomotic revisions, and procedures to correct incontinence and repair of fistulas [24,27].

Patients with compromised intestinal function, particularly inflammatory bowel disease, may be better served by an incontinent bowel conduit. A thorough evaluation of the colon by a contrast enema, sigmoidoscopy, or colonoscopy is recommended when planning to use large bowel segments for the urinary diversions to rule out colonic pathology such as diverticulosis, inflammatory bowel disease, or occult colon cancer, which would prevent

their use. A family or personal history of colon cancer or familial polyposis may predispose the patient to developing an adenocarcinoma in a colonic urinary reservoir segment and should be taken into consideration during the diversion selection process [28,29].

In conclusion the goal of patient counseling about urinary diversion should be to determine the method that is the safest for cancer control, that has the fewest complications over both the short and the long term and that provides the easiest adjustment for patients' lifestyle, thereby supporting the best quality of life [7]. The ileal conduit is still the best urinary diversion method in many patients who have bladder cancer with associated chronic medical disease or certain surgical factors that render other urinary diversion techniques difficult to carry out. Finally we believe that all patients are potentially candidates for an ONR although the main problem is to identify patients for whom an ONR may be not indicated.

Bowel Segment	Primary Indication
Gastric	Children requiring diversion (extrophy, pelvic radiation); Renal insufficiency
Jejunum	Pelvic radiation; Deficient ureteral length; Compromised viability of other small or large bowel
Ileum or ileal-colic reservoirs	Malignancies requiring removal of the bladder; Severe hemorrhagic cystitis; Incontinence
Colon (ureterosigmoidostomy)	Children requiring diversion (extrophy, pelvic radiation); No other bowel segment alternative
Transverse colon conduit	Malignancies requiring removal of the bladder; Small bowel not practical

Table 1. Indications for use of bowel segments in urinary diversion [1,6]

Absolute contraindications
Impaired renal function
Impaired hepatic function
Inadequate intellectual capacity
Positive apical urethral margin (for neobladder)
Unmotivated patient
Relative contraindications
Advanced age
Need for adjuvant chemotherapy
Prior pelvic radiation
Bowel disease (especially inflammatory bowel disease)
Urethral pathology
Local disease and high risk of local recurrence

Table 2. Absolute and Relative Contraindications for Continent Cutaneous/Orthotopic Neobladder Urinary Diversions [1,6]

3. Non continent cutaneous diversions: Surgical aspects and postoperative complications

The ileal and the colon conduit represent the non-continent cutaneous urinary diversions. The ileal conduit has been the mainstay of urinary diversion over the past forty-five years and, in authors' opinion, it remains the first choice against all other compared urinary diversions. It consists of diverting urine to a short intestinal segment brought out through the anterior abdominal wall. The ileal resection can induce malabsorption of bile salts and vitamin B₁₂. The colon conduit was less employed because of resulted in electrolyte abnormalities and was more amenable to antireflux ureteral implantation techniques. The non-refluxing technique is employed for a better maintenance of upper urinary tract integrity.

Ileal conduit

Ureteroileal urinary diversion is the most common method of non-continent urinary diversion. The basic technique for creation of the ileal loop has not changed significantly since the original description by Seiffer 1935. The procedure was subsequently popularized by Bricker.

The patient is placed in supine position and a vertical midline or paramedian incision from the symphysis pubis to the umbilicus or beyond is required for good exposure [30].

The ureters are identified and transected approximately 3 or 4 cm above the bladder and then they are minimally mobilized taking care to preserve the surrounding adventitia and fat. The conduit is constructed using an ileal segment 15 to 20 cm long that is isolated approximately 20 cm proximal to the ileocecal valve [31,32,33].

Once the appropriate length of bowel is selected and isolated, the mesentery is divided proximally and distally and individual mesenteric blood vessels are ligated. The bowel is divided, thus isolating the segment selected for conduit construction. The continuity of the small intestine is reestablished, allowing for normal bowel function. The base of the conduit is closed and the ureters are reimplanted directly, creating an antirefluxing ureteroileal anastomosis.

Ureteral stents (small-diameter, multichannel, silicone catheters) are placed through the ureteral anastomosis, the conduit and into the pelvis to facilitate urinary drainage while the anastomosis is healing [33-34]. The conduit is usually positioned in the right lower quadrant of the abdomen in an isoperistaltic direction [32].

To create the stoma, a small circle of skin is excised at the premarked site. And the underlying cylinder of fat is removed. The fascia is incised in a cruciate fashion. The end of the conduit is brought through the lateral aspect of the rectus abdominis muscle and anchored to the fascia, and the stoma is then formed [34]. The stoma should protrude, without tension approximately 2.5-3 cm above the skin surface. A Rutzen bag can be applied to the stoma on the fifth or sixth postoperative day with complete comfort for the patient [34].

Jejunal conduit

Jejunal conduit urinary diversion is used rarely, since many better alternatives are available. However, jejunal conduits have been used in cases in which there has been significant ileal and colonic disease caused by previous irradiation and inflammatory bowel disease or there has been loss of the middle and distal ureter [35].

As is discussed later, electrolyte disturbances can occur after incorporation of intestinal segments into the urinary tract; these are more common when the jejunum is used for conduit construction. In approximately 40% of patients with jejunal urinary conduits, hyponatremic, hyperkalemic, hypochloremic metabolic acidosis and azotemia develop [36]. The jejunum is unable to maintain large solute gradients, so large amounts of water and solute pass through the jejunal wall. Sodium and chloride are rapidly excreted into the conduit, and potassium is passively absorbed [36-37].

Aldosterone is produced, resulting in reabsorption of hydrogen and excretion of potassium into the distal tubule of the kidney and consequent acidosis and movement of potassium from the body's intracellular stores. As water is lost into the conduit, extracellular fluid volume is reduced, as is the glomerular filtration rate. The renin-angiotensin system is activated, which further stimulates aldosterone secretion. Urea may be absorbed from the jejunal lumen, which (with dehydration) contributes to azotemia [36]. As with other bowel segments incorporated into the urinary tract, the length of jejunum should be as short as possible to reduce metabolic abnormalities. The ureters are brought out from the retroperitoneum below the ligament of Treitz. An appropriate segment of jejunum is identified and isolated and it is important to preserve an adequate blood supply to the segment. In contrast to the ilial conduit, the isolated jejunum should lie above the reanastomosed jejunum. The proximal end of the conduit is directed towards the retroperitoneum and the conduit is oriented in an isoperistaltic direction. The ureters are anastomosed to the jejunum, with placement of stents to reduce early postoperative electrolyte abnormalities. The mesenteric window is closed using nonabsorbable sutures. The stoma is created in the same way as described for an ileal conduit and is usually located in the right upper quadrant [38].

Colon conduit

There are several advantages to using the large bowel for the construction of urinary conduits: nonrefluxing ureterointestinal anastomoses are easily performed, possibly abrogating the deleterious effects of reflux on the upper urinary tracts [37-39].

In the colon conduit stomal stenosis is uncommon because of the wide diameter of the large bowel but limited absorption of electrolytes occurs; the blood supply to the transverse and sigmoid colon is abundant [39]. Either the transverse or the sigmoid colon can be used, allowing for placement of the conduit high or low in the abdomen, depending on the integrity and condition of the ureters. Use of the transverse colon for conduit construction is especially well suited for patients who have received extensive pelvic irradiation or when the middle and distal ureters are absent [37,39].

The blood supply of the transverse colon is based on the middle colic artery.

The greater omentum is separated from the superior surface of the transverse colon, and a segment of bowel, usually 15 cm in length, is selected for the conduit [39]. Short mesenteric incisions are made, and the colon is divided proximally and distally. Once the conduit is isolated, bowel continuity is reestablished. The proximal end of the conduit is closed and fixed in the midline posteriorly. The ureters are brought through small incisions in the posterior peritoneum and reimplanted into the base of the conduit [39]. The stoma may be positioned on either the patient's right or left side.

A sigmoid conduit is constructed in a similar manner. Great care should be taken to preserve the blood supply by carefully selecting a segment with a good blood supply and by

making short mesenteric incisions. The conduit is positioned lateral to the reapproximated sigmoid colon. Ureteral reimplantation and stoma construction are completed [39].

The ureters can be reimplanted into the large intestine either in a way that prevents reflux or by anastomosis directly into the bowel. Ureteral reflux is prevented by constructing a short tunnel (approximately 2-3 cm in length) of bowel mucosa, through which the distal ureter runs [37,39]. Frequently, this is accomplished by incising the tenia of the large bowel for a distance of 3-4 cm. The incision is carried through the muscular fibers of the bowel wall, sparing the mucosa. A small elliptic segment of mucosa is removed, and a mucosa-to-mucosa anastomosis is performed between the ureter and the mucosa of the bowel. The muscularis of the tenia is repositioned over the ureter to create the tunnel [39].

Cutaneous ureterostomy

This surgical technique is based on the simple bilateral ureterostomy or alternatively on the transureteroureterostomy. From a technical point of view the first surgical solution is easier and faster than the transureteroureterostomy. In particular, in order to carry out of a transureteroureterostomy with cutaneous ureterostomy the ureters are isolated with care to preserve the blood supply. A retroperitoneal course anterior to the great vessels for the least dilated is created [40,41]. If only a single ureter is obstructed, a simple stoma can be created by sewing the end of the ureter flush with the skin at the stoma site. Another option, when the ureter is narrow, is to create a V-flap stoma. If both ureters are dilated, a single stoma can be created by suturing the ureters together, everting them and anastomosing the ends to the skin. When a single ureter is dilated, transureterostomy with retroperitoneal passage of the smaller ureter to the contralateral side is combined with the cutaneous ureterostomy [38].

Postoperative complications

Complications occurring after urinary diversion are generally a product of surgical technique, the underlying disease process and its treatment, the age of the patient, and the length of follow-up. Postoperative complications are divided into early and late.

Early complications (occurring in approximately 10% of patients) are wound infection, followed by ureteroileal leakage, intestinal obstruction, intestinal fistula and acute pyelonephritis [30].

Late complications (10-20% of patients) include metabolic disorders, stomal stenosis, chronic pyelonephritis, and calculi [30].

Metabolic and nutritional disorders

Fluid, electrolyte, nutrient, and waste product excretion or absorption normally occurs across the intestinal wall. The extent of absorption or excretion is dependent on the concentration of these substances in the lumen or blood and on which segment of bowel is in contact with them.

Metabolic abnormalities may occur when intestinal segments are interposed into the urinary tract [33].

The pathogenesis and nature of metabolic abnormalities occurring after incorporation of the ileum or colon into the urinary tract differ from those associated with jejunal conduits [35]; when such segments are used, sodium and chloride are absorbed across the bowel surface. Chloride is absorbed in slight excess of sodium, resulting in a net loss of bicarbonate into the bowel lumen. Preexisting renal failure contributes to the development and severity of the

disorder, as does a large bowel surface area and long contact time. Hyperchloremic acidosis is more common in patients who undergo ureterosigmoidostomy than in patients who undergo simple conduit construction using either the ileum or the colon, because of the larger surface area and longer contact time with urine associated with ureterosigmoidostomies [42].

Hyperchloremic metabolic acidosis may manifest clinically as weakness, anorexia, vomiting, Kussmaul breathing, and coma. One potential long-term complication of chronic acidosis may be decreased bone calcium content and osteomalacia [36].

Bile salts are important for fat digestion and uptake of vitamins A and D. Bile salt metabolism may be altered after ileal resection [43].

Resection of small segments of the ileum may be associated with mild malabsorption and steatorrhea owing to increased concentrations of bile salts delivered to the colon.

The increased concentration of such salts leads to decreased colonic absorption of water and electrolytes [35]. The distal ileum is important for reabsorption of bile acids, the use of this part of intestine for uncontinent urinary diversion causes abnormal high concentrations of bile acids in the colon leading to diarrhea due to the altered sodium absorption [43].

Vitamin B12 deficiency may occur as a result of resecting the terminal ileum to reconstruct the lower urinary tract. The signs of vitamin B 12 deficiency include megaloblastic macrocytic anemia and neurologic injury, which become permanent if allowed to persist [33,35,42,44].

Stomal complications

Stoma related complications occurred in 15% of patients with the most frequent being parastomal hernia, stenosis and various skin irritations or fungal infections [32,33]. The majority of stoma related complications occurred within the first 5 years after surgery [32].

Stomal stenosis can lead to conduit elongation and upper-tract obstruction. This condition can be diagnosed relatively easily by catheterizing the stoma and measuring the residual urine volume. It is corrected by revision of the stoma [42].

Skin irritation or infections are most common in procedures in which an appliance is worn and there is prolonged contact of the skin with urine. Some patients' skin may be sensitive to adhesive agents [30].

Urinary tract infection and pyelonephritis

Pyelonephritis occurs in approximately 12% of patients who have undergone urinary diversion. The infectious complications occurred at a median of 1.8 years after surgery [45].

Treatment is based on a properly collected urine sample for culture. A urine sample should not be collected from the pouch; rather, the pouch should be removed, the stoma cleansed with an antiseptic, and a catheter advanced gently through the stoma.

If infection has occurred in a patient with a simple conduit, the volume of residual urine within the conduit should be recorded. Obstruction and stasis of urine within the reconstructed urinary tract are risk factors for the development of infection [32].

Although many patients with preexisting dilation of the upper urinary tract show improvement or resolution of the dilation after urinary diversion or bladder substitution, progressive renal deterioration as manifested by hydronephrosis or an increasing serum creatinine level (or both) occur in a certain percentage of patients who undergo these procedures [42]. The incidence of either complication increases after 10 years. Pyelographic

evidence of upper urinary tract deterioration has been noted in up to 50% of patients who have undergone urinary diversion at an early age.

Recurrent upper urinary tract infection and high-pressure ureteral reflux and obstruction, usually in combination, contribute to the likelihood of renal deterioration.

Calculi

Calculi occur in approximately 8% of patients who undergo urinary diversion, at a median of 2.5 years after surgery [33].

Such patients have several risk factors for the development of various calculi.

Nonabsorbable staples, mesh, or suture material used to construct conduits or reservoirs may act as a nidus for stone formation [33].

Colonization in either conduits or reservoirs is common, whereas symptomatic infection is much rarer.

Certain bacteria can contribute to stone formation; some bacteria commonly found in the urinary tract, including: *Proteus*, *Klebsiella*, and *Pseudomonas* species, produce urease, a urea-splitting enzyme that contributes to the formation of ammonia and carbon dioxide.

Hydrolysis of these products results in an alkaline urine supersaturated with magnesium ammonium phosphate, calcium phosphate, and carbonate apatite crystals.

Management of such infection-related stones requires stone removal, resolution of infection, and, often, use of adjunctive agents to complete stone dissolution [33].

The likelihood of stone formation is increased by the development of systemic acidosis, as described previously. Prolonged contact of the urine with the intestinal surface facilitates the exchange of chloride for bicarbonate [33].

Bicarbonate loss results in systemic acidosis and hypercalciuria. The combination of hypercalciuria and alkaline urine predisposes a patient to the development of calcium calculi. In addition, the terminal ileum is responsible for bile salt absorption; if this portion of the intestine is used for conduit or bladder reservoir construction, excess bile salts in the intestine may bind calcium and result in increased absorption of oxalate, which may lead to the development of oxalate-containing calculi [36].

Hypocitraturia may also be a risk factor for stone disease in patients undergoing bladder replacement [36].

Excess conduit length, urine stasis, and dehydration make the development of calculi more likely.

4. Orthotopic neobladder reconstruction (ONR): Surgical aspects and postoperative complications

In 1979, Camey and Le Duc published their clinical experience with ONR. This orthotopic bladder substitute has evolved into the most ideal form of urinary diversion available today and should be considered the gold standard with which other forms of diversion are compared. Before 1990, the orthotopic substitution was reserved for male patients with invasive bladder cancer while the same surgical approach was considered contraindicated in the female subjects because the urethra was removed during cystectomy to assure adequate oncological results. It was also believed that the female patient would be unable to maintain the continence mechanism if orthotopic diversion was performed after cystectomy. Actually, it has been shown that the urethra can be saved in the most women undergoing cystectomy for bladder cancer without compromising the oncological results [46].

Models of ONR

Radical cystectomy is the standard treatment for localized muscle-invasive bladder cancer. Different types of intestinal segments have been used for urinary diversion, including stomach, ileum, colon in humans and animals. However, the terminal ileum is most often used for bladder substitution. Therefore, the ideal diversion should be fully continent, cosmetically impeccable, allowing easy and complete emptying within socially acceptable intervals, and preserve renal function [47].

- In Camey II orthotopic substitution a total of 65 cm of ileum is isolated, with an area of the ileum identified to reach the region of the urethra in a tension-free manner. After the integrity of the bowel is restored, the mesenteric trap is closed, and the isolated portion of ileum is opened along the antimesenteric border for the entire length, except the area previously identified for urethral anastomosis. In this region, the ileal incision is directed toward the mesenteric border. The ileum is then placed in a transverse U orientation. The medial borders of the U are sutured together with a running absorbable suture. A fingertip opening is made in the preselected area for the ileourethral anastomosis, the entire ileal plate is brought down to the pelvis, and urethroenteric anastomosis is performed. The ureteroileal anastomosis is then performed by a Le Duc technique. The reservoir is completed by folding the ileal plate and suturing with a running absorbable suture. The ends of the U are anchored to the pelvic floor to reduce tension [48].
- The ileal neobladder developed by Hautmann was an ileal reservoir with a “W configuration” that wanted to guarantee a reduction of nighttime incontinence. A segment of terminal ileum of approximately 70 cm is selected. The bowel is reconstituted, and the mesenteric trap is closed. The ileal section that reaches the urethra most easily is identified and marked with a traction suture along the antimesenteric border. The isolated bowel segment is then arranged in either an M or W shape and is incised. The entire segment is opened along the antimesenteric border except for a 5-cm section along the traction suture, where the incision is directed toward the anterior mesenteric border to make a U-shaped flap. This facilitates anastomosis of the neobladder to the urethra. The four limbs of the M or W are then sutured to one another with a running absorbable suture. In the center of the previously developed flap, a segment of the ileal wall is excised. The ileourethral anastomosis is then performed with the sutures tied from “inside” the neobladder. Once the ileal neobladder is situated in the pelvis and the urethral sutures are tied, the ureters are implanted from inside the neobladder through a small incision in the ileum at a convenient site as reported by Abol-Enein (Fig.1) or in monolateral fashion as described by Siracusano [49]. The remaining portion of the anterior wall is then closed with a running absorbable suture.
- The Studer ileal bladder substitute uses a portion of terminal ileal segment: 54 to 60 cm is isolated approximately 25 cm proximal to the ileocecal valve. Bowel continuity is restored, and the ends of the isolated segment are closed with a running absorbable suture. The distal 40-cm segment of ileum is placed in a U shape and opened along the antimesenteric border. The ureters are split and anastomosed in an end-to-side fashion to the proximal afferent tubular portion of ileum. The two medial borders of the U-shaped ileum are then oversewn with a running absorbable suture. The bottom of the U is folded over between the two ends of the U. After the lower half of the anterior wall

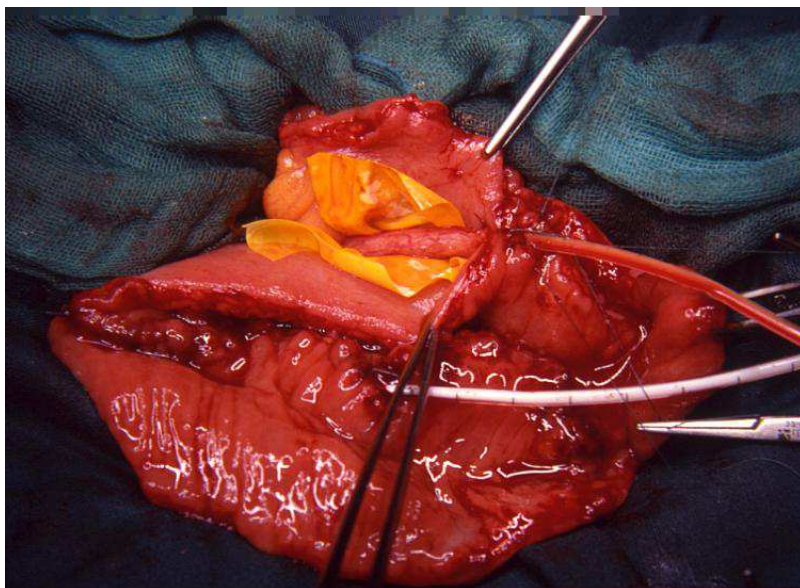


Fig. 1. Spatulated ureters are anastomosed to intestinal mucosa of the lateral wall of the trough. The ureters are anastomosed on 8 Fr anti-reflux double "J" stents (By Siracusano Eur Urol 38 : 313, 2000)

and part of the upper half are closed, a finger is introduced through the remaining reservoir opening to determine the most caudal part of the neobladder. A hole is cut out in this dependent portion of ileum, away from the suture line, which allows urethral anastomosis. The urethroenteric anastomosis is performed, and the remaining portion of the reservoir is then closed [50].

- The Kock ileal reservoir utilizes intussuscepted nipple valves for both the afferent and efferent limbs to prevent urinary reflux. A total of 61 cm of terminal ileum is isolated. 22-cm segments are placed in a U configuration and opened adjacent to the mesentery. The more proximal 17-cm segment of ileum will be used to make the afferent intussuscepted nipple valve. The posterior wall of the reservoir is then formed by joining the medial portions of the U with a continuous running suture. A 5- to 7-cm antireflux valve is made by intussusception of the afferent limb with the use of Allis forceps clamps. The afferent limb is fixed with two rows of staples placed within the leaves of the valve. The valve is fixed to the back wall from outside the reservoir. After completion of the afferent limb, the reservoir is completed by folding the ileum on itself and closing it (anterior wall). The most dependent portion of the reservoir becomes the neourethra. Ureteroileal anastomosis is performed first, and urethroenteric anastomosis is completed in a tension-free, mucosa-to-mucosa fashion [51].
- The "vescica ileale padovana" (VIP) is a modified form of Camey II with a more spherical reservoir. A portion of terminal ileum 40 cm long is isolated approximately 20 cm proximal to the ileocecal valve and opened along the antimesenteric border. The distal 10-cm segment is intended to constitute a tunnel for ileal-urethral anastomosis,

while the proximal 30-cm segment of ileum is folded in a jellyroll fashion to produce a posterior plate. The pouch is then closed anteriorly [52].

- The T pouch ileal neobladder is a variant of Koch ileal reservoir but with a new, safe and simple antireflux technique. The T pouch is constructed from a 44-cm segment of terminal ileum placed in a V formation with a more proximal 8- to 10-cm segment of ileum used to form the antireflux limb. The entire mesentery remains intact to provide excellent viability. Windows of Deaver are opened (with Penrose drains placed into each window) in the distal 3 to 4 cm of the isolated afferent limb. The blood supply remains intact to this afferent ileal segment. A series of interrupted silk sutures are used to approximate the serosa of the adjacent 22-cm limbs (cephalad portion), with the passage of sutures through the corresponding window of Deaver. After the silk suture is passed through the window of Deaver, it is placed at a corresponding site on the adjacent 22-cm segment and then brought back through the same window of Deaver and tied down. The anchored portion of afferent limb is tapered on the antimesenteric border. The ileal segments are opened adjacent to the mesentery beginning at the apex and carried upward to the ostium of the afferent limb. Once the incision reaches the ostium of the afferent limb, it is directed to the antimesenteric border and then carried upward. This provides excellent ileal flaps to cover the tapered afferent ileal segment that is anchored into the serous trough. The ostium of the afferent segment is sutured to the ileal flaps. The ileal flaps are then brought over and oversewn to cover the tapered afferent ileal segment. This completes the posterior wall of the reservoir and forms the antireflux flap-valve mechanism. The reservoir is folded and closed in the opposite direction from which it was opened. The ureteroileal anastomosis is performed to the proximal portion of the afferent ileal segment. The anterior suture line is stopped just short of the right side. Then the result will be anastomosed to the urethra [53].
- The surgeons of Turin University propose an operative technique of a new Y-shaped ileal neobladder reconstruction. The procedure is performed with the isolation of 40cm of ileum, 15-20cm before the ileocecal valve. The isolated segment is arranged in a Y-shape with two central segments of 14cm and two limbs of 6cm. The two central segments are brought together and detubularized, with a nonabsorbable mechanical stapler inserted through an opening made at the lowest point of the neobladder. The Y-neobladder is anastomosed to the urethra with five sutures in 2-0 polyglycolic acid, over a 22F silastic catheter. The ureters, resected above the crossing with the iliac vessels and spatulated anteriorly, are anastomosed to the dorsal aspect of the two limbs with 5.0 polyglycolic acid sutures, using the direct Nesbit technique. Ureteral stents, previously placed, are brought out through the distal portions of each chimney and then through the anterior abdominal wall. The two limbs are fixed to the psoas muscles [54].
- In relation to the use of colon for carrying out ONR we report Mansson's technique and the pouches described by the Mainz School and by Reddy respectively.

In particular Mansson proposes an orthotopic neobladder substitution using a right colon segment (Mansson pouch). The entire right colon and cecum are isolated, and a transverse ileocolonic anastomosis is performed to provide bowel continuity. The ileal stump at the ileocecal valve is closed with a running absorbable suture. The colonic segment is then opened along the anterior taenia, leaving the proximal 2 to 3 inches of cecum intact. An appendectomy is performed, and the ureters are implanted in an antireflux fashion within the reservoir. The colon is then folded in a Heineke-Mikulicz manner and closed with a running absorbable suture. The ureterocolonic anastomosis is then performed [55].

- The surgeons of Mainz Institute describe a surgical procedure with a segment of both ileum and right colon (Mainz pouch). A 10- to 15-cm segment of cecum, in continuity with a 20- to 30-cm segment of ileum, is isolated. An ascending ileocolostomy is performed. The entire segment of bowel is opened along the antimesenteric border, sacrificing the ileocecal valve. The bowel is placed in a W configuration, with the first limb of the W represented by cecum and the middle two limbs represented by ileum. The adjacent three limbs are sutured together with an absorbable suture, forming the posterior plate of the reservoir. At the cephalic portion of the cecum, tunneled ureterocolonic anastomosis is performed. A buttonhole incision is made in the cecum at the base of the reservoir, and a ureterocolonic anastomosis is performed. After this, the reservoir is closed side to side with absorbable suture [56].
- Reddy and Lange describe an orthotopic reconstruction with sigmoid segment (Reddy pouch). A 35-cm portion of descending colon and sigmoid is isolated and arranged in a U configuration. The medial taenia of the U is incised down to an area just short of the urethral anastomosis. The incised medial limbs of the U are then brought together with an absorbable suture. Ureteral implantation is performed in a tunnel antireflux fashion. A small button of colon is removed from the most dependent portion of the reservoir, and the urethroenteric anastomosis is performed. The reservoir is then closed side to side [57].

Complications

The patients may incur early and late complications as previously reported in non continent cutaneous diversions. The early post-operative complications may be identified as enterocolitis, acute pyelonephritis or lymphorrhoea. Therefore, chronic urinary retention, stricture of neobladder-urethra anastomosis, urosepsis secondary to bilateral hydronephrosis and neobladder stones are the main late complications for this form of surgery [58]. Finally the utilization of small bowel for urinary diversion may interfere with the physiological renal acid and salt regulation while osteoporosis and osteomalacia might theoretically develop from a persistent hypokalemic, hyperchloremic acidosis.

5. Conclusions

For many years the ileal conduit and the ureterosigmoidostomy were considered the primary choice for urinary diversion following cystectomy. In the last twenty years the surgical procedures of urinary tract reconstruction after bladder removal have evolved from simply urinary diversions and protecting the upper tract to creating a socially and psychologically more acceptable quality of life. Nevertheless at present there is no optimal surgical urinary diversion for all patients but surgical solutions that must be applied to each type of patient.


6. References

- [1] Ghulam Nabi, June D Cody, Norman Dublin, Samuel McClinton , James MO N'Dow, David E Neal, Robert Pickard, Sze M Yong. Urinary diversion and bladder reconstruction/replacement using intestinal segments for intractable incontinence or following cystectomy Cochrane Database of Systematic Reviews, 2009

- [2] Manoharan M and AM Nieder: "surgical management: cystectomy and urinary diversion" pp348-360 in *Urological Oncology*, VH Nargund, D Raghavan, HM Sandler Ed, Springer-Verlag London Ltd 2008.
- [3] Stein R, Wiesner C, Beetz R, Schwarz M, Thüroff JW. Urinary diversion in children and adolescents with neurogenic bladder: the Mainz experience. Part I: Bladder augmentation and bladder substitution--therapeutic algorithms. *Pediatr Nephrol*. 2005;20(7):920-5
- [4] Lewis DK, Morgan JR, Weston PM, Stephenson TP. The "clam": indications and complications. *British Journal of Urology* 1990;65:488-91.
- [5] Benchekroun A, Lachkar A, Soumana A, Farih MH, Belahnech Z, Marzouk M, Faik M. Urogenital tuberculosis. 80 cases. *Ann Urol*, 1998;32(2):89-94.
- [6] Bricker EM: Bladder substitution with isolated small intestine segments; a progress report. *Am Surg* 1952;18:654-664.
- [7] Dipen J. Parekh and S. Machele Donat Urinary Diversion: Options, Patient Selection, and Outcomes *Semin Oncol* 2007;34:98-109,
- [8] Turnbull RB Jr: Intestinal stomas. *Surg Clin North Am* 1958; 38:1361-1372,
- [9] Kock NG, Nilson AE, Nilsson LO, Norlen LJ, Philipson BM. Urinary diversion via a continent ileal reservoir: clinical results in 12 patients. *Journal of Urology* 1982;128(3):469-75
- [10] Sumfest JM, Burns MW, Mitchell ME. The Mitrofanoff principle in urinary reconstruction. *J Urol*. 1993;150, 1975-1878
- [11] Hautmann RE: Urinary diversion: Ileal conduit to neobladder. *J Urol* 2003; 169:834-842,
- [12] Henna as a durable preoperative skin marker. Henna as a durable preoperative skin marker. *World J Surg*. 2011;35(2):311-5
- [13] Bass EM, Del Pino A, Tan A, Pearl RK, Orsay CP, Abcarian H. Does preoperative stoma marking and education by the enterostomal therapist affect outcome? *Dis Colon Rectum*. 1997;40(4):440-2
- [14] Mills RD, Studer UE: Metabolic consequences of continent urinary diversion. *J Urol* 1999;161:1057-1066.
- [15] Mills RD, Studer UE: Metabolic consequences of continent urinary diversion. *J Urol* 1999; 161:1057-1066.
- [16] Koch MO, McDougal WS, Thompson CO: Mechanisms of solute transport following urinary diversion through intestinal segments: An experimental study with rats. *J Urol* 1991; 146:1390-1394.
- [17] Koch MO, McDougal WS, Flora MD: Urease and the acidosis of urinary intestinal diversion. *J Urol* 1991;146:458-462.
- [18] McDougal WS, Koch MO: Accurate determination of renal function in patients with intestinal urinary diversions. *J Urol* 1986; 135:1175-1178.
- [19] Kaveggia FF, Thompson JS, Schafer EC, et al: Hyperammonemic encephalopathy in urinary diversion with urea-splitting urinary tract infection. *Arch Intern Med* 1990;150:2389-2392.
- [20] Studer UE, Hautmann RE, Hohenfellner M, Mills RD, Okada Y, Rowland RG, et al. Indications for continent diversion after cystectomy and factors affecting long-term results. *Urol Oncol* 1998; 4:172-82

- [21] Steven K, Poulsen AL: The orthotopic Kock ileal neobladder: Functional results, urodynamic features, complications and survival in 166 men. *J Urol* 2000;164:288-295.
- [22] Elmajian DA, Stein JP, Esrig D, et al: The Kock ileal neobladder: Updated experience in 295 male patients. *J Urol* 1996; 156:920-925.
- [23] Colwell JC, Fichera A: Care of the obese patient with an ostomy. *J Wound Ostomy Continence Nurs* 2005; 32:378-383.
- [24] Gheiler EL, Wood DP Jr, Montie JE, et al: Orthotopic urinary diversion is a viable option in patients undergoing salvage cystoprostatectomy for recurrent prostate cancer after definitive radiation therapy. *Urology* 1997; 50:580-584.
- [25] Bochner BH, Figueroa AJ, Skinner EC, et al: Salvage radical cystoprostatectomy and orthotopic urinary diversion following radiation failure. *J Urol* 1998; 160:29-33.
- [26] Leuret T, Herve JM, Barre P, et al: Urethral recurrence of transitional cell carcinoma of the bladder. Predictive value of preoperative latero-montanal biopsies and urethral frozen sections during prostaticectomy. *Eur Urol* 1998; 33:170-174.
- [27] Chang SS, Alberts GL, Smith JA Jr, et al: Ileal conduit urinary diversion in patients with previous history of abdominal/pelvic irradiation. *World J Urol* 2004; 22:272-276.
- [28] Albertini JJ, Sujka SK, Helal MA, et al: Adenocarcinoma in a continent colonic urinary reservoir. *Urology* 1998; 51:499-500.
- [29] Pickard R: Tumour formation within intestinal segments transposed to the urinary tract. *World J Urol* 2004; 22:227-234.
- [30] Oneeka W, Vereb M, Libertino J. Noncontinent urinary diversion. *Urol Clin North Am.* 1997; 24: 735-743
- [31] Gburek B.M, Lieber M.M, Blute M.L. Comparison of studeer ileal neobladder and ileal conduit urinary diversion with respect to perioperative outcome and late complications. *J Urol.* 1998; 160: 721-723
- [32] Madersbacher S, Schmidt J, Eberle M.J, Thoeny H.C, Burkhard F, Hochreiter W, Studer E. Long-term outcome of ileal conduit diversion. *J Urol.* 2003; 169: 985-990.
- [33] Shimko M, Tollefson M, Umbreit E, Farmer S, Blute M, Frank I. Long-Term Complications of Conduit Urinary Diversion. *J Urol.* 2011; 185: 562-567
- [34] Bricker E. Bladder substitution after pelvic evisceration. *J Urol.* 2002; 167:1140-1145
- [35] Hautmann R. Urinary diversion: ileal conduit to neobladder. *J Urol.* 2003; 169:834-842.
- [36] Hall C, Koch M, McDouglas S. Metabolic Consequences of Urinary Diversion Through Intestinal Segment. *Urol Clin North Am.* 1991; 18: 725-735.
- [37] Carroll P et all. Urinary Diversion & Bladder Substitution. Smith's General Urology 17th edition. Mc GrawHill.
- [38] Downs T et all. Noncontinent and Continent Cutaneous Urinary Diversion. *Urologic Oncology* 2005. Elsevier.
- [39] Richie J. Sigmoid Conduit Urinary Diversion. *Urol Clin North Am.* 1986; 13: 225-231.
- [40] Beland G, Iaberge I. Cutaneous transureterostomy in children. *J Urol.* 1975; 114:588-590.
- [41] Rainwater L, Leary F, Rife C. Transureteroureterostomy with cutaneous ureterostomy: a 25-year experience. *J Urol.* 1991; 146:13-15.
- [42] Nieuwenhuijzen J, Vries R, Bex A, van der Poel H, Meinhardt W, Antonini N, Horenblas S. Urinary Diversion after Cystectomy: The Association of Clinical factors, Complications and Functional Results of Four Different Diversions. *Eur Urol.* 2008; 53:834-844.

- [43] Olofsson G, Fjalling M, Kilander A, Ung k, Jonsson O. Bile acid malabsorption after continent urinary diversion with an ileal reservoir. *J Urol*. 1998; 160:724-727
- [44] Terai A, Okada Y, Shichiri Y, Kakehi Y, Terachi T, Arai Y, Yoshida O. Vitamin B 12 Deficiency in patients with Urinary Intestinal Diversion. *Int J Urol*. 1997; 4:21-25.
- [45] Fitzgerald J, Malone M, Gaertner R, Zinman L. Stomal construction, complication, and reconstruction. *Urol Clin North Am*. 1997; 24: 729-733.
- [46] Campbell-Walsh. *Urology*. (2007) Saunders IX Edition, Volume I
- [47] Granberg CF et al. *Functional and oncological outcomes after orthotopic neobladder reconstruction in women*. *BJU Int* 2008; 102; 1551-1555
- [48] Barre PH et al. *Update on the Camey II procedure*. *World J Urol* 1996; 14(1): 27-8
- [49] Siracusano S. et Al. *Modified Ghoneim's technique using single serous-lined extramural orthotopic ileal W-bladder*. *Eur Urol* 2000; 38 : 313-5,
- [50] Studer UE et al. *Orthotopic ileal neobladder*. *BJU Int* (2004) 93(1): 183-93
- [51] Ghoneim MA et al. *An appliance-free, sphincter-controlled bladder substitute: the urethral Kock pouch*. *J Urol* 1987; 138(5): 1150-4
- [52] Novara G et al. *Functional results following vescica ileale Padovana (VIP) neobladder: midterm follow-up analysis with validated questionnaires*. *Eur Urol* 2010; 57(6): 1045-51
- [53] Stein JP et al. *The T pouch: an orthotopic ileal neobladder incorporating a serosal lined ileal antireflux technique*. *J Urol* 1998; 159(6): 1836-42
- [54] Fontana D et al. *Y-neobladder: an easy, fast, and reliable procedure*. *Urology*. 2004; 63(4): 699-703
- [55] Månsson W et al. *Continent urinary tract reconstruction - the Lund experience*. *BJU Int*. 2003; 92(3): 271-6
- [56] Thuroff JW et al. *The Mainz pouch (mixed augmentation ileum 'n zecum) for bladder augmentation and continent urinary diversion*. 1985. *Eur Urol* 2006; 50(6): 1142-50
- [57] Reddy PK. *The colonic neobladder*. *Urol Clin North Am* 1991; 18(4): 609-14
- [58] Wyczolkowski M et al. *Studer orthotopic ileal bladder substitute construction - surgical technique and complication management: one center and 12-year experience*. *Adv Med Sci* 2010; 55(2); 146-15



Bladder Cancer - From Basic Science to Robotic Surgery

Edited by Dr. Abdullah Canda

ISBN 978-953-307-839-7

Hard cover, 460 pages

Publisher InTech

Published online 01, February, 2012

Published in print edition February, 2012

This book is an invaluable source of knowledge on bladder cancer biology, epidemiology, biomarkers, prognostic factors, and clinical presentation and diagnosis. It is also rich with plenty of up-to-date information, in a well-organized and easy to use format, focusing on the treatment of bladder cancer including surgery, chemotherapy, radiation therapy, immunotherapy, and vaccine therapy. These chapters, written by the experts in their fields, include many interesting, demonstrative and colorful pictures, figures, illustrations and tables. Due to its practicality, this book is recommended reading to anyone interested in bladder cancer.

How to reference

In order to correctly reference this scholarly work, feel free to copy and paste the following:

S. Siracusano, S. Ciciliato, F. Visalli, N. Lampropoulou and L. Toffoli (2012). Current Trends in Urinary Diversion in Men, Bladder Cancer - From Basic Science to Robotic Surgery, Dr. Abdullah Canda (Ed.), ISBN: 978-953-307-839-7, InTech, Available from: <http://www.intechopen.com/books/bladder-cancer-from-basic-science-to-robotic-surgery/current-trends-in-urinary-diversion-in-men>

INTECH

open science | open minds

InTech Europe

University Campus STeP Ri
Slavka Krautzeka 83/A
51000 Rijeka, Croatia
Phone: +385 (51) 770 447
Fax: +385 (51) 686 166
www.intechopen.com

InTech China

Unit 405, Office Block, Hotel Equatorial Shanghai
No.65, Yan An Road (West), Shanghai, 200040, China
中国上海市延安西路65号上海国际贵都大饭店办公楼405单元
Phone: +86-21-62489820
Fax: +86-21-62489821

© 2012 The Author(s). Licensee IntechOpen. This is an open access article distributed under the terms of the [Creative Commons Attribution 3.0 License](#), which permits unrestricted use, distribution, and reproduction in any medium, provided the original work is properly cited.