

Multidisciplinary Ophthalmic Imaging

Progressive Loss of Retinal Ganglion Cells and Axons in Nonoptic Neuritis Eyes in Multiple Sclerosis: A Longitudinal Optical Coherence Tomography Study

Elizabeth C. Graham,¹ Yuyi You,^{1,2} Con Yiannikas,³ Raymond Garrick,⁴ John Parratt,³ Michael H. Barnett,^{5,6} and Alexander Klistorner^{1,2,6}

¹Save Sight Institute, Sydney Medical School, University of Sydney, Sydney, New South Wales, Australia

²Faculty of Medicine and Health Sciences, Macquarie University, Sydney, New South Wales, Australia

³Royal North Shore Hospital, Sydney, New South Wales, Australia

⁴St Vincent Hospital, Sydney, New South Wales, Australia

⁵Brain and Mind Research Institute, Sydney Medical School, University of Sydney, Sydney, New South Wales, Australia

⁶Sydney Neuroimaging Analysis Center, Sydney, New South Wales, Australia

Correspondence: Alexander Klistorner, Save Sight Institute, University of Sydney, 8 Macquarie Street, Sydney, NSW 2000, Australia; sasha.klistorner@sydney.edu.au.

Submitted: December 30, 2015

Accepted: February 25, 2016

Citation: Graham EC, You Y, Yiannikas C, et al. Progressive loss of retinal ganglion cells and axons in non-optic neuritis eyes in multiple sclerosis: a longitudinal optical coherence tomography study. *Invest Ophthalmol Vis Sci*. 2016;57:2311–2317. DOI:10.1167/iov.15-19047

PURPOSE. To examine the rate of retinal ganglion cell (RGC) layer and retinal nerve fiber layer (RNFL) changes in nonoptic neuritis (NON) eyes of relapsing remitting multiple sclerosis (RRMS) patients, and to find a specific imaging parameter useful for identifying disease progression.

METHODS. Forty-five consecutive RRMS patients and 20 age- and sex-matched healthy subjects were enrolled. All patients were followed up for 3 years with annual optical coherence tomography (OCT) scans, which included a peripapillary ring scan protocol for RNFL analysis and a macular radial star-like scan to obtain RGC/inner plexiform layer (IPL) thickness measures. Healthy controls were scanned twice, 3 years apart.

RESULTS. Retinal ganglion cell/inner plexiform layer and temporal RNFL (tRNFL) demonstrated highly significant thinning ($P < 0.01$), but all nasal segments and global RNFL (gRNFL) were not significantly different from normal controls. While receiver operating characteristics (ROC) analysis showed no advantage of RGC/IPL over tRNFL in cross-sectional detection of thinning, cut-off point based on fifth percentile in healthy controls demonstrated higher rate of abnormality for RGC/IPL. There was a significant progressive loss of RGC/IPL and tRNFL during the follow-up period. The largest thickness reduction was observed in tRNFL. ROC analysis demonstrated that tRNFL provided better sensitivity/specificity for detecting change over time than RGC/IPL (area under the curve [AUC] 0.78 vs. 0.52), which was confirmed by higher detection rate when 95th percentile of progression in healthy controls was used as a cut-off.

CONCLUSIONS. This study confirmed significant thinning of RGC/IPL and tRNFL in NON eyes of RRMS patients. Progressive losses were more apparent on tRNFL, while RGC/IPL showed less change over the follow-up period.

Keywords: retinal ganglion cell, optic neuritis, multiple sclerosis, optical coherence tomography

With the rapid development of new treatment modalities for multiple sclerosis (MS) there is a need to improve our ability to monitor disease progression over time. High resolution spectral-domain optical coherence tomography (OCT) has provided a means to both detect and monitor subtle changes in the retina and optic nerve in vivo.¹ It is recognized that significant retinal ganglion cell (RGC) and retinal nerve fiber layer (RNFL) loss occurs in MS patients following an episode of optic neuritis (ON).^{2,3} A reduction in RGC may be identified earlier due to transient edema in the acute stage of ON masking any early RNFL loss. However, the eventual magnitude of RNFL decline has been reported by some groups as more extensive than thinning of RGC layer (25% vs. 12%).⁴ In contrast, Garcia-Martin et al.⁵ reported that the RGC provided a better predictor of axonal damage based on the expanded disability status scale (EDSS) disability scores. Several recent

studies have also suggested that RGC layer thinning is a better measure of disease-related visual and general disability and brain atrophy^{6,7} and provides better sensitivity in monitoring longitudinal changes.⁸ Some of these studies, however are limited in the application of their findings as they have either used different time intervals, used lower resolution time-domain OCT scanners, analyzed both eyes or included ON eyes, did not have longitudinal controls or chose to analyses only global RNFL (gRNFL) thickness.^{7–10}

Significant thinning of RGC neuronal and axonal layers in non-ON (NON) eyes of MS patients is also now firmly established in cross-sectional studies.^{11,12} However, the results of longitudinal evaluation remains inconclusive.^{9,13,14}

Therefore, the aim of the current investigation was firstly to verify if progressive neuronal and axonal loss of RGC does occurs in NON eyes of relapsing remitting MS (RRMS) patients,



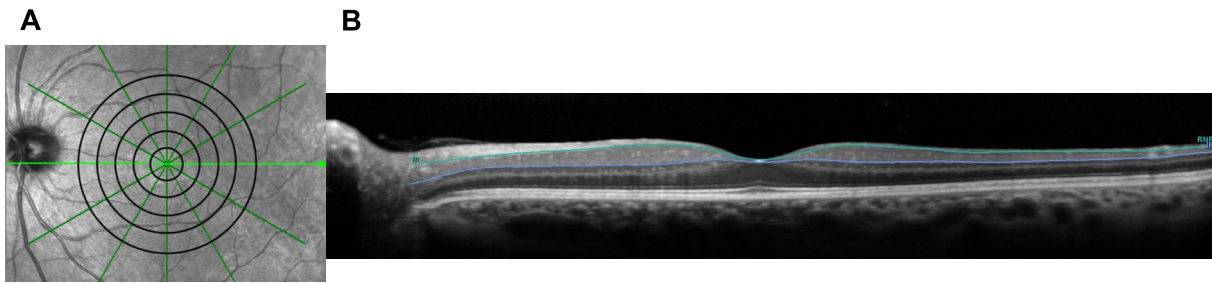


FIGURE 1. (A) Macula radial pattern protocol highlighting 12 radial sections around the central fovea to measure RGC/IPL thickness. Five points were measured on each side of the fovea for analysis. (B) Retinal cross-sectional image highlighting the RGC/IPL thickness. The two visible traces represent the borders of the RGC/IPL layer.

and secondly to determine which measure is the most sensitive to detect such changes. In addition to gRNFL thickness we also analyzed change in individual RNFL sectors and examined thinning of the retinal ganglion cell/inner plexiform layer (RGC/IPL) layer at different retinal eccentricities.

METHODS

Participants and Ethics

Consecutive relapsing-remitting MS (RRMS) patients with no history of clinical optic neuritis in at least one eye were enrolled. Patients with a history of other ocular or neurologic diseases that could affect the results, such as retinal and optic nerve disorders were excluded. All subjects were of Caucasian descent as previous studies have found that ethnicity effects mean RNFL thickness.^{15,16} In addition, 20 age, sex, and race-matched healthy subjects were also recruited as controls, and were examined at baseline and 3-year follow-up. All patients underwent annual OCT scans and attended follow-up appointments for 3 years. For MS patients, while both eyes were scanned only NON eyes were analyzed, and in patients with no history of ON in either eye, one eye was selected at random. Only one eye was randomly selected and scanned in the control group.

This study was approved by the Human Research Ethics Committee of the University of Sydney (Sydney, Australia) and written informed consent was obtained from all participants. The study adhered to the tenets of the Declaration of Helsinki.

OCT Scans and Imaging Analysis

Optical coherence tomography scans were performed using Spectralis HRA+OCT (Heidelberg Engineering, Heidelberg, Germany) as described previously.^{3,17} The macula radial pattern protocol was used, which provided six slices in a star-like pattern; the central fovea being the midpoint of each slice (Fig. 1A). This created 12 radial sections around the

central fovea, each 4.5 mm long and separated by 30° from each other. In total, 30° of visual angle (15° of eccentricity) were scanned. One hundred scans were averaged for each line scan to produce a resolution of 1536 pixels. For each OCT slice around the fovea, segmentation of the retinal layers was performed automatically using segmentation software. Retinal ganglion cell+IPL were analyzed together (Fig. 1B). All traces were inspected and manual corrections were made by one of the authors (EG), where necessary, for identifiable artifacts and clear segmentation errors. All manual corrections were checked by a second reviewer (AK). Both of the reviewers were blinded with respect to patients' identity and scan order. The thickness of RGC/IPL was calculated at five eccentricities (between 2° and 10°) along each radial line (Fig. 1A). A mean value of all points and at each eccentricity was calculated.

A peripapillary circular scan was also performed to obtain the overall global (gRNFL) thickness measures as well as the RNFL thickness for nasal (nRNFL) and temporal (tRNFL) quadrants, the papillomacular bundle (PMB) and superior-temporal (TS), superior-nasal (NS), inferior-nasal (NI), and inferior-temporal (TI) sectors (Fig. 2). The follow-up function was activated to ensure the RGC/IPL and RNFL thicknesses were obtained at exactly the same locations as the baseline scans.

Statistics

Statistical analysis was performed using SPSS 22.0 (SPSS, Chicago, IL, USA). Comparisons were made between MS patients and controls using unpaired Student's *t*-test as well as between baseline and follow-up measurements using repeated measures ANOVA. Sensitivity analysis was carried out using receiver operating characteristics (ROC) curves. Pearson correlation coefficient was used to measure statistical dependence between two numerical variables, while Pearson χ^2 coefficient was used for correlation of nominal variables such as sex. *P* less than 0.05 was considered statistically significant. The McNemar test was used to assess the difference between

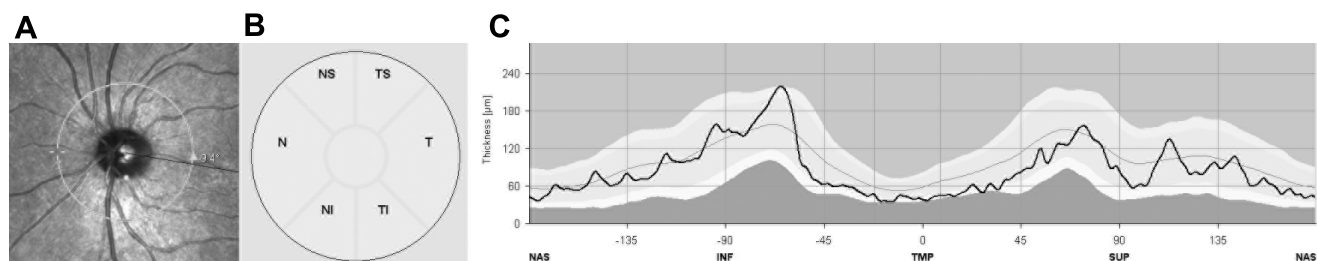


FIGURE 2. (A) A peripapillary circular scan used for RNFL measurement, (B) topography of RNFL sectors, and (C) RNFL profile in NON-eye of RRMS patient.

TABLE 1. Demographics and Clinical Features of Study Participants

	MS Patients	Controls	P Value
<i>n</i>	45	20	
Male	15	7	0.818*
Female	30	13	
Age, y	39.9 ± 9.9	39.3 ± 12.0	0.655†
Disease duration, y	4.3 ± 2.8	N/A	-
EDSS	1.2 ± 1.3	N/A	-
History of ON	24	N/A	

Values are mean ± SD. 42 MS patients were receiving disease-modifying treatments during the follow-up period, including interferon (*n* = 10), glatiramer acetate (*n* = 12), natalizumab (*n* = 5), fingolimod (*n* = 14) and dimethylfumarate (*n* = 1).

* McNemar test.

† Nonpaired *t*-test.

the proportion of males and females in patients and controls groups. Variability of different parameters was assessed by the coefficient of variation (CV), calculated as SD divided by the mean of the measured values.

RESULTS

Forty-five consecutive RRMS patients with no history of clinical optic neuritis in at least one eye and 20 age, sex, and race-matched healthy subjects were enrolled. Demographics and clinical features of study participants are presented in Table 1. Of MS patients, 93% (42/45) were receiving a disease-modifying therapy for the duration of the study.

Baseline Analysis

Retinal ganglion cell/IPL and sectoral/gRNFL thicknesses for the groups of MS patients as well as healthy controls are presented in Table 2. The nine measurement parameters showed different degrees of intersubject variability with RGC/IPL thickness exhibiting the lowest CV in both groups.

In comparison with controls the RGC/IPL and tRNFL demonstrated highly significant thinning at baseline, while reduction of TI, TS, and PMB thickness just reached significance. All nasal segments were not significantly different from normal controls, which no doubt contributed to gRNFL thinning being only at a borderline level (Table 2).

Despite the fact that tRNFL thickness was reduced by 11.8% (8.6 μm) while only a 7.2% (5.4 μm) reduction was observed for RGC/IPL, the level of significance between the two was similar, possibly due to the much higher intersubject variability of tRNFL thickness.

A similar sensitivity of tRNFL and RGC/IPL in detecting abnormally thin neuronal and axonal layers of RGC in RRMS

patients was also demonstrated by ROC analysis. Both parameters showed almost identical area under the curve (AUC 0.72 and 0.73, *P* = 0.007 and 0.003 for RGC/IPL and tRNFL, respectively; Fig. 3). Area under the curve for gRNFL was 0.67 (*P* = 0.034). When examining the shape of ROC curves, the sensitivity of RGC/IPL was slightly larger at the highest level of specificity, (although this difference is marginal and would need to be confirmed in a larger set of patients). However, it was noted that the RGC/IPL was thinner than the fifth percentile of normal controls in 21 patients (47%), while tRNFL was reduced only in 17 patients (38%).

Longitudinal Analysis

There was a significant reduction in RGC/IPL and tRNFL thickness during the follow-up period (Repeated measures ANOVA, Table 3). However, pairwise analysis for RGC/IPL demonstrated that the difference was only significant between baseline and year 3, while tRNFL was significant between all years. Temporal-inferior RNFL sector also demonstrated significant difference between all time-points, while temporal-superior and nasal-inferior sectors were significant between baseline and 1 year and baseline and 2 years for temporal-superior sector and baseline and 3 years for nasal-inferior sector.

Because fibers that subserved the central retina demonstrated the greatest thinning among all RNFL sectors in the cross-sectional study, only the temporal RNFL segments were analyzed further.

The reduction of tRNFL was 5.1% (3.04 μm), while RGC/IPL only lost 1.4% (0.96 μm), resulting in mean annual changes of -1.01 μm and -0.32 μm, respectively. This difference was confirmed by ROC analysis, which demonstrated a significant difference in area under the curve between two measures (AUC 0.52 and 0.78, *P* = 0.7 and <0.001 for RGC/IPL and tRNFL, respectively; Fig. 4). In accordance with this, a progressive rate of thinning exceeding the 95th percentile of change in healthy controls was observed in 24 patients based on tRNFL (53%) and only in 12 patients based on RGC/IPL (27%).

Detection of change of the RGC layer can potentially be affected by the RGC thickness profile as the cells are displaced from the foveal region and their density drops dramatically with retinal eccentricity.¹⁸ Therefore, we investigated RGC loss at five different eccentricities (between 2° and 10°) separately. Apart from most peripheral points (which showed minimal loss probably due to a very thin RGC layer), reduction of RGC layer thickness was relatively uniform across the examined retina at approximately 1 to 1.5 μm, which corresponded overall to approximately 2% of RCGL thinning (Table 4).

It has previously been suggested that patients with a history of ON may have more severe loss of RGC and their axons in the fellow eye when compared with patients with no history of

TABLE 2. Mean Thickness of Controls and MS Patients for Each of the Nine Measurement Parameters Chosen and Percentage of Thinning

	RGC/IPL, μm	RNFL, μm							
		NS	N	NI	TI	T	TS	G	PMB
Controls	74.2 ± 2.8	96.4 ± 17.0	71.6 ± 11.5	114.4 ± 24.8	149.7 ± 16.3	72.2 ± 8.9	138.5 ± 14.5	98.4 ± 8.0	55.2 ± 6.6
CV	3.8%	17.6%	16.1%	21.7%	10.9%	12.3%	10.5%	8.1%	12.0%
RRMS	68.8 ± 7.6	100.4 ± 22.4	70.6 ± 13.3	106.9 ± 21.4	139.1 ± 20.9	63.6 ± 11.7	128.6 ± 19.2	93.0 ± 10.8	50.1 ± 10.1
CV	11.0%	22.3%	18.8%	20.0%	15.0%	18.3%	14.9%	11.6%	20.2%
<i>P</i> value*	0.004	0.479	0.773	0.294	0.049	0.005	0.047	0.052	0.048
Thinning	7.2%	-4.2%	1.4%	6.5%	7.1%	11.8%	7.1%	5.4%	9.1%

Values are mean ± SD.

* Nonpaired *t*-test.

TABLE 3. Progressive Thinning of RGC/IPL and RNFL in MS Patients from Baseline to Year 3 Follow-up

	RGC/IPL, μm	tRNFL, μm	gRNFL, μm	nsRNFL, μm	nRNFL, μm	niRNFL, μm	tsRNFL, μm	tiRNFL, μm
Baseline	68.8 \pm 7.6	63.7 \pm 11.7	93.0 \pm 10.7	101.1 \pm 22.8	70.2 \pm 13.6	106.8 \pm 22.5	128.3 \pm 19.6	139.5 \pm 21.1
Follow-up								
1 y	68.7 \pm 7.8	62.5 \pm 12.1	92.0 \pm 10.5	100.7 \pm 22.9	69.4 \pm 14.9	106.9 \pm 24.9	127.6 \pm 18.1	137.3 \pm 21.1
2 y	68.2 \pm 7.4	61.7 \pm 12.0	91.3 \pm 10.4	100.2 \pm 22.1	68.7 \pm 13.2	105.9 \pm 22.4	126.9 \pm 18.2	136.5 \pm 21.0
3 y	67.9 \pm 7.9	60.6 \pm 12.0	90.6 \pm 10.6	101.7 \pm 22.5	69.0 \pm 13.9	103.3 \pm 21.9	126.3 \pm 20.2	135.2 \pm 21.1
P value*	0.002	<0.001	<0.001	0.3	0.051	0.01	0.01	<0.001
% loss	1.4	5.1	2.6	-0.5	1.7	3.0	1.6	3.1

Values are mean \pm SD.

* Repeated measures ANOVA.

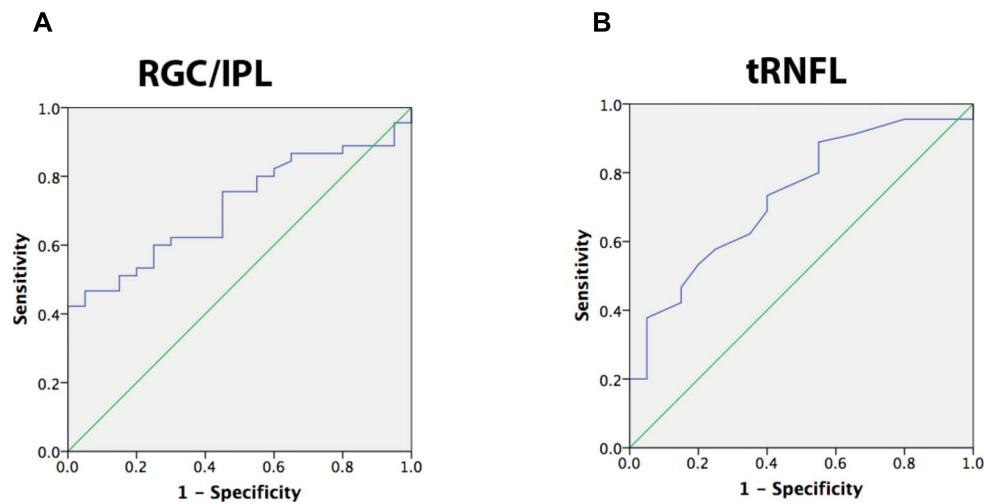


FIGURE 3. ROC analysis at baseline. (A) Baseline RGC/IPL thickness ROC curve. AUC = 0.72, asymptotic significance, -0.007. (B) Baseline tRNFL thickness ROC curve. AUC = 0.73, asymptotic significance, -0.003.

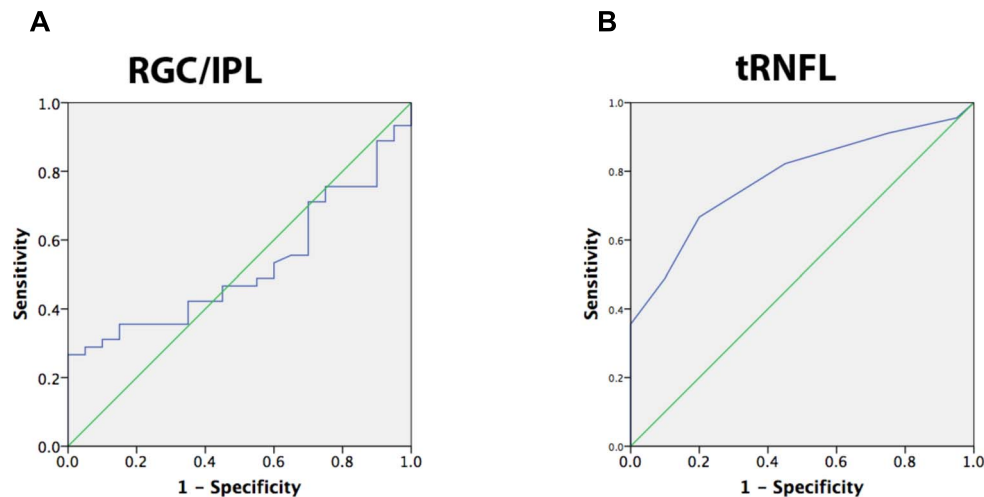


FIGURE 4. ROC curves for longitudinal change in thickness from baseline to 3 years follow-up. (A) Longitudinal RGC/IPL thickness ROC curve. AUC = 0.52, asymptotic significance, -0.7. (B) Longitudinal tRNFL thickness ROC curve. AUC = 0.78, asymptotic significance, <0.001.

TABLE 4. Mean Thickness, Loss (μm and %) of Thinning for Each Eccentricity for 5 Points on Either Side of the Fovea of RGC+IPL Radiating Outwards at 0.5-mm Intervals

	Eccentricity				
	1 (2°)	2 (4°)	3 (6°)	4 (8°)	5 (10°)
Baseline, μm	51.7 \pm 12.0	88.3 \pm 11.9	80.8 \pm 8.9	65.4 \pm 6.6	54.6 \pm 5.0
RGC/IPL loss in μm	1.01 \pm 2.70	1.54 \pm 3.57	1.41 \pm 2.99	1.33 \pm 2.44	0.26 \pm 0.26
RGC/IPL loss in %	2.0 \pm 5.2	1.7 \pm 4.0	1.7 \pm 4.7	2.0 \pm 3.7	0.5 \pm 0.5

Values are mean \pm SD.

ON (so called Phenotype effect).⁷ Therefore, we further separated patients into two groups based on the history of ON. While fellow eyes of ON patients did show a slightly higher rate of progression for all parameters, the difference was not statistically significant ($P > 0.05$ for all, Table 5). As expected, ON eyes demonstrated considerably thinner baseline thickness (54.5 \pm 9.8, 45.5 \pm 11.9, and 74.8 \pm 11.8 μm for GCL, tRNFL and gRNFL, respectively) and smaller loss during follow-up (-0.28 ± 1.3 (0.5%), -1.2 ± 2.3 (2.7%), and $-1.4 \pm 2.6 \mu\text{m}$ (1.9%) for GCL, tRNFL, and gRNFL, respectively).

There was no difference between males and females at baseline or between rates of progression for RGC/IPL, tRNFL, and gRNFL ($P > 0.05$ for all). None of the parameters demonstrated a significant relationship with duration of the disease ($P > 0.05$ for all).

DISCUSSION

Neuronal and axonal loss of RGC in MS patients with no previous history of optic neuritis is well documented. Significant thinning of neuroretina was demonstrated at very early stages of the disease and even before clinical onset of the MS.^{19–23} Several studies examining both RNFL and RGC layer thickness indicated a better sensitivity of the RGC layer in distinguishing MS patients from healthy controls and better correlation of RGC layer thickness with visual acuity and brain atrophy measures.^{8,10,11,21,24} However, in the majority of those studies only analysis of global RNFL was used,^{10,11,21} which may explain the disadvantage in axonal measurement. We have previously reported that in NON eyes of MS patients the tRNFL is reduced relatively more than gRNFL.²⁵

Progressive changes in axonal and neuronal structure of RGC in NON eyes of MS patients is, however, more difficult to establish. While some studies demonstrated thinning of RNFL and RGC layer,⁹ others found changes in one parameter, but not in the other,¹³ while other groups did not find measurable changes in either layer.²⁶ Several factors, such as variable (sometimes even within one study) follow-up period, different

resolution of the equipment used, methodological aspects of retinal segmentation and patients selection may account for this discordance. In addition, the RNFL/GCL parameter measured differs between studies. Thus, while the advantage of measuring progressive thinning of RGC layer over the change in RNFL in NON eyes of MS patients has recently been shown by Narayanan et al.¹⁰ and Ratchford et al.,¹³ both studies only analyzed global RNFL, which is not optimal to detect subtle loss of RGC axons.²⁵

Therefore, this study targeted the rate of RGC and RNFL change in NON eyes of RRMS patients followed annually over 3 years compared with a group of age, sex, and race-matched controls in order to find the best OCT parameter to both identify disease and monitor progression accurately. Cross-sectional evaluation of RNFL and RGC/IPL thickness confirmed both neuronal and axonal damage. Despite the larger relative thinning of tRNFL, measurement of RGC/IPL revealed a similar rate of abnormality in identifying MS patients when ROC analysis was applied. Using fifth percentile of thickness in normal controls as a cut-off point, more eyes demonstrated abnormality when RGC/IPL layer was used compare with RNFL (21 vs. 17).

It is also worth noting that not all RNFL segments were equally affected, the largest effect was seen in the temporal sector following by two surrounding (TI and TS) areas, while none of the nasal sectors demonstrated significant thinning. Because gRNFL is calculated based on averaged values of all sectors, this may explain low sensitivity of global RNFL, found in previous publications.

The longitudinal study, however, revealed that tRNFL performed considerably better than RGC/IPL in detecting progressive loss. Several potential reasons may account for this. The higher sensitivity of RGC/IPL thinning in previous cross-sectional studies may be related to intersubject differences. Intersubject variability is generally much tighter for RGC/IPL thickness measurements compared to RNFL. For example, in our cohort of healthy controls the coefficient of variability was more than four times larger for tRNFL thickness compared with RGC/IPL. A number of factors can affect the accuracy of

TABLE 5. Comparison Between Fellow Eyes of ON Patients and NON Eyes of MS Patients Without ON History at Baseline and Follow-up for RGC+IPL, tRNFL, and gRNFL.

	RGC/IPL			tRNFL			gRNFL		
	Fellow	NON	<i>P</i> Value	Fellow	NON	<i>P</i> Value	Fellow	NON	<i>P</i> Value
Baseline, μm	66.8 \pm 8.4	70.9 \pm 6.1	0.07†	61.9 \pm 11.5	65.5 \pm 11.9	0.30†	91.3 \pm 10.5	94.7 \pm 10.9	0.29†
Follow-up, μm	65.8 \pm 8.7	70.09 \pm 6.5	0.07†	58.5 \pm 12.0	62.9 \pm 11.9	0.23†	88.6 \pm 10.4	93.1 \pm 10.6	0.15†
<i>P</i> value	0.026*	0.038*	-	<0.001*	<0.001*	-	<0.001*	<0.001*	-
Thickness loss, %	1.6 \pm 3.3	1.2 \pm 2.5	0.62†	5.6 \pm 5.9	4.2 \pm 4.2	0.37†	3.0 \pm 2.9	1.6 \pm 2.1	0.08†
Thickness loss, $\mu\text{m}/\text{y}$	0.36 \pm 0.72	0.28 \pm 0.58	0.67†	1.13 \pm 1.20	0.89 \pm 0.92	0.46†	0.91 \pm 0.91	0.53 \pm 0.65	0.11†

Values are mean \pm SD.

* Paired *t*-test was used between baseline and follow-up.

† Nonpaired *t*-test was used between patient's groups.

peripapillary RNFL measurement and therefore, its intersubject variability including disc size.²⁷ In addition, temporal RNFL in particular is significantly affected by optic disc tilt (frequently associated with myopia)²⁸ and unless this is controlled for in the study design, a wider range of tRNFL variability may be expected. Race is another factor, which affects RNFL measurements.²⁹ Our study did not specifically adjust for disc size or myopia, but there were no evident outliers in disc size, no high myopes and all subjects were Caucasian.

Alternatively, there are several factors, which may contribute to the better performance of tRNFL in detecting progressive change. First, the effect of intersubject variability described above is eliminated by longitudinal analysis. Second, the ability of the combined RGC/IPL to detect change over time may be limited by a relative preservation of IPL, which contributes approximately 40% to 60% of the combined layer and masks, therefore, any reduction of RGC layer thickness. Because density of RGC peaks at approximately 2° to 4° of retinal eccentricity and then rapidly declines,³⁰ while IPL thickness remains relatively constant throughout the central retina we speculated that examination of combined RGC/IPL at more central retinal locations may show larger progressive thinning. However, a similar degree of loss (~2%) was found at all, except the most peripheral, eccentricities.

Third, small diameter axons comprising temporal RNFL bundle may be more susceptible to MS damage compare with large diameters fibers subserving more peripheral retina.³¹ Finally, preferential damage of tRNFL fibers may also be related to retrograde transsynaptic degeneration from optic radiation (OR) lesions, which are frequently seen in MS patients. More than 50% of visual cortex subserves the central 10° of the retina.³² This over-representation of the central visual field is largely formed at the retinal level and preserved in the OR.³³ Assuming a uniform distribution of MS lesions within the OR, it is likely that OR fibers subserving central vision are damaged more frequently, which in turn may cause more extensive thinning of tRNFL fibers.²⁵ Taken together, those factors may help to explain better performance of the tRNFL in analyzing progressive loss.

Recent studies have demonstrated a topographic location of retinal ganglion cell death is associated with clock-hour location of pRNFL loss in glaucoma patients.³⁴ The RGC protocol of the Spectralis system used in this study, however, did not allow us to perform a sectoral analysis similar to that used by the Cirrus OCT (Carl Zeiss Meditec AG, Jena, Germany). As a result there is a lack of ability to perform direct comparisons with other RGC studies, representing a limitation of the study. However, an advantage of the technique employed was that we able to determine the rate of change with eccentricity from the fovea did not vary significantly, and this has not previously been reported.

Because we included only patients with relapsing-remitting disease, our results cannot be extrapolated to other types of MS or to patients with very advanced disease. Progressive types may cause higher rates of atrophy of the retinal layers and previous studies have shown RNFL thickness varies with disease subtype.³⁵ It has to be noted, however, that none of the parameters correlated with disease duration.

Most of the patients in this study were on disease-modifying therapies, and it is, therefore, possible that our results may underestimate true rates of retinal atrophy, which might be higher in an untreated study cohort. There was also some variability in terms of the types of disease-modifying therapies patients were undergoing, not only at their baseline visit, but also for the duration of the study. This variability in disease-modifying therapies throughout the study duration prevented assessment of the effects of these treatments on our results. Future studies including more homogeneously

treated subgroups would possibly allow a more accurate calculation of the effects of these therapies on the rate of retinal atrophy.

In conclusion, our study demonstrated that RGC/IPL thickness and RNFL both indicate neuroretinal damage in a cross-sectional analysis in NON eyes of RRMS patients, while tRNFL showed the best sensitivity in detecting progressive thinning. The findings of this study should assist both clinicians managing the disease and in the design of clinical trials where axonal degeneration and neuronal loss in MS patients are monitored and used as biomarkers.

Acknowledgments

Supported by Save Neuron grant (Novartis; Sydney, NSW, Australia), the Sydney Eye Hospital Foundation (Sydney, NSW, Australia) and a grant from the National MS Society (New York City, NY, USA).

Disclosure: **E.C. Graham**, None; **Y. You**, None; **C. Yiannikas**, None; **R. Garrick**, None; **J. Parratt**, None; **M.H. Barnett**, None; **A. Klistorner**, None

References

- Mistlberger A, Liebmann JM, Greenfield DS, et al. Heidelberg retina tomography and optical coherence tomography in normal, ocular-hypertensive, and glaucomatous eyes. *Ophthalmology*. 1999;106:2027-2032.
- Kupersmith MJ, Garvin MK, Wang JK, Durbin M, Kardon R. Retinal ganglion cell layer thinning within one month of presentation for optic neuritis. *Mult Scler*. 2016;22:641-648.
- Sriram P, Graham SL, Wang C, Yiannikas C, Garrick R, Klistorner A. Transsynaptic retinal degeneration in optic neuropathies: optical coherence tomography study. *Invest Ophthalmol Vis Sci*. 2012;53:1271-1275.
- Al-Louzi OA, Bhargava P, Newsome SD, et al. Outer retinal changes following acute optic neuritis. *Mult Scler*. 2016;22:362-372.
- Garcia-Martin E, Pueyo V, Martin J, et al. Progressive changes in the retinal nerve fiber layer in patients with multiple sclerosis. *Eur J Ophthalmol*. 2010;20:167-173.
- Saidha S, Syc S, Ibrahim MA, et al. Primary retinal pathology in multiple sclerosis as detected by optical coherence tomography. *Brain*. 2011;134:518-533.
- Saidha S, Al-Louzi O, Ratchford JN, et al. Optical coherence tomography reflects brain atrophy in multiple sclerosis: a four-year study. *Ann Neurol*. 2015;78:801-813.
- González-López JJ, Rebolleda G, Leal M, et al. Comparative diagnostic accuracy of ganglion cell-inner plexiform and retinal nerve fiber layer thickness measures by Cirrus and Spectralis optical coherence tomography in relapsing-remitting multiple sclerosis. *Biomed Res Int*. 2014;2014:128517-128517.
- Talman LS, Bisker ER, Sackel BS, et al. Longitudinal study of vision and retinal nerve fiber layer thickness in multiple sclerosis. *Ann Neurol*. 2010;67:749-760.
- Narayanan D, Cheng H, Bonem KN, Saenz R, Tang RA, Frishman LJ. Tracking changes over time in retinal nerve fiber layer and ganglion cell-inner plexiform layer thickness in multiple sclerosis. *Mult Scler*. 2014;20:1331-1341.
- Walter SD, Ishikawa H, Galetta KM, et al. Ganglion cell loss in relation to visual disability in multiple sclerosis. *Ophthalmology*. 2013;119:1250-1257.
- Petzold A, de Boer JF, Schippling S, et al. Optical coherence tomography in multiple sclerosis: a systematic review and meta-analysis. *Lancet Neurol*. 2010;9:921-932.

13. Ratchford JN, Saidha S, Sotirchos ES, et al. Active MS is associated with accelerated retinal ganglion cell/inner plexiform layer thinning. *Neurology*. 2013;80:47-54.
14. Serbecic N, Beutelspacher SC, Geitzenauer W, et al. RNFL thickness in MS-associated acute optic neuritis using SD-OCT: critical interpretation and limitations. *Acta Ophthalmol*. 2011;89:e451-e460.
15. Bourne RRA. Ethnicity and ocular imaging Cambridge Ophthalmological Symposium. *Eye*. 2010;25:297-300.
16. Paunescu LA, Schuman JS, Price LL, Stark L. Variation of nerve fiber layer thickness measurements with age and ethnicity by scanning laser polarimetry. *Invest Ophthalmol Visual Sci*. 2004;40:2520-2527.
17. Kaushik M, Wang CY, Barnett MH, et al. Inner nuclear layer thickening is inversely proportional to retinal ganglion cell loss in optic neuritis. *PLoS One*. 2013;8:e78341.
18. Watson AB. A formula for human retinal ganglion cell receptive field density as a function of visual field location. *J Vis*. 2014;14(7):pii:15.
19. Oreja-Guevara C, Noval S, Alvarez-Linera J, et al. Clinically isolated syndromes suggestive of multiple sclerosis: an optical coherence tomography study. *PLoS One*. 2012;7:e33907.
20. Gelfand JM, Goodin DS, Boscardin WJ, Nolan R, Cuneo R, Green AJ. Retinal axonal loss begins early in the course of multiple sclerosis and is similar between progressive phenotypes. *PLoS One*. 2012;7:e36847-e36847.
21. Oberwahrenbrock T, Ringelstein M, Jentschke S, et al. Retinal ganglion cell and inner plexiform layer thinning in clinically isolated syndrome. *Mult Scler*. 2013;19:1887-1895.
22. Knier B, Berthele A, Buck D, et al. Optical coherence tomography indicates disease activity prior to clinical onset of central nervous system demyelination [published online ahead of print September 11, 2015]. *Mult Scler*. doi:10.1177/1352458515604496.
23. Maghzi AH, Graves J, Revirajan N, et al. Retinal axonal loss in very early stages of multiple sclerosis. *Eur J Neurol*. 2015;22:1138-1141.
24. Saidha S, Syc SB, Durbin MK, et al. Visual dysfunction in multiple sclerosis correlates better with optical coherence tomography derived estimates of macular ganglion cell layer thickness than peripapillary retinal nerve fiber layer thickness. *Mult Scler*. 2011;17:1449-1463.
25. Klistorner A, Sriram P, Vootakuru N, et al. Axonal loss of retinal neurons in multiple sclerosis associated with optic radiation lesions. *Neurology*. 2014;82:2165-2172.
26. Serbecic N, Aboul-Enein F, Beutelspacher SC, et al. High resolution spectral domain optical coherence tomography (SD-OCT) in multiple sclerosis: the first follow up study over two years. *PLoS One*. 2011;6:e19843-e19843.
27. Moghimi S, Hosseini H, Riddle J, et al. Measurement of optic disc size and rim area with spectral-domain OCT and scanning laser ophthalmoscopy. *Invest Ophthalmol Vis Sci*. 2012;53:4519-4530.
28. Hwang YH, Yoo C, Kim YY. Myopic optic disc tilt and the characteristics of peripapillary retinal nerve fiber layer thickness measured by spectral-domain optical coherence tomography. *J Glaucoma*. 2012;21:260-265.
29. Alasil T, Wang K, Keane PA, et al. Analysis of normal retinal nerve fiber layer thickness by age, sex, and race using spectral domain optical coherence tomography. *J Glaucoma*. 2013;22:532-541.
30. Curcio CA, Allen KA. Topography of ganglion cells in human retina. *J Comp Neurol*. 1990;300:5-25.
31. Evangelou N, Konz D, Esiri MM, Smith S, Palace J, Matthews PM. Size-selective neuronal changes in the anterior optic pathways suggest a differential susceptibility to injury in multiple sclerosis. *Brain*. 2001;124:1813-1820.
32. Horton JC, Hoyt WF. Quadrantic visual field defect. A hallmark of lesions in extra-striate (V2/V3) cortex. *Brain*. 1991;114:1703-1718.
33. Chaplin TA, Yu HH, Rosa MG. Representation of the visual field in the primary visual area of the marmoset monkey: magnification factors, point-image size, and proportionality to retinal ganglion cell density. *J Comp Neurol*. 2013;521:1001-1019.
34. Kim KE, Park KH, Yoo BW, Jeoung JW, Kim DM, Kim HC. Topographic localization of macular retinal ganglion cell loss associated with localized peripapillary retinal nerve fiber layer defect. *Invest Ophthalmol Vis Sci*. 2014;55:3501-3508.
35. Costello F, Hodge W, Pan YI, Eggenberger E, Freedman MS. Using retinal architecture to help characterize multiple sclerosis patients. *Can J Ophthalmol*. 2010;45:520-526.