

Progressive atrophy of retinal pigment epithelium after trypan-blue-assisted ILM peeling for macular hole surgery

Sachin Jain¹, Kamal Kishore^{1,2}, Yog Raj Sharma³

We report a case of progressive atrophy of the retinal pigment epithelium (RPE) after trypan-blue-assisted peeling of internal limiting membrane (ILM) for macular hole surgery. A 68-year-old Caucasian female underwent a 20-g pars plana vitrectomy for a chronic stage-3 macular hole. The ILM was stained with 0.06% trypan blue (VisionBlue™, DORC Netherlands) for 2 min after fluid air exchange. Dye was reapplied for another 2 min due to poor staining. The ILM was completely removed around the macular hole with forceps. RPE atrophy was noticed at the edge of the hole 1 month after surgery. It progressively increased in intensity and enlarged over 2 years. Her final visual acuity was counting fingers, significantly worse compared to her presenting visual acuity of 20/200. Progressive atrophy of RPE in our patient was most likely due to the toxicity of trypan blue. Reapplication of the dye may increase the likelihood of toxicity.

Key words: Internal limiting membrane, macular hole, retinal pigment epithelial atrophy, trypan blue, vital dyes

Vital dyes such as indocyanine green, trypan blue (TB), and brilliant blue green are commonly employed during macular hole surgery to stain the internal limiting membrane (ILM). TB provides a faint staining of the ILM and has been reported to be safe in some clinical studies.^[1] However, experimental studies^[2-4] and electron microscopy of excised ILM specimens after TB staining^[5] seem to suggest possible toxicity of TB to the retinal tissue. Here, we present a patient who developed progressive atrophy of the retinal pigment epithelium after TB-assisted ILM peeling for macular hole surgery.

Case Report

A 68-year-old phakic Caucasian female presented with decreased central vision in the left eye for the past 18 months secondary to a large macular hole. She denied any prior history of trauma,

high myopia, or any other ocular problems. Her presenting visual acuity was 20/200. A full-thickness stage-3 macular hole measuring 680µ in diameter on color photographs (OIS WinStation™ software, Ophthalmic Imaging Systems, Sacramento, CA) was diagnosed. [Fig. 1a]. An intravenous fluorescein angiogram showed mild hyperfluorescence at the base [Fig. 1b], but no obvious atrophy of the retinal pigment epithelium was observed on clinical photographs. The right eye was 20/20, with normal appearing macula. A 20-g pars plana vitrectomy was performed using Accurus machine (Alcon, Fort Worth, TX) under local anesthesia. Halogen illumination at 100% intensity built into the Accurus was used for endoillumination. Posterior vitreous detachment was created by suction with the cutter nasal to the nerve and was confirmed by a visible Weiss ring in the vitreous cavity. After completion of vitrectomy, fluid air exchange was performed and 0.2 ml 0.06% TB (VisionBlue™, DORC Netherlands) was injected over the macular area. The sclerotomy sites were plugged and the microscope light was turned off during the staining period. After waiting for 2 min, air fluid exchange was performed. Process was repeated and TB was left for another 2 min because of poor staining of the ILM. Microforceps were used to remove the ILM completely for about 2 disk diameters around the hole. No subretinal TB was observed beyond the macular hole. Endoilluminator was kept as far away from the macular hole as possible during the ILM peel. Fluid air exchange was performed with a silicone-tipped cannula. Air pressure was set at 35 mm Hg during all fluid air exchanges. No attempt was made to drain through or near the macular hole at any time. Fourteen percent C₃F₈-air mixture was used for tamponade followed by face-down position for 2 weeks.

A ring-shaped area of hypopigmentation corresponding to the edge of the macular hole was noted one month after surgery [Fig. 2]. Seven months after surgery, atrophy of the RPE involved the entire base and edge of the macular hole [Fig. 3a]. Spectral domain optical coherence tomography (OCT) showed closed macular hole, defect in inner segment/outer segment junction, and increased transmission of light consistent with RPE atrophy [Fig. 3b]. Two years after surgery, area of RPE atrophy had increased in intensity and also showed slight enlargement in size to 790µ in diameter [Fig. 4a], and spectral domain OCT demonstrated closed macular hole, defect in IS/OS junction, further attenuation of outer retinal layers, and increased transmission of light [Fig. 4b]. Her visual acuity was 20/200 3 months after surgery, but declined to counting fingers 2 years postoperatively with no improvement with refraction. She developed moderate nuclear sclerosis, which was not believed to be responsible for such a profound loss of vision. The right eye has remained 20/20 without any RPE atrophy, or changes of age-related macular degeneration. She denied history of chloroquine or hydroxychloroquine intake.

Discussion

RPE atrophy, first noted at the edge of the hole 1 month postoperatively, gradually became more intense and enlarged over a 2-year period with progressive decline in visual acuity to counting fingers. The lesion was not typical of facet or phototoxicity lesions observed after macular hole surgery.^[6] The final appearance of the macula was very similar to that seen after mechanical debridement of RPE.^[7] We believe that progressive RPE atrophy most likely was due to toxicity of TB to the RPE. Recent evidence suggests that TB might be toxic to the RPE cells, particularly with chronic exposure. Concentration

Access this article online	
Quick Response Code:	Website: www.ijjo.in

¹Illinois Retina Institute, Peoria, IL, U.S.A., ²Department of Surgery, University of Illinois College of Medicine-Peoria Campus, Peoria, IL, U.S.A., ³Department of Vitreo-retinal Surgery, Dr. R.P. Center for Ophthalmic Sciences, Ansari Nagar, New Delhi, India

Correspondence to: Dr. Kamal Kishore, 5016 N University, Suite 106, Peoria, IL 61614, USA., E-mail: kishorekvn@comcast.net

Manuscript received: 05.08.11; **Revision accepted:** 12.09.11

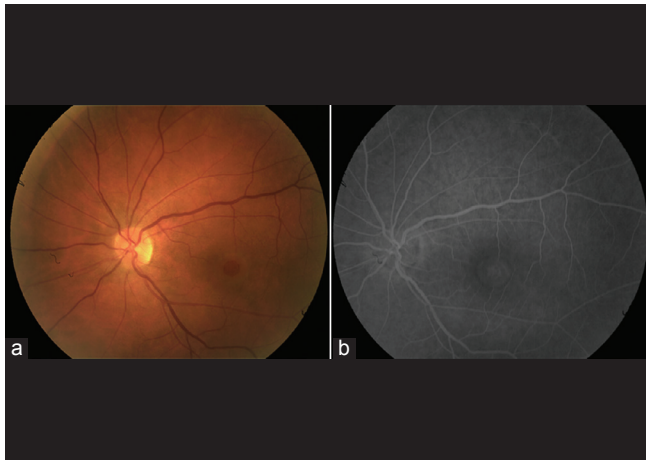


Figure 1: (a) Stage-3 macular hole measuring 680 μ in diameter. (b) Midphase fluorescein angiogram of the left eye at presentation showing mild hyperfluorescence at the base of the hole

and time-dependent cytotoxicity to cultured human RPE cells has been demonstrated,^[2,3] including increased expression of p53 gene that triggers apoptosis.^[3]

In rabbit eyes, subretinal injection of 0.15% TB led to RPE atrophy at injection site. Progressive damage starting with photoreceptor outer segments was observed 6 h after subretinal injection, involving outer nuclear layer at 24 h, and RPE by 14 days.^[4]

The Vitrectomy for Macular Hole Study Group demonstrated that eyes with macular holes larger than 475 μ m were two times more likely to develop RPE changes compared to those with smaller holes.^[6] The macular hole diameter in our patient was 680 μ m, suggesting the possibility that damage to the RPE was accentuated by the large size of the macular hole. The relatively larger size of the hole may allow TB to come in contact with a larger area of RPE.

Our patient required a second 2 min application of the dye.

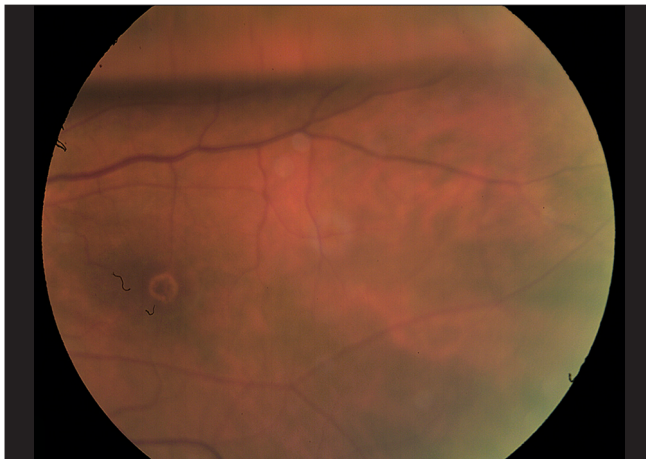

Figure 2: One month post-op: RPE atrophy seen as a ring-shaped area of hypopigmentation corresponding to the edge of the macular hole

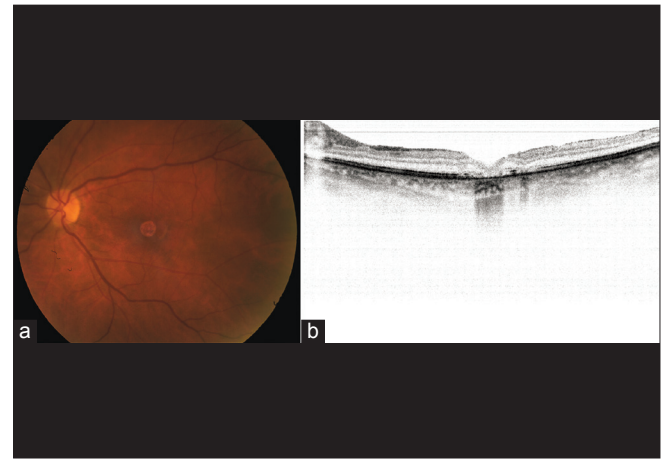


Figure 3: (a) Seven months post-op: Atrophy of the RPE has extended to include the entire base and edge of the macular hole. (b) Spectral domain OCT at 7 months showing a closed macular hole, interruption of inner segment/outer segment junction, and RPE atrophy

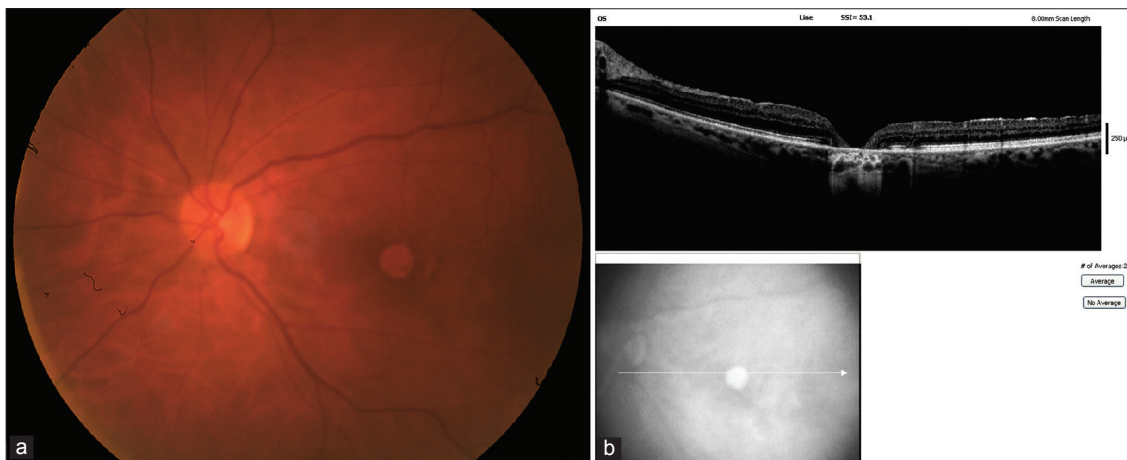


Figure 4: Two years post-op: (a) Area of RPE atrophy has become more intense and increased in size to 790 μ m diameter. (b) Spectral domain OCT showing a closed macular hole, defect in inner segment/outer segment junction, further attenuation of outer retinal layers compared to Figure 3B, and increased transmission of light, consistent with atrophy of the RPE

Reapplication of TB could potentially increase the likelihood of toxicity. Lesnik Oberstein and de Smet reapplied heavy TB, prepared by isovolumetrically mixing 10% glucose with 0.15% TB without any toxicity.^[8] However, they injected TB into a fluid-filled eye, while we injected TB into an air-filled eye, as recommended by the manufacturer and performed in most other studies.

Two recent case reports described RPE atrophy from the use of TB in macular hole surgery. In both cases, RPE atrophy was observed within a few weeks after surgery and was nonprogressive.^[9,10] We are not aware of any report of progressive RPE atrophy following the use of TB.

Our case report suggests that TB has the potential risk to cause retinal damage and caution should be exercised while using it for vitreo-retinal surgery. We prefer to peel the ILM without any vital dye in our cases.

References

1. Teba FA, Mohr A, Eckardt C, Wong D, Kusaka S, Joondeph BC, *et al.* Trypan blue staining in vitreoretinal surgery. *Ophthalmology* 2003;110:2409-12.
2. Kodjikian L, Richter T, Halberstadt M, Beby F, Flueckiger F, Boehnke M, *et al.* Toxic effects of indocyanine green, infracyanine green, and trypan blue on the human retinal pigmented epithelium. *Graefes Arch Clin Exp Ophthalmol* 2005;243: 917-25.
3. Kwok AK, Yeung CK, Lai TY, Chan KP, Pang CP. Effects of trypan blue on cell viability and gene expression in human retinal pigment epithelial cells. *Br J Ophthalmol* 2004;88:1590-4.
4. Penha FM, Maia M, Eid Farah M, Principe AH, Freymüller EH, Maia A, *et al.* Effects of subretinal injections of indocyanine green, trypan blue, and glucose in rabbit eyes. *Ophthalmology* 2007;114:899-908.
5. Schumann RG, Gandorfer A, Priglinger SG, Kampik A, Haritoglou C. Vital dyes for macular surgery: A comparative electron microscopy study of the internal limiting membrane. *Retina* 2009;29:669-76.
6. Banker AS, Freeman WR, Kim JW, Munguia D, Azen SP. Vision-threatening complications of surgery for full-thickness macular holes. Vitrectomy for macular hole study group. *Ophthalmology* 1997;104:1442-52; discussion 1452-3.
7. Nao-i N, Sawada A. Effect of debridement of the retinal pigment epithelium in full-thickness macular hole surgery. *Acta Ophthalmol Scand* 1998;76:234-7.
8. Lesnik Oberstein SY, de Smet MD. Use of heavy trypan blue in macular hole surgery. *Eye (Lond)* 2010;24:1177-81.
9. Saeed MU, Heimann H. Atrophy of the retinal pigment epithelium following vitrectomy with trypan blue. *Int Ophthalmol* 2009;29:239-41.
10. Rishi P, Rishi E, Kothari A. Retinal pigment epithelial changes after trypan blue-assisted internal limiting membrane peeling for idiopathic macular hole. *Oman J Ophthalmol* 2011;4:37-8.

Cite this article as: Citation will be included before issue gets online***

Source of Support: Nil, **Conflict of Interest:** None declared.