



The morbidity of inguinal lymphadenectomy can be minimized by early diagnosis of metastasis, the use of optimal operative techniques, and prophylaxis for deep venous thromboembolism and lymphedema.

Catherine Hickson. *Apples in Venetian Red*. Oil on Belgian linen, 60 cm × 90 cm.

Limiting the Morbidity of Inguinal Lymphadenectomy for Metastatic Melanoma

Amod A. Sarnaik, MD, Christopher A. Puleo, PA-C, Jonathan S. Zager, MD, FACS and Vernon K. Sondak, MD

Background: Surgery is currently the primary treatment modality for metastatic melanoma involving the inguinal lymph nodes. However, inguinal lymph node dissections are associated with substantial morbidity including infection, wound dehiscence, lymphedema, seroma, and deep venous thromboembolism (DVT). Improved understanding is needed regarding the factors predisposing patients to complications and the operative and perioperative maneuvers that can decrease morbidity.

Methods: We reviewed recently published literature regarding the morbidity associated with lymphadenectomy in the treatment of inguinal metastatic melanoma. Where available, emphasis was focused on appropriately designed studies aimed at reducing treatment-related morbidity. When appropriate, the review was supplemented by our personal experience.

Results: Strategies to limit treatment-related morbidity involve optimizing the preoperative assessment, operative technique, and postoperative care. Establishing the diagnosis of nodal metastasis early using minimally invasive techniques is critical to reduce subsequent perioperative complications. Morbidity is higher for inguinal compared to cervical or axillary lymphadenectomy, and many variations in extent of inguinal lymphadenectomy and operative technique have been reported. The lack of definitive trials has led to controversy regarding surgical technique such as indications for pelvic lymphadenectomy ("deep" node dissection), saphenous vein preservation, and sartorius transposition. In the postoperative period, the use of DVT and lymphedema prophylaxis should be considered to potentially improve patient outcomes.

Conclusions: While the morbidity of inguinal lymphadenectomy can be substantial, several straightforward pre- and postoperative measures can be instituted to limit morbidity. Controversy persists regarding the indications for and benefit of pelvic lymphadenectomy, saphenous vein preservation, and sartorius muscle transposition. A multi-institutional trial is currently in progress to investigate the safety of avoiding lymphadenectomy in patients with microscopic metastases in the sentinel node.

From the Department of Cutaneous Oncology (AAS, CAP, JSZ, VKS), H. Lee Moffitt Cancer Center & Research Institute, and the Departments of Oncologic Sciences (AAS, JSZ, VKS), and Surgery (VKS), University of South Florida College of Medicine, Tampa, Florida.

Submitted July 9, 2008; accepted October 13, 2008.

Address correspondence to Vernon K. Sondak, MD, Cutaneous Oncology Program, Moffitt Cancer Center, 12902 Magnolia Drive, Tampa,

FL 33612. E-mail: vernon.sondak@moffitt.org

Dr Sondak is a consultant for Schering-Plough, Pfizer, BMS/Medarex, Bayer/Onyx, and Glaxo Smith-Kline/Synta. Dr Zager receives honoraria from and is on the speakers bureau for Eisai and Pfizer. He is also a consultant for Perfusion Sciences. The other authors report no significant relationship with the companies/organizations whose products or services may be referenced in this article.

Introduction

Regional lymph node metastases from primary melanoma commonly involve the cervical, axillary, or inguinal node basins, depending on the site of the primary lesion. When lymphatic metastasis occurs, surgery is the primary treatment modality and is curative in a quarter to a half of all melanoma patients, depending on whether the nodal metastases are diagnosed clinically (palpable or macroscopic metastases) or histologically in clinically negative nodes (micrometastases). Of the three nodal basins, resection of inguinal lymph node metastasis is associated with the greatest operative morbidity, in both frequency and severity. Potential complications include infection, wound dehiscence, lymphedema, seroma/hematoma, and venous thromboembolism.

Several strategies have been developed to minimize the morbidity associated with inguinal lymphadenectomy and are discussed in this review. Unfortunately, prospective, randomized trials to validate these strategies are largely lacking. One ongoing trial is examining the potential to omit lymphadenectomy in the setting of micrometastatic disease as the ultimate step of limiting morbidity. Until the results of this trial are known, inguinal node dissection remains the treatment of choice for all patients with micro- and macroscopic nodal metastases and no evidence of distant disease. Surgeons performing inguinal node dissection need to be familiar not only with the indications for the procedure — including when pelvic or “deep” node dissection should be performed — but also with the available options to limit the morbidity associated with inguinal lymphadenectomy.

Establishing the Diagnosis of Regional Inguinal Disease

Prompt diagnosis of inguinal metastasis by the least invasive means possible is an important initial step in reducing subsequent operative morbidity. Diagnosing nodal disease when the disease is microscopic using sentinel lymph node biopsy has significant benefit in reducing operative morbidity. Sabel et al¹ recently reviewed the institutional experience at the University of Michigan involving 212 patients who underwent inguinal node dissection for microscopic (sentinel node positive) or macroscopic (palpable) nodal metastases from melanoma. The authors observed a significantly lower wound complication rate in the sentinel node-positive group compared to patients presenting with clinically palpable nodal disease (14% vs 28%, $P = .019$). Importantly, they noted a significantly lower lymphedema rate in the sentinel node-positive group compared to patients undergoing the same procedure for palpable nodal disease (24% vs 41%, $P = .025$). The authors postulate that the higher morbidity in the palpable node group may be related to creation of thinner flaps and the use of longer incisions with increased tension on wound closure.

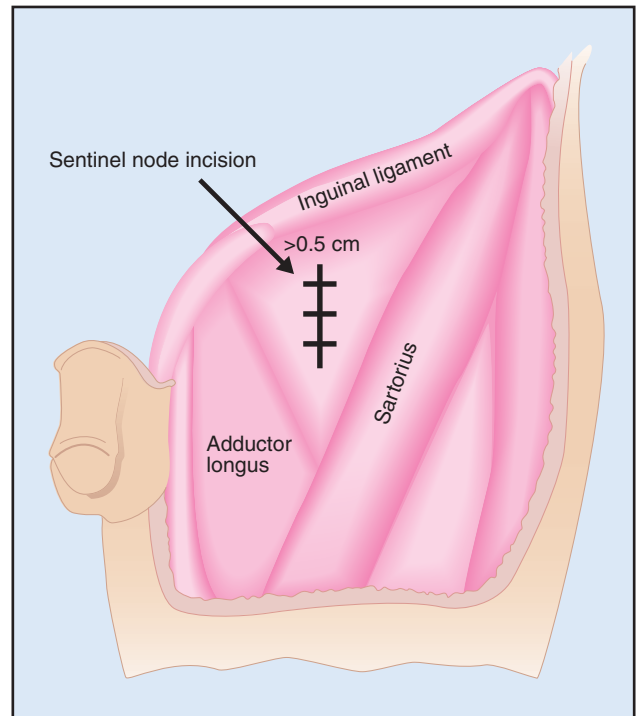


Fig 1A. — Schematic representation of a vertically oriented sentinel node biopsy incision in the situation where the node is mapped below the inguinal ligament. Adapted from Gray, Henry. *Anatomy of the Human Body*. Philadelphia, PA: Lea & Febiger, 1918; Bartleby.com, 2000. www.bartleby.com/107/. Permission by Bartleby.com, Inc.

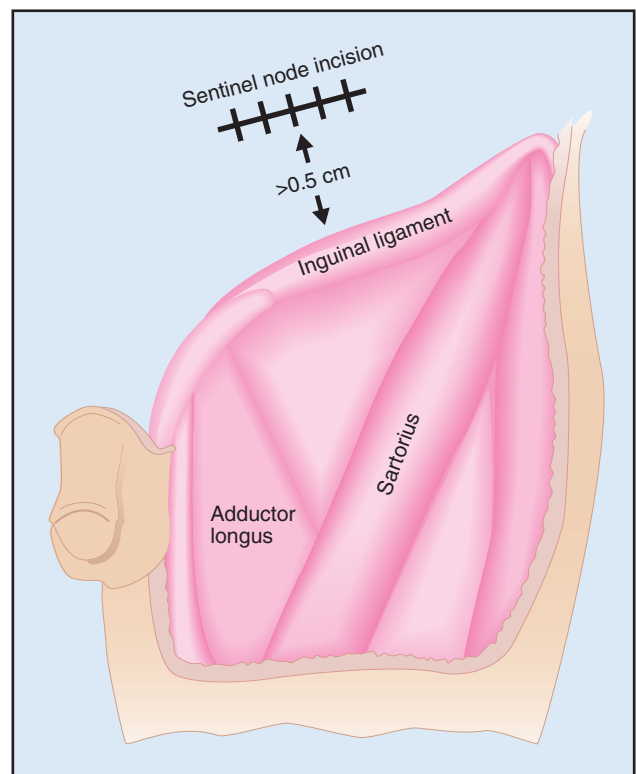


Fig 1B. — Schematic representation of an obliquely oriented sentinel node biopsy incision in the situation where the node is mapped above the inguinal ligament. Adapted from Gray, Henry. *Anatomy of the Human Body*. Philadelphia, PA: Lea & Febiger, 1918; Bartleby.com, 2000. www.bartleby.com/107/. Permission by Bartleby.com, Inc.

Minimizing the morbidity of an inguinal node dissection starts with careful planning when performing an inguinal sentinel node biopsy. When the sentinel node is mapped to the lower portion of the groin, below the inguinal ligament (ie, in the femoral triangle), the incision should be vertically oriented and at least 0.5 cm below the groin crease (Fig 1A). When the sentinel node is mapped to the upper portion of the groin, above the inguinal ligament, the incision should be horizontally or obliquely oriented, again at least 0.5 cm above the groin crease (Fig 1B). Appropriately planned sentinel node incisions facilitate the excision of the sentinel node biopsy scar at the time of completion lymphadenectomy and allow the surgeon to avoid placing the lymphadenectomy incision in or across the groin crease. This simple step can limit the wound morbidity associated with inguinal node dissection.

Palpable inguinal nodal metastases can present in patients with or without a history of melanoma. For a patient presenting with a palpable inguinal mass, with or without a known prior melanoma, a thorough history and physical examination are the first steps in the evaluation. A patient presenting with an inguinal mass and a history of melanoma in the lower half of the body (anywhere below the umbilicus) should be considered to have metastatic melanoma until proven otherwise. Recognizing that there may be unexpected patterns of lymphatic flow in individual cases, Fig 2 depicts the expected lymphatic drainage patterns that terminate in the inguinal and pelvic nodes. Unless carefully and specifically questioned, patients often forget to men-

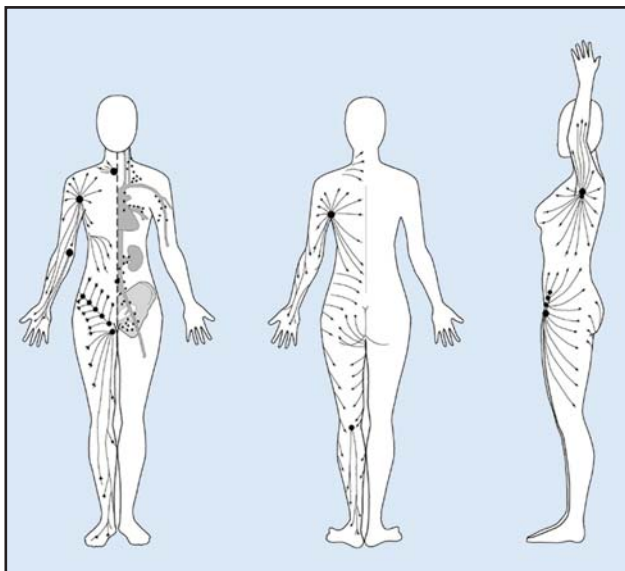


Fig 2. — Expected lymphatic drainage of various cutaneous sites. The observed drainage can often vary considerably from the depicted expected drainage, thus necessitating preoperative and intraoperative lymphatic mapping. From Ellis S. What is the lymphatic system? LymphLine (Lymphoedema Support Network's quarterly newsletter). Spring 2005. Available at <http://www.lymphoedema.org/Isn/Isn140.htm#LYMPHATICS>. Courtesy of Sandy Ellis, Nurse Consultant in Lymphoedema, St George's NHS Trust, London, UK.

tion the removal of previous cutaneous lesions from the drainage area of the basin involved; moreover, it is not uncommon for a melanoma to have been previously excised but misdiagnosed as a benign lesion. In addition, there are well-documented cases of metastatic melanoma to the nodes in the absence of a primary melanoma. In cases where the primary melanoma is not readily apparent, a thorough skin examination is augmented by the use of a Wood's lamp (UV or "black" light) to identify areas of depigmentation that could represent a regressed primary. In the absence of a documented cutaneous primary, patients presenting with melanoma in inguinal nodes should have a rectal and vulvar/vaginal or penile examination to exclude primary sites in these areas.

In patients presenting with an inguinal mass in whom the history and physical examination reveal no evidence of melanoma, the differential diagnosis includes inguinal and femoral hernias, reactive and infectious causes of lymphadenopathy including "cat scratch fever," lymphoma, or metastatic cancers, but as previously indicated also still includes melanoma. If the mass is clearly not a hernia on physical examination, then a fine-needle aspiration cytology or core-needle biopsy should be performed to establish the diagnosis. In cases of deep-seated disease that cannot be easily palpated, image-guided core-needle biopsy is favored over excisional biopsy. If needle biopsy is nondiagnostic, open excisional biopsy should be performed. In patients with a history of a prior melanoma or any history suggesting a regressed or excised primary melanoma, it is appropriate to perform a frozen section analysis of the excised lymph node. Patients should be informed of and agreeable to a plan to proceed directly to inguinal lymphadenectomy in the same setting should the frozen section reveal melanoma. However, if lymphoma or a nonmalignant explanation is found on frozen section analysis, the planned lymphadenectomy is aborted. Retrospective studies have consistently documented a lower morbidity for single-stage lymphadenectomies than for those performed after an open biopsy.^{2,3}

Technique of Inguinal Lymphadenectomy

Inguinal lymphadenectomy, or superficial inguinal node dissection, involves the en bloc removal of all inguinal lymphatic tissue contained within the femoral triangle, as well as the node-bearing tissue superior to the inguinal ligament but superficial to the external abdominal oblique aponeurosis (Fig 3). Ilioinguinal lymphadenectomy, or superficial and deep inguinal node dissection, combines the inguinal component with a deep or pelvic dissection, removing at a minimum the lymph nodes in the external iliac and obturator regions. For most inguinal and ilioinguinal lymphadenectomies, we prefer a curvilinear, vertically oriented incision that incorporates the scar from any prior node biopsy procedure, if

present. Care should be taken to avoid the creation of skin flaps that are excessively thin, as this is associated with postoperative skin necrosis. Likewise, it is important to restrict the raising of skin flaps only to the extent required to clear the anticipated boundaries of the dissection and remain well outside any prior biopsy cavity. Creating well-placed node biopsy incisions (or better yet, avoiding open biopsies altogether in the case of palpable nodal metastases diagnosed by fine-needle aspiration cytology) facilitates clearing all node-bearing tissue with the least requirement for extended, thin skin flaps. Once the flaps are raised, the boundaries of the dissection are developed down to the muscular and abdominal wall fascia. Superiorly, the superolateral and medial boundaries of the dissection are the anterior superior iliac spine and the pubic tubercle, respectively. Inferiorly, the medial and lateral boundaries of the dissection are the adductor longus and sartorius muscles, respectively. The crossing of these two muscles (the “apex” of the femoral triangle) marks the infe-

rior extent of dissection (Fig 3). Since electrocautery devices do not seal off lymphatics, tissue potentially containing lymphatic vessels should be clipped or ligated to reduce the rate of lymphocele or seroma formation. More recently, some have suggested that harmonic shears can seal lymphatic vessels effectively and efficiently,⁴ an observation that merits further prospective testing in the groin.

In most cases, the saphenous vein is sacrificed during the inguinal portion of the lymphadenectomy, dividing the vein first distally near the apex of the femoral triangle and again proximally at the saphenofemoral junction. The femoral artery and vein are skeletonized over their anterior 180° of surface, and the lymphatics are transected at the level of the inguinal ligament as they pass into the pelvis. The node-bearing tissue superior to the inguinal ligament and superficial to the external oblique fascia, up to the level of a line joining the anterior superior iliac spine and the pubic tubercle, should be dissected off the external oblique fascia and

included en bloc with the resected specimen. Prior to closure, the sartorius muscle is taken off its insertion on the anterior superior iliac spine and transposed onto the inguinal ligament in order to prevent exposure of the femoral vessels in the event of wound dehiscence. A closed-suction drain is routinely placed in the wound bed and brought out through a separate stab incision just beyond the edge of the skin flaps either superiorly (the authors’ preference) or inferomedially.

A deep or pelvic lymphadenectomy involves, at a minimum, the removal of the obturator and external iliac nodes up to the bifurcation of the internal and external iliac vessels. Through the same skin incision as the inguinal dissection, the external and internal oblique aponeuroses are incised along the direction of their fibers. The peritoneum and ureter are retracted superiorly and medially to expose the external iliac vessels and overlying nodal tissue. Extensively involved low external iliac or obturator nodes may require division of the inguinal ligament and extension of the external oblique fascial incision along a line directly superficial to the vessels. Fortunately, this is rarely necessary. The superior extent of dissection may be carried up to the level of the aortic bifurcation while remain-

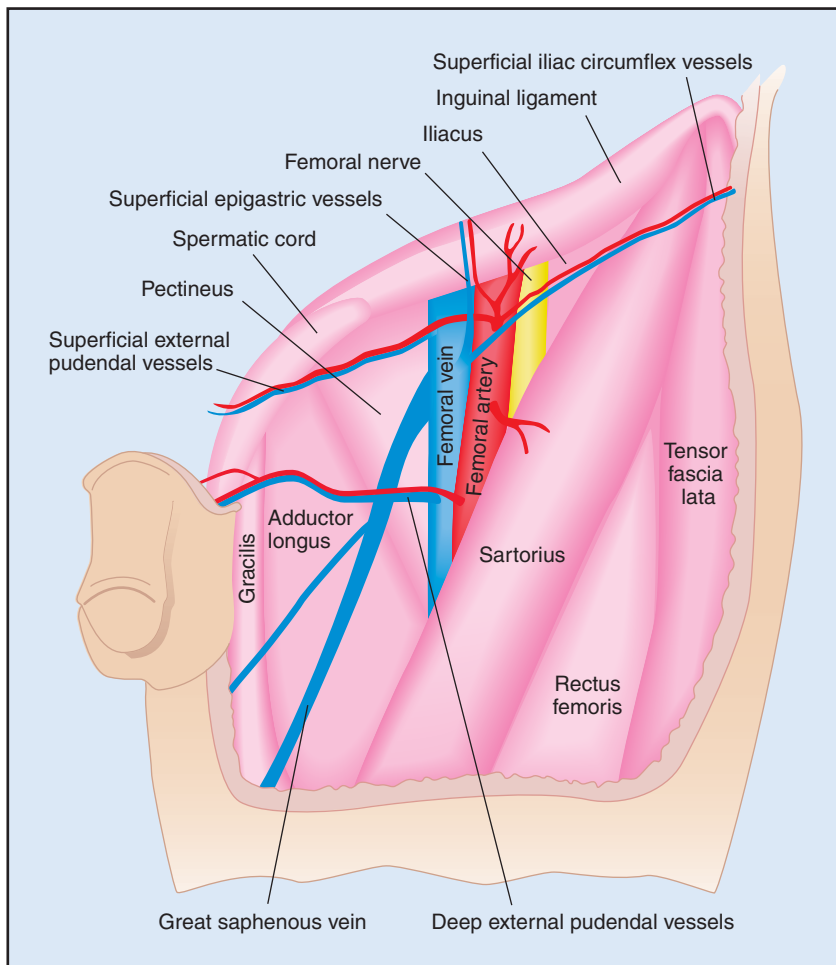


Fig 3. — Anatomy of the femoral triangle. The femoral triangle is bounded superiorly and laterally by the anterior superior iliac spine, superiorly and medially by the pubic tubercle, inferiorly and laterally by the sartorius muscle, and inferiorly and medially by the adductor longus muscle. The crossing of the latter two muscles (the “apex” of the femoral triangle) marks the inferior extent of the triangle. Adapted from Gray, Henry. *Anatomy of the Human Body*. Philadelphia, PA: Lea & Febiger, 1918; Bartleby.com, 2000. www.bartleby.com/107/. Permission by Bartleby.com, Inc.

ing entirely retroperitoneal. This involves elongation of the fascial incision and extensive mobilization, and we utilize it only for radiographic or intraoperative evidence of lymphadenopathy involving common iliac nodes. Para-aortic lymph node involvement is considered stage IV rather than stage III disease, and resection of para-aortic lymph nodes is beyond the scope of a pelvic lymphadenectomy. Prior to closure, a second closed-suction drain is placed through the external oblique fascia into the pelvis. The internal and external oblique fascia are closed with running absorbable sutures, and the skin incision is closed in layers with subcutaneous sutures and a subcuticular closure whenever possible.

When to Perform a Pelvic Lymphadenectomy

Perhaps the greatest controversy regarding inguinal lymphadenectomy for metastatic melanoma involves the risks, benefits, and indications for inclusion of the pelvic portion of the dissection. This remains an unsettled issue due to the lack of prospective randomized studies weighing the added morbidity against the benefit associated with the addition of the pelvic node dissection. Karakousis et al⁵ retrospectively reviewed the operative morbidity associated with inguinal node dissections in 117 melanoma patients, with 62 patients undergoing superficial inguinal lymphadenectomy and 55 undergoing combined superficial and pelvic lymphadenectomy. The authors observed a 16% incidence of infection in the combined group compared to 5% in the superficial group. However, no difference was observed in other morbidities, including wound necrosis, lymphocele, or lymphedema. In a separate report, Karakousis and Driscoll⁶ retrospectively reviewed 94 patients undergoing superficial dissection and 111 undergoing combined superficial and deep dissection.

They found a 43% incidence of leg swelling in the combined group compared to 37% in the superficial group. However, the criteria used to assess “leg swelling” and differences in other types of morbidity were not reported. While it is probable that pelvic lymphadenectomy increases operative morbidity to some extent, the magnitude of this increased risk is unclear and may be less than commonly presumed.

The clinical benefit of pelvic lymphadenectomy is also unclear due to the lack of appropriately designed studies. Kretschmer et al⁷ retrospectively compared 69 patients undergoing combined superficial and deep node dissections to 35 patients undergoing superficial node dissection alone. While there was no observed improvement in survival in the deep node dissection group, the study was underpowered to detect a difference and also was potentially biased since patients with higher comorbidities were more likely to undergo only the superficial node dissection.

Some have discussed the use of Cloquet’s node to predict pelvic nodal involvement and dictate whether to perform the deep dissection. Essner et al⁸ retrospectively reviewed 93 cases of patients with positive inguinal sentinel nodes. All patients in the study underwent completion superficial lymphadenectomy; 31 of them had intraoperative sampling of Cloquet’s node, which was defined as the lymphatic tissue medial to the femoral vein at the superior aspect of the femoral canal, with deep dissection performed only if that node was found to be involved with melanoma. The remaining patients had either a superficial node dissection only (20 patients) or a superficial and deep node dissection independent of the status of Cloquet’s node (38 patients). The authors found the status of Cloquet’s node had a 66% positive predictive value, with 4 of 7 patients who had a positive Cloquet’s node having documented pelvic nodal metastases and a 97% negative predictive value,

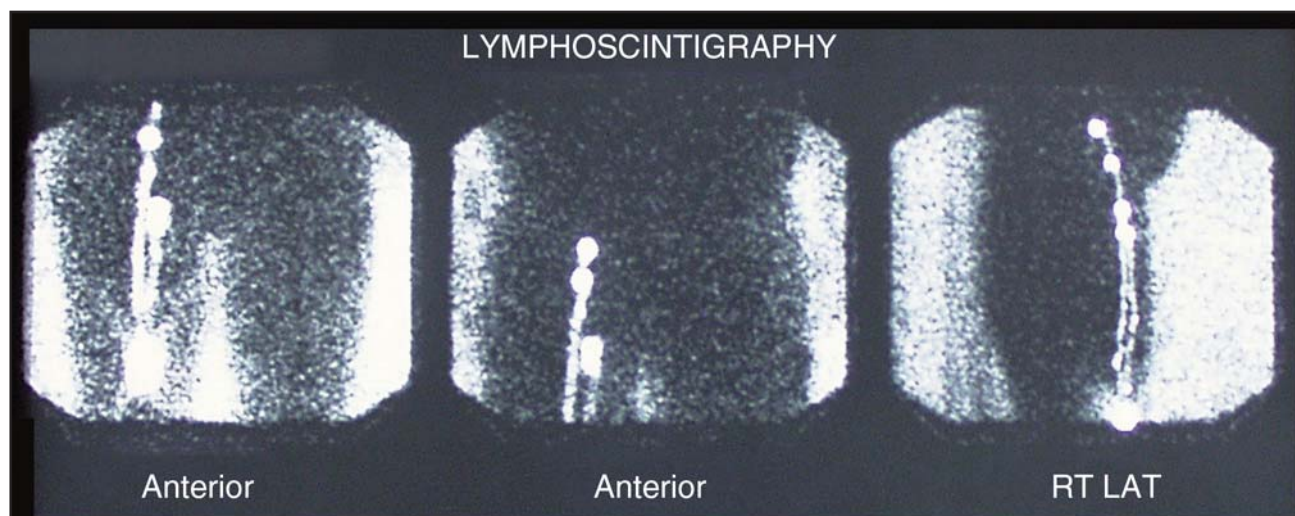


Fig 4. — A lymphoscintigram demonstrating drainage of an anterior thigh melanoma directly to sentinel iliac nodes. On the lateral view, nodes with uptake are above the inguinal ligament and therefore beyond Cloquet’s node.

and with 46 of 47 patients with a negative node of Cloquet having no evidence of pelvic nodes either at the time of deep dissection, if performed, or on subsequent follow-up. However, other studies have not supported the use of Cloquet's node to determine the need for pelvic lymphadenectomy, reporting negative predictive values of less than 90%.⁹ Badgwell et al¹⁰ reported a negative predictive value of only 63% in cases where Cloquet's node was negative, but pelvic dissection was pursued nonetheless due to high clinical suspicion.

Based on our own experience, we do not rely on the status of Cloquet's node in any way. We have observed many cases wherein lymphoscintigraphy performed for sentinel node biopsy demonstrates lymphatic drainage to the pelvic nodes directly from the low- or mid-inguinal nodes, entirely bypassing Cloquet's node (Fig 4). Further complicating the matter, the definition of Cloquet's node is not standardized. Some surgeons dissect the lowest external iliac node from beneath the inguinal ligament and call this Cloquet's node; in this case, a positive Cloquet's node by definition means that the pelvic nodes are involved. Again, however, in our experience the converse is not true — the lowest external iliac node may be negative in some cases with involvement of other pelvic nodes. Given the large degree of variability in lymphatic drainage patterns seen on sentinel node lymphoscintigrams, it is not surprising that no single predefined lymph node can predict the status of the iliac and obturator nodes, just as no single inguinal node — without intraoperative lymphatic mapping — can routinely predict the status of the superficial nodal basin. On the other hand, if clinical or radiographic evidence of pelvic nodal metastasis exists, this should routinely lead to performing a deep node dissection as well as a superficial lymphadenectomy. Hughes et al¹¹ relied on clinical suspicion based on physical examination and preoperative computed tomography (CT) imaging to determine the extent of dissection, and they performed 60 superficial node dissections and 72 superficial and deep node dissections. After a median follow-up of 43 months for surviving patients, 40% of patients in the combined dissection group had positive pelvic nodes, while only 10% of patients in the superficial node dissection group exhibited a pelvic recurrence. In addition to preoperative imaging and physical examination, other clinicopathologic features associated with pelvic nodal spread in this study included extracapsular extension and the involvement of multiple nodes in the superficial node basin.

Given the uncertainty of both the risk and benefit of pelvic node dissection, we advocate a "selective" approach when considering both the choice and the extent of a pelvic lymphadenectomy. Adding a pelvic lymphadenectomy to a superficial node dissection is justifiable for most cases of palpable inguinal disease and is warranted whenever pelvic lymphadenopathy is seen on preoperative CT or when hypermetabolic pelvic nodes

are identified on preoperative positron-emission tomography (PET) scans. In the absence of clinical evidence of pelvic nodal metastasis, it is reasonable to restrict the dissection exclusively to the superficial inguinal node basin in patients with significant operative risk or medical comorbidities. Currently, we do not perform a pelvic dissection in cases of microscopic inguinal disease in the sentinel node where the initial lymphoscintigraphy does not demonstrate any evidence of drainage through to the pelvic nodes. When the preoperative lymphoscintigraphy does indicate drainage to the pelvis, we generally do not extend the sentinel node biopsy procedure into the pelvis, but rather include the pelvic nodes in the completion lymphadenectomy if the inguinal sentinel node is found to contain micrometastatic disease. The exception to this approach is when the pelvic sentinel node appears to be a primary draining node as evidenced by the presence of a separate lymphatic channel proceeding directly from the primary site to the pelvic node. In this case, we do pursue pelvic sentinel node biopsy, and we base our decision to perform a deep dissection entirely on the results of that biopsy.

Modifications of Operative Technique to Decrease Morbidity

Some groups have attempted to reduce operative morbidity by eliminating elements of the superficial portion of the procedure. Judson et al¹² undertook a prospective, randomized trial evaluating the morbidity of sartorius transposition in 99 patients with metastatic vulvar cancer. The authors did not find a significant difference in lymphedema rate, wound cellulitis, or dehiscence. In their nonrandomized retrospective series, Sabel et al¹ also found no significant difference in wound complication or lymphedema rates in their patients who did or did not undergo sartorius transposition. Even though this would be difficult to substantiate without a large randomized trial, given the potentially dire consequences of exposure of the femoral vessels in the admittedly rare event of complete or near-complete wound dehiscence, we continue to advocate the routine performance of sartorius transposition when dissecting the contents of the femoral triangle. We consider omitting sartorius transposition in selected cases, particularly where the node dissection incision does not directly overlie the femoral vessels, as in the case of a completion lymphadenectomy after a positive sentinel node biopsy performed high in the groin, above the inguinal crease (Fig 1B).

Other groups have proposed preserving the saphenous vein during the performance of superficial lymphadenectomy. Sparing the saphenous vein has the theoretical objective of reducing the rate of lymphedema, wound complications, and potentially venous thromboembolism. Dardarian et al¹³ retrospectively reviewed this modification for metastatic vulvar cancer. They found a significantly reduced rate of cellulitis,

wound dehiscence, and chronic lymphedema ($P < .05$). Importantly, this benefit was observed without an increased rate of local recurrence. Sabel et al¹ adopted the strategy of saphenous vein preservation in selected patients with microscopic inguinal disease. The authors found that preserving the saphenous vein was associated with a reduction of lymphedema from 30% to 13% and a reduction of wound complications from 20% to 7%. As the study was relatively small and non-randomized, these results are not statistically significant and are potentially biased by restriction of saphenous vein preservation to patients without extensive disease, who likely have an inherently lower complication rate whether or not the vein is preserved. While neither study reported the rate of venous thromboembolism, a reduction in this potentially life-threatening complication is another theoretical benefit. Based on the available literature, we believe there is a role for preserving the saphenous vein in cases of microscopic inguinal disease, and we do so routinely when performing completion inguinal or ilioinguinal node dissections after positive sentinel node biopsies, provided the vein is not directly involved with the biopsy cavity and can be dissected free without entering that cavity. The risks and benefits of saphenous vein preservation during inguinal lymphadenectomy for melanoma merit further investigation in a prospective, randomized study.

Postoperative Care After Inguinal Node Dissections

Several elements of postoperative care are important to consider in minimizing the morbidity of inguinal node dissections. Lymphedema is a serious postoperative complication of this operation, but its development and severity can be limited with appropriate postoperative care. To monitor and prevent lymphedema, we believe it is important to obtain preoperative leg circumference measurements and fitted gradient compression stockings. Immediately postoperatively, elastic wraps (eg, ACE bandages, Becton Dickinson and Co, Franklin Lakes, NJ) are placed from the foot to above the knee with overlying sequential compression devices since patients generally cannot tolerate wearing fitted compression stockings early on after surgery. Patients are kept on bed rest overnight but then are encouraged to ambulate slowly starting on the first postoperative day. Strict leg elevation is maintained in the hospital when the patients are not ambulating. They are generally discharged the next day after inguinal node dissection, but those who underwent ilioinguinal node dissection remain in the hospital a minimum of 2 days to as many as 4 or 5 days. At home and in the hospital, patients are restricted from sitting for prolonged periods of time for the first 1 to 2 postoperative weeks. Upon the first clinical sign of lymphedema, patients are immediately started on massage therapy, and compliance with ACE wrappings or com-

pression stocking use is verified. After the closed-suction drains have been removed and the wound is healed, patients are instructed to wear their fitted leg garments during the day for the initial 3 postoperative months and longer if lymphedema has been noted during that time. Most patients will note swelling in the upper thigh just above the top of the compression garment, and they should be reassured that this does not constitute lymphedema and is an expected and temporary consequence of the aggressive efforts to keep fluid from accumulating lower in the leg and foot.

Ko et al¹⁴ reported the technique of “complete decongestive physiotherapy” in 150 patients referred for established lower extremity lymphedema. This therapy involves aggressive massage therapy, compressive bandages, and exercises. Extremity circumferences were measured at seven specific locations to estimate limb volume. The authors documented an impressive mean of 67% reduction in volume after 2 weeks of therapy, and the observed results were durable at 12 months of therapy in compliant patients. Noncompliant patients regained a mean of 33% of their initial reduction of volume. While not directly comparing two groups of patients, this study emphasizes the value of promptly instituting massage and compressive therapy at the onset of clinically evident lymphedema as well as the importance of ongoing compliance with that therapy after initial improvement.

Deep venous thromboembolism (DVT) is a life-threatening complication associated with inguinal lymphadenectomy. Arbeit et al¹⁵ found a 14% rate of DVT or pulmonary embolism in a group of 44 patients undergoing inguinal lymphadenectomy for melanoma, despite the use of prophylactic subcutaneous heparin. It is likely that patients undergoing lymphadenectomy following sentinel node biopsy are at increased risk of venous thromboembolism as the two operations are usually performed in close temporal proximity and a small and otherwise insignificant clot formed during the first operation can propagate quickly after the larger second procedure. Several measures can be easily adopted to reduce the risk of DVT. Sequential compression devices (SCDs) are placed prior to the induction of general anesthesia for both the initial node biopsy procedure and the inguinal lymphadenectomy. Generally, a knee-high SCD is placed on the operative side (unless the primary site on the lower leg or foot is also being addressed surgically, in which case only the contralateral side is placed into an SCD) and a thigh-high SCD is placed on the contralateral side. Once the node dissection is completed, the knee-length SCD is removed and the operated side is wrapped in an ACE bandage covered with a thigh-length SCD. Drain output is closely monitored for evidence of early postoperative bleeding; if none is encountered, subcutaneous low-molecular-weight heparin therapy at a standard prophylactic dose is instituted on the first

postoperative evening. Patients with a prior history of DVT are treated with a preoperative dose of low-molecular-weight heparin as well. After an initial night of bed rest, ambulation is encouraged both in the hospital and at home; ambulatory patients without a prior history of DVT are not continued on any form of anticoagulation once discharged. Finally, a low threshold of clinical suspicion for DVT or pulmonary embolus should be maintained, and prompt investigation with venous ultrasonography is indicated in patients with new onset calf pain or leg swelling extending beyond mild lymphedema of the foot and ankle. Unexplained pulmonary symptoms are investigated with pulmonary angiogram-protocol CT, and pulmonary embolism is treated aggressively if encountered. Using these measures, we have seen two documented cases of pulmonary embolism following inguinal node dissection in the past 4 years, one of which was fatal. This represents an incidence rate well below 2%, although it is possible the rate would be higher if all patients were evaluated ultrasonographically for the presence of asymptomatic clots.

Future Directions

The best potential way to limit the morbidity of inguinal node dissection is to avoid utilizing the procedure. It is possible that a significant fraction of patients with micrometastatic lymphatic disease would never develop further nodal recurrence after sentinel node biopsy alone. Nodal observation as an alternative to immediate completion lymphadenectomy in melanoma patients with positive sentinel lymph nodes is currently being investigated in the Multicenter Selective Lymphadenectomy Trial II. In this prospective trial, patients with positive sentinel lymph nodes are randomized to either immediate complete node dissection or observation with serial ultrasonography. Patients randomized to observation undergo delayed complete lymphadenectomy upon clinical or ultrasonographic evidence of regional recurrence. However, while some patients may be able to safely delay or even entirely avoid completion lymphadenectomy, most patients with positive inguinal nodes are best served by a thorough and complete node dissection done with careful attention to detail by an experienced surgical team. Important goals for surgical oncologists to pursue in prospective trials in the years ahead include further minimizing wound complications, reducing the length of time closed-suction drains are required, and decreasing the rates of lymphedema and venous thromboembolism.

References

1. Sabel MS, Griffith KA, Arora A, et al. Inguinal node dissection for melanoma in the era of sentinel lymph node biopsy. *Surgery*. 2007;141(6):728-735.
2. Nathansohn N, Schachter J, Gutman H. Patterns of recurrence in patients with melanoma after radical lymph node dissection. *Arch Surg*. 2005;140(12):1172-1177.
3. Landry CS, McMasters KM, Scoggins CR. The evolution of the man-

agement of regional lymph nodes in melanoma. *J Surg Oncol*. 2007;96(4):316-321.

4. Janetschek G, Hobisch A, Peschel R, et al. Laparoscopic retroperitoneal lymph node dissection. *Urology*. 2000;55(1):136-140.

5. Karakousis CP, Emrich LJ, Rao U. Groin dissection in malignant melanoma. *Am J Surg*. 1986;152(5):491-495.

6. Karakousis CP, Driscoll DL. Groin dissection in malignant melanoma. *Br J Surg*. 1994;81(12):1771-1774.

7. Kretschmer L, Neumann C, Preusser K, et al. Superficial inguinal and radical ilioinguinal lymph node dissection in patients with palpable melanoma metastases to the groin: an analysis of survival and local recurrence. *Acta Oncol*. 2001;40(1):72-78.

8. Essner R, Scheri R, Kavanagh M, et al. Surgical management of the groin lymph nodes in melanoma in the era of sentinel lymph node dissection. *Arch Surg*. 2006;141(9):877-882; discussion 882-884.

9. Strobbe LJ, Jonk A, Hart AA, et al. The value of Cloquet's node in predicting melanoma nodal metastases in the pelvic lymph node basin. *Ann Surg Oncol*. 2001;8(3):209-214.

10. Badgwell B, Xing Y, Gershenwald JE, et al. Pelvic lymph node dissection is beneficial in subsets of patients with node-positive melanoma. *Ann Surg Oncol*. 2007;14(10):2867-2875. Epub 2007 Aug 1.

11. Hughes TM, A'Hern RP, Thomas JM. Prognosis and surgical management of patients with palpable inguinal lymph node metastases from melanoma. *Br J Surg*. 2000;87(7):892-901.

12. Judson PL, Jonson AL, Paley PJ, et al. A prospective, randomized study analyzing sartorius transposition following inguinal-femoral lymphadenectomy. *Gynecol Oncol*. 2004;95(1):226-230.

13. Dardarian TS, Gray HJ, Morgan MA, et al. Saphenous vein sparing during inguinal lymphadenectomy to reduce morbidity in patients with vulvar carcinoma. *Gynecol Oncol*. 2006;101(1):140-142. Epub 2005 Dec 20.

14. Ko DS, Lerner R, Klose G, et al. Effective treatment of lymphedema of the extremities. *Arch Surg*. 1998;133(4):452-458.

15. Arbeit JM, Lowry SF, Line BR, et al. Deep venous thromboembolism in patients undergoing inguinal lymph node dissection for melanoma. *Ann Surg*. 1981;194(5):648-655.