

Videocapsule Endoscopy of the Small Bowel

Cristin Constantin Vere, Costin Teodor Streba,
Ion Rogoveanu and Alin Gabriel Ionescu
*University of Medicine and Pharmacy of Craiova
Romania*

1. Introduction

The most difficult to examine segment of the digestive tract is the small bowel. However, examining the distal portions that follow the duodeno-jejunal junction is vital when trying to diagnose an important number of pathologies, most of them with vital implications for the patient.

Until recently, standard diagnostic techniques were limited to radiological barium-enhanced investigations, "push-enteroscopy" and intraoperative enteroscopy, selective arteriography, scintigraphy or computer tomography. All these methods were either too intrusive, such as the case with intraoperative enteroscopy, or did not provide sufficient data for an accurate diagnostic.

Technological progresses in recent years allowed for the rapid development of novel, more patient-friendly and diagnostically competent investigation techniques dedicated to this particular GI segment.

Videocapsule endoscopies (VCE), along with balloon (single or double) enteroscopy are currently considered the two most valuable tools available to the gastroenterologist. (Iddan et al, 2000; Swain P, 2003)

The VCE system is currently the most widespread investigation technique for the small bowel, due to its convenience of use and slightly better affordability. It has been tested in a large number of studies, being compared to all other investigatory techniques, currently a large number of high-impact papers existing on the subject. It is estimated that over one million such devices have been swallowed over the course of almost ten years since its first introduction on a global scale.

2. Historical background

A miniaturized device, small enough for a human to swallow, that could reach all segments of the digestive tracts was imagined thirty years ago, in 1981, by Gavriel Iddan (considered the inventor of capsule endoscopy). He was the first to conceive a miniature wireless camera-enabled device that could reach the difficult segments of the digestive tract, otherwise accessible at that time only by means of small-bowel follow-through (SBFT). The technology of that time did not however permit for such miniaturized devices which could complete this task; hence, production was stopped for nearly 20 years. In 1994, he filled a patent for such a small wireless device equipped with a videocamera and capable of

transiting the gastrointestinal tract, while similar results being reported by Gong and Swain in the same year (Gong et al, 1994) and in 1996 (Swain et al, 1996).

The initial blueprint of the system remained mostly unchanged since conception, and consists of three main elements: a small, swallowable device equipped with a lens system, a recording sensor, an integrated circuit and a wireless antenna; a recording device equipped with skin-mounted sensors that receives and stores the video data, and a computer interface equipped with a specialized software application, necessary for later interpretation of these recordings. (Jeremy G et al, 2007; Koulaouzidis A et al, 2009)

The technology progressed rapidly over the following years, and after almost 20 years since the first time that the idea emerged, the first prototype was produced by Given Imaging of Yokneam, Israel, in 1999. The device received FDA (U.S. Food and Drug Administration) approval in 2001, being the first such device to receive official accreditation for human use. This was the birth of the first videocapsule endoscopy system (VCE for short), and was entitled Pillcam® M2A. A series of more specialized devices for different anatomical regions were later introduced, such as the Pillcam® ESO (for the esophagus) and Pillcam® COLON, which is currently used in Europe and Israel. A specialized capsule for investigating the small bowel (entitled Pillcam® SB) followed the more general-use device M2A, and the ESO and Colon devices already received a generation update.

Other VCE platforms became available, such as the one produced by Olympus Medical Systems Corp, Japan, the Chinese company Chongqing Jinshan Science and Technology, and the Korean company IntroMedic.

Currently, the main differences between these platforms consist in different sensor types used for video recording, battery operating time and the complexity and features of the interpretation software.

3. Technical characteristics

As we noted earlier, technical constraints delayed the production of VCE systems. Complementary metal oxide semiconductor (CMOS) imaging sensors, small and affordable in price, became available in the late 1990s, the introduction of application-specific integrated circuits (ASIC) chips allowed for rapid data integration. Light emitting diode (LED) light sources became widespread, and all these components made good use of a small enough battery that could be integrated in the pill-shaped concept a videocapsule required. Recording devices could be smaller and lighter, larger capacity magnetic hard drives allowed for extensive storage space necessary for the several hours of recording time, and personal computing sufficiently evolved, allowing the production of software capable of displaying and analyzing the video files resulting from VCE recordings. (Vere et al, 2008)

The videocapsule itself is basically an ingestible cylindrical device measuring 26x11 mm and weighing 3.7 grams. The on-board CMOS sensor captures two images per second. The device also contains an optical system, a LED light source, an ASIC control chip, a RFID antenna system, all these circuits being powered by a battery pack with a median lifespan of approximately 8 hours, which is considered to be the average duration of a full GI transit. The resulting video contains well over 50 000 images for one test. Recent generations improved the lighting capabilities of the LED system, with advanced light controls, as well as a wider lens system, offering 156° viewing angles (versus only 140° in the old systems). The improved optics also provides 1:8 magnifications and an estimated 1-30 mm depth of view.




Fig. 1. (a) – Videocapsule. The transparent optical dome hosts the camera lens system and the six LEDs used for illumination. The battery pack, circuit board and communication antenna are protected inside the body. (b) – Videocapsule in its original plastic container. Once removed, the capsule activates and starts sending images to the recording device.

The Olympus version, the EndoCapsule for the small bowel, is equipped with a CCD (Charge Coupled Device) sensor for image acquisition. Its dimensions are basically the same (26x11 mm), weighting 3.8 grams and having a field of view of 145°, while providing a similar battery life of 8 hours. The EndoCapsule received clinical approval in the United States, parts of Europe and Japan.

MiroCam®, the device produced by the Korean company Intromedic, records three frames per second (compared to only two frames on other devices), using a high resolution (320x320 pixels) CCD image sensor, and has an improved battery pack capable of sustaining 11 hours of recording. The battery life is also improved by the different transmission method, which uses the human body as a conductive medium for sending data to the attached electrodes. The higher battery life, as well as different transmission method, may allow for a type of „second-look” enteroscopy to be performed by consecutively ingesting the two VCE systems. A recent pilot study however did not provide statistically significant data in this respect. (Kim HM et al, 2010)

This system is not widely spread and clinical data is scarce on the actual upgrades in terms of patient management, although the extended recording time might make it more suitable for localizing distal lesions, which might be missed by other VCE systems due to incomplete examinations caused by lower battery life or patient-related factors such as higher transit times or longer GI tracts.




Fig. 2. The videocapsule in detail.

Both the CMOS and the CCD imaging sensor offer excellent picture quality of the GI tract. While the CCD does produce the highest level of signal with the least amount of signal noise, the CMOS images get more uniform illumination at theoretical higher frame rates, due to the decreased size and dedicated ASIC imager chips enabled with power management algorithms and dynamic light and exposure adjustments.

The second part of the wireless endoscopic capsule platform is represented by the lightweight data recorder unit, attached to the patients' body by a belt, designed not only to support it, but also to attenuate radio signal loss. This receiver is equipped with a set of eight external adhesive electrodes that are placed on the lower chest and abdomen in precise locations. These serve as receivers for the radio frequency communication coming from the wireless capsule, while the recording unit itself, equipped with a magnetic disk drive and an appropriate hardware interface receives the signals, processes and stores them as image clips. The recorder has a rechargeable battery pack that ensures eight to ten hours of continuous functioning.

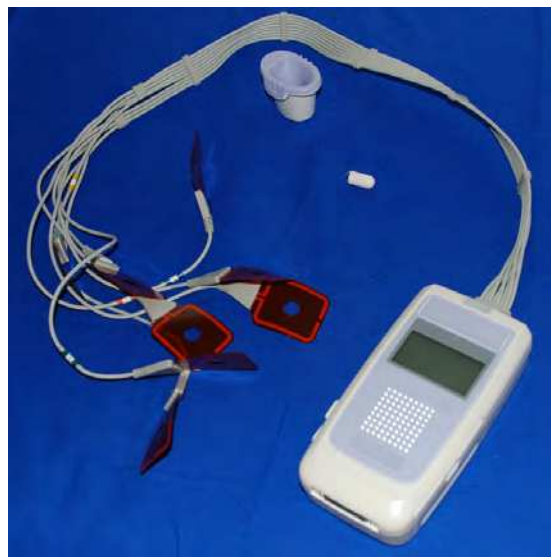

Fig. 3. Recording unit with the receiving electrodes. The videocapsule itself, as well as the initial cradle are pictured above.

It is possible to review the live recording coming from the wireless videocapsule using an USB-connected viewing device equipped with a small LCD screen. It is also possible to approximate the capsule location by using a triangulation method that takes into account the receiving electrode, knowing that the capsule itself should be in the immediate vicinity of the active pad. This is extremely important, as prokinetics can be administered to ensure faster passage of the videocapsule through the pylorus, thus reducing the possibility of an incomplete enteroscopies due to gastric retention. (Qureshi Wa et al, 2005; Souquet JC et al, 2005)

It is notable that the MiroCam system developed in Korea uses a different system to transmit data, which, as noted above, improves battery performance of the video capsule, as well as making the use of both systems in parallel possible. (Delvaux M et al, 2008)

Initially, protocols for capsule endoscopy excluded its use in patients with cardiac pacemakers, implantable defibrillators or other vital medical equipment, due to possible interference between the wireless capsule and these devices. As a large number of cardiac pacemakers and implantable defibrillators are available on the market today, it is practically impossible to test every single one, hence caution is always advised when dealing with this type of patients. Even though the majority of hospital protocols still enforce this regulation, several recent trials provided conclusive evidence that no significant interference actually occurs. Several reports cite blank periods when the receiving electrode was the one near the location of the patient's pacemaker, lasting from 20 to 30 minutes. This problem was resolved by adjusting the position of the electrode in relation to the pacemaking unit. (Gravina AG et al, 2010) No malfunctioning of the pacemaking units were recorded in the case report presented by Gravina et al, as well as several other studies. (Gravina A.G et al 2010; Guyomar Y. et al, 2004; Leighton J. A. et al, 2004; Payeras G et al, 2005; Dirks M. H. et al, 2008; Bandorski D. et al, 2008; Daas AY et al, 2008)

The reader station consists of a base unit that is connected to a workstation computer, equipped with specialized software that can receive and display in a specific user interface the recordings. The software installed on this computer receives each image recorded by CE and assembles a movie, in a proprietary format specific to each manufacturer that can only be read by its designed software equipment. Each recording device uses different compression algorithms; however the end result is a series of uncompressed images that can be fully exploited by the analyzer. The workstation software also applies various algorithms for image enhancement and land marking, later used by the examiner in reviewing a recording. Movies are usually stored on Data Versatile Disks (DVDs) or even high capacity universal-serial bus (USB) magnetic drives. Flash memory keys are usually used to transfer the data between the workstation and any computer or laptop which has the viewing software installed.

The viewing software is one of the most updated components of the WCE platform, suffering continuous upgrades that come to help the physician in interpreting the CE recordings and reducing viewing time. (Jeremy et al, 2007)

It is possible to scroll faster or choose the exact moment from which to begin viewing, as with any recorded video material. The visual time bar also contains a color-grading component which can be used by the reviewer to distinguish between each type of mucosa, pertinent to one particular GI segment. All software programs also have the ability to extract single images from a video, or cut and edit video segments. The viewing speed may vary from 5-40 to up to 80 frames per second, depending on the viewed segment and the physician's experience with CE recordings. Usual reviewing frame rates are between 12 and 24 frames per second for small bowel investigations. (Gay G et al, 2006)

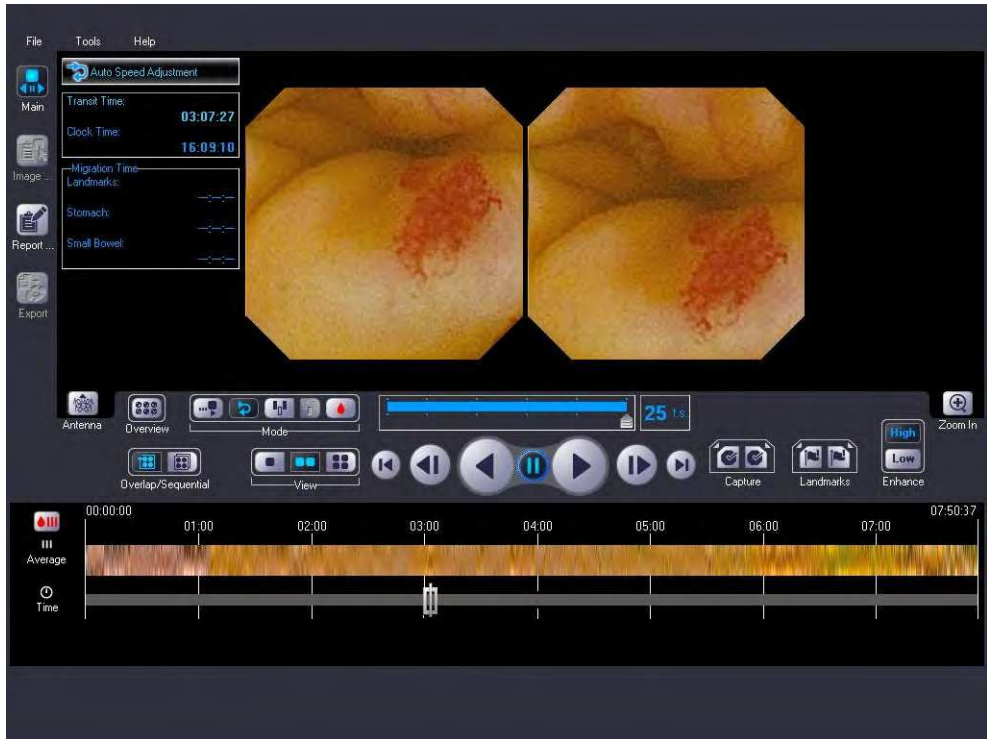

Fig. 4. Videocapsule software interface.

It is also possible to view thumbnail previews of interest areas of the GI tract, giving the examining physician an overview, while cutting down on viewing time. Features such as the QuickView function, provided by both the Given and the Olympus software, or similar tools, are designed to reduce reading time, however are associated with greater diagnostic bias, hence being recommended only when Inflammatory bowel disease (IBD) is suspected, or prior to a full examination, for previewing purposes. (Westerhof J et al, 2009)

Other useful additions to the viewing software are represented by the inclusion of the Fiji intelligent color enhancement (FICE) system, an inflammation (Lewis) scoring system, as well as a reference atlas to come to the aid of the interpreter. (Eliakim R et al, 2010)

As a whole recording may take up to eight hours hence all software provided by companies producing CE systems offer a wide variety of specialized tools that help eliminating human error, as well as making the interest areas easier to spot. One such tool is the red color detection component, which highlights the images containing traces of red color, thus pinpointing the location of possible OGIBs, telangiectasia etc. According to some studies this function gives a high rate of false positives; however it remains extremely useful in detecting intestinal bleedings. (Signorelli C et al, 2005; D'Halluin PN et al, 2005)

The time spent analyzing the video recordings varies from one to three-four hours, depending on the experience of the clinician, as well as the suspected pathology. Generally, viewing time for the small bowel varies between one and two hours. Many factors related to the existing conditions in the examining room may influence the interpretation of these

results, such as viewers' distance from the computer screen, position and number of light sources, as well as factors linked to the examiner, such as reading speed, attention level and level of specialized training. Several studies compared reading abilities of specialized gastroenterologists versus trained physicians as well as gastroenterology nurses. (Reena S et al, 2007; Hoeroldt B.S. et al, 2008) The general consensus was that interpretation of these recordings does not pose extreme difficulties to any examiner, however, specialized training should be considered for all individuals performing this task. (Cave DR, 2004) Internet-based reading services currently exist, where several institutes provide on-line help with the analysis of the recordings, through a web-based interface. Specialized teams of physicians offer their experience, thus reducing the risk of overlooking essential diagnostic signs in an investigation.

4. Examining technique

4.1 Patient consent

Even though it is a minimal invasive procedure, CE requires prior informed consent given by the patient. The performing physician has to fully explain the procedure, all risks deriving from it, as well as stating all potential complications, such as capsule retention, inconclusive findings or capsule aspiration. It should be noted that magnetic resonance imaging (MRI) is an absolute contraindication until the capsule passed the GI tract and its exit is confirmed. (Rondonotti E et al, 2005; Koulaouzidis A et al, 2009) The existence of cardiac pacemakers or implanted defibrillators may represent contraindications for capsule use, however, as noted earlier, recent consensus policies and a number of studies, confirm that the functioning of these devices is not influenced by CE. Caution is however advised, as a high number of different devices exist and not all have been tested.

4.2 Bowel preparation

According to existing literature, there is no standard bowel preparation for CE examining. (Melmed Gy et al, 2005) All patients are required to fast 10-12 hours prior to the investigation, and specific medication, such as iron tablets, opiates, and antimony drugs should be stopped two-three days prior to the investigation.

Some studies recommend the use of prokinetic solutions which should accelerate intestinal transit, while claiming to improve image clarity and diagnostic accuracy. (Viazis N et al, 2004; Mylonaki M et al, 2003) when compared to clear liquids alone. (Niv Y et al, 2004; Cave D et al, 2004; Ning D et al, 2005) However, a number of recent studies and meta-analyses concluded that bowel preparation is not necessary, as it does not improve the image quality or diagnostic rate of CE investigations. This conclusion is also supported by the latest consensus reports (de Franchis R et al, 2005) as well as by official recommendations given by several major capsule-producing companies. The polyethylene glycol (PEG) electrolyte purgative solution is widely used for bowel preparation, as it was proven to improve the rate of complete procedures, (Triantafyllou K et al, 2010; Rokkas T et al, 2009) along with prokinetics (metoclopramid, domperidone or tegaserod), while not significantly influencing the quality of the results in small bowel investigations. The majority of UK clinics do not use prokinetics in daily practice. (Lapalus MG et al, 2008; Ben-Soussan E et al, 2005; Postgate A et al, 2009)

4.3 Steps of the procedure

Electrodes are placed with the patient in supine position on a bed or a bench, except obese patients on which they can be placed while standing. The recording device should have the

battery fully charged and all necessary connections with the sensor array properly established; afterwards the device is attached using the belt.

The capsule is activated automatically once it is removed from its containing blister, after making sure that the expiration date is not overdue. The patient swallows the camera pill and the receiver starts recording as soon as it receives the first signal from the capsule.

In cases when swallowing difficulties may interfere with the procedure, or when the device has failed to enter the small bowel despite prokinetic preparations, an endoscope equipped with a Roth® net or a special delivery device such as the AdvanCE® may be used.

Once the capsule reached the small intestine, patients are free to move around, or in some cases even leave the hospital for a few hours.

4.4 Capsule retention and the patency capsule

One major concern when using CE is capsule retention at any level of the gastrointestinal (GI) tract. Besides the major cause of retention, obstruction, which also constitutes a major contraindication of this procedure, these situations can occur in stricturing Crohn's disease patients, or in some obscure/occult GI bleedings (OGIBs).

This problem can be prevented by using standard radiology and/or a special patency capsule, such as the Agile® patency capsule developed by Given Imaging. The patency system received a recent update. The second generation device now used consists of a central 13 x 3 mm radiofrequency identifiable tag (RFID), an antenna system and a magnet. A battery is not necessary for operating the device. It can receive electromagnetic waves at a frequency of 128 KHz, while emitting at 64 KHz. It also contains a small barium pellet which makes it trackable under a fluoroscopic screen. The device is placed in a lactose shell which completely dissolves once inside the GI tract and a plastic coating protects the device from digestive fluids. Excretion can be confirmed by X-ray examination or through the portable scanner which detects the electromagnetic signal it emits. If the patency capsule is excreted in under 30 hours of ingestion, the patient is viable for CE investigation.

5. Indications and contraindications for Capsule Endoscopy

The current list of indications for the VCE include a number of different pathologies, being somewhat limited by concomitant conditions which may be found in particular patients.

As such, possible indications include, but are not restricted to:

- Obscure, occult or manifest gastrointestinal bleedings with negative endoscopy/colonoscopy results;
- Feripriva anemia of unknown cause;
- Suspected small bowel Crohn's disease;
- Early evaluation of small bowel Crohn's disease recurrence after surgical treatment;
- Differential diagnosis of undetermined colitis;
- Refractory or recurrent celiac disease despite treatment; Selected cases of intestinal malabsorption with inconclusive conventional test results;
- Complications of non-steroidal anti-inflammatory drug treatment;
- Screening and surveillance of polyps in familial polyposis syndromes;
- Suspected tumors of the small bowel;
- Gastrointestinal „graft versus host“ symptoms with GI interest;
- Small bowel transplant;

Several contraindications are cited in literature, some of them being relative while other clearly excluding the use of the device.

- Swallowing disorders (relative contraindication, as the capsule can be inserted with devices cited above);
- Patients with implanted defibrillators/cardiac pacemakers, or who are to be subjected to RMI investigations before capsule passage completion (relative contraindication, as noted above);
- Pregnant patients (tolerance insufficiencies);
- Altered peristalsis (diabetic gastro paresis);
- Gastrointestinal fistula;
- Previous major surgical interventions in the abdominal/pelvic areas;
- Suspicion of stenosis which could lead to capsule retention.

6. Diagnostic yield, comparison with other investigations, and impact on clinical outcome

A large number of studies exist on the diagnostic capabilities of this technology. The diagnostic yield of capsule endoscopy varies depending on the number of patients included in these studies, and several meta-analyses deal with the impact it has on disease progression and outcome. (Pennazio M et al, 2004; Appleyard MN et al, 2006; Gupta R et al, 2006; Ersoy O et al, 2006; Lewis BS et al, 2002; Appleyard M et al, 2001; Rastogi A et al, 2004) The indications for CE investigations are somewhat limited, and insufficient evidence currently prevents its use on a larger scale (table 1)

Indication	Evidence Level	Grade of recommendation
Obscure gastrointestinal bleeding		
VCE may be used as the first investigation for OGIB after negative endoscopies (upper and lower)	2b	B
Recommended in patients with unexplained iron-deficiency anemia	2b	B
Crohn's disease		
Most indicated procedure for evaluation of small-bowel mucosal lesions specific to Crohn's disease	3a	B
Small bowel imaging or patency capsules should be used to eliminate the risk of capsule retention in Crohn's Disease	2b	B
NSAIDs treatment should be stopped two months prior to CE	2a	B
Celiac disease		
High diagnostic yield in Celiac disease patients	2b	B
Refractory or complicated celiac disease patients should receive CE	2b	B
Small bowel tumors / Polyposis		
Should be considered as first line of screening in patients with Peutz-Jeghers syndrome	2b	B
CE indicated in familial adenomatous polypos patients with duodenal polyps	2b	B
Influenced the therapeutic work-up of small-bowel tumors	3b	B

Table 1. The 2009 European Society of Gastrointestinal Endoscopy (ESGE) updated information on the indications for video capsule endoscopy (adapted from Ladas SD et al, 2009)

6.1 Capsule endoscopy in obscure gastrointestinal bleedings

Subgroup analysis showed that if patients suffer from ongoing GI bleedings, the diagnostic yield reaches as high as 92.3%, however it sharply descends to 44.2% in obscure occult bleedings. (Gupta R & Reddy DN, 2007)

The International Consensus on Capsule endoscopy (2005 and 2006) recommend that the procedure should be performed within the first two weeks following patient admission (Pennazio M et al, 2005), as it has been proven that early use dramatically increases the chances of discovery of OGIBs. (Bresci G et al, 2005) Figure XX presents the suggested diagnostic algorithm for OGIBs, which recommends early use of CE after negative upper and lower endoscopy findings.

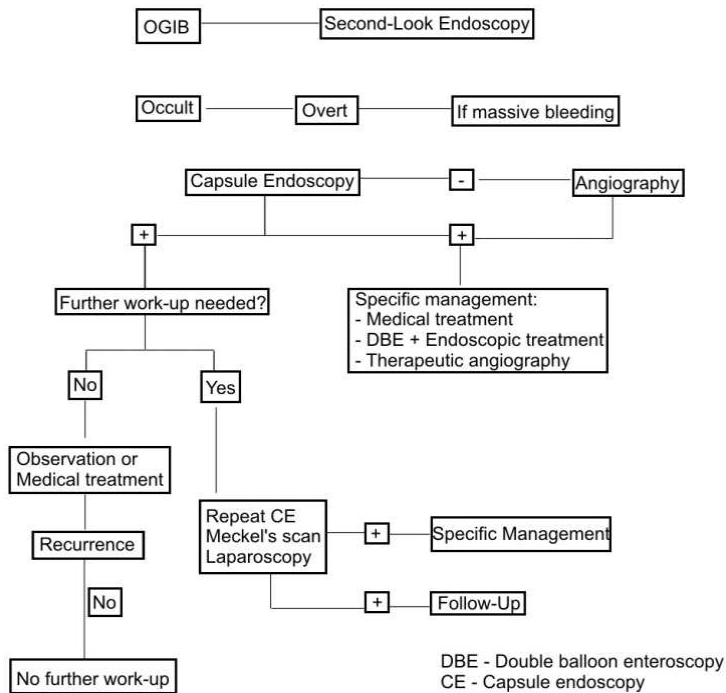


Fig. 5. Proposed algorithm for the diagnosis and management of OGIBs. ICCE Consensus for obscure gastrointestinal bleedings, 2005

The large majority of studies discuss the changes in patient management after capsule investigation, however failing to provide accurate information on the clinical outcome. In the case of OGIBs, a positive outcome is represented by successfully identifying the cause of bleeding and efficiently stopping it while preventing recurrences. Compean et al (2007) referred to 40 patient patients with chronic OGIB investigated by CE between 2003 and 2005. They assessed the impact of therapeutic interventions on the recurrence of OGIBs, following positive CE findings. The study found a positive correlation between the success rate of CE and favorable clinical outcome, recurrent bleedings being less likely in these patients. Pennazio et al (2004) followed a group of 56 patients over the course of 18 months,

determining that 85.9% of the patients with ongoing overt GI bleedings had complete resolution, compared with only 69.2% of the patients with current OGIBs and 41.4% of patients with prior episodes of OGIBs. Its conclusion was that a direct correlation between the time when CE is performed and the status of the GI bleeding exists, and is extremely important when assessing clinical outcome.

A series of large multicentric studies reported changes in the management of OGIB patients after capsule endoscopy. Albert et al (2005) reported that 66% of a total of 247 included patients were recommended a certain procedure or followed a specific treatment after positive diagnostic by using CE. Other studies report that nearly 70% of all positively-identified patients received adequate treatment. Contradictory results were reported however by Rastogi et al (2004), with positive clinical outcome in only 16% of all patients considered in their study. Positive and negative predictive values (PPV and NPV) of CE were reported to be extremely high in various studies. Delvaux and his team (2004) after a one-year follow-up of 44 patients, found a 94.% PPV and 100% NPV in CE patients. In his study of 100 consecutive cases, Pennazio et al (2004) reported a PPV of 97%, and 82.6% NPV. A large retrospective study performed in the Mayo Clinic proved that there was a significant decrease in hospitalization time for all OGIB patients after CE was performed. Also, it was noted that less investigations were performed, and that transfusional needs were reduced after positive CE investigations.

Each study included variable population groups and lacked standardized management specific to different medical centers. This accounts for the relatively variable outcome and different diagnostic yields reported. (Lai LH et al, 2006; Carey EJ et al, 2007) More meta-analyses and large populational studies are needed in order to give a final verdict on the efficacy of this method; however it is clear that both clinical outcome and disease management is influenced by CE in a positive manner.

High diagnostic yield and ease of use make it a prime candidate in early diagnosis and screening programs for OGIBs.

Since its introduction in 2000, the main concern with capsule endoscopy was to determine the advantages it provides over other more invasive existing techniques.

The vast majority of published literature compared CE to PE, DBE and barium follow-through. Wireless capsule performed better than radiation techniques and surpassed PE in diagnostic capabilities. Costamagna (Costamagna G et al, 2002) and Eliakim (Eliakim R et al, 2003) reported more than 100% increase in positive findings when using CE after classical radiology. One meta-analysis (Leighton JA et al, 2006) totalizing 88 patients found a 59% increase in positive findings (67% positive CE versus only 8% barium investigations).

Comparison with PE favors the use of CE, as the vast majority of studies indicate more than double diagnostic rates for capsule investigations (Saurin JC et al, 2003; Lewis BS et al, 2002; Ell C et al, 2002; Mylonaki M et al, 2003; Adler DG et al, 2004; Mata A et al, 2004; Hartmann D et al, 2003; Van Gossum A et al, 2003; Ge ZZ et al, 2004), especially when studies deal with occult OGIBs (Neu B et al, 2005) An analysis of these reports prompt a 63% yield for CE versus only 24% yield for PE. Another meta-analysis including 14 different studies (Leighton JA et al, 2006) and 396 patients revealed similar results, 63% positive results for CE and only 28% for PE. Small population groups, eligibility criteria and biases in the selection criteria were the main issues which could influence these statistics.

In a study published in 2007, Saperas E et al showed that CE diagnostic yield was 72%, compared with CT angiography (24%) or standard angiography (56%), also giving

more than double positive results when compared with standard CT scans. (Saperas E et al, 2007)

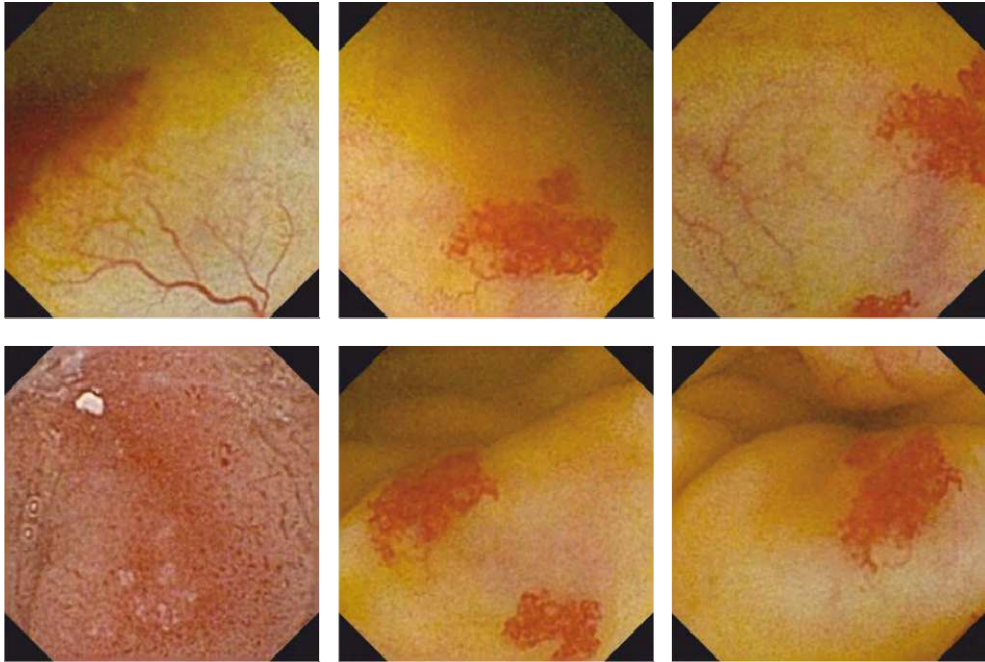


Fig. 6. Telangiectasias. Still images from different patients investigated with CE. (from the Research Center of Gastroenterology and Hepatology of Craiova Videocapsule Endoscopy Image Archive).

Recent studies focused on balloon enteroscopy, mainly the double balloon version, as it became increasingly popular over the world. CE has a higher detection rate of potential bleeding sources in a number of studies, mainly due to more complete investigations when compared with DBE. (Mehdizadeh S et al, 2006; Hadithi M et al, 2006) Hatidi et al (2006) performed both procedures on a lot of 35 patients, concluding that CE is more likely to detect the presence of bleedings; however the two procedures should be regarded as complementary rather than competitive.

General consensus today is that early diagnosis by CE can be followed by DBE findings, combined with interventional enteroscopy by the same method. (Kameda N et al, 2008; Marmo R et al, 2007)

6.2 Capsule endoscopy in Crohn's disease

In Crohn's disease, patients often experience pain, diarrhea and weight loss, non-specific symptoms that do not correlate with the negative results from usual imaging investigations. (Kornbluth A et al, 2005) A consensus panel suggested that further investigation by CE is useful when patients display at least two of these symptoms. (Kornbluth A et al, 2005)

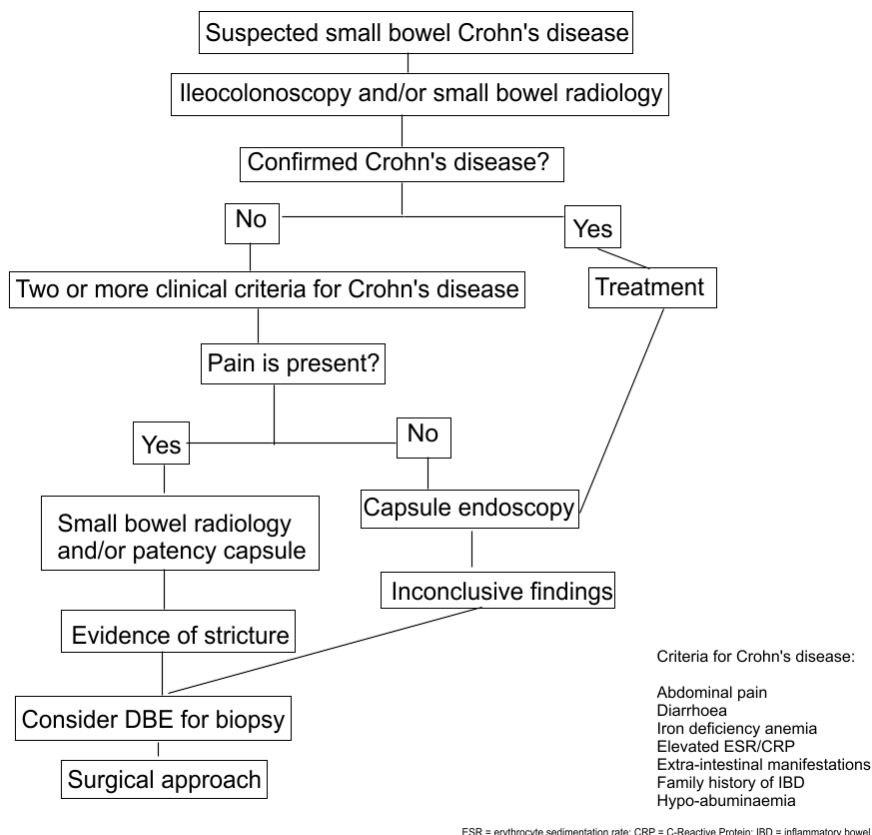


Fig. 7. Proposed algorithm for the diagnosis and management of Crohn's disease by using CE and DBE. Adapted from Sidhu R et al, 2008.

Capsule endoscopy has been shown to have a rather high diagnostic yield in non-stricturing Crohn's disease. CE might prove useful in both diagnosing early the disease, as well as in establishing disease prognostic, activity or mucosal response to treatment. Triester et al (2006) concluded in their meta-analysis that CE does not differ in diagnostic yield from other investigations when an initial suspicion of Crohn's disease existed. A statistically significant difference, favoring CE, existed however when analyzing subgroups of patients with established disease and suspected small-bowel recurrence. A small prospective study on only 27 patients having a suspected diagnosis of Crohn's disease shown a sensitivity of 93% and specificity of 84% for CE, also demonstrating significant changes in their management and subsequent outcome. (Girelli CM et al, 2007) A recent study shown that CE is useful in patients displaying atypical clinical symptoms, especially when surgery was performed at some point. (Mehdizadeh S et al, 2008) However, not all studies published so far rate CE as the most effective method of investigating Crohn's disease. A retention rate as high as 5 to 13 percent in Crohn's disease patients (Cheifetz AS et al, 2006) encourage the use of small-bowel follow-through, CT or a patency capsule examination prior to capsule

ingestion. This was shown to limit the use as a first-intent test in a small prospective study. (Solem CA et al, 2008) When investigating disease recurrence after surgery, CE proved to be more useful than colonoscopy and ileal intubation. Recurrence was demonstrated in 15 out of 24 patients after CE, compared to only 6 after colonoscopy (62% *versus* 25%). (Pons B et al, 2007)

A diagnostic index with a scoring system designed for grading disease activity in the small bowel, destined for clinical needs and research, was recently developed, as nonsteroidal anti-inflammatory drug intake, lymphomas, vasculitis or infectious disease may resemble the lesions found in Crohn's disease patients. (Gal E et al, 2008)

A meta-analysis of multiple studies, totaling 115 patients, showed a diagnostic yield of 61% for CE, compared to only 46% for ileo-colonoscopy. (Kornbluth A et al, 2005). Comparisons with push enteroscopy also favored the videocapsule, as this method allows deeper small bowel mucosa visualization. (Chong AK et al, 2005; Herrerias JM et al, 2003) Ileo-colonoscopy has a higher yield in the detection of disease recurrence compared to CE in patients who underwent ileo-colonic resection (Sidhu et al, 2008); however, one study showed that even at lower sensitivity, CE positively identified lesions outside the reach of the ileo-colonoscope. (Bourreille A et al, 2006)

Comparison with small bowel barium imaging showed superior diagnostic yield for CE, when dealing with suspected or recurrent Crohn's disease. (Chong AK et al, 2005; Dubcenco E et al, 2005; Triester et al, 2005; Marmo R et al, 2005) Higher diagnostic yield of CE when compared with CT enteroclysis were reported, and comparisons between CE and MR enteroclysis showed comparable or better yield for CE. Capsule retention remains a risk in patients with Crohn's disease, hence the majority of studies comparing radiological imaging techniques with CE clearly underline that the presence of strictures identified by said methods precluded further use of the videocapsule. A recent meta-analysis showed superior diagnostic yield to both barium follow-through and ileo-colonoscopy in non-stricturing Crohn's disease patients. (Triester et al, 2006)

Double balloon enteroscopy is considered the golden standard when assessing the diagnostic yield of CE, however studies with a longer follow-up period are required. The general consensus, as with most other indications, is that both procedures are beneficial and are not exclusive to each other.

6.3 Capsule endoscopy in celiac disease

Being a non-invasive investigation with a deep visualization of the intestine, CE may prove useful in the diagnosis of celiac disease. The mucosal "mosaic" pattern specific to celiac disease is recognized on the CE recording, and the usual aspects such as scalloping, loss of mucosal folds and mucosal atrophy are easily spotted. Also, positive correlation between aspects seen in endoscopy and those observed after CE evaluation, coupled with the greater reach of the latter, point to it as a useful tool for "virtual histology", giving the possibility of a correct macroscopic interpretation of the mucosal lesions.

In suspected celiac disease, when using duodenal histology as a gold standard, three studies shown good sensitivity (80%, 87.5% and 92%, respectively), as well as excellent specificity (100%, 90.9% and 100%, respectively) of the CE for a positive diagnosis. (Hopper AD et al, 2007; Rondonotti E et al, 2007; Murray JA et al, 2008) At present, however, more evidence is needed for CE to be used as a routine investigation in celiac disease, and duodenal biopsy remains the gold standard. (Sidhu R et al, 2008)

Patients with known celiac disease would also benefit from CE, as an evaluation of refractory or complicated forms is often needed. CE was shown to have a high diagnostic yield in identifying abnormalities of the mucosa and exclusion of adenocarcinomas. A study reported a yield of 60% in detection of complications relating to celiac disease, including ulcerated mucosa, malignancy and strictures (Culliford A et al, 2005)

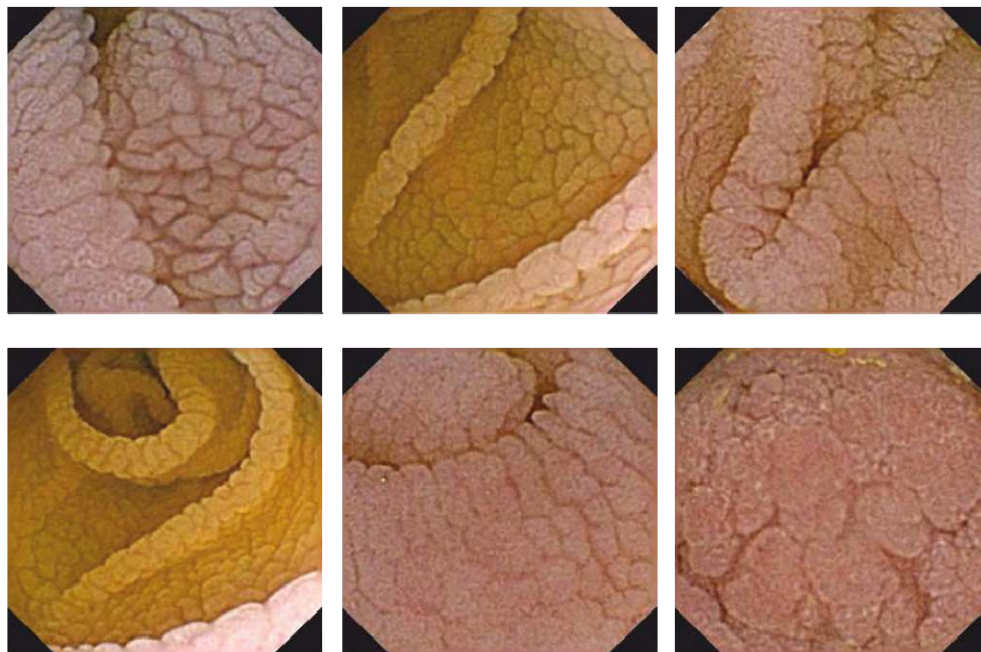


Fig. 8. Celiac disease. Still images from different patients investigated with CE. (from the Research Center of Gastroenterology and Hepatology of Craiova Videocapsule Endoscopy Image Archive)

6.4 Capsule endoscopy in hereditary polyposis syndromes

A number of studies indicate that CE has a superior diagnostic capability in identifying polyposis syndromes (both familial polyposis, and Peutz-Jeghers syndrome) when compared with small bowel barium follow-through and MRI. (Mata A et al, 2005) Detection rate was however influenced by the polyp size, as detection rate was equal for polyps larger than 15 mm, and greatly improved when sizes decreased, being visible only through CE when they were below 5 mm. However, CE provided incomplete data regarding large polyps, while MRI provided a better estimation of their site and size. (Caspari R et al, 2004)

Recent data suggests that CE may be used as a replacement for enteroclysis for surveillance of Peutz-Heghers syndrome patients; however this is not accurate in all cases, as it has low sensitivity for identifying the major papilla, also being inaccurate in distinguishing between periampullar and ampullary regions. (Ladas et al, 2009)

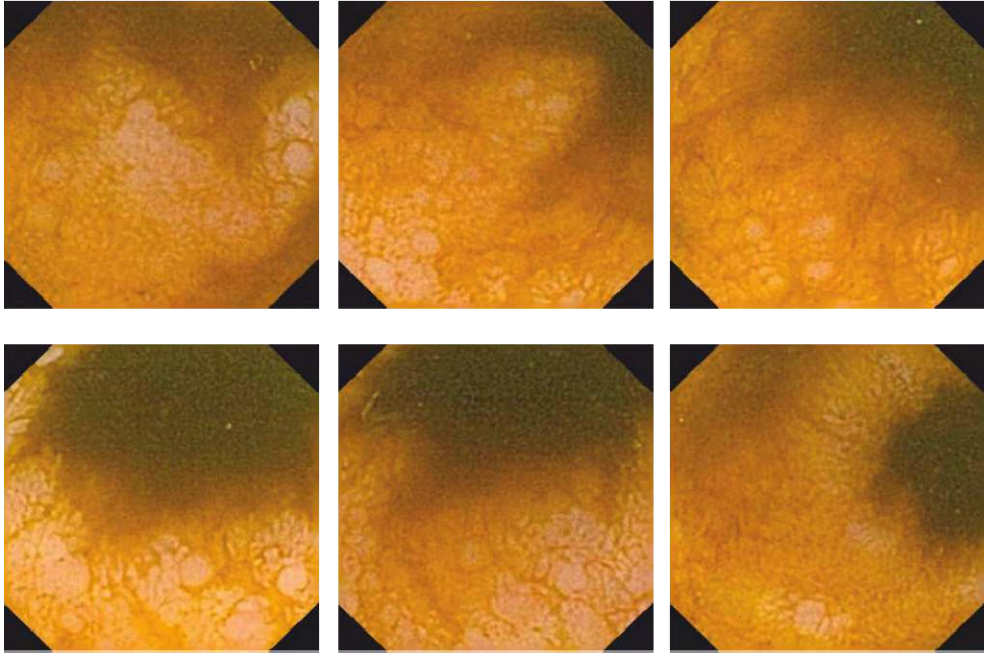


Fig. 9. Intestinal polyps. Still images from different patients investigated with CE. (from the Research Center of Gastroenterology and Hepatology of Craiova Videocapsule Endoscopy Image Archive)

6.5 Capsule endoscopy in diagnosing small-bowel tumors

Older literature showed a discrepancy between the number of diagnosed small bowel tumors during the course of life, and post-mortem autopsy findings. This was mostly due to the lack of investigatory techniques for this portion of the intestinal tract. As such, after the introduction of CE in routine clinical practice, the reported incidence for small-bowel tumors raised from 2% to as high as 9.6% (Corbin et al, 2006; Urbain D et al, 2006; Rondonotti E et al, 2008)

Capsule endoscopy is useful in diagnosing a full range of malignancies, the majority of findings being adenocarcinomas. Gastrointestinal stromal tumors are the most frequent benign tumoral finding, with more than 32% incidence (Rondonotti E et al, 2008) A complete list of usual tumors identified by CE can be found in table 2.

The majority of tumors are found in the jejunum (approximately 60%), followed by ileum (25-40%) and the duodenum (15-20%).

CE investigation is frequently delayed by multiple negative standard techniques, which do not provide sufficient data regarding the small bowel. It was shown that a good estimation of tumor location compared with surgical findings exists, thus dramatically influencing the course of the treatment and disease outcome. Accurate information regarding the location, dimensions and appearance is also available after CE. (Sidhu R et al, 2009)

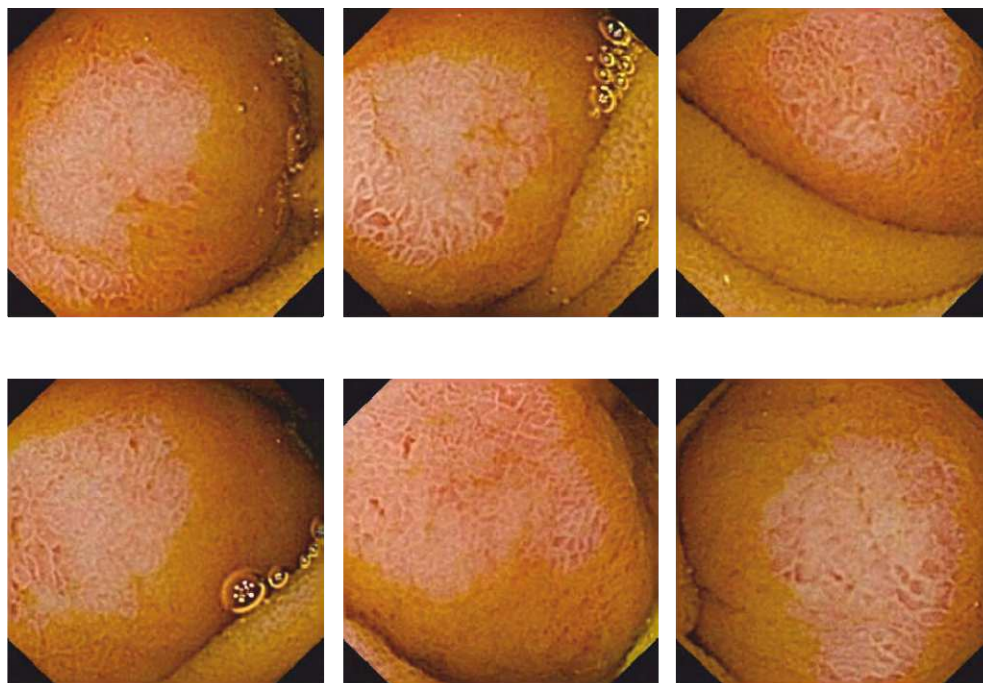

Fig. 10. Intestinal tumor. Still images from different patients investigated with CE. (from the Research Center of Gastroenterology and Hepatology of Craiova Videocapsule Endoscopy Image Archive)

Malignant tumors	Adenocarcinomas Carcinoid tumors Lymphomas Sarcomas Hamartomas
Benign tumors	Gastrointestinal stromal tumors (GISTs) Inflammatory polyps Lymphangiomas Lymphangioectasias, Hemangiomas, Hamartomas, Adenomas, Lipomas
Metastases	Colonic adenocarcinomas Hepatocellular Carcinomas

Table 2. Usual tumoral findings following Capsule Endoscopy.

7. Capsule endoscopy: Cost effectiveness

Capsule endoscopy represents a viable diagnostic tool in the early detection of OGIBs. One of the primary advantages being the ease of use, when accounting for its similar or greater diagnostic yields, it becomes evident that the method may be cost-effective for both screening and for patient diagnostic. Oradei et al (2005) estimated the costs of CE treatment on a population of 76 OGIB patients by studying synthetic indicators of different diagnostic tests. The main conclusion was that CE is indicated when diagnosing small bowel pathology, especially when an active bleeding is present. Similar findings were reported by Dyer et al (2004) in an Australian hospital, this study also proving the superiority of this procedure when compared with series radiography (58% versus only 4%).

As patients need no further diagnostic tests after a positive CE finding, do not necessarily require hospitalization, and there is no imperative need for bowel preparation, the procedure may be cost-effective when dealing with OGIB suspected subjects. (Marmo R et al, 2007; Oradei et al, 2005)

DBE and CE are considered complementary, initial DBE proved to be more cost effective; however CE followed by DBE was more cost-effective if DBE showed a probability below 59% of angiectasia. (Dyer S et al, 2004; Kamal A et al, 2006)

8. Conclusion

The videocapsule represents one of the most useful technologies for exploring an otherwise difficult segment of the digestive tracts. Its use on a larger scale in a clinical environment will help provide physicians take correct, informed decisions regarding a wide range of pathologies. A number of studies demonstrated multiple uses in screening, diagnostic or stadialization of different diseases.

Future protocols will probably include the technology in even more therapeutic strategies, confirming its usefulness and unique abilities. Hospitalization costs will be reduced as technology advances, as patients will not require extensive care before and after the completion of the procedure.

Despite the limitations and lack of treatment abilities, CE established itself as an accurate tool in the arsenal of endoscopic procedures available to an increasing number of clinicians around the globe. Different products offer a wide choice of features, even enabling concomitant use of two different devices to perhaps improve diagnostic accuracy, under special conditions.

Different improvements are expected in the following years, most notably in the image capturing field, where new compact High-Definition image sensors are expected to drastically improve the level of detail in captured movies. The software used for analysis is under continuous development, new features aiding the clinicians in their task to detect abnormalities. Improved battery life-span and perhaps basic maneuverability inside the digestive tract should be available in future generations of the device, thus dramatically improving diagnostic accuracy and specificity. Drug-delivery mechanisms, small surgical tools and enhanced imagistic equipment are just some of the multiple future add-ons which are planned for future iterations, further expanding the list of uses for the device.

In conclusion, Capsule Endoscopy currently provides a convenient alternative to more conventional or novel, but invasive techniques for exploring the small intestine. Future improvements of the platform, and virtually endless possibilities to improve upon the concept, will continue to offer even more benefits for the patients, at increasingly lower costs.

9. References

- Adler DG, Knipschild M, Gostout C. A prospective comparison of capsule endoscopy and push enteroscopy in patients with GI bleeding of obscure origin. *Gastrointest Endosc* 2004;59:492-498.
- Albert J, Schulbe R, Hahn W. Therapeutic consequences of capsule endoscopy in obscure intestinal bleeding; a multicenter outcome study, in *proceedings of the 4th International Conference on Capsule Endoscopy* 2005; Miami, Florida, USA.
- Appleyard M, Glukhovskiy A, Swain P. Wireless-capsule diagnostic endoscopy for recurrent small-bowel bleeding. *N Engl J Med* 2001; 344: 232-233.
- Appleyard MN, Walsh A. Capsule endoscopy for obscure gastro intestinal bleeding; a report of 100 consecutive cases and long term clinical outcome. *Gastrointest endosc* 2006; 63 Suppl: S154.
- Bandorski D., W. Irnich, M. Bruck, et al., Capsule endoscopy and cardiac pacemaker: Investigation for possible interference, *Endoscopy*, Vol. 40, pp. 36-39, 2008.
- Ben-Soussan E, Savoye G, Antonietti M, Ramirez S, Ducrotté P, Lerebours E. Is a 2-liter PEG preparation useful before capsule endoscopy? *J Clin Gastroenterol.* 2005;39:381-384.
- Bourreille A, Jarry M, D'Halluin PN, et al. Wireless capsule endoscopy versus ileocolonoscopy for the diagnosis of post-operative recurrence of Crohn's disease: a prospective study. *Gut* 2006;55:978-83.
- Bresci G, Parisi G, Bertoni M, Tumino E, Capria A. The role of video capsule endoscopy for evaluating obscure gastrointestinal bleeding: usefulness of early use. *J Gastroenterol* 2005; 40: 256-259.
- Carey EJ, Leighton JA, Heigh RI et al. A single-center experience of 260 consecutive patients undergoing capsule endoscopy for obscure gastrointestinal bleeding. *Am J Gastroenterol* 2007; 102: 89-95
- Caspari R, von Falkenhausen M, Krautmacher C et al. Comparison of capsule endoscopy and magnetic resonance imaging for the detection of polyps of the small intestine in patients with familial adenomatous polyposis or with Peutz-Jeghers' syndrome. *Endoscopy* 2004; 36: 1054-1059
- Cave D. Reading wireless video capsule endoscopy. *Gastrointest Endosc Clin North Am* 2004;14:17-24
- Cheifetz AS, Korenbluth AA, Legnani P et al. The risk of retention of the capsule endoscope in patients with known or suspected Crohn's disease. *Am J Gastroenterol* 2006; 101: 2218-2222
- Chong AK, Taylor A, Miller A, et al. Capsule endoscopy vs. push enteroscopy and enteroclysis in suspected small-bowel Crohn's disease. *Gastrointest Endosc* 2005;61:255-61.
- Compean et al. Impact of therapeutic interventions induced by capsule endoscopy on long term outcome in chronic obscure GI bleeding. *Gastroenterol Clin Biol* 2007;31:806-811.
- Cobrin GM, Pittman RH, Lewis BS. Increased diagnostic yield of small bowel tumors with capsule endoscopy. *Cancer* 2006; 107: 22-27
- Costamagna G, Shah SK, Riccioni ME, Foschia F, Mutignani M, Perri V, et al. A prospective trial comparing small bowel radiographs and video capsule endoscopy for suspected small bowel disease. *Gastroenterology* 2002;123(4):999-1005.
- Culliford A, Daly J, Diamond B, et al. The value of wireless capsule endoscopy in patients with complicated celiac disease. *Gastrointest Endosc* 2005;62:55-61.
- D'Halluin PN, Delvaux M, Lalalus MG, et al. Does the "Suspected Blood Indicator" improve the detection of bleeding lesions by capsule endoscopy? *Gastrointest Endosc* 2005;61:243-9

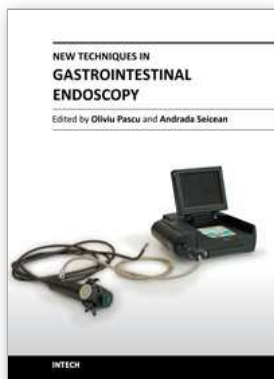
- Daas AY, Small MB, Pinkas H, Brady PG. Safety of conventional and wireless capsule endoscopy in patients supported with nonpulsatile axial flow Heart-Mate II left ventricular assist device. *Gastrointest Endosc.* 2008;68:379-382
- de Franchis R, Avgerinos A, Barkin J, Cave D, Filoche B; ICCE. ICCE consensus for bowel preparation and prokinetics. *Endoscopy.* 2005 Oct;37(10):1040-5] [Consensus Report on videocapsule endoscopy. 5th ICCE 2006 Miami Florida
- de Leusse A, Vahedi K, Edery J et al. Capsule endoscopy or push enteroscopy for first-line exploration of obscure gastrointestinal bleeding? *Gastroenterology* 2007; 132: 855-862
- Delvaux M, Fassler I, Gay G. Clinical usefulness of the endoscopic video capsule as the initial intestinal investigation in patients with obscure digestive bleeding: validation of a diagnostic strategy based on the patient outcome after 12 months. *Endoscopy* 2004;36:1067-1073.
- Delvaux M, Gay G. Capsule endoscopy: technique and indications. *Best Pract Res Clin Gastroenterol.* 2008;22:813-837
- Dirks M. H., F. Costea, and E. G. Seidman, Successful videocapsule endoscopy in patients with an abdominal cardiac pacemaker, *Endoscopy*, Vol. 40, pp. 73-75, 2008.
- Dubcenco E, Jeejeebhoy KN, Petroniene R, et al. Capsule endoscopy findings in patients with established and suspected small-bowel Crohn's disease: correlation with radiologic, endoscopic, and histologic findings. *Gastrointest Endosc* 2005;62:538-44.
- Dyer S, Standfield L, Tilden D, Mernagh P, Fitzgerald P. Assessment of the cost-effectiveness of M2A (TM) capsule endoscopy to inform public funding policy in Australia. *Proc One HTA Health Technol Assess Int Meet 1st 2004 Krakow Pol.* 2004; 1: 30.
- Eliakim R, Fischer D, Suissa A, Yassin K, Katz D, Guttman N, et al. Wireless capsule video endoscopy is a superior diagnostic tool in comparison to barium follow-through and computerized tomography in patients with suspected Crohn's disease. *Eur J Gastroenterol Hepatol* 2003;15(4):363-7.
- Eliakim R. Video Capsule Endoscopy of the Small Bowel. *Curr Opin Gastroenterol.* 2010;26(2):129-133
- Ell C, Remke S, May A, Helou L, Henrich R, Mayer G. The first prospective controlled trial comparing wireless capsule endoscopy with push enteroscopy in chronic gastrointestinal bleeding. *Endoscopy* 2002;34:685-689.
- Ersoy O, Sivri B, Arslan S, Batman F, Bayraktar Y. How much helpful is the capsule endoscopy for the diagnosis of small bowel lesions? *World J Gastroenterol* 2006; 12: 3906-3910.
- Fireman Z, Mahajna E, Broide E, et al. Diagnosing small bowel Crohn's disease with wireless capsule endoscopy. *Gut* 2003; 52: 390-2.
- Gal E, Geller A, Fraser G et al. Assessment and validation of the new capsule endoscopy Crohn's disease activity index. *Dig Dis Sci* 2008; 53: 1933-193
- Gay G, Delvaux M, Fassler I. Capsule endoscopy of the small bowel. Nancy (France): ALN Editions; 2006
- Ge ZZ, Hu YB, Xiao SD. Capsule endoscopy and push enteroscopy in the diagnosis of obscure gastrointestinal bleeding. *Chin Med J (Engl)* 2004;117:1045-1049.
- Ge ZZ, Hu YB, Xiao SD. Capsule endoscopy in diagnosis of small bowel Crohn's disease. *World J Gastroenterol* 2004; 10: 1349-52.
- Gerber J, MSc, MPhil ARCS, Ari Bergwerk, MD, David Fleischer, MD A capsule endoscopy guide for the practicing clinician: technology and troubleshooting *Gastrointestinal Endoscopy* 2007; 66(6) : 1188-1195
- Girelli CM, Porta P, Malacrida V et al. Clinical outcome of patients examined by capsule endoscopy for suspected small bowel Crohn's disease. *Dig Liv Dis* 2007; 39: 148-154

- Gong F, Swain CP, Mills TN. An endorobot for gastrointestinal endoscopy. *Gut* 1994;35(Suppl):52S
- Gravina, A.G.; Bozzi, R.; Romano, I.J.; Pezzullo, E.; Miranda, A.; Merola, M.G.; Romano, M.; Pezzull. Cardiac pacemaker and wireless capsule endoscopy interference: case report in a patient with gastric vascular ectasias. *Wireless Sensor Network*. Published: Mar 1, 2010
- Gupta R, Lakhtakia S, Tandan M, Banerjee R, Ramchandani M, Anuradha S, Ramji C, Rao GV, Pradeep R, Reddy DN. Capsule endoscopy in obscure gastrointestinal bleeding--an Indian experience. *Indian J Gastroenterol* 2006; 25: 188-190.
- Gupta R, Reddy DN. Capsule endoscopy: Current status in obscure gastrointestinal bleeding. *World J Gastroenterol* 2007; 13(34): 4551-4553.
- Guyomar Y., L. Vandeville, S. Heuls, et al., Interference between pacemaker and video capsule endoscopy, *Pacing and Clinical Electrophysiology*, Vol. 27, pp. 1329-1330, 2004
- Hadithi M, Heine GD, Jacobs MA et al. A prospective study comparing video capsule endoscopy with double balloon enteroscopy in patients with obscure gastrointestinal bleeding. *Am J Gastroenterol* 2006; 101: 52-57
- Hartmann D, Schilling D, Bolz G, Hahne M, Jakobs R, Siegel E, Weickert U, Adamek HE, Riemann JF. Capsule endoscopy versus push enteroscopy in patients with occult gastrointestinal bleeding. *Z Gastroenterol* 2003;41:377-382.
- Hartmann D, Schmidt H, Bolz G et al. A prospective two-center study comparing wireless capsule endoscopy with intraoperative enteroscopy in patients with obscure GI bleeding. *Gastrointest Endosc* 2005; 61: 826-832
- Herrerias JM, Caunedo A, Rodriguez-Tellez M, et al. Capsule endoscopy in patients with suspected Crohn's disease and negative endoscopy. *Endoscopy* 2003; 35: 564-8.
- Hoeroldt B.S., A.D. Hopper, M. Karmo, C. Salmon, D. Elphick, A. Ali, D.S. Sanders. Is formal training necessary for capsule endoscopy?: The largest gastroenterology trainee study with controls. *Digestive and Liver Disease*, 2008, 40(4): 298-302
- Hopper AD, Sidhu R, Hurlstone DP et al. Capsule endoscopy: an alternative to duodenal biopsy for the recognition of villous atrophy in coeliac disease? *Dig Liv Dis* 2007; 39: 140-145
- Iddan G, Meron G, Glukhovskiy A, Swain P. Wireless capsule endoscopy. *Nature* 2000;405:417
- Kamal A, Gerson LB. Jejunal diverticulosis diagnosed by double-balloon enteroscopy. *Gastrointest Endosc* 2006; 63: 864.
- Kamalaporn P, Cho S, Basset N et al. Double-balloon enteroscopy following capsule endoscopy in the management of obscure gastrointestinal bleeding: outcome of a combined approach. *Can J Gastroenterol* 2008; 22: 491-495
- Kameda N, Higuchi K, Shiba M et al. A prospective, single-blind trial comparing wireless capsule endoscopy and double-balloon enteroscopy in patients with obscure gastrointestinal bleeding. *J Gastroenterol* 2008; 43: 434-440
- Kim HM, YJ Kim, HJ Kim et al. A Pilot Study of Sequential Capsule Endoscopy Using MiroCam and PillCam SB Devices with Different Transmission Technologies. *Gut and Liver*, 2010, 4(2), 192-200
- Koulaouzidis A, Douglas S. Capsule endoscopy in clinical practice: concise up-to-date overview. *Clinical and Experimental Gastroenterology* 2009;2 111-116
- Koulaouzidis A, Pendlebury J, Douglas S, Plevris JN. Aspiration of video capsule; rare but potentially life threatening complication to include in your consent form. *Am J Gastroenterol*. 2009;104:1602-1603
- Kornbluth A, Colombel JF, Leighton JA, et al. ICCE Consensus for Inflammatory Bowel Disease. *Endoscopy* 2005;37:1051-4.

- Ladas SD, Triantafyllou K, Spada C, Riccioni ME, Rey JF, Niv Y, Delvaux M, de FR, Costamagna G. European Society of Gastrointestinal Endoscopy (ESGE): recommendations (2009) on clinical use of video capsule endoscopy to investigate small-bowel, esophageal and colonic diseases. *Endoscopy* 2010; 42:220-227
- Lai LH, Wong GI, Chow DK et al. Long term follow-up of patients with obscure gastrointestinal bleeding after negative capsule endoscopy. *Am J Gastroenterol* 2006; 101: 1224-1228
- Lapalus MG, Ben Soussan E, Saurin JC, et al; Société Française d'Endoscopie Digestive. Capsule endoscopy and bowel preparation with oral sodium phosphate: a prospective randomized controlled trial. *Gastrointest Endosc*. 2008;67:1091-1096.
- Leighton J. A., V. K. Sharma, K. Srivathsan, et al., "Safety of capsule endoscopy in patients with pacemakers," *Gastrointestinal Endoscopy*, Vol. 59, pp. 567, 2004.
- Leighton JA, Triester SL, Sharma VK. Capsule endoscopy: A meta-analysis for use with obscure gastrointestinal bleeding, and Crohn's disease. *Gastrointest Endosc* 2006;16:229-250.
- Lewis BS, Swain P. Capsule endoscopy in the evaluation of patients with suspected small intestinal bleeding: Results of a pilot study. *Gastrointest Endosc* 2002; 56: 349-353.
- Manning-Dimmitt LL, Dimmitt SG, Wilson GR. Diagnosis of gastrointestinal bleeding in adults. *Am Fam Physician* 2005; 71: 1339-46.
- Marmo R, Rotondano G, Piscopo R, et al. Capsule endoscopy versus enteroclysis in the detection of small-bowel involvement in Crohn's disease: a prospective trial. *Clin Gastroenterol Hepatol* 2005;3:772-6.
- Marmo R, Rotondano G, Rondonotti E et al. Capsule enteroscopy vs other diagnostic procedures in diagnosing obscure gastrointestinal bleeding: a cost-effectiveness study. *Eur J Gastroenterol Hepatol* 2007; 19: 535-542
- Mata A, Bordas JM, Feu F, Gines A, Pellise M, Fernandez-Esparrach G, Balaguer F, Pique JM, Llach J. Wireless capsule endoscopy in patients with obscure gastrointestinal bleeding: a comparative study with push enteroscopy. *Aliment Pharmacol Ther* 2004;20:189-194.
- Mata A, Llach J, Castells A et al. A prospective trial comparing wireless capsule endoscopy and barium contrast series for small-bowel surveillance in hereditary GI polyposis syndromes. *Gastrointest Endosc* 2005; 61: 721-725
- Mehdizadeh S, Ross A, Gerson L et al. What is the learning curve associated with double balloon enteroscopy? Technical details and early experience in 6 U.S. tertiary care centers. *Gastrointest Endosc* 2006; 64: 740-750
- Mehdizadeh S, Chen G, Enayati PJ et al. Diagnostic yield of capsule endoscopy in ulcerative colitis and inflammatory bowel disease of unspecific type. *Endoscopy* 2008; 40: 30-35
- Melmed Gil Y., Simon K. Lo. Capsule Endoscopy: Practical Applications. *Clin Gastro and Hepato* 2005;3:411-422
- Murray JA, Rubio-Tapia A, VanDyke CT et al. Mucosal atrophy in celiac disease: extent of involvement, correlation with clinical presentation and response to treatment. *Clin Gastroenterol Hepatol* 2008; 6: 186- 193
- Mylonaki M, Fritscher-Ravens A, Swain P. Wireless capsule endoscopy: a comparison with push enteroscopy in patients with gastroscopy and colonoscopy negative gastrointestinal bleeding. *Gut* 2003;52:1122-1126
- Nakamura M, Niwa Y, Ohmiya N et al. Preliminary comparison of capsule endoscopy and double-balloon enteroscopy in patients with suspected small-bowel bleeding. *Endoscopy* 2006; 38: 59-66

- Neu B, Ell C, May A, Schmid E, Riemann JF, Hagenmuller F, Keuchel M, Soehendra N, Seitz U, Meining A, Rosch T. Capsule endoscopy versus standard tests in influencing management of obscure digestive bleeding: results from a German multicenter trial. *Am J Gastroenterol* 2005;100:1736-1742.
- Ning Dai MD, Christoph Gubler MD, Peter Hengstler et al Improved capsule endoscopy after bowel preparation *Gastroint Endosc.* 2005; 61(1):28-31
- Niv Y, Niv G. Capsule endoscopy: role of bowel preparation in successful visualization. *Scand J Gastroenterol* 2004;39:1005-1009
- Oradei M, Calandriello M, Riccioni ME, Pirozzi GA, Costamagna G. Cost-effectiveness of video capsule endoscopy for diagnosis of suspected small bowel disease. *Ital J Public Health.* 2005; 2: 272.
- Payeras G., J. Piqueras, V. J. Morena, et al., Effects of capsule endoscopy on cardiac pacemakers, *Endoscopy*, Vol. 37, pp. 1181-1185, 2005.
- Pennazio M, Eisen G, Goldfarb N. ICCE consensus for obscure gastrointestinal bleeding. *Endoscopy* 2005; 37: 1046-1050.
- Pennazio M, Santucci R, Rondonotti E, Abbiati C, Beccari G, Rossini FP, De Franchis R. Outcome of patients with obscure gastrointestinal bleeding after capsule endoscopy: report of 100 consecutive cases. *Gastroenterology* 2004; 126: 643-653.
- Pons Beltran, V, Nos P, Bastida G et al. Evaluation of postsurgical recurrence in Crohn's disease: a new indication for capsule endoscopy. *Gastrointest Endosc* 2007; 66: 533-540
- Postgate A, Tekkis P, Patterson N, Fitzpatrick A, Bassett P, Fraser C. Are bowel purgatives and prokinetics useful for small bowel capsule endoscopy? A prospective randomized controlled study. *Gastrointest Endosc.* 2009;69(6):1120-1128
- Qureshi WA, Willingham F, Opekun A, et al. Localizing the lesion in capsule endoscopy: factors determining accuracy [abstract]. *4th International Conference on Capsule Endoscopy, March 7-8, 2005.* Program and Abstracts. p. 151.
- Rastogi A, Schoen RE, Slivka A. Diagnostic yield and clinical outcomes of capsule endoscopy. *Gastrointest Endosc* 2004; 60: 959-964.
- Rokkas T, Papaxoinis K, Triantafyllou K, Pistiolas D, Ladas SD. Does purgative preparation influence the diagnostic yield of small bowel video capsule endoscopy? A metaanalysis. *Am J Gastroenterol* 2009; 104: 219-227
- Rondonotti E, Herrerias JM, Pennazio M, et al. Complications, limitations, and failures of capsule endoscopy: a review of 733 cases. *Gastrointest Endosc.* 2005;62:712-716.
- Rondonotti E, Spada C, Cave D et al. Video capsule enteroscopy in the diagnosis of celiac disease: a multicenter study. *Am J Gastroenterol* 2007; 102: 1624-1631
- Rondonotti E, Pennazio M, Toth E et al. Small-bowel neoplasms in patients undergoing video capsule endoscopy: a multicenter European study. *Endoscopy* 2008; 40: 488-495
- Saperas E, Dot J, Videla S et al. Capsule endoscopy versus computed tomographic or standard angiography for the diagnosis of obscure gastrointestinal bleeding. *Am J Gastroenterol* 2007; 102: 731-737
- Saperas E, Dot J, Videla S et al. Capsule endoscopy versus computed tomographic or standard angiography for the diagnosis of obscure gastrointestinal bleeding. *Am J Gastroenterol* 2007; 102: 731-737.
- Saurin JC, Delvaux M, Gaudin JL, Fassler I, Villarejo J, Vahedi K, Bitoun A, Canard JM, Souquet JC, Ponchon T, Florent C, Gay G. Diagnostic value of endoscopic capsule in patients with obscure digestive bleeding: blinded comparison with video push-enteroscopy. *Endoscopy* 2003;35:576-584.

- Sidhu, Reena MRCP; Sanders, David S. MD, FRCP, FACC; Kapur, Kapil FRCP; Marshall, Laura RGN; Hurlstone, David P. MD, MRCP; McAlindon, Mark E. Capsule Endoscopy: Is There a Role for Nurses as Physician Extenders? *Gastroenterology Nursing*. 2007, 30(1): 45-50
- Sidhu R, Sanders DS, Morris AJ, McAlindon ME, Guidelines on small bowel enteroscopy and capsule endoscopy in adults. *Gut* 2008;57:125-136
- Signorelli C, Villa F, Rondonotti E, et al. Sensitivity and specificity of the suspected blood identification system in videocapsule endoscopy. *Endoscopy* 2005;37:1170-3
- Solem CA, Loftus EV Jr, Fletcher JG et al. Small-bowel imaging in Crohn's disease: a prospective, blinded, 4-way comparison trial. *Gastrointest Endosc* 2008; 68: 255-266
- Souquet JC, Bellecoste M, Belbouab S, et al. Prospective evaluation of the automatic localization system of the videocapsule during small intestine exploration [abstract]. *4th International Conference on Capsule Endoscopy, March 7-8, 2005. Program and Abstracts*. 2005. *Program and Abstracts*. p. 237
- Swain CP, Gong F, Mills TN. Wireless transmission of a color television moving image from the stomach using a miniature CCD camera, light source and microwave transmitter [abstract]. *Gut* 1996;39:A26
- Swain P. Wireless capsule endoscopy. *Gut* 2003; 52:4:48-50
- Toth E, Fork F, Almquist P, et al. Should capsule endoscopy be the first line imaging examination in patients with suspected small bowel Crohn's disease ? (abstract) *International Conference on Capsule Endoscopy Miami 2004*
- Triantafyllou K. Can we improve the diagnostic yield of small bowel videocapsule endoscopy? *World J Gastrointest Endosc* 2010 May 16; 2(5): 143-146.
- Triester SL, Leighton JA, Leontiadis GI et al. A meta-analysis of the yield of capsule endoscopy compared to other diagnostic modalities in patients with obscure gastrointestinal bleeding. *Am J Gastroenterol* 2005; 100: 2407-2418
- Triester SL, Leighton JA, Leontiadis GI et al. A meta-analysis of the yield of capsule endoscopy compared to other diagnostic modalities in patients with non-stricturing small bowel Crohn's disease. *Am J Gastroenterol* 2006; 101: 954-964
- Urbain D, De Looze D, Demedts I et al. Video capsule endoscopy in small-bowel malignancy: a multicenter Belgian study. *Endoscopy* 2006; 38: 408-411
- Van Gossum A, Hittelet A, Schmit A, Francois E, Deviere J. A prospective comparative study of push and wireless-capsule enteroscopy in patients with obscure digestive bleeding. *Acta Gastroenterol Belg* 2003;66:199-205.
- Vere C., F. Sima, F. Țăpu, T. Ciurea. Videocapsula endoscopică și enteroscopia cu balon, metode moderne de explorare a intestinului subțire. *Craiova Medicală*, Vol 10, Nr 1, 2008, 57-63
- Viazis N, Sgouros S, Papaxoinis K, et al. Bowel preparation increases the diagnostic yield of capsule endoscopy: a prospective, randomized, controlled study. *Gastrointest Endosc* 2004;60:534-538
- Westerhof J, J J Koornstra, RK Weersma. Can we reduce capsule endoscopy reading times? *Gastrointest Endosc* 2009; 69(3): 497-502



New Techniques in Gastrointestinal Endoscopy

Edited by Prof. Oliviu Pascu

ISBN 978-953-307-777-2

Hard cover, 310 pages

Publisher InTech

Published online 30, September, 2011

Published in print edition September, 2011

As result of progress, endoscopy has become more complex, using more sophisticated devices and has claimed a special form. In this moment, the gastroenterologist performing endoscopy has to be an expert in macroscopic view of the lesions in the gut, with good skills for using standard endoscopes, with good experience in ultrasound (for performing endoscopic ultrasound), with pathology experience for confocal examination. It is compulsory to get experience and to have patience and attention for the follow-up of thousands of images transmitted during capsule endoscopy or to have knowledge in physics necessary for autofluorescence imaging endoscopy. Therefore, the idea of an endoscopist has changed. Examinations mentioned need a special formation, a superior level of instruction, accessible to those who have already gained enough experience in basic diagnostic endoscopy. This is the reason for what these new issues of endoscopy are presented in this book of New techniques in Gastrointestinal Endoscopy.

How to reference

In order to correctly reference this scholarly work, feel free to copy and paste the following:

Cristin Constantin Vere, Costin Teodor Streba, Ion Rogoveanu and Alin Gabriel Ionescu (2011). Videocapsule Endoscopy of the Small Bowel, New Techniques in Gastrointestinal Endoscopy, Prof. Oliviu Pascu (Ed.), ISBN: 978-953-307-777-2, InTech, Available from: <http://www.intechopen.com/books/new-techniques-in-gastrointestinal-endoscopy/videocapsule-endoscopy-of-the-small-bowel>

INTECH

open science | open minds

InTech Europe

University Campus STeP Ri
Slavka Krautzeka 83/A
51000 Rijeka, Croatia
Phone: +385 (51) 770 447
Fax: +385 (51) 686 166
www.intechopen.com

InTech China

Unit 405, Office Block, Hotel Equatorial Shanghai
No.65, Yan An Road (West), Shanghai, 200040, China
中国上海市延安西路65号上海国际贵都大饭店办公楼405单元
Phone: +86-21-62489820
Fax: +86-21-62489821

© 2011 The Author(s). Licensee IntechOpen. This chapter is distributed under the terms of the [Creative Commons Attribution-NonCommercial-ShareAlike-3.0 License](#), which permits use, distribution and reproduction for non-commercial purposes, provided the original is properly cited and derivative works building on this content are distributed under the same license.