

Spectral-Domain Optical Coherence Tomography Findings in Neurofibromatosis Type 2

Vanessa Waisberg,¹ Luiz Oswaldo Carneiro Rodrigues,² Márcio Bittar Nehemy,¹ Maria Frasson,¹ and Débora Marques de Miranda³

¹Department of Ophthalmology, Clinical Hospital of Federal University of Minas Gerais, Belo Horizonte (MG), Brazil

²Department of Clinical Medicine and Neurofibromatosis Reference Center, Clinical Hospital of Federal University of Minas Gerais, Belo Horizonte (MG), Brazil

³Department of Pediatrics and INCT Molecular Medicine, Clinical Hospital of Federal University of Minas Gerais, Belo Horizonte (MG), Brazil

Correspondence: Vanessa Waisberg, Avenida Brasil, 691/401, Belo Horizonte, MG, 30140-000, Brazil; vanessawaisberg@hotmail.com.

Submitted: December 14, 2015

Accepted: May 14, 2016

Citation: Waisberg V, Rodrigues LOC, Nehemy MB, Frasson M, de Miranda DM. Spectral-domain optical coherence tomography findings in neurofibromatosis type 2. *Invest Ophthalmol Vis Sci*. 2016;57:OCT262–OCT267. DOI:10.1167/iovs.15-18919

PURPOSE. Neurofibromatosis type 2 (NF2) is an autosomal-dominant disease, characterized by bilateral vestibular schwannomas, multiple central nervous system (CNS) tumors, skin tumors, and juvenile cataract. The present study assessed retinal abnormalities using spectral-domain optical coherence tomography (SD-OCT) in a case series of NF2 patients.

METHODS. Nine NF2 patients from the neurofibromatosis outpatient reference center of the Federal University of Minas Gerais, in Brazil, were submitted to a complete anamnesis and a detailed ophthalmic evaluation, including SD-OCT, to detect retinal lesions.

RESULTS. Of the nine NF2 patients evaluated, five had an early onset (<20 years) of NF2, and four patients had a late onset (>20 years) of symptoms. SD-OCT scans revealed retinal abnormalities in every patient with early onset (EOS) and in two patients with late onset (LOS) of the disease. In the EOS group, SD-OCT scans revealed flame-shaped epiretinal membranes (ERM) with peculiar characteristics in four eyes of three patients. Two patients had fine undulations of the inner retinal surface with a subtle ERM. Retinal hamartomas were present in four eyes of three patients with EOS; in two eyes, they were subclinical and were detected only by SD-OCT scans. In two patients with LOS and one patient with EOS, SD-OCT scans revealed retinal tufts of a nerve fiber layer.

CONCLUSIONS. SD-OCT revealed ERM in most patients with NF2, therefore it may be a valuable exam for evaluating NF2 patients. Epiretinal membranes in NF2 has unique features, distinguishing it from idiopathic ERM or membranes associated with other diseases. We suggest that flame-shaped ERM seems to be specific for NF2 and that ERM can be considered as an important diagnostic sign of NF2.

Keywords: neurofibromatosis type 2, optical coherence tomography, retina, vestibular schwannoma, epiretinal membrane

Neurofibromatosis comprises at least three distinct disorders caused by mutations in different genes¹ as follows: neurofibromatosis 1 (NF1) is caused by mutations that inactivate the neurofibromin gene on chromosome 17q²; neurofibromatosis 2 (NF2) is caused by inactivating mutations of the merlin gene on chromosome 22q^{3,4}; and Schwannomatosis, is caused by germline mutations in the *SMARCB1* (or *INI1*) gene.⁵

Neurofibromatosis 2 is an autosomal-dominant disease, which is characterized by bilateral vestibular schwannomas, multiple central nervous system (CNS) tumors, skin tumors, and juvenile cataract.^{6,7} Its estimated incidence lies between 1 in 33,000⁸ live births and 1 in 87,410 live births.⁹

The following two clinical subtypes have been proposed: (1) the severe subtype, or Wishart subtype, which usually presents an age onset at approximately 20 and are seen to enhance CNS tumors formations in addition to bilateral vestibular schwannoma, exhibiting rapid clinical progression,^{7,10,11} and (2) the mild subtype, or Gardner subtype, which often lacks symptoms within the third decade of the patient's life, and presents with

few tumors other than vestibular schwannoma, which has a relatively benign clinical course.^{7,10,12} Although NF2 is inherited in an autosomal-dominant manner, approximately half of the cases in affected individuals are caused by sporadic mutation, and there is a high rate of mosaicism.^{13,14}

A well-defined spectrum of ocular features is associated with NF2. Ocular abnormalities associated with NF2 are posterior subcapsular/capsular or cortical lenticular opacities, RPE hamartomas, retinal hamartomas, epiretinal membranes (ERM), paralytic strabismus, and optic nerve sheath meningiomas.^{15–17}

Optical coherence tomography (OCT) is a noninvasive diagnostic technique that renders an in vivo cross-sectional view of the retina. SD-OCT technology uses infrared light to produce images of the retina with very high resolution (<7 μm).

Optical coherence tomography and near-infrared reflectance (NIR) have been shown to be valuable tools to evaluate NF1 patients. Choroidal nodules detected by NIR and SD-OCT have high specificity as diagnostic indicators of NF1.^{18,19}



TABLE 1. Patient Demographics

Patient N°	Sex	Symptom Duration, y	Age at Last Visit, y	Delay in Diagnosis, y
1	M	3	50	0
2	F	3	33	0
3*	M	20	28	8
4*	M	17	19	15
5*	M	8	14	3
6	F	12	37	12
7*	F	16	32	1
8*	F	6	24	1
9	F	21	48	14

* Patients with early onset.

Evaluation of peripapillary RNFL thickness has been proposed as a noninvasive testing method to detect early signs of optic pathway gliomas in children with NF1.^{20,21} There is little information about OCT in NF2, probably because NF2 is much rarer than NF1. There should be more studies on the prevalence, significance, relevance, and impact of ophthalmologic findings on NF2. Epiretinal membranes is a semitranslucent, avascular, fibrocellular membrane on the inner retinal surface that is caused by proliferating changes at the vitreoretinal interface. Epiretinal membranes can be idiopathic or secondary to a wide variety of intraocular conditions. Idiopathic ERM is most common in patients over the age of fifty. Epiretinal membranes have been described as an NF2 ocular finding since 1992, and its incidence varies among authors from 30% to 80%.^{15,16,22-24} Sisk²⁵ associated ERM with a severe phenotype of NF2. The gold standard exam for diagnosing and analyzing ERM is SD-OCT. Scheffer²⁶ described OCT characteristics of ERM in three patients with NF2. This description reported an ERM with unique features, which were described as several cell layers thick with curled edges stretching into the vitreoretinal interface. Considering that SD-OCT is a noninvasive and easily performed exam, the present study aims to evaluate retinal abnormalities using SD-OCT in a group of NF2 patients to characterize the frequency and relevance of ERM for NF2.

METHODS

Patients

Between February 2014 and June 2015, we evaluated nine patients with NF2. Patients were clinically examined in a neurofibromatosis outpatient reference center of the Federal University of Minas Gerais, Belo Horizonte, Brazil. The NF2 diagnosis was confirmed by neuroimaging. None of the nine NF2 patients were parentally related. Nine age- and sex-matching controls with no history of neurologic or ophthalmologic disorders were included.

Eye examination was performed in 18 NF2 eyes, and it included measurement of the visual acuity and biomicroscopy before and after pupillary dilatation, with special attention to the presence of iris hamartomas and lens opacities, dilated fundus examination, color fundus photography, infrared photography, fundus autofluorescence, and SD-OCT. SD-OCT was accomplished in 17 NF2 eyes; in one eye, OCT scans were not performed, due to a dense subcapsular lens opacity. Optical coherence tomography examinations were performed by means of Spectralis HRA + OCT (Heidelberg Eye Explorer Version 1.9.10.0 - Acquisition Software Version: 6.0.11.0;

Heidelberg Engineering, Heidelberg, Germany). Acquisition protocols included at least one cross-hair scan, a 20° × 15° 19 B-scans macular cube, a 20° × 15° 19 B-scans macular cube with enhanced-depth imaging (EDI) and mode with additional horizontal and vertical single lines or cube, to cover any lesion detected by clinical examination or fundus photography.

The study was approved by the ethics committee of the Clinical Hospital of the Federal University of Minas Gerais and followed the principles of the Declaration of Helsinki.

OCT Image Analysis

Two trained ophthalmologists independently analyzed the images for qualitative OCT variables, and quantitative measurements of anatomical features and a senior masked investigator provided arbitration in cases of disagreement.

The images were evaluated for the presence of ERM, type of ERM, presence of vitreous macular adhesion (VMA), foveal deformation, retinal folds or undulations, internal limiting membrane (ILM) disruption, ellipsoid zone disruption (EZD), central macular thickness (CMT), and retinal nerve fiber layer (RNFL) thickness. The inner circle of 1-mm radius of Early Treatment Diabetic Retinopathy Study map was defined as CMT.

RESULTS

Demographics

Demographic data are shown in Table 1. The overall delay between the onset of symptoms and diagnosis of NF2 averaged 6.7 years. Of the nine patients, five had an early onset (EOS) of NF2 (<20 years), and the delay between the first symptoms and diagnosis in this group was an average of 7.8 years (range, 1-18 years; Table 1). The initial symptoms of these five patients were unspecific symptoms, such as convulsion, strabismus, chest pain, inferior limb paresis, and café au lait spots. Late onset (LOS) of NF2 (>20 years) was observed in four of nine patients, and the delay between the first symptoms and diagnosis averaged 5.5 years (range, 0-14 years). The initial symptoms of these four patients were also unspecific, including inferior limbs paresis, facial palsy, facial pain, and cervical pain.

Specific NF2 Ocular Findings

Neurofibromatosis 2-specific ocular findings were observed in eight of nine patients, all five patients in the EOS group, and three in the LOS group. Cataracts were noted in five of nine patients (3 with EOS and 2 with LOS). Cataracts were visually impacting four eyes of three patients. One patient in the EOS group had chronic-appearing retinal detachment and retinal hamartoma in the right eye. Epiretinal membranes were noted in all five patients in the EOS group; three patients had thick ERM with peculiar characteristics on SD-OCT scans, and two patients had subtle ERM with fine undulations on the inner retinal surface. Retinal hamartomas were noted in four eyes of three patients in the EOS group. In both eyes of patient seven retinal hamartomas were subclinical, detected only by SD-OCT. All patients with epiretinal membrane and retinal hamartoma were in the early onset group. Two patients with LOS had subtle retinal abnormalities that were detected exclusively by SD-OCT; these abnormalities were small elevations of RNFL that were compatible with RNFL tufts. Strabismus was noted in two patients in the EOS group. Patients with an early onset had more NF2-specific ocular findings (Table 2).

TABLE 2. Incidence of Ocular Specific Findings in Patients With Neurofibromatosis Type 2

Ocular Finding	All 9 Patients			Early Onset (n = 5)			Late Onset (n = 4)		
	Eyes	Patients	% of n = 9	Eyes	Patients	% of n = 5	Eyes	Patients	% of n = 4
Cataract	8	5	55.5	6	3	60	2	2	50
ERM	7	5	55.5	7	5	100	0	0	0
Hamartoma	4	3	33.3	4	3	60	0	0	0
Strabismus	2	2	22.2	2	2	40	0	0	0

Other Ophthalmologic Findings

Nonspecific ophthalmologic findings were detected in four patients. Exposure keratopathy was found in three patients (2 with EOS and 1 with LOS), caruncula nevus in one patient in the LOS group, optic disc edema in three eyes of two patients in the EOS group, and optic nerve atrophy in one eye of a patient in the EOS group.

Optical Coherence Tomography

Quantitative Analysis. The mean central macular thickness (CMT) was $269 \pm 35 \mu\text{m}$ in control eyes and $311 \pm 83 \mu\text{m}$ in all NF2 eyes. In the EOS eyes, CMT was $352 \pm 101 \mu\text{m}$; in the LOS eyes, CMT was $268 \pm 17 \mu\text{m}$. The total macular volume (TMV) was $8.79 \pm 0.18 \text{ mm}^3$ in control eyes and $8.66 \pm 0.78 \text{ mm}^3$ in all NF2 eyes. In the EOS eyes, the TMV was $8.68 \pm 1.12 \text{ mm}^3$; in the LOS eyes, the TMV was $8.64 \pm 0.24 \text{ mm}^3$. The SD shows great variability in the thickness and volume measurements in the EOS eyes (Table 3). The mean peripapillary RNFL thickness in EOS patients was $153 \pm 104 \mu\text{m}$ in the superior sector, $97 \pm 77 \mu\text{m}$ in the nasal sector, $170 \pm 125 \mu\text{m}$ in the inferior sector and $64 \pm 18 \mu\text{m}$ in the temporal sector. In LOS patients the mean peripapillary RNFL thickness was $144 \pm 14 \mu\text{m}$ in the superior sector, $70 \pm 13 \mu\text{m}$ in the nasal sector, $139 \pm 12 \mu\text{m}$ in the inferior sector and $75 \pm 8 \mu\text{m}$ in the temporal sector. The great variability in peripapillary thickness observed in EOS group was related to optic nerve atrophy in one eye and optic disc edema in tree eyes.

Qualitative Analysis. SD-OCT scans revealed retinal abnormalities in all patients with EOS and in two patients

with LOS. A thick and dense ERM at the macula, with a flame-shaped appearance extending into the vitreous, was observed in four eyes of three patients with EOS (Fig. 1). In three eyes with a flame-shaped ERM, there was loss of foveal contour. These ERMs were not visually significant, despite the marked retinal thickening and foveal deformation. Undulations of the inner retinal surface with a subtle ERM were observed in three eyes of two patients with EOS (Fig. 2). In two eyes of two patients with LOS and one eye of a patient with EOS, SD-OCT scans revealed small focal elevations at the retina surface (Fig. 3). Choroidal abnormalities were detected in two eyes of two patients with EOS. One eye presented with a palcoid choroidal nodule and the other eye presented with a localized reduction in choroidal thickness at the perifoveal region. Qualitative abnormalities were not observed in control subjects.

The SD-OCT of four retinal hamartomas in four eyes revealed tumors with different aspects. In both eyes of a patient, tumors had a highly internally reflective and translucent mass with clear delineation of the external retinal layers and RPE. These endophytic tumors seem to be confined to the RNFL and ganglion cell layer (Figs. 4A, 4B). Two hamartomas in another two patients were associated with ERM on their surface and displayed retinal disorganization of multiple layers with disruption of the ellipsoid zone (Figs. 4C, 4D). At the macula, the ellipsoid zone was preserved in all eyes, the VMA was present in all eyes, and no eyes presented cystoid macular edema (Table 3). It is interesting to note that most of the findings were present in only one eye from each patient; with the exceptions of patients 7 and 8. The first of these patients presented bilateral subclinical retinal hamartomas and subtle ERM with undulations of the inner retinal surface and the

TABLE 3. Spectral-Domain Optical Coherence Tomography: Features in Neurofibromatosis Type 2 Eyes

Patients	CMT	TMV	Flame-Shaped ERM	Subtle ERM	RNFL Elevation	Retinal Hamartoma	EZD	VMA
1-OD	253 μm	8.57 mm^3	-	-	-	-	-	+
1-OS	251 μm	8.75 mm^3	-	-	+	-	-	+
2-OD	261 μm	8.32 mm^3	-	-	+	-	-	+
2-OS	249 μm	8.33 mm^3	-	-	-	-	-	+
3-OD	RD	RD	RD	RD	RD	+	RD	RD
3-OS	267 μm	7.97 mm^3	-	+	-	-	-	+
4-OD	CAT	CAT	CAT	CAT	CAT	CAT	CAT	CAT
4-OS	555 μm	9.79 mm^3	+	-	-	-	-	+
5-OD	443 μm	9.59 mm^3	+	-	+	-	-	+
5-OS	332 μm	9.19 mm^3	-	-	-	-	-	+
6-OD	286 μm	8.91 mm^3	-	-	-	-	-	+
6-OS	284 μm	8.95 mm^3	-	-	-	-	-	+
7-OD	283 μm	6.35 mm^3	-	+	-	+	-	+
7-OS	320 μm	8.75 mm^3	-	+	-	+	-	+
8-OD	364 μm	9.44 mm^3	+	-	-	-	-	+
8-OS	257 μm	8.41 mm^3	+	-	-	+	+	+
9-OD	291 μm	8.77 mm^3	-	-	-	-	-	+
9-OS	275 μm	8.53 mm^3	-	-	-	-	-	+

VMA, vitreomacular adhesion; CME, cystoid macula edema; RD, retinal detachment; CAT, cataract.

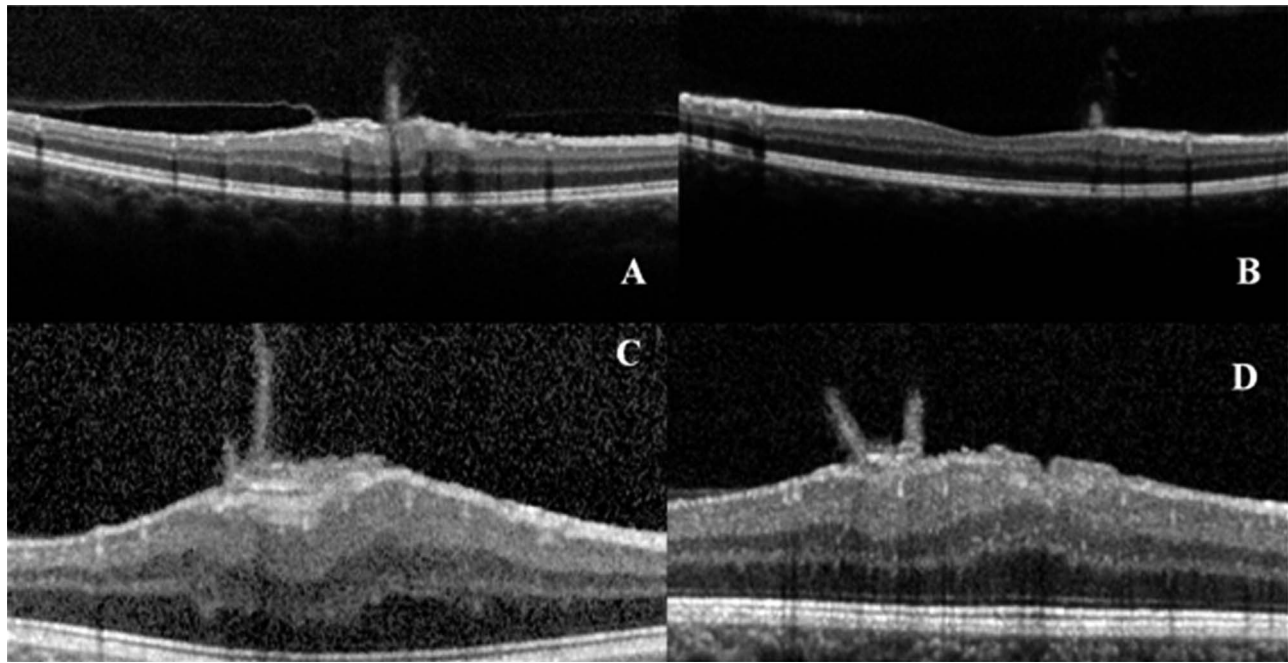


FIGURE 1. (A) SD-OCT of the right eye of patient 8 showing an ERM with flame-shaped appearance extending to the vitreous. There is mild disorganization of the internal retinal layers and vitreous partial detachment with VMA. (B) SD-OCT of the left eye showing a flame-shaped ERM with preservation of the retinal contour and microarchitecture. (C) SD-OCT of the left eye of case 4 showing a several-layer ERM extending into the vitreous and evident retinal thickening with preservation of the ellipsoid zone. (D) SD-OCT demonstrating a thick ERM with a flame shape appearance extending into the vitreous, which is similar to case 4. There are folds on the retina surface and marked retinal thickening. The ellipsoid zone is preserved.

second patient was observed to have bilateral flame-shaped ERM.

DISCUSSION

Neurofibromatosis 2 is a rare disease with a lifelong potential for unpredictable tumor growth. Early diagnosis and comprehensive follow-up are challenging. Most of the ophthalmic findings in NF2 are probably congenital, but they may become symptomatic over time.^{15,27} Ocular NF2-specific findings usually appear before neurological symptoms and hearing loss; therefore, they are extremely useful in early diagnosis, allowing for better planning of therapy in young patients with NF2.²⁷⁻²⁹

SD-OCT scans revealed retinal abnormalities in seven of nine patients with NF2. All patients with retinal abnormalities on SD-OCT had bilateral vestibular schwannomas. It is possible that the two patients with unilateral vestibular schwannoma and without retina abnormalities were mosaics, which occurs in approximately 25% of NF2 patients.^{13,14} Increase in CMT found in EOS group was probably due to traction effects of the ERM in three patients. One patient with EOS presented a perifoveal hamartoma that caused foveal deformation and

increased in CMT in both eyes. Common features among our patients included flame-shaped ERM, retinal undulations with a subtle ERM, focal elevations of RNFL, and retinal hamartomas. Two of our patient's lesions were subclinical retinal hamartomas that were only detected by SD-OCT scans. The flame-shaped appearance on OCT scans of ERM in four eyes of three patients with an early onset of NF2 were sufficiently distinct, allowing the establishment of a pattern. Scheffler et al.²⁶ described the OCT characteristics of a peculiar ERM in three NF2 patients with a severe phenotype. In one of the cases described, the unique OCT findings were the sole reasons the diagnosis of NF2 was established.

McLaughlin et al.³⁰ described ocular histopathologic findings in a 32-year-old woman who died from NF2 complications. They found a thin ERM in the right eye consisting of spindled and cuboidal cells, consistent with a glial origin. In the left eye, they found a thick ERM consisting of cords that are predominantly cuboidal cells, which are consistent with Müller cells and an astrocyte origin. Han et al.³¹ described the histologic features of an ERM that was surgically removed in a 2-year-old child. They found a highly cellular membrane with up to four layers of cells of indeterminate origin and speculated

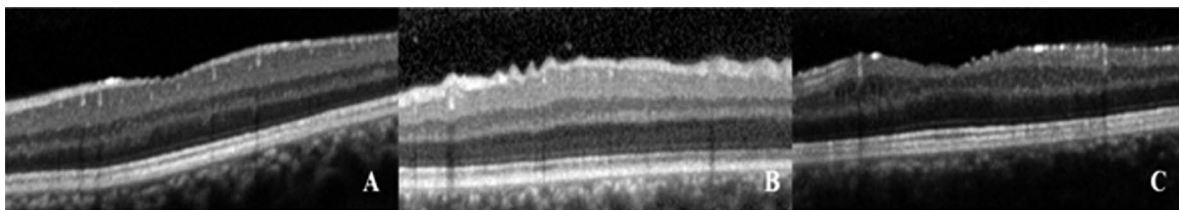


FIGURE 2. (A) SD-OCT of the left eye of patient 3 showing fine undulations on the retinal surface, with preservation of the retinal microarchitecture and with a subtle ERM. (B) SD-OCT of the left eye of patient 7 showing speculated undulations of the retina surface without an evident ERM. The ellipsoid zone is preserved. (C) SD-OCT of the right eye of patient 7 showing fine undulations of the retinal surface, similar to patient 3.

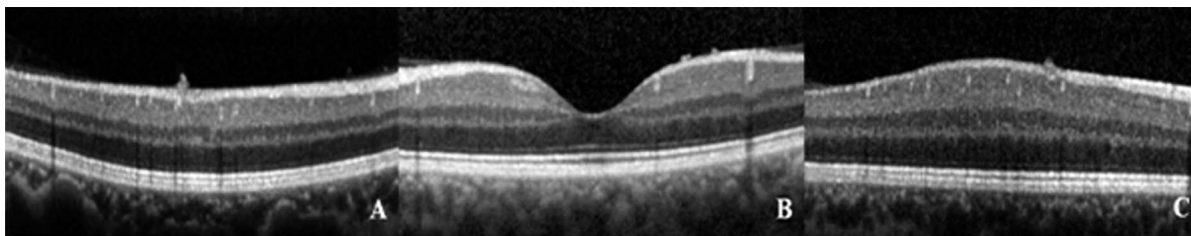


FIGURE 3. (A) SD-OCT of case 2 showing disruption of ILM with a focal elevation of RNFL and preservation of retinal microarchitecture. (B) SD-OCT of case 1 showing small focal elevations at the left eye fovea. The foveal contour and ellipsoid zone are preserved. (C) SD-OCT of case 5 showing a small focal elevation of RNFL similar to cases 2 and 1.

that the NF2 ERM is hamartomatous in origin. Chan et al.³² described the histopathologic and immunohistochemistry findings of seven NF2 eyes, and they found ERM and retinal hamartomas in all eyes. They also found retinal tufts arising from RNFL in four eyes of three patients. Some of our patient's images show remarkable similarity to the RNFL tufts found in histopathologic sections of NF2 eyes that were previously described by Chan. To the best of our knowledge, this is the first description of SD-OCT features of such lesions.

Epiretinal membranes associated with NF2 may be directly related to dysplastic Müller cells. Müller cells are the predominant glial element of the retina. They provide the mechanical support to the retina and produce the basement membrane material that forms the ILM. Experimental models of cultured sensory retina suggest that Müller cells might contribute to the development of a cellular membrane in case of ILM disruption.³³ Owing to the abnormal adherens junctions, Müller cells that have lost their wild-type NF2 allele may not be able to elongate and establish radial polarity, leading to epiretinal accumulation.³¹ Müller cells, like the other main cell types affected in NF2, are glial cells with epithelial features, suggesting that this subset of glial cells is particularly sensitive to NF2 loss. Neurofibromatosis 2 hamartomas result

from mutations in the cytoskeletal protein encoded in the long arm of chromosome 22, which functions as a tumor suppressor.³⁴ It has been suggested that NF2-ERM and retinal hamartomas represent different aspects of the same pathological process.³² It is possible that the retinal tufts and undulations of the retinal surface found in some of our patients are also related to dysplastic Müller cells.

In conclusion, our study showed that SD-OCT depicted retina and vitreous alterations in most patients with NF2, and it is a valuable tool for evaluating these patients. Epiretinal membranes and subclinical hamartomas that are evident on SD-OCT can be difficult to identify with the fundus exam. Epiretinal membrane in NF2 has unique features that distinguish it from idiopathic ERM or membranes associated with other diseases. Therefore, the detection of this peculiar ERM in a young patient is very suggestive of NF2. The NF2 diagnostic criteria may be absent at the initial clinical presentation in children, and it is probably the main reason for the delayed diagnosis in the NF2 EOS group. Although this paper reports a small number of patients flame-shaped ERM appears to be specific for NF2, and its inclusion in the classical diagnostic criteria could be very useful.

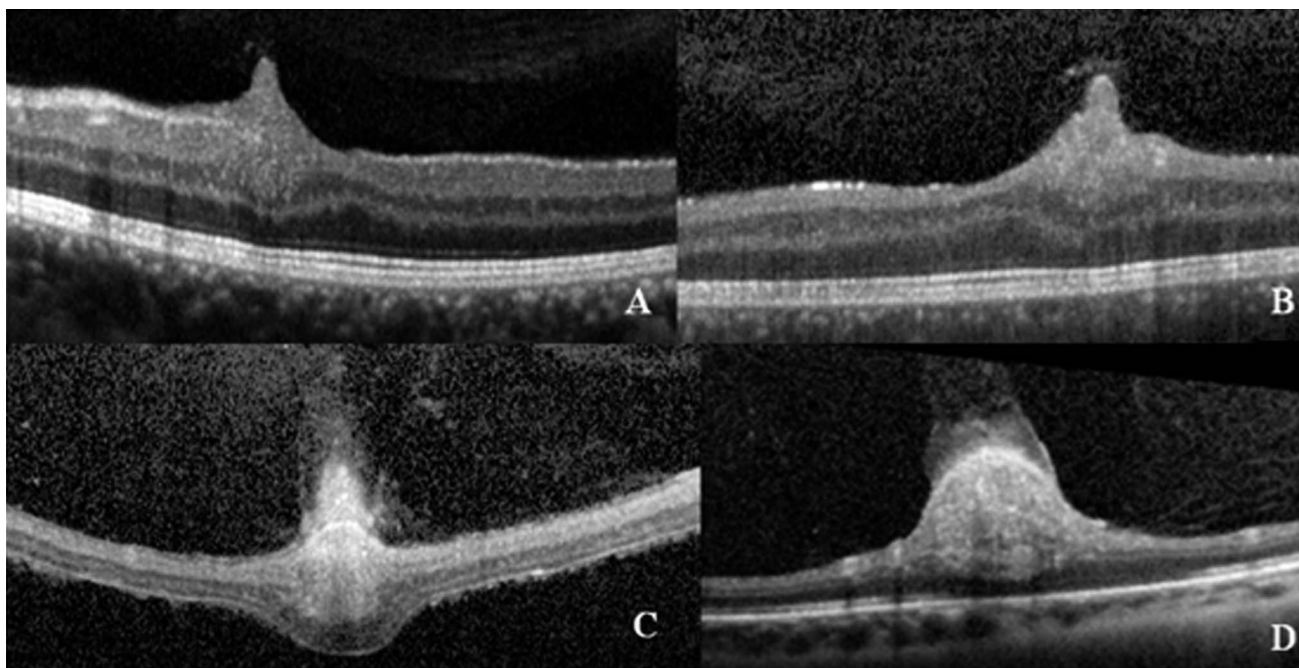


FIGURE 4. (A) SD-OCT of the left eye of patient 7, showing a retinal hamartoma involving the RNFL and ganglion layer. External layers and ellipsoid zone are preserved. (B) SD-OCT of the right eye of patient 7 showing a retinal hamartoma that is similar to the one in the fellow eye. (C) SD-OCT of a retinal hamartoma with an ERM associated with a detached retina of patient 3. (D) SD-OCT of the left eye of patient 8, showing a retinal hamartoma with disorganization of the internal and external retinal layers, which is associated with ERM and disruption of the ellipsoid zone.

Acknowledgments

Supported by Federal University of Minas Gerais - Brazil (Belo Horizonte, MG, Brazil) and INCT de Medicina Molecular, CNPq/FAPEMIG/CAPES (Belo Horizonte, MG, Brazil).

Disclosure: **V. Waisberg**, None; **L.O.C. Rodrigues**, None; **M.B. Nehemy**, None; **M. Frasson**, None; **D. M. de Miranda**, None

References

1. NIH conference statement. Neurofibromatosis 1 (von Recklinghausen disease) and neurofibromatosis 2 (bilateral acoustic neurofibromatosis). *Ann Intern Med.* 1990;113:39-52.
2. Seizinger BR, Rouleau GA, Ozelius LJ, et al. Genetic linkage of von Recklinghausen neurofibromatosis to the nerve growth factor receptor gene. *Cell.* 1987;49:589-594.
3. Roleau G, Seizinger BR, Ozelius LG, et al. Genetic linkage analysis of bilateral acoustic neurofibromatosis to a DNA marker on chromosome 22. *Nature.* 1987;329:246-248.
4. Cooper J, Giancotti FG. Molecular insights into NF2/Merlin tumor suppressor function. *FEBS Lett.* 2014;16:2743-2752.
5. Rodrigues LO, Batista PB, Goloni-Bertollo EM, et al. Neurofibromatosis part 1 - diagnosis and differential diagnosis. *Arq Neuropsiquiatr.* 2014;72:241-250.
6. Evans DGR. Neurofibromatosis type 2 (NF2): a clinical and molecular review. *Orphanet J Rare Dis.* 2009;4:16.
7. Evans DG, Huson SM, Donnai D, et al. A clinical study of type 2 neurofibromatosis. *Q J Med.* 1992;84:603-618.
8. Evans DG, Howard E, Giblin C, et al. Birth incidence and prevalence of tumor-prone syndromes: estimates from a UK family genetic register service. *Am J Med Genet.* 2010;152A:327-332.
9. Antinheimo J, Sankila R, Carpén O, Pukkala E, Sainio M, Jääskeläinen J. Population-based analysis of sporadic and type 2 neurofibromatosis-associated meningiomas and schwannomas. *Neurology.* 2000;54:71-76.
10. Parry DM, Eldridge R, Kaiser-Kupfer MI, et al. Neurofibromatosis 2 (NF): clinical characteristics of 63 affected individual and clinical evidence for heterogeneity. *Am J Med Genet.* 1994;52:450-461.
11. Eldridge R, Parry DM, Kaiser-Kupfer MI. Neurofibromatosis 2: clinical heterogeneity and natural history in 39 individual in 9 families and 16 sporadic cases. *Am J Hum Genet Suppl.* 1991;49:A676.
12. Gardner WJ, Frazier CH. Bilateral acoustic neurofibromatosis: a clinical study and field survey of a family of five generations with bilateral deafness in thirty-eight members. *Arch Neurol Psychiatry.* 1930;23:266-302.
13. Kluwe L, Mautner V, Heinrich B, et al. Molecular study of frequency of mosaicism in neurofibromatosis 2 patients with bilateral vestibular schwannomas. *J Med Genet.* 2003;40:109-114.
14. Kluwe L, Mautner VF. Mosaicism in sporadic neurofibromatosis 2 patients. *Hum Mol Genet.* 1998;7:2051-2055.
15. Kaye LD, Rothner AD, Beauchamp GR, Meyers SM, Estes ML. Ocular findings associated with neurofibromatosis type II. *Ophthalmology.* 1992;99:1424-1429.
16. Bosch MM, Boltshauser E, Harpes P, Landau K. Ophthalmologic findings and a long-term course in patients with neurofibromatosis type 2. *Am J Ophthalmol.* 2006;141:1068-1077.
17. Feucht M, Griffiths B, Niemüller I, Haase W, Richard G, Mautner VF. Neurofibromatosis 2 leads to higher incidence of strabismic and neuro-ophthalmological disorders. *Acta Ophthalmol.* 2008;86:882-886.
18. Viola F, Villani E, Natacci F, et al. Choroidal abnormalities detected by near-infrared reflectance imaging as a new diagnostic criterion for neurofibromatosis 1. *Ophthalmology.* 2012;119:369-375.
19. Abdolrahimzadeh S, Felli L, Plateroti R, et al. Morphologic and vasculature features of the choroid and associated choroid-retinal thickness alterations in neurofibromatosis type 1. *Br J Ophthalmol.* 2015;99:789-793.
20. Chang L, El-Dairi MA, Frempong TA, et al. Optical coherence tomography in the evaluation of neurofibromatosis type 1 subjects with optic pathway gliomas. *J AAPOS.* 2010;14:511-517.
21. Topcu-Yilmaz P, Kasim B, Kiratli H. Investigation of retinal nerve fiber layer thickness in patients with neurofibromatosis 1. *Jpn J Ophthalmol.* 2014;88:172-176.
22. Landau K, Yasargil GM. Ocular fundus in neurofibromatosis type 2. *Br J Ophthalmol.* 1993;77:646-649.
23. Meyers SM, Gutman FA, Kaye LD, Rothner AD. Retinal changes associated with neurofibromatosis 2. *Trans Am Ophthalmol Soc.* 1995;93:245-257.
24. Feucht M, Kluwe L, Mautner VF, Richard G. Correlation of nonsense and frameshift mutations with severity of retinal abnormalities in neurofibromatosis 2. *Arch Ophthalmol.* 2008;126:1376-1380.
25. Sisk RA, Berrocal AM, Scheffler AC, Dubovy SR, Bauer MS. Epiretinal membranes indicate a severe phenotype of neurofibromatosis type 2. *Retina.* 2010;30:51-58.
26. Scheffler AC, Dubovy SR, Berrocal AM. Optical coherence tomography characteristics of epiretinal membranes in neurofibromatosis 2. *Ophthalmic Surg Lasers Imaging.* 2008;39:73-77.
27. Parry DM, MacCollin MM, Kaiser-Kupfer MI, et al. Germ-line mutations in the neurofibromatosis 2 gene: correlations with disease severity and retinal abnormalities. *Am J Hum Genet.* 1996;59:529-539.
28. Evans DGR, Birch JM, Ramsden RT. Paediatric presentation of type 2 neurofibromatosis. *Arch Dis Child.* 1999;81:496-499.
29. Parry A, Giannini C, Raghavan R, et al. Aggressive phenotypic and genotypic features in pediatric and NF2-associated meningiomas: a clinicopathologic study of 53 cases. *J Neuro-pathol Exp Neurol.* 2001;60:994-1003.
30. McLaughlin ME, Pepin SM, MacCollin MM, Choopong P, Lessell S. Ocular pathologic findings of neurofibromatosis type 2. *Arch Ophthalmol.* 2007;125:389-394.
31. Han DP, Chin M, Simons KB, Albert DM. Surgical removal of an atypical macular epiretinal membrane in neurofibromatosis type 2: clinicopathologic correlation and visual outcome. *Arch Ophthalmol.* 2012;130:1337-1339.
32. Chan C, Koch CA, Kaiser-Kupfer MI, et al. Loss of heterozygosity for the NF gene in retinal and optic nerve lesions of patients with neurofibromatosis 2. *J Pathol.* 2002;198:14-20.
33. Song BJ, Ko MK, Choe JK. Ultrastructural change of the Müller cell in the culture of sensory retina. *Korean J Ophthalmol.* 1995;9:84-88.
34. Schachat AP, Shields JA, Fine SL, et al. Combined hamartomas of the retina and retinal pigment epithelium. *Ophthalmology.* 1984;91:1609-1615.