

Femoroacetabular Impingement Syndrome: An Underrecognized Cause of Hip Pain and Premature Osteoarthritis?

GRAHAM D. REID, CALLUM G. REID, NADIA WIDMER, and PETER L. MUNK

ABSTRACT. Acetabular dysplasia is well recognized as a potential predisposing factor to the development of hip osteoarthritis (OA). In the orthopedic literature, other dysmorphic and orientation abnormalities of the femoral head, femoral head-neck junction, and the acetabulum have been reported, with increasing frequency in recent years, under the term femoroacetabular impingement syndrome (FAI). The studies have shown a clear association of these structural anomalies with patients' symptoms and signs, radiographic and pathologic abnormalities, and the development of degenerative hip arthritis. FAI is now believed to be a very important predisposing factor for the development of degenerative hip arthritis, particularly in younger adults. Although the results of longterm studies are awaited, the hope is that early surgical intervention in patients with FAI will change the course or prevent the development of hip OA. It is well documented that early recognition of potential FAI surgical candidates, before OA is advanced, determines the postsurgical outcome. FAI has not been reported in the rheumatology literature, but since patients with FAI likely often initially present to rheumatology clinics for assessment of hip pain, it is important for rheumatologists to be aware of this condition and refer to orthopedics when appropriate. The objective of this review is to provide an outline of the basic concepts of FAI, including clinical presentation and radiographic findings, so that rheumatologists become more familiar with this important emerging entity. (First Release June 1 2010; J Rheumatol 2010;37:1395–404; doi:10.3899/jrheum.091186)

Key Indexing Terms:

FEMOROACETABULAR IMPINGEMENT SYNDROME HIP PAIN OSTEOARTHRITIS

Osteoarthritis (OA) of the hip is not a diagnosis but a description of a degenerative condition that has many precipitating etiologies. Harris stated, "either osteoarthritis of the hip does not exist at all as a primary disease entity or, if it does, it is extraordinarily rare"¹.

The complex development of the hip provides the potential for many possible dysplasias of both the acetabulum and the femoral head-neck components of the joint. It has been stated that if secondary causes of hip OA such as rheumatoid arthritis, calcium pyrophosphate disease, etc., are excluded, morphological developmental abnormalities account for 90% of cases of hip OA¹. This is particularly true in patients who develop symptomatic hip OA before the age of 50 years. Others have suggested that the data to support this

claim are not yet conclusive². Acetabular dysplasia has been recognized as a cause of hip OA for many years^{3,4}.

The concept of femoroacetabular impingement (FAI) was first reported in 1936 by Smith Petersen, who reported on his surgical results⁵. Only in recent years, however, has the concept been developed further. Study of the complex interaction of the structural hip abnormalities that can result in FAI, the radiographic signs, and the treatment of FAI was pioneered by Ganz, and many current researchers have trained with him^{6,7,8}. Variations in the size, shape, and configuration of the acetabulum, femoral head, and femoral neck are responsible for FAI⁹. It is now recognized that FAI is a common cause of hip OA¹⁰.

The purpose of this report is to describe an illustrative case and provide an overview of the anatomical basis and clinical features of the FAI syndrome. The radiologic assessment techniques are reviewed and the current orthopedic surgical treatment options discussed. Although FAI is increasingly reported in the orthopedic and radiologic literature, the entity is likely underrecognized by rheumatologists. Early recognition and intervention for the FAI syndrome may delay or prevent the development of progressive hip OA.

From the Department of Medicine and Department of Radiology, University of British Columbia, Vancouver, British Columbia, Canada.

G.D. Reid, MB, ChB, FRCP, Clinical Professor, Rheumatology; C.G. Reid, MD, Chief Resident, Internal Medicine; N. Widmer, MD, Resident, Internal Medicine; P.L. Munk, MD, CM, FRCP, Professor of Radiology and Orthopedics.

*Address correspondence to Dr. G. Reid, 306–888 West 8th Avenue, Vancouver, BC V5Z 3Y1, Canada. E-mail: reid@greid.net
Accepted for publication February 5, 2010.*

Anatomy of FIA Syndrome

FAI describes a syndrome in which there is abutment of the femoral head-neck junction with the acetabular rim and labrum (Figure 1).

The syndrome of FAI can be divided into 2 major subgroups¹¹. In the so-called “pincer” type FAI the primary abnormality is in the acetabulum. In the “cam” type subgroup the abnormality is at the femoral head-neck junction. Cam-type FAI syndrome is the more frequent¹², but the majority of patients will have a mixed presentation with components of both subtypes¹³.

In both categories damage to the labrum occurs from repetitive impingement stress. Labral tears and degeneration occurring at the superior aspect of the acetabulum are commonly associated with FAI syndrome^{12,14,15}.

Pincer-type FAI. In this category, problems arise as a result of abnormalities in either the shape of the acetabulum and/or its orientation within the pelvis. When the hip is in full flexion the femoral head-neck junction abuts the anterosuperior aspect of the acetabulum (Figure 1C). Pincer-type FAI can result as a consequence of a deep acetabular socket with over-coverage of the femoral head. This would be classified as coxa profunda or protrusio acetabuli (Figure 2). A more common cause is retroversion of the acetabulum^{16,17}, in

which the opening of the acetabular cup is oriented more posteriorly within the pelvis in the sagittal plane (Figure 3). Anterior rotation of the pelvis (pelvic version, inclination) in the coronal plane (Figure 4) has been recognized as a potential confounding variable in radiological assessment of retroversion^{18,19}, and may contribute to FAI syndrome^{17,20}. The “tilt” of the acetabulum within the pelvis needs to be considered in addition to pelvic rotation⁹. Pincer-type impingement most commonly is recognized in women in the 30–40 year age group.

Cam-type FAI. In regard to etiology, abnormalities of the femoral head-neck junction (Figure 1B) in this group can be either developmental or acquired. The common result is a reduced clearance distance between the femoral head-neck junction and the anterior acetabular margin when the hip is in flexion and internal rotation (Figure 5).

Cam-type impingement syndrome is more commonly reported in young men, and subclinical physeal damage from aggressive sporting activities in young men is suggested as a possible explanation for this gender difference²¹.

The “pistol grip” hip deformity (Figure 6) occurs in 8%–10% of the male population²². There is debate whether this arises as a primary developmental dysplasia or results from a subclinical slipped capital femoral epiphysis.

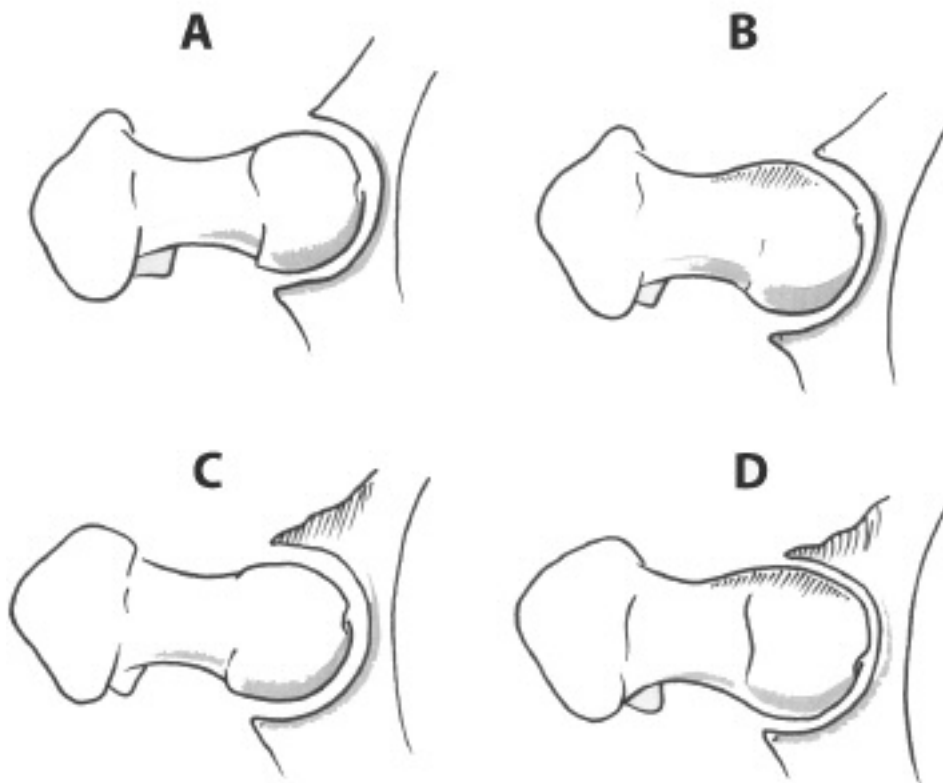


Figure 1. Normal configuration (A). In “cam-type” femoroacetabular impingement syndrome (FAI) the femoral head-neck junction is abnormal (B). In “pincer-type” FAI the acetabulum shape or its configuration within the pelvis is abnormal (C). Frequently FAI may have components of both types (D).

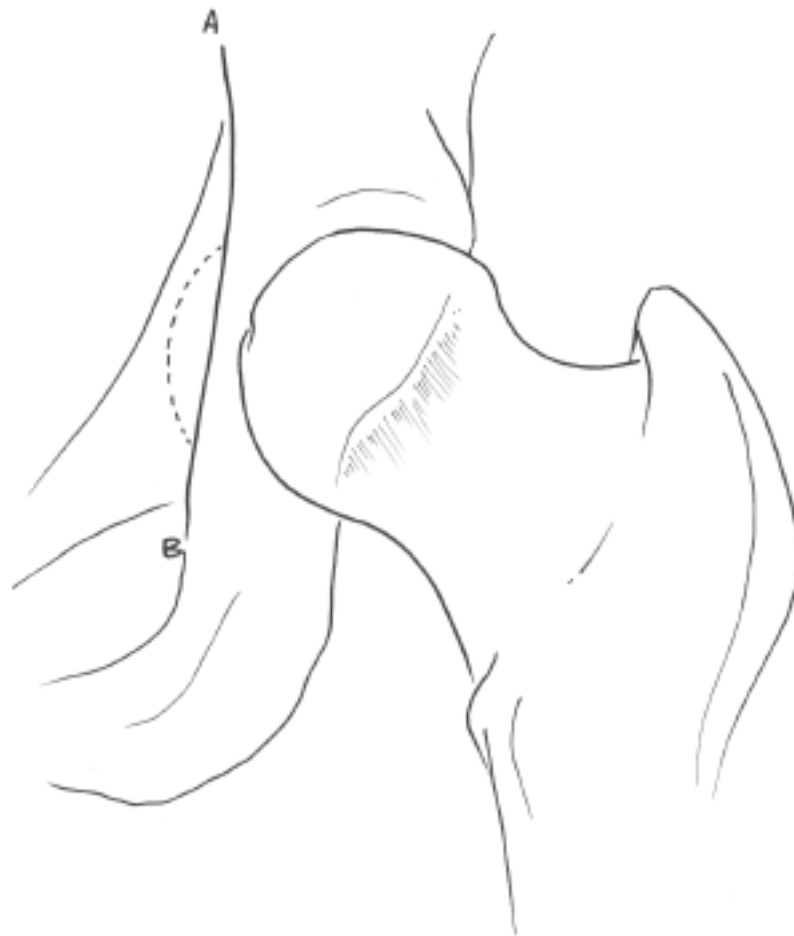


Figure 2. A deep acetabulum is defined as protrusio acetabulum if the acetabulum extends medial to the ilioischial line (A-B) and coxa profunda if it extends to the A-B line.

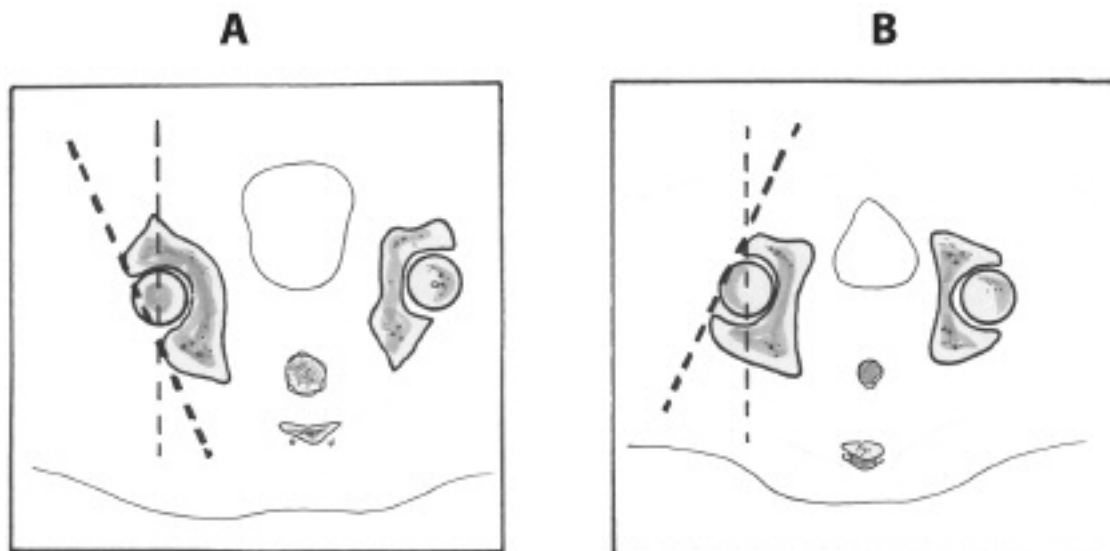


Figure 3. In acetabular retroversion (A) the opening of the acetabulum is oriented posteriorly, in contrast to the more normal anterior orientation (B).

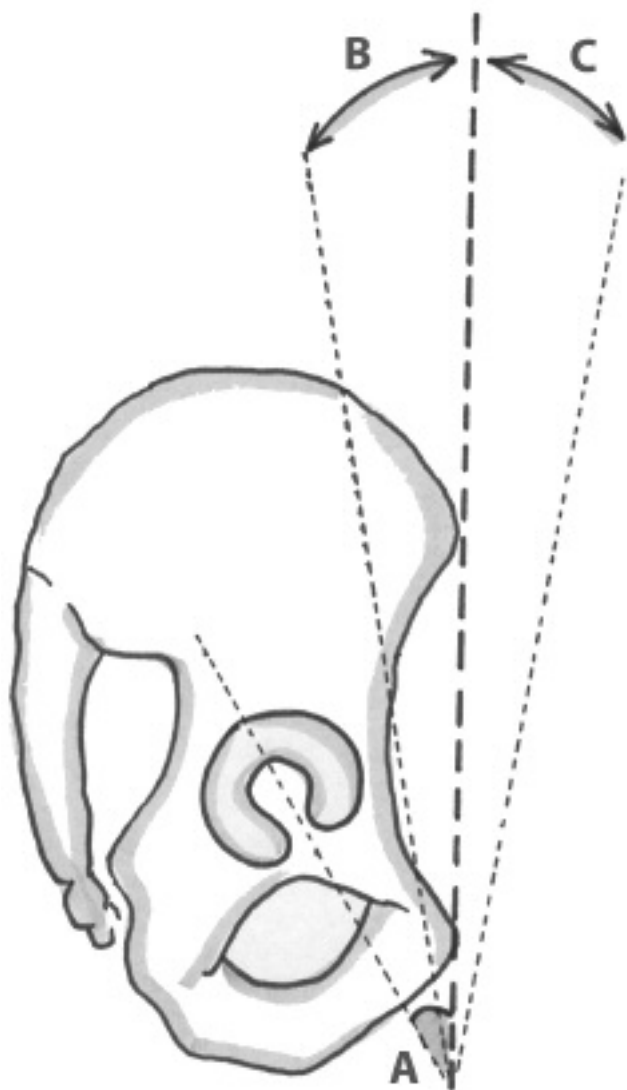


Figure 4. The pelvis may be rotated anteriorly (C) or posteriorly (B). The acetabular tilt (A) defines the angle of the acetabulum in relation to the pelvis.

Abnormally increased anteversion of the femoral neck has been associated with an increased risk of OA^{23,24}. This and a decreased femoral head-neck offset are usually also developmental in origin.

FAI is also described as an acquired problem following abnormal femoral head-neck alignment after hip fracture fixation²⁵ and periacetabular osteotomy^{11,26}. Additionally, cam-type FAI has been reported as a consequence of prior Legg-Calvé-Perthes disease²⁷.

Role of FAI in Hip OA

Increasing clinical experience has demonstrated that FAI is frequently associated with premature development of OA⁸. It is postulated that in the cam-type FAI there is initial chondrolabral damage from asymmetric shear forces at the

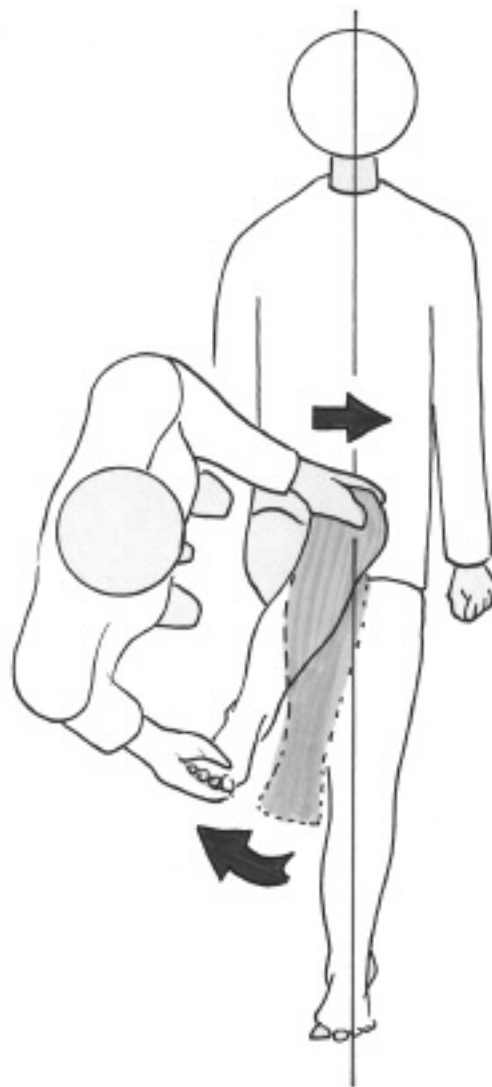


Figure 5. The anterior impingement test, with the hip internally rotated and adducted in the flexed position.

anterosuperior acetabular rim. The acetabular cartilage fails and there is then reciprocal damage to the femoral head cartilage^{28,29,30,31}. The extent of the anomalies at the femoral head-neck junction has been correlated with the extent of hip labrum and chondral damage²⁸. Loss of physiological functioning of the labrum might be a factor contributing to hip OA in the same way that knee meniscectomy contributes to OA of the knee⁸.

In contrast, in pincer-type FAI, although there is antero-superior labral and acetabular cartilage damage from these same shear forces, contra-coup forces also result in posteroinferior hip OA at a comparatively later age¹³. The abnormal radiographic morphology of the hip joint currently associated with FAI may not be the sole predictor of progressive hip OA. Bardakos and Villar reported that the rate of progression of OA is very variable and that the femoral shaft-neck angle and retroversion may be important factors

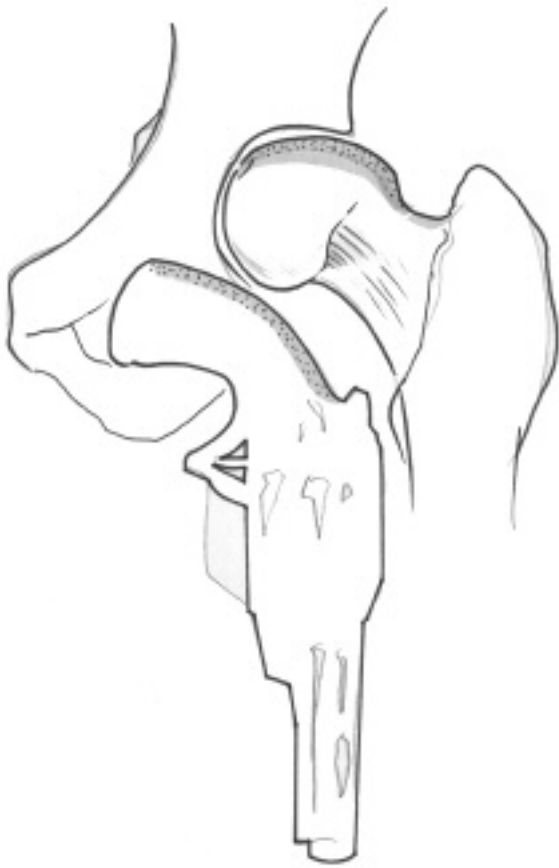


Figure 6. Pistol grip deformity.

that predict a more rapid deterioration¹⁰. The level of physical activity may also be a factor.

Patients who have had a total hip arthroplasty for “osteoarthritis” on the basis of FAI usually have signs of FAI in the contralateral hip and develop progressive degenerative changes in the nonoperated hip³².

Clinical Presentation

The lack of recognition of this disorder often results in long delays in achieving the correct diagnosis, multiple misdiagnoses, and ineffective treatment interventions. Patients are young³³ and often active in sports. The clinical presentation is typically with groin pain of insidious onset, with only a minority of patients recalling a specific precipitating traumatic or sporting injury³⁴. A “click” or snapping sensation is common. Physical activity aggravates symptoms but pain with prolonged sitting is common.

A limp and positive Trendelenberg test may be present. Hip range of movement is restricted in flexion to less than 100 degrees and internal rotation is decreased when assessed in the flexed position. The combination of these 2 movements with adduction is the foundation of the provocative anterior impingement test (Figure 5), which induces the hip symptoms in nearly all patients.

Radiologic assessment. Patients may present late with radiologic signs of joint space narrowing, osteophytes, sclerosis, and cystic change consistent with a diagnosis of “osteoarthritis.” In these late cases, but importantly in early cases, there are radiologic signs that point to the diagnosis of FAI as the precipitating cause of the osteoarthritic process. Since patients may present to rheumatologists initially, it is important that rheumatologists be aware of the radiologic signs of FAI and some of the radiologic methods of assessment.

There are multiple described radiologic signs and measurements for assessing the complex array of hip dysplasias^{10,35}. A recent assessment, however, showed large interobserver variability, suggesting that more work to standardize radiologic evaluation is still required³⁶. It is important also to emphasize that one abnormal radiologic sign in itself does not make a diagnosis of FAI. An abnormal aspherical femoral head may not cause abutment against the acetabular rim if the acetabulum itself is underdeveloped and dysplastic³⁷.

Coxa profunda and protrusio acetabuli. Coxa profunda and protrusio acetabuli in which the floor of the acetabulum abuts or crosses the ilioischial line have increased CE angles > 40 or 45 degrees, respectively (Figures 2 and 7).

Acetabular retroversion. Acetabular retroversion in a pelvis without anterior rotation^{18,19} may have a “crossover” or “figure of 8” sign in which the lines of the anterior and posterior margins of the acetabulum overlap on radiographs (Figure 8). The “posterior wall sign”¹⁷, in which the line of the posterior acetabular margin lies medial to a point placed at the center of the femoral head, is often easier to identify.

Aspherical femoral head. Aspherical femoral head may be seen on anteroposterior (AP) radiographs (Figure 6), but since the asphericity is often anterior, cross-table lateral views or magnetic resonance images may be necessary³⁷. The alpha angle (Figure 9) is a measure of the extent of the asphericity. The alpha angle should be < 55 degrees. The triangular index may also be useful³⁸.

Short femoral neck and coxa vara. Short femoral neck and coxa vara are often seen in conjunction with the pistol grip deformity. The superior tip of the greater trochanter lies 5 mm or more above a horizontal line drawn through the center of the femoral head (Figure 10).

Herniation pits. Herniation pits (Figure 11) at the femoral head junction are indicators of repetitive abutment trauma in FAI³⁹.

Treatment

The syndrome of FAI is a relatively newly recognized disorder and as a result longterm outcome studies to assess the efficacy of the operative interventions are not yet available. The measures used to assess outcome in FAI patients are those used in hip arthroplasty outcome studies, and these may not be appropriate⁴⁰.

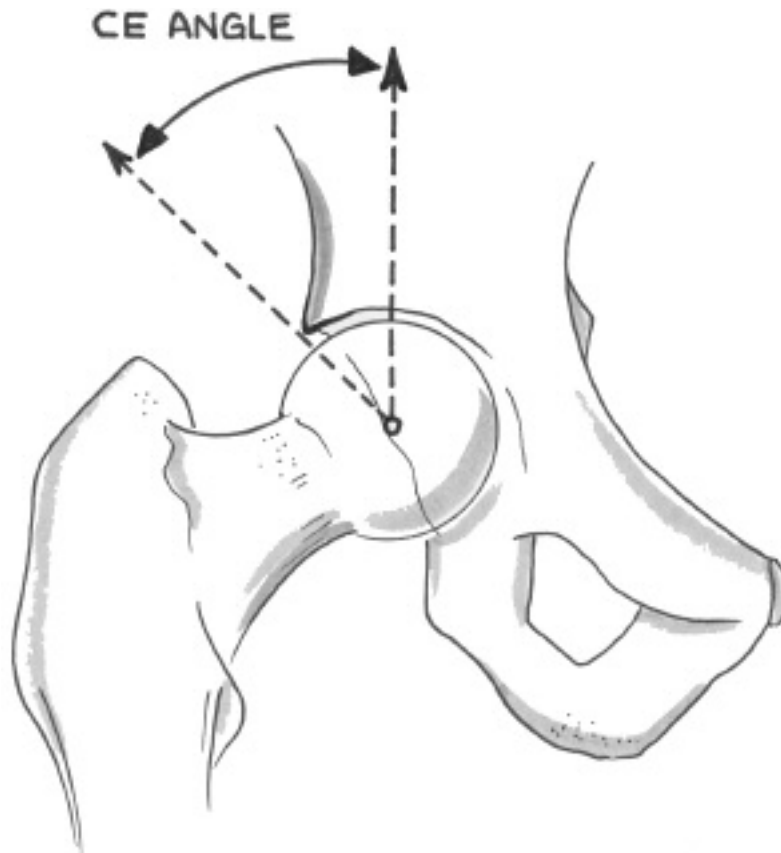


Figure 7. The center-edge (CE) angle. The normal range is 20 degrees to 40 degrees.

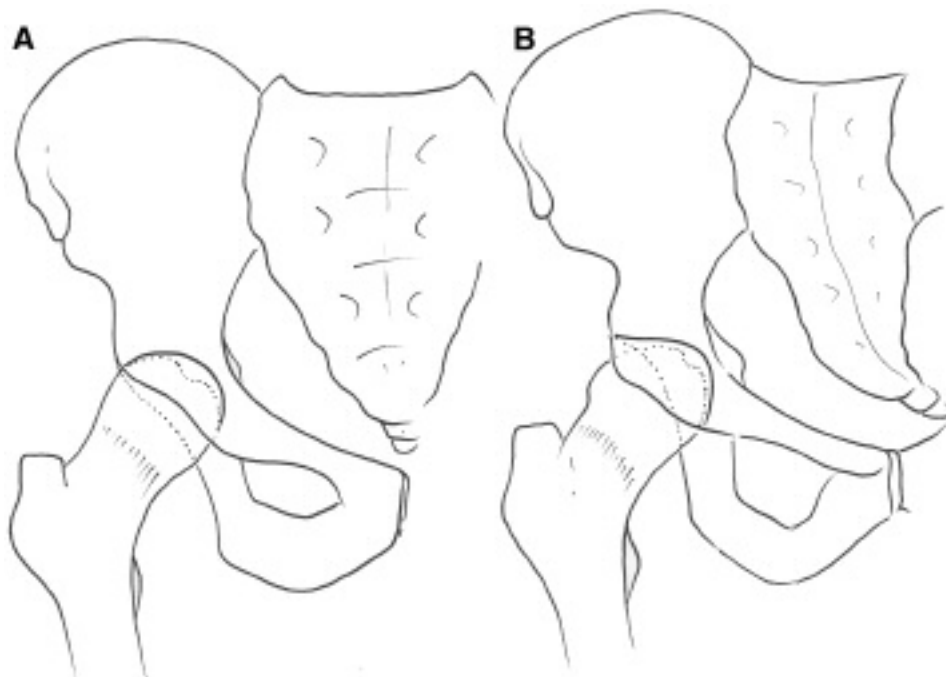


Figure 8. In (A) the line of the posterior margin of the acetabulum lies lateral to the anterior margin of the acetabulum at all times. In (B), with a retroverted acetabulum, the anterior margin crosses the line of the posterior acetabular margin, giving a “figure of 8” crossover sign. The more easily visualized posterior acetabular margin lies medial to the center of the femoral head — “posterior wall sign.”

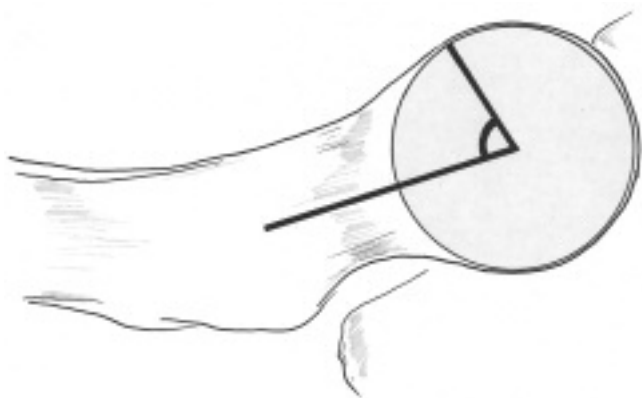


Figure 9. The alpha angle is the angle between a line drawn through the center of the femoral neck and the line joining the center of the femoral head to the point where the femoral head becomes aspherical.

The operative procedures are designed to address the adverse mechanical effects of impingement and delay or prevent the development of OA. Once advanced OA has already developed, such interventions would thus be too late.

In cam-type FAI syndrome, surgical intervention to reduce the bone mass at the head-neck junction is addressed by resection of the bone. This may be performed by open surgery with hip dislocation or arthroscopically^{21,41}. For pincer-type FAI the approach to the acetabular abnormalities may be with periacetabular osteotomy⁴² to correct retroversion, but for anterior overcoverage from a deep socket, resection of the superior anterior acetabular rim (acetabuloplasty) with salvage of the labrum is suggested¹². The relative benefits of open surgery with hip dislocation versus an arthroscopic approach are not yet clarified⁴³. Short-term surgical results have been reported for arthroscopic FAI decompression in adolescents⁴⁴. Since FAI frequently has components of both cam and pincer mechanisms, patients may require both the femoral head-neck junction and the acetabulum to be addressed simultaneously. Repair and preservation of the labrum may improve outcome⁴⁵.

Outcome studies of surgical intervention for FAI have recently been reviewed⁴³. Patient selection clearly has a very important influence on outcome. Not surprisingly, intraoperative assessment of the extent of existent OA is a strong predictor of poor outcome. Patients need to be iden-

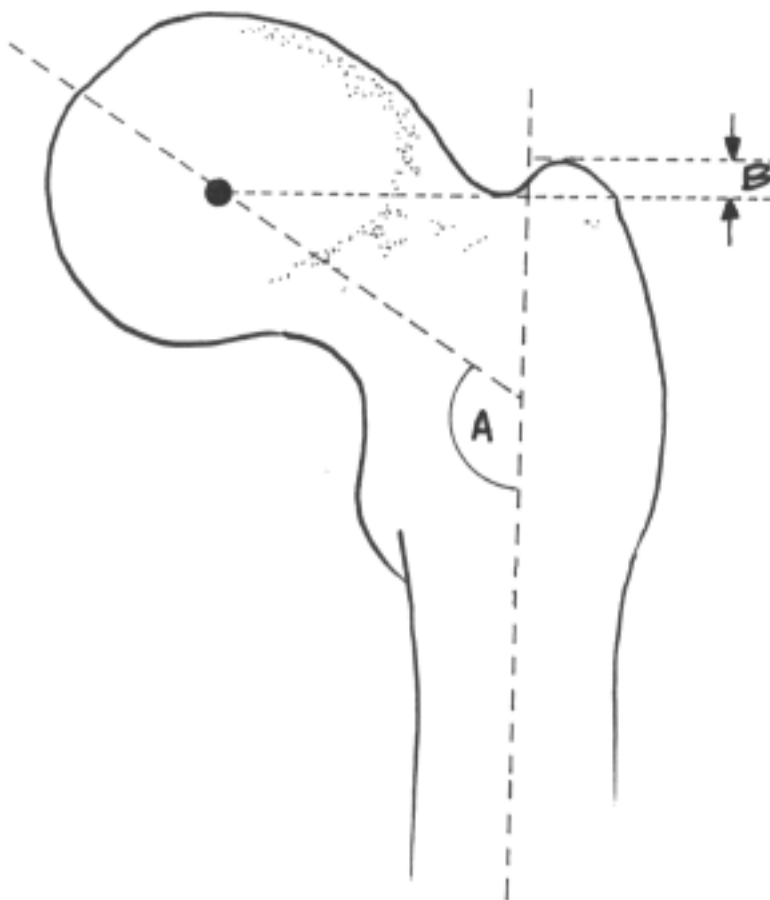


Figure 10. The aspherical femoral head may be accompanied by a short femoral neck and coxa vara (angle A). The superior tip of the greater trochanter lies less than 5 mm above a horizontal line drawn through the center of the femoral head (measurement B).

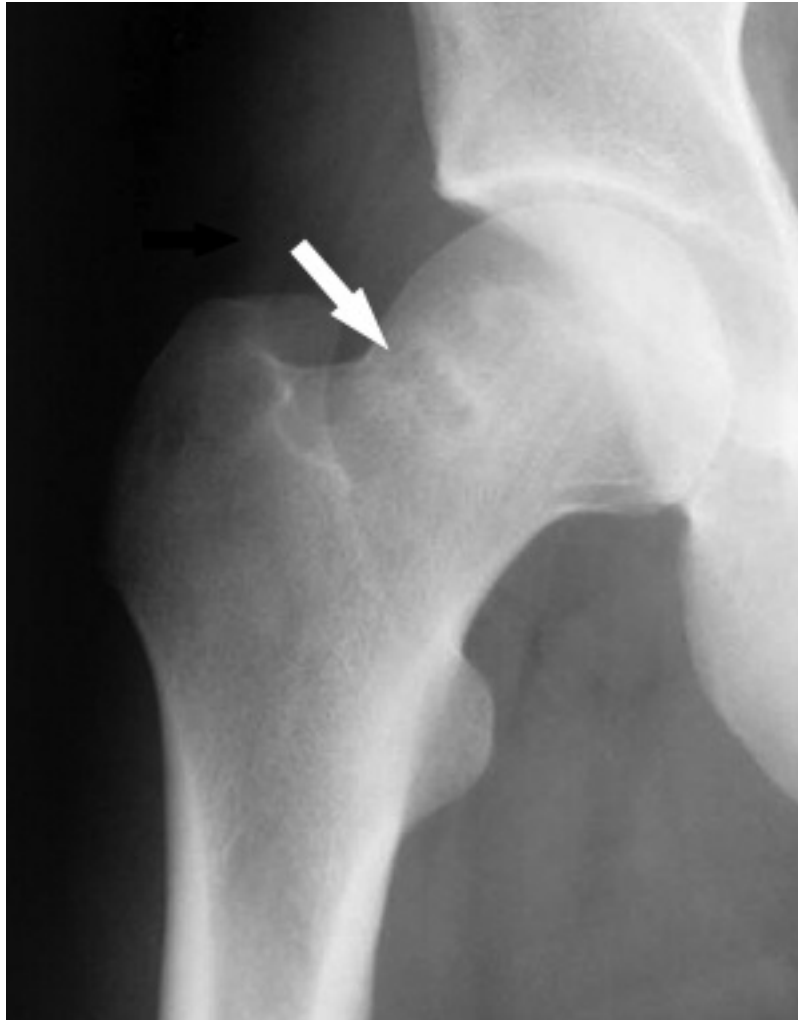

Figure 11. Herniation pits appear as lucent areas at the femoral head-neck junction area in plain radiographs.

tified before significant degenerative changes in the cartilage have developed if surgical intervention is to be effective in modifying the natural history of hip OA.

Case Presentation

A 25-year-old woman presented with a 10 year history of increasing right hip pain and “clicking.” She clearly recalled onset of symptoms following a lunging movement while playing soccer. Symptoms were exacerbated by sporting activities, but on some days even 1 mile of level walking produced pain. Pain-free walking and running could be accomplished by restriction of stride length. Increasingly, prolonged sitting bent forward when working at a desk produced pain in the groin. Examination revealed an anteriorly rotated pelvis with flexion of the hip limited to 90 degrees with pain. Internal rotation of the right hip in the flexed and adducted position reproduced her pain and was restricted to 5 degrees, but was normal and equal to the left hip internal rotation when assessed with the leg in the anatomic or

extended position. When extending the hip from the flexed position an audible and palpable “click” in the groin was inconsistently present.

Plain radiographs had the appearance of an inlet view consistent with pelvic inclination (Figure 12). Coxa profunda with the floor of the acetabulum abutting the ilioischial line was noted bilaterally. The CE angle measured 50 degrees. The “figure of 8” sign was equivocal. A magnetic resonance arthrogram showed cystic degenerative change in the anterior superior labrum, with no degenerative changes identified in the femoral or acetabular cartilage. Hyperostosis at the femoral head-neck junction was present with an alpha angle of 55 degrees. A diagnosis was made of pincer-type FAI with degenerative acetabular labral changes. There was a small cam-type effect from the hyperostosis. The acetabular retroversion was within normal limits, but there was a “functional” retroversion secondary to anterior pelvis rotation.

Because of increasing pain, functional restriction, and the

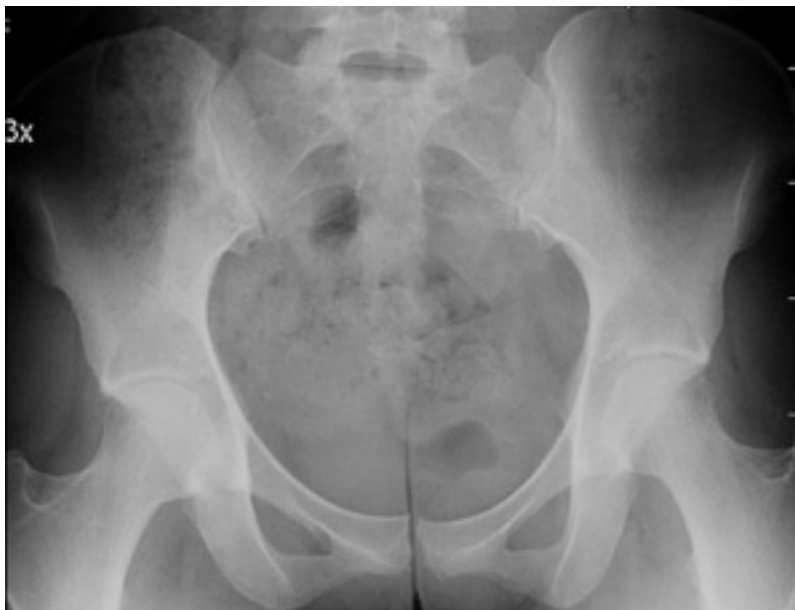

Figure 12. Anteroposterior radiograph of the pelvis showing anterior rotation of the pelvis and coxa profunda. Borderline appearance of acetabular retroversion needs to be interpreted with caution in setting of pelvis anterior rotation.

fear of probable premature development of hip OA, the patient decided to proceed with surgery. A degenerated labrum was identified and reattached following an acetabuloplasty in which the anterior rim was cut back. The slight asphericity at the femoral head-neck junction was also removed. Postoperatively, flexion was to 110 degrees with 25 degrees of internal rotation when examined with the hip flexed at 90 degrees. At 6 month followup there was some residual trochanteric discomfort and hip abductor weakness, but no groin symptoms. Repeat radiographs showed no changes of hip OA.

Conclusion

The syndrome of FAI results from several structural anomalies of the hip that result in repetitive pressure of the anterior acetabular rim against the femoral neck. Most commonly this is a result of abnormal bone formation at the femoral head-neck junction, giving the appearance of asphericity of the femoral head (cam-type) or excessive frontal acetabular coverage of the femoral head (pincer-type). It is now clear that FAI is an important etiologic factor in the development of premature OA of the hip in young adults.

FAI is frequently associated with hip labrum pathology and an associated FAI syndrome should be considered in patients who are diagnosed with labral tears.

It is important that rheumatologists be aware of and recognize the pattern of symptoms and signs associated with this newly emerging syndrome and be familiar with the radiologic signs and methods of assessment, so that appropriate referral to orthopedic surgery can be made in a timely manner before hip OA develops.

Surgical treatment approaches are developing, and with time, additional outcomes studies will provide more data on the success of surgery in preventing hip OA.

ACKNOWLEDGMENT

The authors thank Lorie Marchinkow for preparation of the figures.

REFERENCES

1. Harris WH. Etiology of osteoarthritis of the hip. *Clin Orthop Relat Res* 1986;213:20-33.
2. Lievens AM, Bierma-Zeinstra SM, Verhagen AP, Verhaar JA, Koes BW. Influence of hip dysplasia on the development of osteoarthritis of the hip; a systematic review. *Ann Rheum Dis* 2004;63:621-6.
3. Reijman M, Hazes JMW, Pols HAP, Koes BW, Bierma-Zeinstra SMA. Acetabular dysplasia predicts incident osteoarthritis of the hip: The Rotterdam study. *Arthritis Rheum* 2005;52:787-93.
4. Lane NE, Lin P, Christiansen L, Gore LR, Williams EN, Hochberg MC, et al. Association of mild acetabular dysplasia with an increased risk of incident hip osteoarthritis in elderly white women. *Arthritis Rheum* 2000;43:400-4.
5. Brand RA. Femoroacetabular impingement: current status of diagnosis and treatment. *Clin Orthop Relat Res* 2009;467:605-7.
6. Klaue K, Durnin CW, Ganz R. The acetabular rim syndrome: a clinical presentation of dysplasia of the hip. *J Bone Joint Surg Br* 1991;73:423-9.
7. Ganz R, Leunig M, Leunig-Ganz K, Harris WH. The etiology of osteoarthritis of the hip: an integrated mechanical concept. *Clin Orthop Relat Res* 2008;466:264-72.
8. Leunig M, Beaulé PE, Ganz R. The concept of femoroacetabular impingement: current status and future perspectives. *Clin Orthop Relat Res* 2009;467:616-22.
9. Kohnlein W, Ganz R. Acetabular morphology. *Clin Orthop Relat Res* 2009;467:682-91.
10. Bardakos NV, Villar RN. Predictors of progression of osteoarthritis in femoroacetabular impingement syndrome. *J Bone Joint Surg Br* 2009;91:162-9.

11. Ganz R, Parvizi J, Beck M, Leunig M, Notzli H, Siebenrock KA. Femoroacetabular impingement. A cause for osteoarthritis of the hip. *Clin Orthop Relat Res* 2003;417:112-120.
12. Graves ML, Mast JW. Femoroacetabular impingement: do outcomes reliably improve with surgical dislocations? *Clin Orthop Relat Res* 2009;467:717-23.
13. Beck M, Kalhor M, Leunig M, Ganz R. Hip morphology influences the pattern of damage to the acetabular cartilage: femoroacetabular impingement as a cause of early osteoarthritis of the hip. *J Bone Jt Surg Br* 2005;87:1012-8.
14. Ito K, Minka MA, Leunig M, Werlen S, Ganz R. Femoroacetabular impingement and the cam effect: A MRI based quantitative anatomical study of the femoral head-neck offset. *J Bone Joint Surg Br* 2001;83:171-6.
15. Wenger DE, Kendell KR, Miner MR, Trousdale RT. Acetabular labral tears rarely occur in the absence of bony abnormalities. *Clin Orthop Relat Res* 2004;426:145-50.
16. Khanduja V, Villar RN. The arthroscopic management of femoroacetabular impingement. *Knee Surg Sports Traumatol Arthrosc* 2007;15:1035-40.
17. Reynolds D, Lucas J, Klauke K. Retroversion of the acetabulum. A cause of hip pain. *J Bone Joint Surg Br* 1999;81:281-8.
18. Anda S. Pelvic inclination and spatial orientation of the acetabulum. *Acta Radiol* 1990;31:389-94.
19. Siebenrock KA, Kalbermatten DF, Ganz R. Effect of pelvic tilt on acetabular retroversion: A study of pelves from cadavers. *Clin Orthop Relat Res* 2003;407:241-8.
20. Langlais F, Lambotte JC, Lannou R, Gedouin JE, Belot N, Thomazeau H, et al. Hip pain from impingement and dysplasia in patients aged 20-50 years. Work up and role for reconstruction. *Joint Bone Spine* 2006;73:614-23.
21. Philippon M, Schenker M, Briggs K, Kuppersmith D. Femoroacetabular impingement in 45 professional athletes; associated pathologies and return to sport following arthroscopic decompression. *Knee Surg Sports Traumatol Arthrosc* 2007; 15:908-14.
22. Goodman DA, Feighan JE, Smith AD, Latimer B, Buly RL. Subclinical slipped capital femoral epiphysis. *J Bone Joint Surg Am* 1997;79:1489-97.
23. Tonnis D, Heinecke A. Acetabular and femoral anteversion: relationship with osteoarthritis of the hip. *J Bone Joint Surg Am* 1999;81:1747-70.
24. Reikeras O, Bjerkreim I, Kolbenstvedt A. Anteversion of the acetabulum and femoral neck in normals and in patients with osteoarthritis of the hip. *Acta Orthop Scand* 1983;54:18-23.
25. Eijer H, Myers SR, Ganz R. Anterior femoroacetabular impingement after femoral neck fractures. *J Orthop Trauma* 2001;15:475-81.
26. Myers SR, Eijer H, Ganz R. Anterior femoroacetabular impingement after periacetabular osteotomy. *Clin Orthop Relat Res* 1999;363:93-9.
27. Stulberg SD, Cooperman DR, Wallensten R. The natural history of Legg-Calvé-Perthes disease. *J Bone Joint Surg Am* 1981; 63:1095-108.
28. Johnston TL, Schenker ML. Relationship between offset angle alpha and hip chondral injury in femoroacetabular impingement. *Arthroscopy* 2008;24:669-75.
29. Wagner S, Hofstetter W, Chiquet M, Mainil-Varlet P, Stauffer E, Ganz R, et al. Early OA changes of human femoral head cartilage subsequent to femoro-acetabular impingement. *Osteoarthritis Cartilage* 2003;11:508-18.
30. Pfirrmann CW, Duc SR, Zanetti M, Dora C, Hodler J. MR arthrography of acetabular cartilage delamination in femoroacetabular cam impingement. *Radiology* 2008;249:236-41.
31. Tannast M, Goricki D, Beck M, Murphy SB, Siebenrock KA. Hip damage occurs at the zone of femoroacetabular impingement. *Clin Orthop Relat Res* 2008;488:264-72.
32. Clohisy J, Dobson M, Warth L, Liu S, Steger-May K, Callaghan J. Femoroacetabular impingement: What is the fate of the contralateral hip? Paper presented at: Adult reconstruction hip 3: Non arthroplasty. 75th Annual Meeting, American Academy of Orthopedic Surgeons, Mar 5-9 2008, San Francisco, CA.
33. Sink EL, Gralla J, Ryba A, Dayton M. Clinical presentation of femoroacetabular impingement in adolescents. *J Pediatr Orthop* 2008;28:806-11.
34. Clohisy JC, Knaus ER, Hunt DM, Leshner JM, Harris-Hayes M, Prather H. Clinical presentation of patients with symptomatic anterior hip impingement. *Clin Orthop Relat Res* 2009;467:638-44.
35. Tannast M, Kubiak-Langer M, Langlotz F, Puls M, Murphy SB, Siebenrock KA. Noninvasive Three-dimensional assessment of femoroacetabular impingement. *J Orthop Res* 2007;25:122-31.
36. Clohisy JC, Carlisle JC, Trousdale R, Kim YJ, Beaulé PE, Morgan P, et al. Radiographic evaluation of the hip has limited reliability. *Clin Orthop Relat Res* 2009;467:666-75.
37. Dudda M, Albers C, Mamisch TC, Werlen S, Beck M. Do normal radiographs exclude asphericity of the femoral head-neck junction? *Clin Orthop Relat Res* 2009;467:651-9.
38. Gosvig KK, Jacobsen S, Palm H, Sonne-Holm S, Magnusson E. A new radiological index for assessing asphericity of the femoral head in cam impingement. *J Bone Joint Surg Br* 2007;89:162-9.
39. Leunig M, Beck M, Kahlor M, Kim YJ, Werlen S, Ganz R. Fibrocystic changes at the anterosuperior femoral neck: Prevalence in hips with femoroacetabular impingement. *Radiology* 2005;236:237-46.
40. Philippon MJ, Briggs KK, Yen YM, Kuppersmith DA. Outcomes following hip arthroscopy for femoroacetabular impingement with associated chondrolabral dysfunction: minimum two year follow up. *J Bone Joint Surg Br* 2009;91:16-23.
41. Weiland DE, Philippon MJ. Arthroscopic technique for femoroacetabular impingement. *Op Tech Orthop* 2005;15:256-60.
42. Siebenrock KA, Schoeniger R, Ganz R. Anterior femoro- acetabular impingement due to acetabular retroversion: Treatment with periacetabular osteotomy. *J Bone Joint Surg Am* 2003;85:278-86.
43. Bedi A, Chen N, Robertson W, Kelly BT. The management of labral tears and femoroacetabular impingement of the hip in the young, active patient. *Arthroscopy* 2008;24:1135-45.
44. Philippon MJ, Yen YM, Briggs KK, Kuppersmith DA, Maxwell RB. Early outcomes after hip arthroscopy for femoroacetabular impingement in the athletic adolescent patient. A preliminary report. *J Pediatr Orthop* 2008;28:705-10.
45. Espinosa N, Beck M, Rothenflug DA, Ganz R, Leunig M. Treatment of femoroacetabular impingement: Preliminary results of labral fixation: surgical technique. *J Bone Joint Surg Am* 2006;88:925-35.