

# Distinct patterns of grey matter abnormality in high-functioning autism and Asperger's syndrome

Gráinne M. McAlonan,<sup>1,2</sup> John Suckling,<sup>3</sup> Naiké Wong,<sup>1</sup> Vinci Cheung,<sup>1</sup>  
Nina Lienenkaemper,<sup>4</sup> Charlton Cheung<sup>1</sup> and Siew E. Chua<sup>1,2</sup>

<sup>1</sup>Department of Psychiatry and <sup>2</sup>State Key Laboratory for Brain and Cognitive Sciences, University of Hong Kong;

<sup>3</sup>Cambridge Brain Mapping Unit, Department of Psychiatry, University of Cambridge, UK; <sup>4</sup>Department of Neuroscience, Faculty of Biomedical Science, University of Utrecht, The Netherlands

**Background:** Autism exists across a wide spectrum and there is considerable debate as to whether children with Asperger's syndrome, who have normal language milestones, should be considered to comprise a subgroup distinct other from high-functioning children with autism (HFA), who have a history of delayed language development. Magnetic resonance imaging (MRI) studies of autism are in disagreement. One possible reason is that the diagnosis of autism takes precedence over Asperger's syndrome and a distinction in language acquisition is rarely made. We therefore planned to examine a whole brain hypothesis that the patterns of grey matter differences in Asperger's syndrome and HFA can be distinguished. **Methods:** We used voxel-based computational morphometry to map grey matter volume differences in 33 children with either Asperger's syndrome or high-functioning autism compared to 55 typical developing control children balanced for age, IQ, gender, maternal language and ethnicity. **Results:** Children with HFA had significantly smaller grey matter volumes in subcortical, posterior cingulate and precuneus regions than the Asperger's group. Compared to controls, children with HFA had smaller grey matter volumes in predominantly fronto-pallidal regions, while children with Asperger's had less grey matter in mainly bilateral caudate and left thalamus. In addition we found a significant negative correlation between the size of a grey matter cluster around BA44 language area and the age of acquisition of phrase speech in the children with HFA. When the groups were combined we confirmed a mixed picture of smaller grey matter volumes in frontal, basal ganglia, temporal and parietal regions. **Conclusions:** Our study suggests that the underlying neurobiology in HFA and Asperger's syndrome is at least partly discrete. Future studies should therefore consider the history of language acquisition as a valuable tool to refine investigation of aetiological factors and management options in pervasive developmental disorders. **Keywords:** Asperger's disorder, autistic disorder, brain imaging. **Abbreviations:** HFA: high-functioning autism; LFA: low-functioning autism; ADI-R: Autism Diagnostic Interview – Revised; AC-PC: anterior commissure–posterior commissure.

Autism exists across a spectrum. Although features of impaired social reciprocity, communication difficulty, and repetitive interests or motor activities are common to all individuals suffering the disorder, the autism spectrum accommodates individuals with and without learning impairment. Individuals without learning disability can be further categorised according to their history of phrase language development; delayed acquisition of phrase language distinguishes those with high-functioning autism (HFA) from others with Asperger's syndrome, who use phrase language prior to 36 months (Gilchrist et al., 2001; Howlin, 2003; Ozonoff, Rogers, & Pennington, 1991; Szatmari, Archer, Fisman, Streiner, & Wilson, 1995). However, as discussed by Lotspeich and colleagues (2004), the diagnosis of autism takes precedence over Asperger's syndrome, resulting in some degree of diagnostic overlap, and it is unclear whether the unique language features of Asperger's

syndrome are sufficient to render it a specific category (Klin & Volkmar, 2003; Rinehart, Bradshaw, Breton, & Tonge, 2002a).

Asperger's original description of his eponymous syndrome captured children with similar difficulties in social interaction, greater motor problems and less speech delay than those with Kanner's autism (Volkmar, Klin, & Pauls, 1998). More extensive differences in autism and Asperger's have since been described. Performance IQ may be greater than verbal IQ in autism, not Asperger's, and people with autism have reportedly better visual–motor integration, visual-spatial perception, visual memory, and nonverbal reasoning, but more deficits in auditory perception, verbal memory and vocabulary than Asperger's (Klin, Volkmar, Sparrow, Cicchetti, & Rourke, 1995). However, in an extensive review of the empirical evidence, Macintosh and Dissanayake (2004) found the differences were too limited to justify a distinction between Asperger's syndrome and autism and high-functioning autism.

Conflict of interest statement: No conflicts declared.

© 2008 The Authors

Journal compilation © 2008 Association for Child and Adolescent Mental Health.

Published by Blackwell Publishing, 9600 Garsington Road, Oxford OX4 2DQ, UK and 350 Main Street, Malden, MA 02148, USA

MRI studies of autism spectrum disorders have implicated a distributed network of grey matter volume abnormalities, incorporating brain areas thought to be important for social and executive function including prefrontal, temporal, striatal and cerebellar regions (Abell et al., 1999; Carper & Courchesne, 2005; Courchesne, 1997, 1999; McAlonan et al., 2005; Sears et al., 1999; Tsatsanis et al., 2003; Waiter et al., 2004). Thus, the complex phenotype of autism is considered to reflect disruption at a supra-regional, brain systems level rather than some focal lesion (McAlonan et al., 2005, 2002), and the many inconsistencies in the literature (Brambilla et al., 2003) may reflect the heterogeneity within the disorder. MRI studies do not routinely separate patients with HFA from Asperger's, potentially exacerbating the confusion in the literature.

Haznedar and colleagues (Haznedar et al., 2006) recently found that adult men with autism spectrum disorder (10 HFA, 7 Asperger's syndrome) had greater right caudate volumes than controls and lower metabolic activity in striato-pallidal-thalamic regions despite no overall group differences in brain volume. They found lower metabolic activity in the ventral thalamus in those with HFA compared to Asperger's syndrome. Taken together, these and other findings (Chugani et al., 1997; Sears et al., 1999; Tsatsanis et al., 2003) implicate disruption within striato-thalamo-cortical circuits in the spectrum, but point to differences in the extent to which the brain is affected by HFA or Asperger's syndrome. In a 2-site MRI study of Asperger's, HFA and low functioning autism (LFA), grey matter volumes were reported to be significantly greater in HFA and LFA, but not Asperger's (Lotspeich et al., 2004). This result placed Asperger's on the mild end of the spectrum of brain change. However, in a subset of boys from that study scanned at 1 site, more grey matter deficits were reported for Asperger's (11) compared to HFA (9) (Kwon, Ow, Pedatella, Lotspeich, & Reiss, 2004).

Thus, the extent to which the history of language acquisition can act as a marker to separate heterogeneous neurobiology in intellectually able children with pervasive developmental disorders is unclear. We planned a well-powered voxel-based study of Asperger's syndrome and HFA using datasets acquired on a single scanner. We tested the hypothesis that regional grey matter volumes would distinguish children with Asperger's from HFA and controls. We also planned to confirm that combining Asperger's and HFA datasets would generate a mixed picture consistent with previous reports (McAlonan et al., 2005, 2002).

## Methods

### Participants

Eighty-eight ethnic Chinese, right-handed children aged 7–16 years old with IQ > 70 (estimated using the

vocabulary subset of the Wechsler Intelligence Scale for Children) participated in the study. Exclusion criteria were co-morbid psychiatric (e.g., mood disorder or attention deficit-hyperactivity disorder) or medical conditions (e.g., epilepsy) requiring intervention, history of head injury, or genetic disorder associated with autism (e.g., tuberous sclerosis or fragile X syndrome). Thirty-three were non-medicated children who had an independent clinical diagnosis of autism spectrum disorder recruited from local psychiatry services (17 had been recruited for a previous study; McAlonan et al., 2005). Parents were interviewed using the Autism Diagnostic Interview – Revised (ADI-R; Lord et al., 1994). Adopting the same categorisation as other neuroimaging studies (Kwon et al., 2004; Lotspeich et al., 2004): 16 (3 females) had Asperger's syndrome (7 from our 2005 study) with phrase speech acquired prior to 36 months; 17 (3 females) had HFA with a history of delayed language acquisition (10 from our 2005 study). The children did not differ in diagnostic algorithm scores of the ADI-R: ADIA, reciprocal social interaction; ADIB, communication; and ADIC, restricted, repetitive, stereotypical behaviour (see Table 1). Fifty-five typically developing control children (8 females) were recruited from local schools and screened for major psychiatric illness using the Diagnostic Interview Schedule for Children for DSM-IV (17 had been recruited for our 2005 study). They did not differ in mean age or verbal IQ (see Table 1), maternal language or ethnicity from the autism spectrum group. Every child's parent gave informed consent for the protocol approved by the University of Hong Kong Faculty of Medicine Research Ethics Committee, and each child gave their assent.

### MR imaging and analysis

Images were acquired across the whole brain on a GE Signa 1.5 Tesla system (General Electric, Milwaukee, WI, USA) in Queen Mary Hospital, Hong Kong. Data collection used an interleaved dual-echo fast-spin echo (FSE) sequence with repetition time, TR = 3000 ms, echo times, TE1 = 20 ms (proton density weighted images) and TE2 = 100 ms (T2-weighted images). Acquisition was in the axial plane (aligned to the AC-PC line) with contiguous slices .859 mm in-plane and 3 mm thick. Every scan was screened by a consultant radiologist to exclude gross morphological differences. Voxel-wise group differences in grey matter volume were examined by non-parametric methods using BAMB software (Brain Analysis Morphological Mapping version 2.5, <http://www-bmu.psychiatry.cam.ac.uk/BAMB/index.html>) on a SPARC workstation (Sun Microsystems Europe Inc.) as done previously (McAlonan et al., 2007, 2005, 2002). There were three main comparisons:

- i) HFA compared to Asperger's;
- ii) HFA compared to control;
- iii) Asperger's syndrome compared to control;

and one secondary comparison:

- iv) combined Asperger's and HFA group compared to controls.

The statistical thresholds were corrected for multiple comparisons by controlling the 'family wise error rate'

**Table 1** Group characteristics

	Contrast	Mean	Standard deviation	Test statistics
ADIA	ASP	20.1	3.65	$t = -.22$
	HFA	20.5	5.84	$p = .83$
ADIB	ASP	14.7	4.50	$t = .65$
	HFA	13.8	3.07	$p = .52$
ADIC	ASP	4.9	2.38	$t = -.08$
	HFA	5.0	2.06	$p = .94$
AGE (years)	ASP	11.7	2.78	$t = .33$
	HFA	11.4	2.48	$p = .74$
	Control	10.7	2.74	$t = -1.47$
	PDD	11.6	2.59	$p = .14$
VIQ	ASP	109.1	16.9	$t = 1.34$
	HFA	117.4	18.4	$p = .19$
	Control	117.1	18.1	$t = .94$
	PDD	113.2	17.9	$p = .35$

PDD, combined group with autism spectrum,  $n = 33$ . ASP, Asperger's syndrome,  $n = 16$ . HFA, high-functioning autism,  $n = 17$ . VIQ, pro-rated verbal IQ.

ADI-R diagnostic algorithm: ADIA, social interaction; ADIB, communication; ADIC, repetitive behaviours.

such that  $<1$  false positive cluster (fpc) was expected under the null-hypothesis. A cluster of grey matter volume difference was defined as smaller or greater relative to control group apart from in the Asperger's-HFA comparison where volume differences were labelled relative to Asperger's. We extracted the volumes derived from group differences analyses for exploration of effect sizes using partial eta squared measures in SPSS (Olejnik & Algina, 2003). Post-hoc, we investigated potential correlations between the grey matter volume abnormalities in left prefrontal language areas and the age of first use of phrase speech in HFA.

## Results

### Main comparisons

(i) *HFA compared to Asperger's syndrome.* Total grey matter volume was not significantly different across these groups. Regional brain volumes of the thalamus and pallidum were significantly smaller in HFA compared to Asperger's ( $p < .002$ ; fpc  $< 1$ ) and the effect sizes were large (.48 and .72 respectively), see Table 2 and Figure 1.

(ii) *HFA compared to control.* The HFA group had slightly smaller total grey matter volumes compared to controls, although the effect size was small: partial eta squared = .06,  $p = .03$ . However, this group had extensive fronto-pallidal grey matter clusters with smaller volume relative to controls ( $p < .002$ ; fpc  $< 1$ ). The effect sizes were good (e.g., partial eta squared .52 for anterior cingulate), see Table 2 and Figure 1. The areas affected in the frontal lobe in HFA compared to controls were predominantly found in the left hemisphere and extended to BA44 language area. We found significant negative correlation between age in months when phrase speech was acquired and grey matter volume within

this cluster; smaller volumes were associated with an older age of phrase speech acquisition in the HFA group (Spearman's rho =  $-.554$ ;  $p = .01$ ).

(iii) *Asperger's syndrome compared to control.* There was no difference in total grey matter volume in Asperger's syndrome and controls. However, children with Asperger's syndrome had significantly less grey matter in the striatum, thalamus and posterior brain regions ( $p < .002$ ; fpc  $< 1$ ; Figure 1). The effect sizes were sizeable (e.g., partial eta squared = .58 for precuneus), see Table 2. There were no areas with greater grey matter volume in Asperger's compared to controls.

### Secondary comparison

*Combined Asperger's and HFA group compared to control.* Total grey matter volumes were smaller in the combined group relative to controls, but the effect size was small; partial eta squared = .05,  $p = .03$ . Compared to controls, children in the combined group had smaller regional grey matter volumes in left dorsolateral prefrontal cortex, bilateral basal ganglia (though more pronounced in the left hemisphere), inferior cerebellar vermis, left superior temporal cortex and bilateral posterior parietal cortices ( $p < .002$ ; fpc  $< 1$ ). However, the effect sizes were modest with partial eta squared ranging from .19 to .53 (Table 3). The lowest effect size (.16) was found for the cerebellum, while the greatest effect sizes were in the left temporo-parietal and precuneus regions (both .53).

## Discussion

Our main finding is that patterns of regional grey matter abnormalities in children with HFA and Asperger's syndrome can be distinguished. Children with HFA had significantly smaller grey matter volumes in subcortical, posterior cingulate and precuneus regions than the Asperger's group. The comparison of each subgroup with typically developing controls also resulted in distinct patterns of abnormality. Children with HFA had smaller fronto-pallidal grey matter volumes relative to typically developing control children; children with Asperger's syndrome had smaller grey matter volumes in bilateral caudate, left thalamus and parietal lobe relative to controls. Importantly, scores on the ADI-R diagnostic algorithm were not different in the Asperger's and HFA groups as defined here. Therefore, the particular brain phenotype we describe here does not reflect any obvious differences in the core diagnostic features which define the pervasive developmental disorders. Instead, the history of language acquisition appears to function as a marker distinguishing heterogeneous brain phenotypes within the autism spectrum.

**Table 2** Grey matter volumes in Asperger's syndrome and HFA

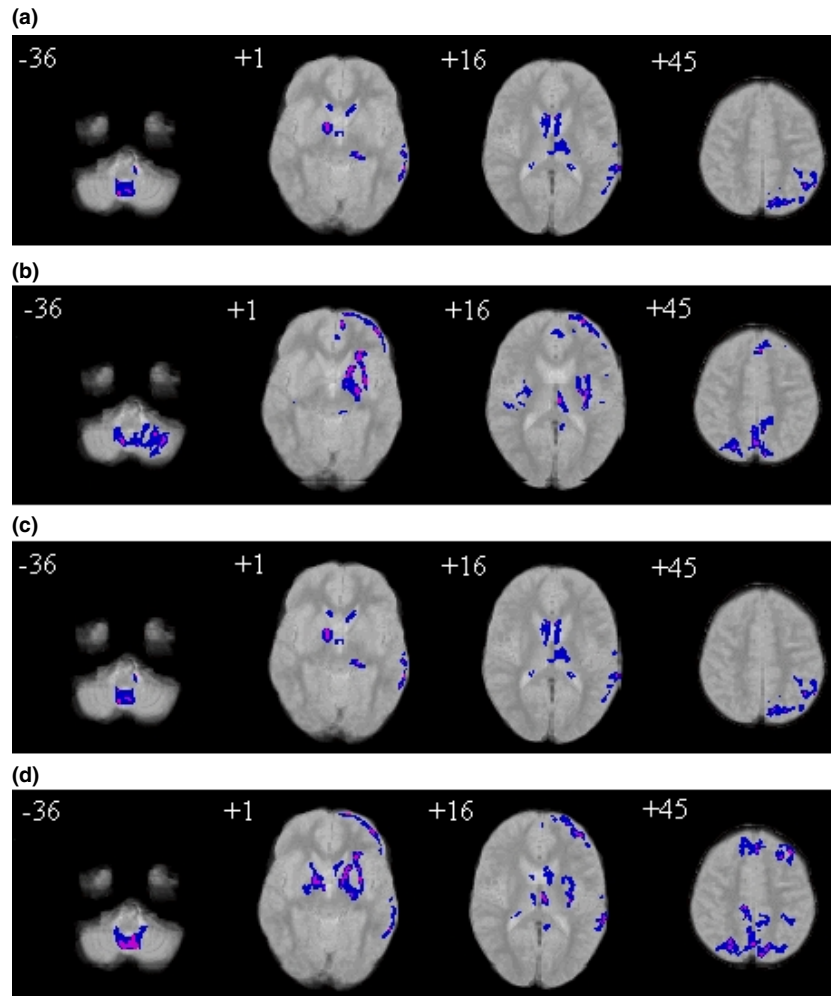
	Group	Mean (mls)	Standard Deviation	Partial Eta Sq	Voxel number
<b>Asperger's and HFA</b>					
Putamen/GP/thalamus	HFA	1.032076	.2066922	.475	526
-17.8 -8.8 2.9	ASP	1.427750	.2222785		
Precun, post cingulate (BA7,31)	HFA	.951306	.0834043	.720	294
-3.0 -52.6 39.6	ASP	1.275419	.1226707		
Total Grey Matter	HFA	590.73961	42.273380	.024	$p = .39$
	ASP	602.46024	34.027122		
<b>HFA and controls</b>					
Cerebellum	HFA	1.546712	.3628790	.181	453
-10.3 -56.3 -37.3	CON	1.876882	.2821483		
Putamen/Globus Pallidus	HFA	3.760812	.4170102	.372	1184
-23.2 2.4 4.4	CON	4.821553	.6364933		
Insula/putamen	HFA	.962988	.1740122	.316	261
35.8 -16.7 14.8	CON	1.193360	.1363650		
Thalamus, hippocampus, PHG	HFA	.645471	.1378846	.228	194
-6.2 -23.9 10.9	CON	.811407	.1294837		
Prefrontal (BA10,11,32,44,46)	HFA	3.943147	.5607216	.515	1198
-26.0 46.1 11.8	CON	5.013538	.4072240		
Med, sup frontal gyrus (BA9,8)	HFA	1.070782	.1150876	.383	296
-2.5 38.2 33.3	CON	1.330340	.1490502		
Postcentral gyrus (BA2)	HFA	.767306	.1422815	.438	224
-48.3 -21.8 26.3	CON	1.042062	.1316187		
Parieto-occip (BA7,19,31,4)	HFA	3.572100	.2897264	.575	996
2.8 -53.3 44.7	CON	4.527851	.3706761		
Total Grey Matter	HFA	590.739618	42.273380	.064	$p = 0.03$
	CON	616.319562	41.993546		
<b>Asperger's and controls</b>					
Brain stem and cerebellum	ASP	.824781	.2850136	.181	196
2.3 -53.7 -37.3	CON	1.098229	.2348829		
Caudate and thalamus	ASP	1.808350	.3657773	.413	1044
0.0 -4.8 12.4	CON	2.349364	.2415541		
Inf parietal, STG (BA22,40,42)	ASP	2.831194	.2936710	.579	766
-51.3 -36.8 24.2	CON	3.501069	.2254382		
Precun, pre/postcentral (BA4,5,7)	ASP	2.270681	.2284763	.539	631
-19.3 -47.0 52.7	CON	2.900731	.2515846		
Total Grey Matter	ASP	602.4602	34.02712	.021	$p$ ns
	CON	616.3195	41.99354		

A sample Talaraich co-ordinate (x,y,z) is given for the approximate centre of each cluster. BA, Brodman's Area. p ns, no significant difference. The 3D clusters are not confined to these areas, nor are they all encompassing. GP, Globus pallidum; Precun, precuneus; Med, medial; Sup, superior; Inf, Inferior; STG, superior temporal gyrus; CON, control; ASP, Asperger's syndrome; HFA, high functioning autism. HFA  $n = 17$ ; Asperger's syndrome  $n = 16$ ; Controls  $n = 55$ .

When the Asperger's and HFA groups were combined (as is the usual practice in MRI studies) and compared to controls, the results picture was mixed. Unsurprisingly, the brain areas affected (fronto-striatal and midline parietal) were broadly similar to our 2005 study, which sampled a proportion of the children included here. However, many effect sizes of the total group comparison were modest, suggesting that, in MRI studies of autism, the pattern of results from study to study will vary depending on the make-up of the group. This may partly explain replication difficulties in the literature.

Common to all groups with pervasive developmental disorder were smaller temporo-parietal volumes around the superior temporal sulcus, and smaller posterior cingulate and precuneus volumes. The effect sizes of these contrasts were sizeable. This is consistent with previous reports of abnormalities in these regions (Boddaert et al., 2004; Kwon et al., 2004; Lotspeich et al., 2004; McAlonan et al., 2005,

2002; Zilbovicius et al., 2006). The abnormalities in the superior temporal sulcus, important for judging changeable characteristics of faces such as eye gaze, expression and lip movement (Haxby, Hoffman, & Gobbini, 2000, 2002; Haxby, Petit, Ungerleider, & Courtney, 2000), fit with the difficulties people from all parts of the autism spectrum have in decoding faces (Adolphs, Sears, & Piven, 2001; Bailey, Braeutigam, Jousmaki, & Swithenby, 2005; Castelli, 2005; Grelotti, Gauthier, & Schultz, 2002; Schultz, 2005; Schultz et al., 2003). In functional imaging studies posterior midline areas are typically active during rest, possibly reflecting introspective or autobiographical processes which stop when behaviour becomes externally directed, leading to functional deactivation (Raichle et al., 2001). These regions have lower metabolic activity in autism (Haznedar et al., 2000) and functional deactivation during demanding cognitive tasks does not appear to zhappen (Kennedy, Redcay, & Courchesne, 2006).



**Figure 1** Relative deficit clusters (blue) in grey matter volume in children with autism (a) HFA relative to Asperger's syndrome (b) HFA relative to controls. (c) Asperger's syndrome relative to controls. (d) Total autism group relative to controls. The maps are orientated with the right side of the brain shown on the left side of each panel. The z coordinate for each axial slice in the standard space of Talairach and Tournoux is given in millimetres

In the latter study, the authors speculated that lower midline activity at rest in autism is accompanied by abnormal internal thought processes. The smaller midline volumes observed here potentially constitute a structural correlate of this finding. In particular, our observation the HFA group has even lower grey matter volumes in the posterior midline cortices than Asperger's should prompt further investigation into functional characteristics of these groups at rest.

In the separate comparisons of HFA and Asperger's groups to controls, patterns of grey matter differences did not fully overlap. Lower grey matter volumes were localised in caudate and thalamus in Asperger's, but were predominantly fronto-pallidal in HFA. Notably, frontal lobe deficits in the HFA group incorporated the left inferior frontal gyrus BA44, Brodmann's language area. Consistent with the language delay which discriminated the HFA group, the age in months of acquisition of phrase language was negatively correlated with grey matter volume in this region. We cannot say from our data whether

this correlation reflects delayed language development or altered brain maturation in the frontal lobe. The developmental trajectory of brain in children with autism is very different to typically developing children. At birth head circumference is small, followed by a rapid, large expansion in brain size over 2 years (Carper, Moses, Tigue, & Courchesne, 2002; Courchesne, 2002, 2004; Courchesne, Carper, & Akshoomoff, 2003). Brain growth then slows and overall brain sizes of older children and adults are similar to controls (Redcay & Courchesne, 2005). In general, the frontal lobe is differentially enlarged in young children with autism (Carper & Courchesne, 2000, 2005) and in those individuals with large frontal lobes the cerebellum is smaller (Carper & Courchesne, 2000). In the context of these studies of brain development in the autism spectrum, our observation of frontal lobe differences in HFA, rather than Asperger's syndrome, is striking. Whether the history of language acquisition is also a marker for distinct patterns of brain maturation will be important to explore in a longitudinal design.

**Table 3** Grey matter volumes in the combined autism group compared to controls

Controls and combined PDD					
Brain stem and cerebellum	PDD	1.1699	.32853	.161	291
0.3 -52.5 -37.1	CON	1.4311	.26813		
Striatum and globus pallidus	PDD	3.3657	.47595	.301	977
-22.8 4.2 4.4	CON	4.0173	.49224		
Caudate	PDD	1.2024	.27077	.196	617
0.2 -7.4 17.8	CON	1.4744	.26874		
Putamen and globus pallidus	PDD	.6040	.09986	.190	275
14.4 0.7 3.5	CON	.7256	.13502		
STG/Inf parietal (BA42,40)	PDD	2.2587	.25632	.530	627
-53.8 -29.4 16.7	CON	2.7571	.21263		
Prefrontal lobe (BA9, 10, 46, 47)	PDD	3.8349	.46641	.428	1038
-29.0 44.9 21.3	CON	4.5432	.35616		
Medial prefrontal (BA8)	PDD	.9694	.12566	.364	234
1.4 36.3 42.4	CON	1.1521	.11373		
Pre, post central gyrus (BA4,5)	PDD	.7593	.11065	.369	201
-32.4 -39.6 54.2	CON	.9165	.09442		
Precuneus (BA7)	PDD	5.6902	.47350	.533	1509
1.1 -50.2 46.8	CON	6.8281	.54824		
Total grey matter	PDD	596.4223	38.36200	.054	<i>p</i> = .029
	CON	616.3196	41.99355		

A sample Talaraich co-ordinate (x,y,z) is given for the approximate centre of each cluster. BA, Brodman's Area. The 3D clusters are not confined to these areas, nor are they all encompassing. Inf, Inferior; STG, superior temporal gyrus; CON, control; PDD, combined group with autism spectrum. Autism Spectrum *n* = 33; Controls *n* = 55.

Our results should not be taken to mean that the differences in brain structure in HFA and Asperger's are necessarily due to language delay. There are other possible explanations, such as differences in executive or motoric function (Nayate et al., 2005; Rinehart et al., 2006a; Rinehart, Bradshaw, Brereton, & Tonge, 2002b; Rinehart, Bradshaw, Moss, Brereton, & Tonge, 2006b; Rinehart, Bradshaw, Moss, Brereton, & Tonge, 2001; Rinehart et al., 2006c). We emphasise that language acquisition may simply be a useful marker. For example, lower grey matter volumes in the left prefrontal cortex of the HFA group also fit well with reports of a 'left hemisphere executive-function specific impairment' in HFA but not Asperger's syndrome (Rinehart et al., 2002b), including preserved set-shifting ability in Asperger's syndrome (Rinehart et al., 2001).

Further evidence for specific cortico-striatal differences between individuals with Asperger's and HFA can be drawn from other imaging techniques. Increases in presynaptic dopamine function in the fronto-striatal areas of adults with Asperger's (Nieminen-von Wendt et al., 2005) contrast with a report of reduction in medial prefrontal dopamine activity and no change in striatal activity in autism (Ernst et al., 1997). Importantly, the sample characteristics of the 2 studies were very different. A number of participants in the Ernst et al., study most certainly had classical autism, given the reported IQ range of 46–123; those in the Nieminen-von Wendt et al. study had Asperger's syndrome (IQ 97–140). Thus structural differences in fronto-striatal circuitry could well have impacted upon the outcome.

The findings of increased dopamine activity in the caudate of people with Asperger's syndrome (Nieminen-von Wendt et al., 2005) mirror

observations in schizophrenia (Lindstrom et al., 1999). Moreover, caudate abnormalities similar to those found in the Asperger's group are found in schizophrenia early in the course of illness (at first episode) and prior to treatment with antipsychotic medication (Chua et al., 2007). Interestingly, although autism spectrum disorder has high heritability (Gupta & State, 2007), people with Asperger's syndrome have been reported to have a strong family history of schizophrenia and bipolar disorder (Ghaziuddin, 2005). People with Asperger's syndrome have higher scores on measures of paranoia than healthy controls (Craig, Hatton, Craig, & Bentall, 2004) and 'negative' symptoms in Asperger's syndrome may respond to the antipsychotic risperidone (Rausch et al., 2005). A genome-wide scan for susceptibility loci in Asperger's syndrome found loci which overlapped with previously identified loci for autism, while others overlapped with previously identified loci for schizophrenia (Ylisaukko-oja et al., 2004). These observations raise the possibility that the pervasive developmental disorders and schizophrenia share genetic influences. We speculate that a particular complement of common susceptibility genes and environmental factors during neurodevelopment drives subgroup-specific pathology within cortico-striatal circuits. Caudate, globus pallidus, thalamus and frontal lobe have intimate interconnections organised in a system of parallel loops (Alexander, Crutcher, & DeLong, 1990; Alexander, DeLong, & Strick, 1986; DeLong & Wichmann, 2007). Disruption at different parts of the same loop system could theoretically lead to similar core behavioural features as described by the ADI-R, in addition to region specific differences in executive or motoric function (Nayate, Bradshaw, & Rinehart,

2005; Rinehart et al., 2006a, 2002b, 2001, 2006b, 2006c).

The present study has a number of limitations. The numbers in the separate Asperger's and HFA groups were less than in the combined group, so lowering statistical power. However, the large effect sizes obtained, despite fewer numbers, suggests that more homogenous subject groupings may be a critical consideration in brain imaging in autism spectrum disorders. Except for their history of language acquisition, the groups with pervasive developmental disorders in our study were diagnostically very similar. While this highlights the use of language as a discriminatory marker to identify subgroups within the spectrum, our study did not directly explore whether other features, such as motor or executive function, relate to the brain phenotypes reported. We only included intellectually able children so we cannot say whether the results can be extrapolated to an adult population or LFA. The plan is to follow up this cohort to determine whether there are longitudinal differences in ageing in Asperger's syndrome and HFA.

In conclusion, our study suggests that the autism spectrum maps onto a spectrum of brain abnormalities. Using the history of language acquisition as a marker for HFA and Asperger's syndrome, we found that these subgroups have partially distinguishable neurobiological bases. A better understanding of the heterogeneity of pervasive developmental disorder will refine our search for causative factors and promote more tailored approaches to treatment.

## Acknowledgements

This work was supported by a University of Hong Kong grant to S.E. Chua. We thank Ms Michelle Deng for her help with image preparation.

## Correspondence to

Gráinne M. McAlonan, Department of Psychiatry, University of Hong Kong, Pokfulam, Hong Kong SAR China; Tel: + (852) 2855 4486; Fax: + (852) 2855 1345; Email: mcalonan@hkucc.hku.hk

## References

- Abell, F., Krams, M., Ashburner, J., Passingham, R., Friston, K., Frackowiak, R., Happé, F., Frith, C., & Frith, U. (1999). The neuroanatomy of autism: A voxel-based whole brain analysis of structural scans. *Neuroreport*, *10*, 1647–1651.
- Adolphs, R., Sears, L., & Piven, J. (2001). Abnormal processing of social information from faces in autism. *Journal of Cognitive Neuroscience*, *13*, 232–240.
- Alexander, G.E., Crutcher, M.D., & DeLong, M.R. (1990). Basal ganglia-thalamocortical circuits: Parallel substrates for motor, oculomotor, 'prefrontal' and 'limbic' functions. *Progress in Brain Research*, *85*, 119–146.
- Alexander, G.E., DeLong, M.R., & Strick, P.L. (1986). Parallel organization of functionally segregated circuits linking basal ganglia and cortex. *Annual Review of Neuroscience*, *9*, 357–381.
- Bailey, A.J., Braeutigam, S., Jousmaki, V., & Switkenby, S.J. (2005). Abnormal activation of face processing systems at early and intermediate latency in individuals with autism spectrum disorder: A magnetoencephalographic study. *European Journal of Neuroscience*, *21*, 2575–2585.
- Boddaert, N., Chabane, N., Gervais, H., Good, C.D., Bourgeois, M., Plumet, M.H., Barthelemy, C., Mourren, M.C., Artiges, E., Samson, Y., Brunelle, F., Frackowiak, R.S., & Zilbovicius, M. (2004). Superior temporal sulcus anatomical abnormalities in childhood autism: A voxel-based morphometry MRI study. *Neuroimage*, *23*, 364–369.
- Brambilla, P., Hardan, A., di Nemi, S.U., Perez, J., Soares, J.C., & Barale, F. (2003). Brain anatomy and development in autism: Review of structural MRI studies. *Brain Research Bulletin*, *61*, 557–569.
- Carper, R.A., & Courchesne, E. (2000). Inverse correlation between frontal lobe and cerebellum sizes in children with autism. *Brain*, *123*(Pt 4), 836–844.
- Carper, R.A., & Courchesne, E. (2005). Localized enlargement of the frontal cortex in early autism. *Biological Psychiatry*, *57*, 126–133.
- Carper, R.A., Moses, P., Tigue, Z.D., & Courchesne, E. (2002). Cerebral lobes in autism: Early hyperplasia and abnormal age effects. *Neuroimage*, *16*, 1038–1051.
- Castelli, F. (2005). Understanding emotions from standardized facial expressions in autism and normal development. *Autism*, *9*, 428–449.
- Chua, S.E., Cheung, C., Cheung, V., Tsang, J.T., Chen, E.Y., Wong, J.C., Cheung, J.P., Yip, L., Tai, K.S., Suckling, J., & McAlonan, G.M. (2007). Cerebral grey, white matter and csf in never-medicated, first-episode schizophrenia. *Schizophrenia Research*, *89*, 12–21.
- Chugani, D.C., Muzik, O., Rothermel, R., Behen, M., Chakraborty, P., Mangner, T., da Silva, E.A., & Chugani, H.T. (1997). Altered serotonin synthesis in the dentatohalamocortical pathway in autistic boys. *Annals of Neurology*, *42*, 666–669.
- Courchesne, E. (1997). Brainstem, cerebellar and limbic neuroanatomical abnormalities in autism. *Current Opinion in Neurobiology*, *7*, 269–278.
- Courchesne, E. (1999). An MRI study of autism: The cerebellum revisited. *Neurology*, *52*, 1106–1107.
- Courchesne, E. (2002). Abnormal early brain development in autism. *Molecular Psychiatry*, *7*(Suppl. 2), S21–23.
- Courchesne, E. (2004). Brain development in autism: Early overgrowth followed by premature arrest of growth. *Mental Retardation and Developmental Disability Research Review*, *10*, 106–111.
- Courchesne, E., Carper, R., & Akshoomoff, N. (2003). Evidence of brain overgrowth in the first year of life in autism. *Journal of the American Academy of Medicine*, *290*, 337–344.
- Craig, J.S., Hatton, C., Craig, F.B., & Bentall, R.P. (2004). Persecutory beliefs, attributions and theory of

- mind: Comparison of patients with paranoid delusions, Asperger's syndrome and healthy controls. *Schizophrenia Research*, 69, 29–33.
- DeLong, M.R., & Wichmann, T. (2007). Circuits and circuit disorders of the basal ganglia. *Archives of Neurology*, 64, 20–24.
- Ernst, M., Zametkin, A.J., Matochik, J.A., Pascualvaca, D., & Cohen, R.M. (1997). Low medial prefrontal dopaminergic activity in autistic children. *Lancet*, 350, 638.
- Ghaziuddin, M. (2005). A family history study of Asperger syndrome. *Journal of Autism and Developmental Disorders*, 35, 177–182.
- Gilchrist, A., Green, J., Cox, A., Burton, D., Rutter, M., & Le Couteur, A. (2001). Development and current functioning in adolescents with Asperger syndrome: A comparative study. *Journal of Child Psychology and Psychiatry*, 42, 227–240.
- Grelotti, D.J., Gauthier, I., & Schultz, R.T. (2002). Social interest and the development of cortical face specialization: What autism teaches us about face processing. *Developmental Psychobiology*, 40, 213–225.
- Gupta, A.R., & State, M.W. (2007). Recent advances in the genetics of autism. *Biological Psychiatry*, 61, 429–437.
- Haxby, J.V., Hoffman, E.A., & Gobbini, M.I. (2000b). The distributed human neural system for face perception. *Trends in Cognitive Sciences*, 4, 223–233.
- Haxby, J.V., Hoffman, E.A., & Gobbini, M.I. (2002). Human neural systems for face recognition and social communication. *Biological Psychiatry*, 51, 59–67.
- Haxby, J.V., Petit, L., Ungerleider, L.G., & Courtney, S.M. (2000a). Distinguishing the functional roles of multiple regions in distributed neural systems for visual working memory. *Neuroimage*, 11(5 Pt 1), 380–391.
- Haznedar, M.M., Buchsbaum, M.S., Hazlett, E.A., LiCalzi, E.M., Cartwright, C., & Hollander, E. (2006). Volumetric analysis and three-dimensional glucose metabolic mapping of the striatum and thalamus in patients with autism spectrum disorders. *American Journal of Psychiatry*, 163, 1252–1263.
- Haznedar, M.M., Buchsbaum, M.S., Wei, T.C., Hof, P.R., Cartwright, C., Bienstock, C.A., & Hollander, E. (2000). Limbic circuitry in patients with autism spectrum disorders studied with positron emission tomography and magnetic resonance imaging. *American Journal of Psychiatry*, 157, 1994–2001.
- Howlin, P. (2003). Outcome in high-functioning adults with autism with and without early language delays: Implications for the differentiation between autism and Asperger syndrome. *Journal of Autism and Developmental Disorders*, 33, 3–13.
- Kennedy, D.P., Redcay, E., & Courchesne, E. (2006). Failing to deactivate: Resting functional abnormalities in autism. *Proceedings of the National Academy of Science USA*, 103, 8275–8280.
- Klin, A., & Volkmar, F.R. (2003). Asperger syndrome: Diagnosis and external validity. *Child and Adolescent Psychiatry Clinics of North America*, 12, 1–13.
- Klin, A., Volkmar, F.R., Sparrow, S.S., Cicchetti, D.V., & Rourke, B.P. (1995). Validity and neuropsychological characterisation of Asperger syndrome: Convergence with nonverbal learning disabilities syndrome. *Journal of Child Psychology and Psychiatry*, 36, 1127–1140.
- Kwon, H., Ow, A.W., Pedatella, K.E., Lotspeich, L.J., & Reiss, A.L. (2004). Voxel-based morphometry elucidates structural neuroanatomy of high-functioning autism and Asperger syndrome. *Developmental Medicine and Child Neurology*, 46, 760–764.
- Lindstrom, L.H., Gefvert, O., Hagberg, G., Lundberg, T., Bergstrom, M., Hartvig, P., & Langstrom, B. (1999). Increased dopamine synthesis rate in medial prefrontal cortex and striatum in schizophrenia indicated by L-(beta-11C) DOPA and PET. *Biological Psychiatry*, 46, 681–688.
- Lotspeich, L.J., Kwon, H., Schumann, C.M., Fryer, S.L., Goodlin-Jones, B.L., Buonocore, M.H., Lammers, C.R., Amaral, D.G., & Reiss, A.L. (2004). Investigation of neuroanatomical differences between autism and Asperger syndrome. *Archives of General Psychiatry*, 61, 291–298.
- Macintosh, K.E., & Dissanayake, C. (2004). Annotation: The similarities and differences between autistic disorder and Asperger's disorder: A review of the empirical evidence. *Journal of Child Psychology and Psychiatry*, 45, 421–434.
- McAlonan, G.M., Cheung, V., Cheung, C., Chua, S.E., Murphy, D.G., Suckling, J., Simmons, A., Sigmundsson, T., Greenwood, K., Russell, A., Schmitz, N., Happé, F., Howlin, P., & Murphy, D.G. (2007). Mapping brain structure in attention deficit-hyperactivity disorder: A voxel-based MRI study of regional grey and white matter volume. *Psychiatry Research Neuroimaging*, 154, 171–180.
- McAlonan, G.M., Cheung, V., Cheung, C., Suckling, J., Lam, G.Y., Tai, K.S., Yip, L., Murphy, D.G., & Chua, S.E. (2005). Mapping the brain in autism. A voxel-based MRI study of volumetric differences and intercorrelations in autism. *Brain*, 128(Pt 2), 268–276.
- McAlonan, G.M., Daly, E., Kumari, V., Critchley, H.D., van Amelsvoort, T., Suckling, J., Tai, K.S., Yip, L.K., Leung, P., & Ho, T.P. (2002). Brain anatomy and sensorimotor gating in Asperger's syndrome. *Brain*, 125(Pt 7), 1594–1606.
- Nayate, A., Bradshaw, J.L., & Rinehart, N.J. (2005). Autism and Asperger's disorder: Are they movement disorders involving the cerebellum and/or basal ganglia? *Brain Research Bulletin*, 67, 327–334.
- Nieminen-von Wendt, T., Paavonen, J.E., Ylisaukko-Oja, T., Sarenus, S., Kallman, T., Jarvela, I., & von Wendt, L. (2005). Subjective face recognition difficulties, aberrant sensibility, sleeping disturbances and aberrant eating habits in families with Asperger syndrome. *BioMed Central Psychiatry*, 5, 20.
- Olejnik, S., & Algina, J. (2003). Generalized eta and omega squared statistics: Measures of effect size for some common research designs. *Psychology Methods*, 8, 434–447.
- Ozonoff, S., Rogers, S.J., & Pennington, B.F. (1991). Asperger's syndrome: Evidence of an empirical distinction from high-functioning autism. *Journal of Child Psychology and Psychiatry*, 32, 1107–1122.
- Raichle, M.E., MacLeod, A.M., Snyder, A.Z., Powers, W.J., Gusnard, D.A., & Shulman, G.L. (2001). A default mode of brain function. *Proceedings of the National Academy of Science USA*, 98, 676–682.



- Rausch, J.L., Sirota, E.L., Londino, D.L., Johnson, M.E., Carr, B.M., Bhatia, R., & Miller, S. (2005). Open-label risperidone for Asperger's disorder: Negative symptom spectrum response. *Journal of Clinical Psychiatry*, *66*, 1592–1597.
- Redcay, E., & Courchesne, E. (2005). When is the brain enlarged in autism? A meta-analysis of all brain size reports. *Biological Psychiatry*, *58*, 1–9.
- Rinehart, N.J., Bellgrove, M.A., Tonge, B.J., Brereton, A.V., Howells-Rankin, D., & Bradshaw, J.L. (2006a). An examination of movement kinematics in young people with high-functioning autism and Asperger's disorder: Further evidence for a motor planning deficit. *Journal of Autism and Developmental Disorders*, *36*, 757–767.
- Rinehart, N.J., Bradshaw, J.L., Brereton, A.V., & Tonge, B.J. (2002a). A clinical and neurobehavioural review of high-functioning autism and Asperger's disorder. *Australian and New Zealand Journal of Psychiatry*, *36*, 762–770.
- Rinehart, N.J., Bradshaw, J.L., Brereton, A.V., & Tonge, B.J. (2002b). Lateralization in individuals with high-functioning autism and Asperger's disorder: A frontostriatal model. *Journal of Autism and Developmental Disorders*, *32*, 321–331.
- Rinehart, N.J., Bradshaw, J.L., Moss, S.A., Brereton, A.V., & Tonge, B.J. (2001). A deficit in shifting attention present in high-functioning autism but not Asperger's disorder. *Autism*, *5*, 67–80.
- Rinehart, N.J., Bradshaw, J.L., Moss, S.A., Brereton, A.V., & Tonge, B.J. (2006b). Pseudo-random number generation in children with high-functioning autism and Asperger's disorder: Further evidence for a dissociation in executive functioning? *Autism*, *10*, 70–85.
- Rinehart, N.J., Tonge, B.J., Bradshaw, J.L., Iansek, R., Enticott, P.G., & McGinley, J. (2006c). Gait function in high-functioning autism and Asperger's disorder: Evidence for basal-ganglia and cerebellar involvement? *European Child and Adolescent Psychiatry*, *15*, 256–264.
- Schultz, R.T. (2005). Developmental deficits in social perception in autism: The role of the amygdala and fusiform face area. *International Journal of Developmental Neuroscience*, *23*, 125–141.
- Schultz, R.T., Grelotti, D.J., Klin, A., Kleinman, J., Van der Gaag, C., Marois, R., & Skudlarski, P. (2003). The role of the fusiform face area in social cognition: Implications for the pathobiology of autism. *Philosophical Transactions of the Royal Society B: Biological Sciences*, *358*, 415–427.
- Sears, L.L., Vest, C., Mohamed, S., Bailey, J., Ranson, B.J., & Piven, J. (1999). An MRI study of the basal ganglia in autism. *Progress in Neuropsychopharmacology and Biological Psychiatry*, *23*, 613–624.
- Szatmari, P., Archer, L., Fisman, S., Streiner, D.L., & Wilson, F. (1995). Asperger's syndrome and autism: Differences in behavior, cognition, and adaptive functioning. *Journal of the American Academy of Child and Adolescent Psychiatry*, *34*, 1662–1671.
- Tsatsanis, K.D., Rourke, B.P., Klin, A., Volkmar, F.R., Cicchetti, D., & Schultz, R.T. (2003). Reduced thalamic volume in high-functioning individuals with autism. *Biological Psychiatry*, *53*, 121–129.
- Volkmar, F.R., Klin, A., & Pauls, D. (1998). Nosological and genetic aspects of Asperger syndrome. *Journal of Autism and Developmental Disorders*, *28*, 457–463.
- Waiter, G.D., Williams, J.H., Murray, A.D., Gilchrist, A., Perrett, D.I., & Whiten, A. (2004). A voxel-based investigation of brain structure in male adolescents with autistic spectrum disorder. *Neuroimage*, *22*, 619–625.
- Ylisaukko-oja, T., Nieminen-von Wendt, T., Kempas, E., Sarenius, S., Varilo, T., von Wendt, L., Peltonen, L., & Jarvela, I. (2004). Genome-wide scan for loci of Asperger syndrome. *Molecular Psychiatry*, *9*, 161–168.
- Zilbovicius, M., Meresse, I., Chabane, N., Brunelle, F., Samson, Y., & Boddaert, N. (2006). Autism, the superior temporal sulcus and social perception. *Trends in Neurosciences*, *29*, 359–366.

Manuscript accepted 15 April 2008