

Amelioration of Photic Injury in Rat Retina by Ascorbic Acid: A Histopathologic Study

Zong-Yi Li,* Mark O. M. Tso,* Hih-min Wang,† and Daniel T. Organisciak†

It has been postulated that ascorbic acid may help to protect the retina from oxidative insult by light. To confirm this hypothesis, the authors compared light-damaged retinas of rats with or without ascorbate supplement by morphologic and morphometric studies at different time periods after light exposure. No dramatic morphologic differences were observed in the photoreceptor-retinal pigment epithelium complex between the two groups six hr after light exposure to 200 to 250-foot candles of visible light. Six to 13 days after 24 hr of exposure, the retina of rats that received ascorbate supplement showed significantly less severe damage than the retina of unsupplemented rats. The superior and temporal quadrants of the retina appeared to be most susceptible to the light damage when comparing rats with or without ascorbate supplement. These findings suggested that ascorbate ameliorates the photic injury in rat retina. Invest Ophthalmol Vis Sci 26:1589-1598, 1985

Although the mechanisms of photic injury to the retina have not been determined definitely, oxidative reaction is believed to play an important role.^{1,2} Light acts on some photo-excitabile components in the retina to produce superoxide radicals, which may induce plasma membrane injury. It is postulated that, as a natural antioxidant, ascorbic acid may neutralize these superoxide radicals and provide protection for the retina³⁻⁵ and other tissues such as lens and brain, which contain abundant ascorbic acid.^{6,7} In a previous report, we exposed guinea pig and baboon retinas to light and observed that the reduced ascorbate in the retina was decreased,^{3,4} suggesting that ascorbate may indeed be involved in retinal photic injury. Organisciak et al noted that after light injury, less rhodopsin remained in the retina of rats fed on a normal diet compared with rats that received vitamin C supplement. They suggested that supplemental ascorbic acid may ameliorate the light damage in the rat retina.⁵ To confirm

this hypothesis, we compared the light-induced pathologic changes of the retina of rats fed on a normal diet with rats that received vitamin C supplement. Results of morphologic and morphometric studies demonstrated ameliorative effects of ascorbic acid on light damage to the rat retina.

Materials and Methods

Sixteen 21-day-old albino rats were kept in a 12-hr cycle of 5-foot candle light and darkness and were fed a normal diet ad libitum for 30 days before the experiment. Before exposure to intense visible light, rats were dark adapted for 16 to 18 hr. Eight rats were injected intraperitoneally with a dose of 0.5 g/kg of ascorbic acid 24 hr before and just before intense light exposure. Six rats fed a normal diet and six rats that received ascorbic acid supplement were exposed to green-filtered fluorescent light (Plexiglas #2092 filter; Polycast Technology Corp.; Stamford, CT) of 200 to 250 foot candles for 24 hr. Normal rat were paired with ascorbate-treated rat during light exposure. Following light exposure, the animals were returned to a totally dark environment. Four rats, two fed a normal diet and two that received ascorbic acid supplement, were kept in a cyclic light environment as controls.

The rats were killed six hr, six days, and 13 days after light exposure. The right eyes were removed for rhodopsin measurement.⁸ The left eyes were placed into 4% paraformaldehyde and 1% glutaraldehyde in phosphate buffer fixative overnight and shipped by air express at 4°C from Ohio to Chicago. Immediately

From the Georgiana Theobald Ophthalmic Pathology Laboratory, Department of Ophthalmology, University of Illinois Eye and Ear Infirmary, Chicago,* and the Department of Biological Chemistry, Wright State University, Ohio.†

Presented at the Annual Spring Meeting of the Association for Research in Vision and Ophthalmology, Sarasota, Florida, April 30-May 4, 1984.

Supported in part by Public Health Service Grant EY-1903 and Core grant IP30 EY 01792 and EY-1959.

Submitted for publication: January 14, 1985.

Reprint requests: Mark O. M. Tso, MD, Department of Ophthalmology, University of Illinois Eye and Ear Infirmary, 1855 West Taylor Street, Chicago, IL 60612.

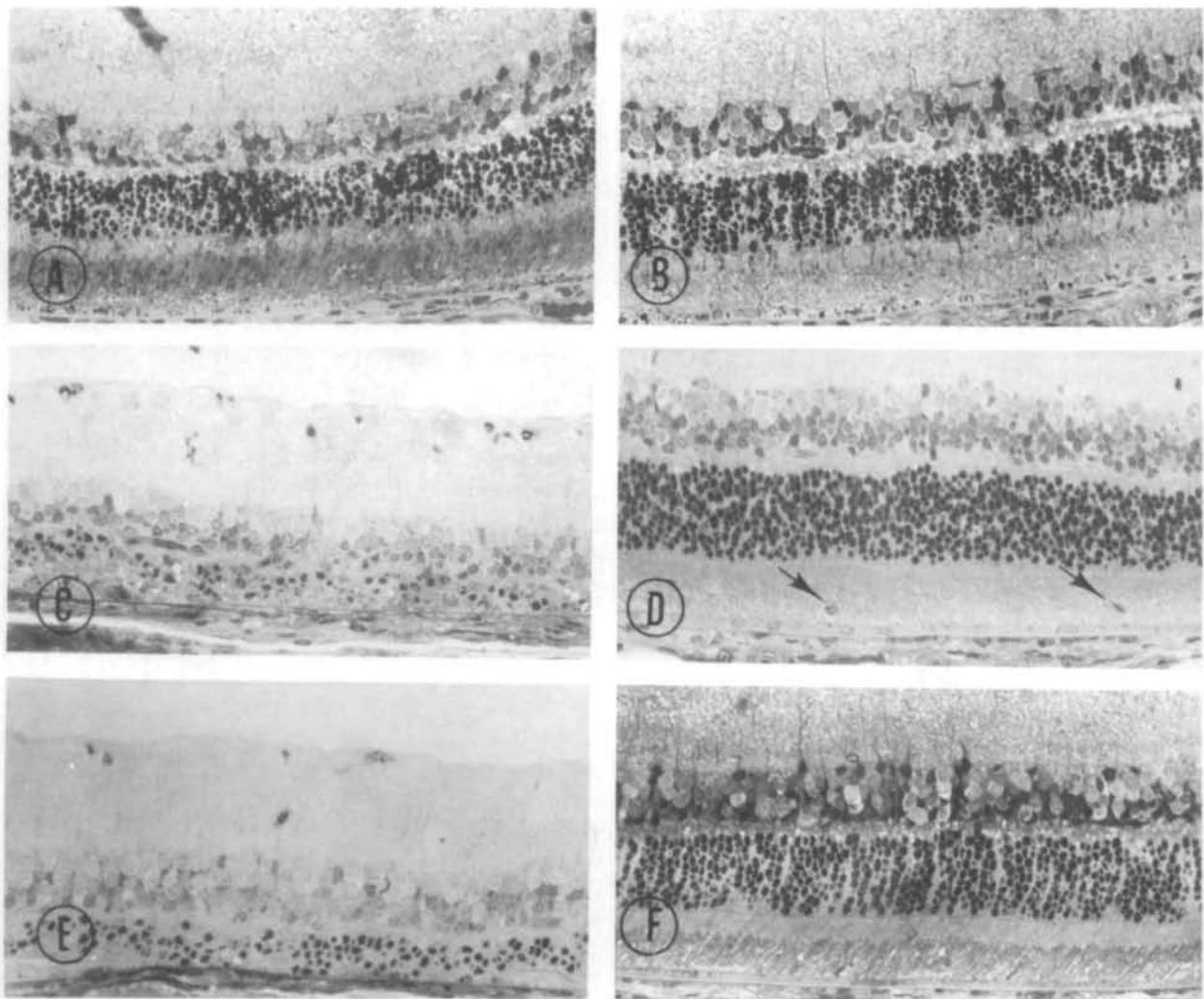


Fig. 1. Rat retina after light exposure. The photomicrographs were taken from most representative areas of each experimental group. Six hours after light exposure, the retina of a rat fed on a normal diet (A) shows scattered pyknotic nuclei with densified and granular inner and outer segments, and the retina of a rat treated with vitamin C supplement (B) exhibits mild disorganization of the photoreceptor elements. Six days after light exposure, the retina of a rat fed on a normal diet (C) shows moderate loss of photoreceptor nuclei with extensive loss of photoreceptor elements, and the retina of a rat that received vitamin C supplement (D) shows mild disorganization of inner and outer photoreceptor segments. Macrophages have migrated into the subretinal space (arrow). Thirteen days after light exposure, the retina of a rat fed on a normal diet (E) shows a few remaining pyknotic photoreceptor nuclei, and the retina of rat treated with vitamin C supplement (F) demonstrates the recovery of most photoreceptor cells. Irregular photoreceptor elements are present in some areas. ($\times 280$)

upon receipt, the anterior segments of the eyes were removed. The posterior segments were divided into a superior, inferior, nasal and temporal quadrants, osmicated and processed for light and electron microscopy. To assess loss of photoreceptor cells quantitatively, the number of photoreceptor nuclei per vertical column in the outer nuclear layer were counted at loci 0.178 mm apart at a magnification of 450 times with an eyepiece micrometer (American Optical Co.).⁹ The counts were collected from the four quadrants of the posterior segment of each eye, which included retina extending from the posterior pole to the ora serrata.

Two eyes were studied histopathologically and morphometrically per group. The regional differences in light damage by quadrants were examined in all experimental rats with or without vitamin C supplement. The counts of photoreceptor nuclei on a vertical column of each pair of rats were plotted on graphs for comparison.

Statistical significance was determined by two-way analysis of variance, using the fixed effects model.¹⁰ All procedures involving animals were performed according to policies set forth in the ARVO Resolution on the Use of Animals in Research.

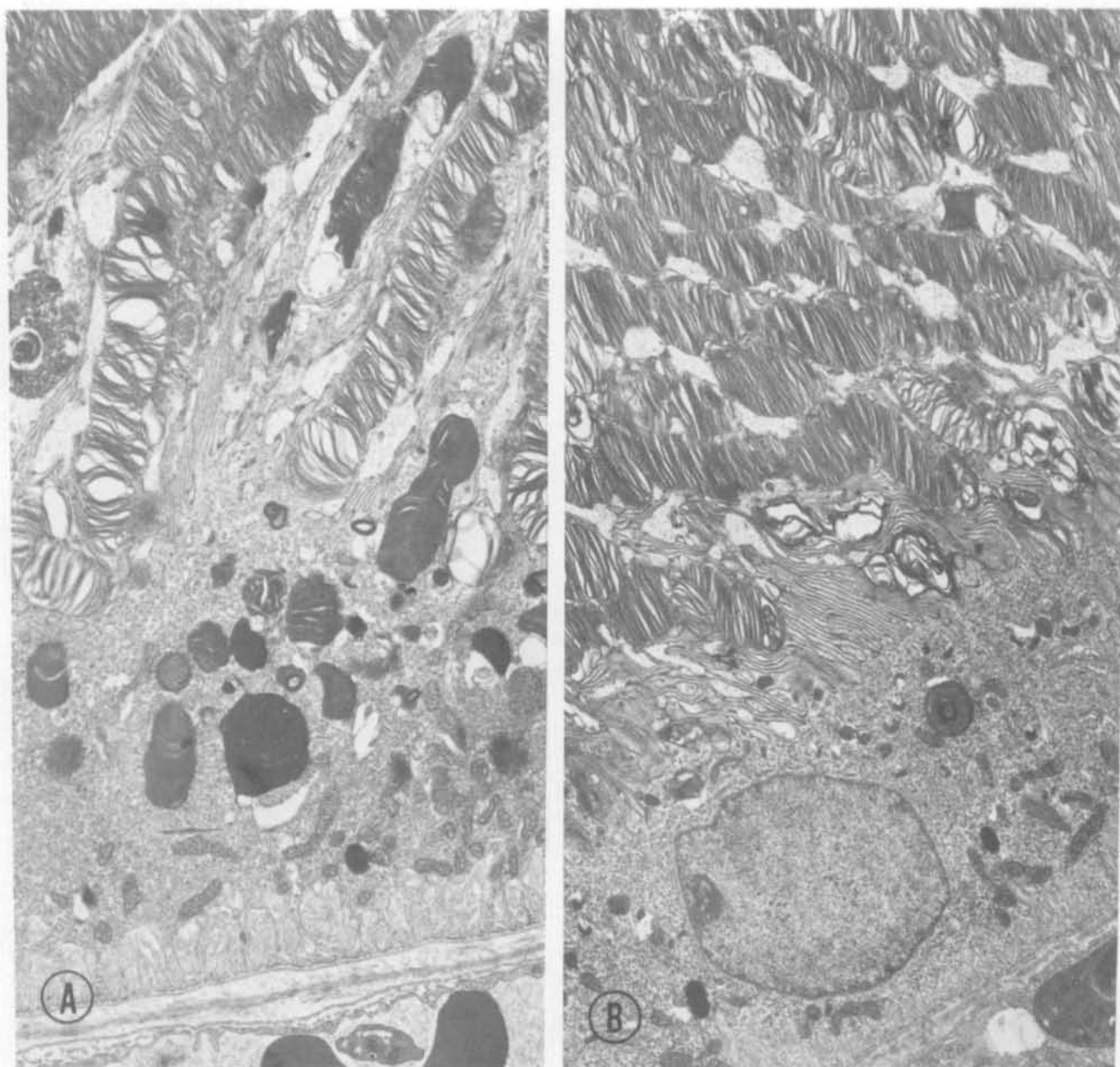


Fig. 2. (A) Six hours after light exposure, retinal pigment epithelium (RPE) and outer photoreceptor elements from rats fed on a normal diet showing moderate disorganization of the outer segments with abundant phagocytosis of outer segments by the RPE. (B) Six hours after light exposure, the retina of a rat that received vitamin C supplement exhibits mild derangement of the outer segments. The RPE appears unremarkable. ($\times 7500$)

Results

Light and electron microscopic studies six hr after light exposure showed the retinal pigment epithelium (RPE) of rats fed on a normal diet to have numerous phagosomes containing outer segment fragments (Fig. 1A and 2A). The lamellas of the outer segments of photoreceptor cells were mildly densified and disor-

ganized with densification of inner segments, and there were scattered, shrunken, pyknotic photoreceptor nuclei (Fig. 2A and 3). The rats that received vitamin C supplement showed only mild disorganization of the photoreceptor elements (Fig. 1B and 2B).

With increasing time after exposure to light, the alterations of the outer retinal layers became more severe in the rats fed on a normal diet. Six days after light

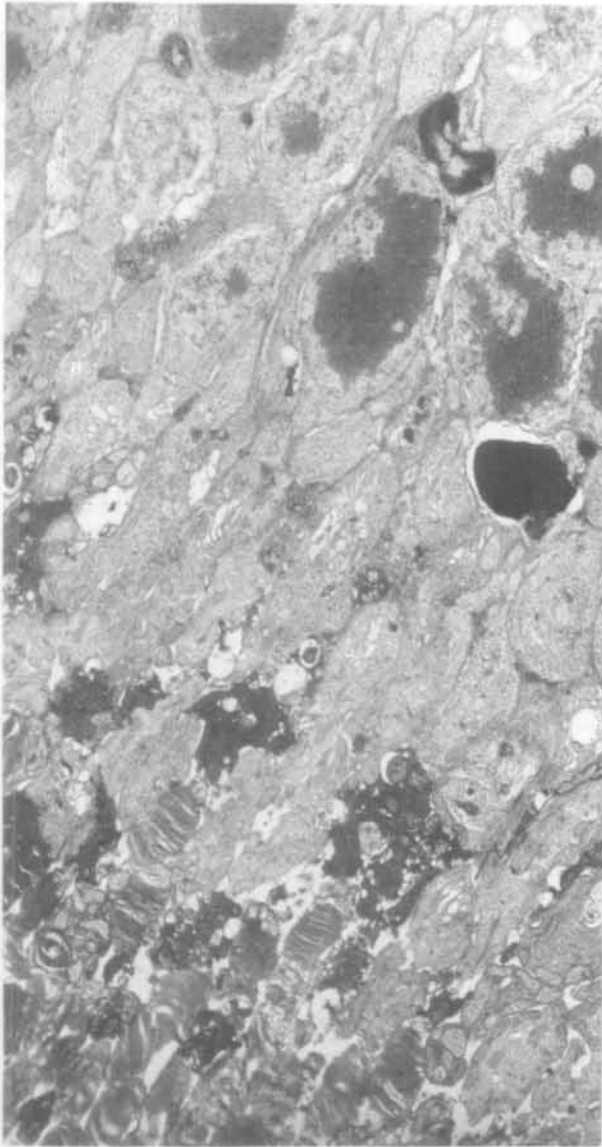


Fig. 3. Six hours after light exposure, the retina of a rat fed on normal diet exhibits disorganized outer segments of photoreceptor cells with densification of inner segments and a few pyknotic photoreceptor nuclei. ($\times 5500$)

exposure, photoreceptor nuclei were markedly decreased with extensive loss of photoreceptor elements (Fig. 1C). By electron microscopy, RPE showed moderate swelling with dilated smooth endoplasmic reticulum. The choroid and subretinal space demonstrated an infiltration of mononuclear cells (Figs. 4 and 5). In focal areas, the RPE was degenerated, and inner and outer segments of photoreceptor cells had disappeared. These alterations of the photoreceptor cells were comparatively mild in rats that received vitamin C supplement; however, occasional macrophages were noted in

the subretinal space (Fig. 1D), and the choroidal capillaries had produced multiple layers of basement membrane (Fig. 6).

Thirteen days after light exposure, the photoreceptor cells of rats fed on a normal diet showed severe damage (Fig. 1E). A few pyknotic photoreceptor nuclei remained. In focal area the RPE was necrotic, and remnant of inner segments of the photoreceptor cells lay close to Bruch's membrane. In the other area, fragments of outer segments persisted but were distorted (Fig. 7). The rats that received vitamin C supplement exhibited only moderate reactive proliferation of the RPE with edema (Fig. 8A). Most of the photoreceptors appeared intact (Fig. 8B), even though mild irregular photoreceptor elements were present focally (Fig. 1F).

The above morphologic observations depicted the representative retinal changes after photic injury, but the severity of damage varied in individual animals, as well as in different regions of the eye. To further delineate the retinal injury, we studied quantitatively the loss of photoreceptor nuclei.

The bar graph in Figure 9 shows the severity of loss of photoreceptor cells in different periods after light exposure. There is a greater reduction in the number of nuclei in the outer nuclear layer in the rats fed on a normal diet than in those that received vitamin C supplement after light exposure.

The mean number of photoreceptor nuclei per column in the outer nuclear layer was 9.03 in normal rats fed on a normal diet and 9.43 in rats that received vitamin C supplement. Six hr after light exposure, the mean number of photoreceptor nuclei was 7.85 in rats fed on a normal diet and 8.55 in rats that received vitamin C supplement. No statistical difference between these two groups was noted. Six days after light exposure, the mean number of photoreceptor nuclei in rats fed on a normal diet decreased to 4.27. However, the rats that received vitamin C supplement had 7.35 nuclei per column. Thirteen days after light exposure, the mean number of photoreceptor nuclei was 5.19 in rats fed on a normal diet and 7.14 in rats that received vitamin C supplement. These results correlate with rhodopsin measurements in a separate communication.⁸ Two-way analysis of variance shows that the average loss of photoreceptor cells was significantly related to treatment with vitamin C ($P = 0.00095$).

The regional differences in light damage were examined by comparing pairs of rats with or without vitamin C supplement. No regional differences were noted in rats killed six hr after light exposure. Significant differences were noted in rats killed 6 days and 13 days after light exposure. A pair of rats with or without vitamin C supplement killed 13 days after light

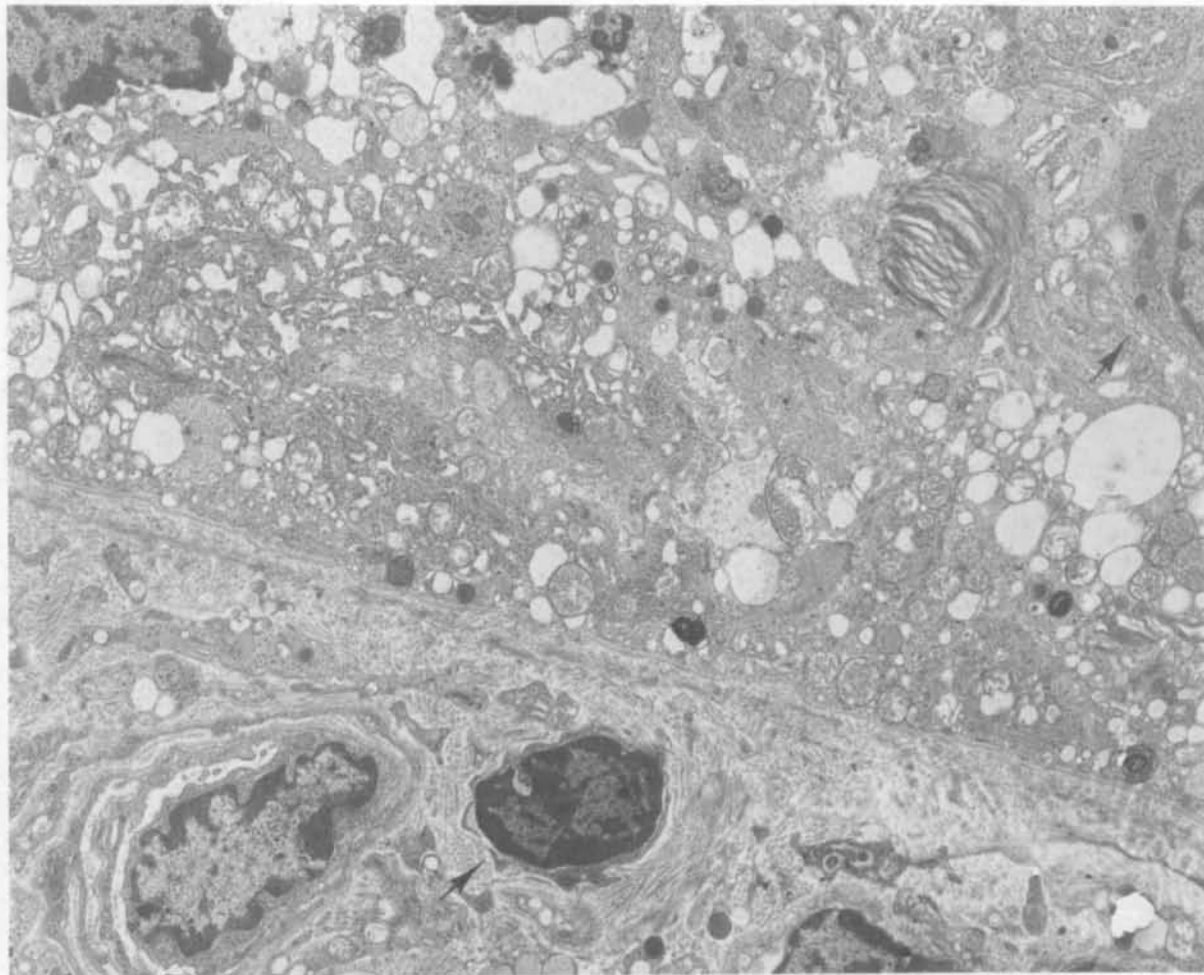


Fig. 4. Six days after light exposure, the retinal pigment epithelium from a rat fed on normal diet shows dilated smooth endoplasmic reticulum and loss of basal infolding. There are mononuclear cells in the choroid and in the subretinal space (*arrow*). ($\times 7600$)

exposure is shown in Figure 10. Susceptibility of photoreceptor cells varied with region; the most severe damage was in the superior and temporal quadrants. The difference of reduction in the number of photoreceptor nuclei in the retinas of rats with or without vitamin C supplement was also most pronounced in the superior and temporal quadrants of the retina. The rats killed 6 days and 13 days showed comparable differences.

Discussion

Noell postulated that the pathologic process of photic injury may involve lipid peroxidation.¹ Ascorbate, which is present in high concentrations in the retina¹¹⁻¹³ may act as a natural antioxidant to neutralize superoxide radicals generated during photic insult of the ret-

ina. Woodford, Tso, and Lam noted that reduced ascorbate in the normal retina decreased and dehydroascorbic acid increased after mild photic exposure in guinea pigs and baboons.^{3,4} Organisciak, Wang, and Kou showed that reduced retinal ascorbate decreased after 24 hr of light exposure in 50- to 60-day-old rats.⁵ Thus, the possible role of ascorbate as an antioxidant must be seriously considered. In our study, scattered pyknotic photoreceptor nuclei and RPE phagocytosis of degenerated outer segments were noted in rats with ascorbate supplement and suggested that ascorbate could not provide total protection to mild retinal photic injury.

Six to 13 days after light exposure, the damage became very severe in rats fed with a normal diet; there was extensive loss of photoreceptor nuclei and inner and outer segments and necrosis of the RPE. Rats sup-

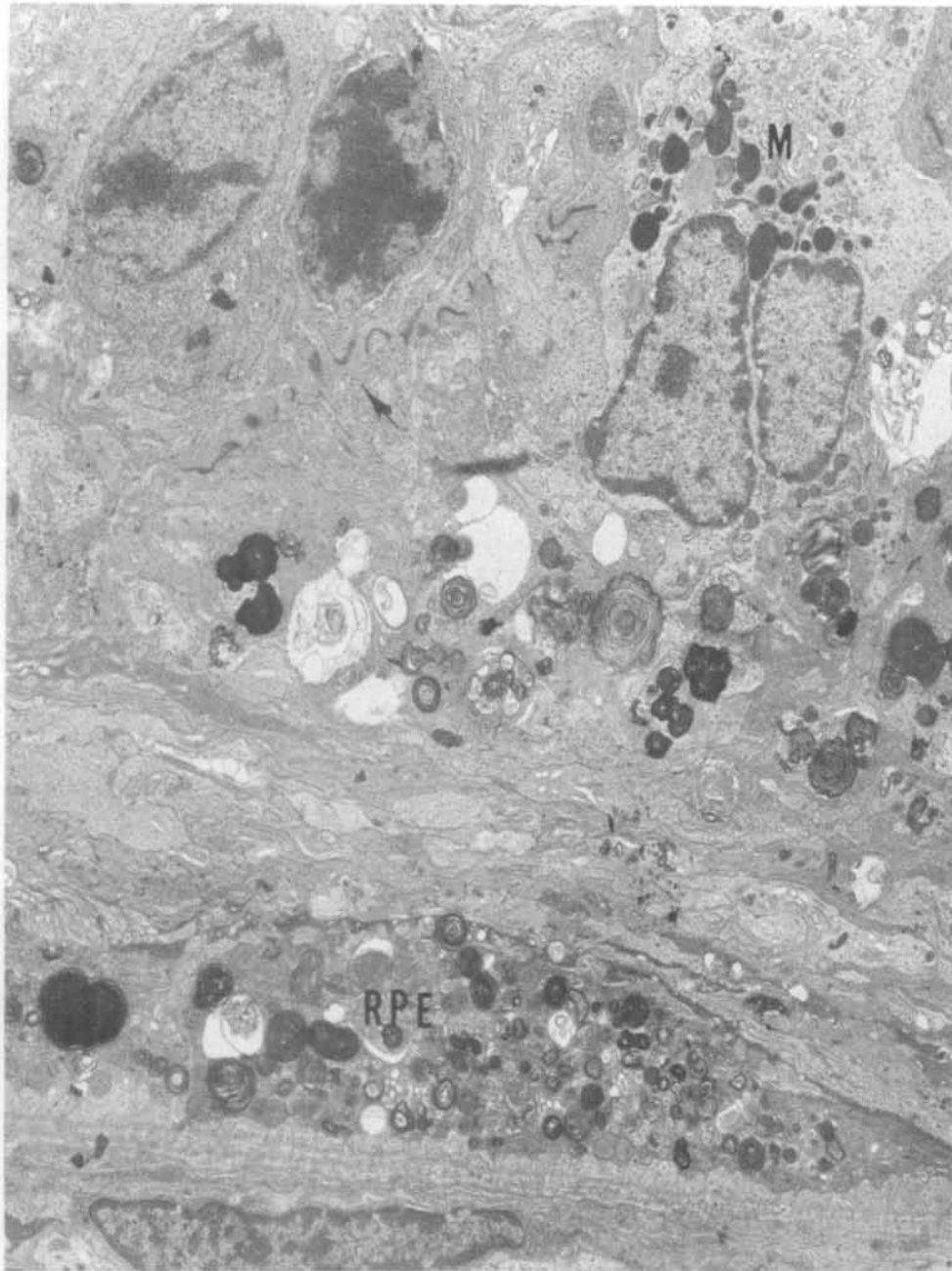


Fig. 5. Six days after light exposure, the retina of a rat fed on normal diet demonstrates more severe injury than shown in Fig. 4, evidenced by focal area degeneration of the retinal pigment epithelium (RPE) and disappearance of inner and outer segments of photoreceptor cells. Macrophages (M) have migrated into the subretinal space. The outer limiting membrane (*arrow*) is disrupted. ($\times 6700$)

plemented with ascorbate, however, showed only mild loss of photoreceptor cells, subtle disorganization of photoreceptor cell outer segments, and infiltration of occasional subretinal macrophages. The morphologic and morphometric studies in this report suggested that the damage of photoreceptor cells could be ameliorated by ascorbic acid supplement. These findings corresponded well with those of Organisciak et al that more rhodopsin remained in the retina of rats that received

ascorbate supplement than in the retina of unsupplemented rats.^{5,8}

However, mild morphologic differences were observed in the photoreceptor-RPE complex in rats with or without ascorbate supplement six hr after light exposure. In rats without ascorbate supplement, light damage in the retina worsened in the dark phase after exposure. The protective function of ascorbate may be present at the cellular level during light exposure, but

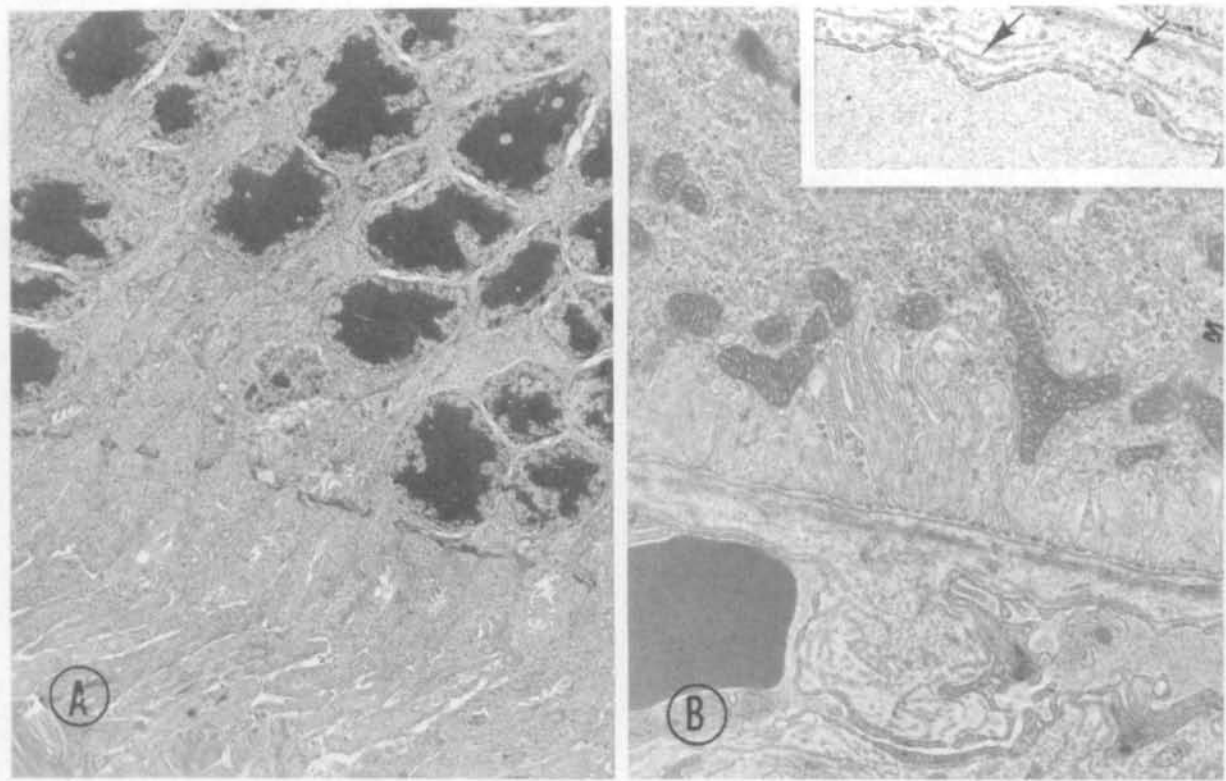


Fig. 6. Six days after light exposure, the retina from a rat with vitamin C supplement has relatively intact photoreceptor cells (*A* $\times 4700$) and retinal pigment epithelium (*B* $\times 11,000$). Occasionally the endothelial cells of the choriocapillaris show an increased laying down of basement membrane-like materials (*arrow*). (*insert* $\times 14,000$)

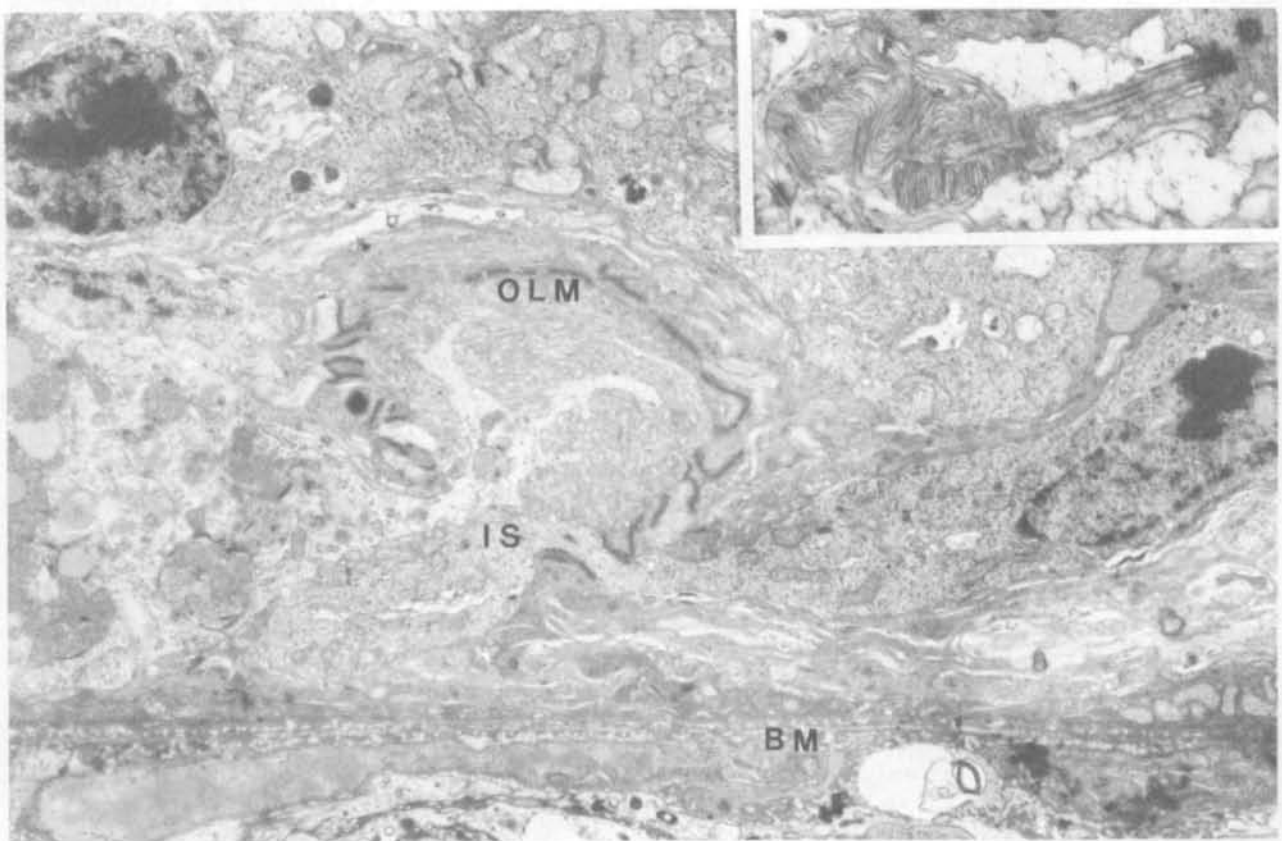


Fig. 7. Thirteen days after light exposure, the retina from a rat fed on normal diet has a necrotic retinal pigment epithelium. There is a loss of outer segments. Remnants of a photoreceptor cell, possibly a cone cell, and its inner segment (IS) lie close to Bruch's membrane (BM). Outer limiting membrane (OLM) is distorted ($\times 8500$). *Inset:* In focal areas of the retina, fragments of distorted outer segments of photoreceptor cells persist. ($\times 12,500$)

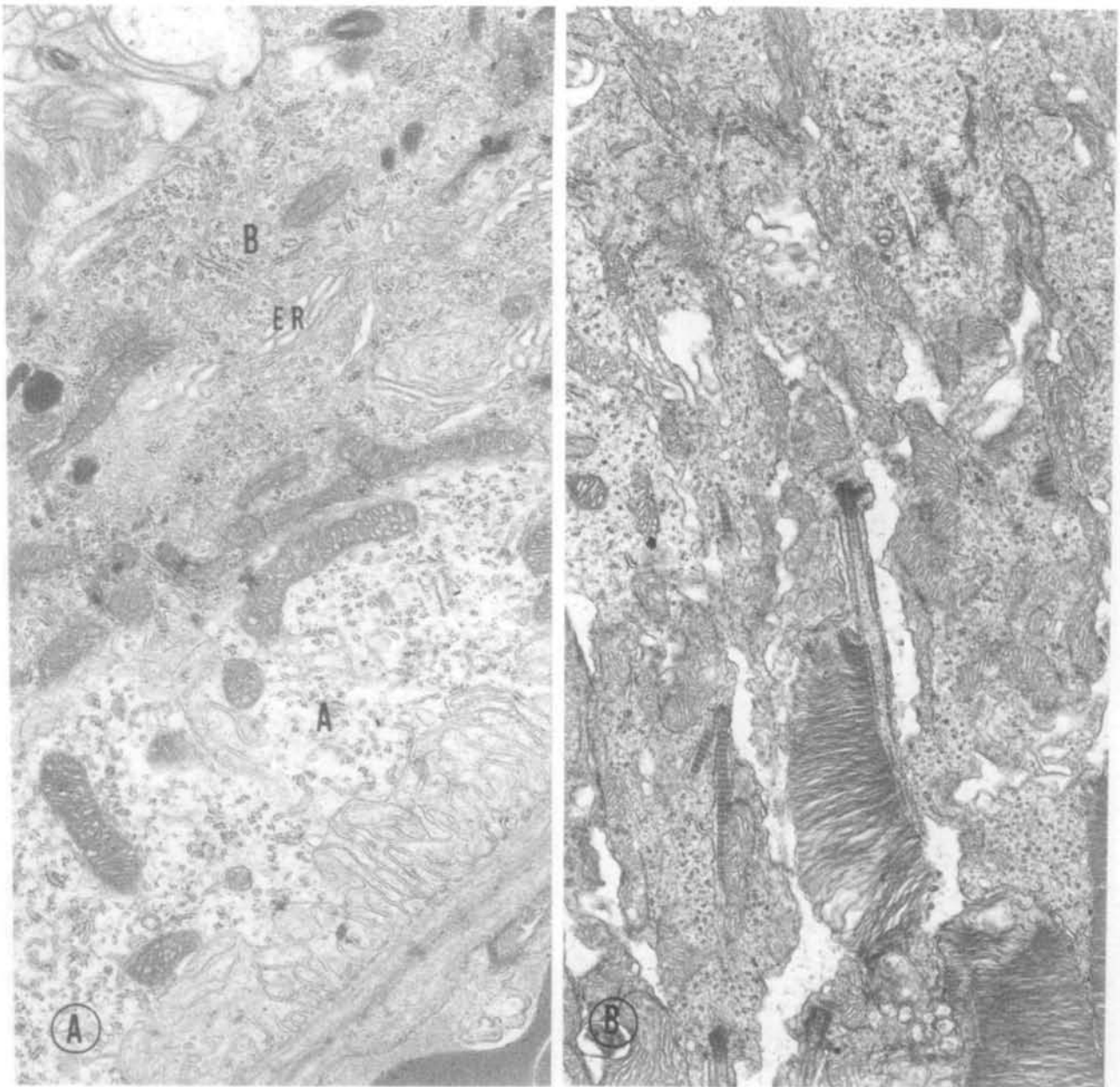


Fig. 8. Thirteen days after light exposure, (A) the retinal pigment epithelium from a rat treated with vitamin C supplement has proliferated into two layers. The RPE cell A sitting on Bruch's membrane has watery cytoplasm, while the proliferated RPE cell B has dense cytoplasm and abundant smooth surface endoplasmic reticulum (ER). ($\times 17,000$); (B) the photoreceptor elements are largely intact. ($\times 18,000$)

without showing morphologic manifestations in the early stage of photic injury. The functions of ascorbate in the reparative process of the photoreceptor cells and RPE are currently being investigated in our laboratories.

Noteworthy was the observation that the light-damaged areas in the retina changed abruptly into normal areas. In these normal areas, intact RPE and photo-

receptors were seen; in the damaged areas, the RPE was flattened, atrophic, or extensively degenerated. In his study of photic injury to rat retina, Kuwabara¹⁴ postulated that the survival of the photoreceptor cells depended on the preservation of the RPE. The role of the RPE in light damage in the rat needs further study.

In our regional study (Fig. 10), we noted the most severe damage to be in the superior and temporal

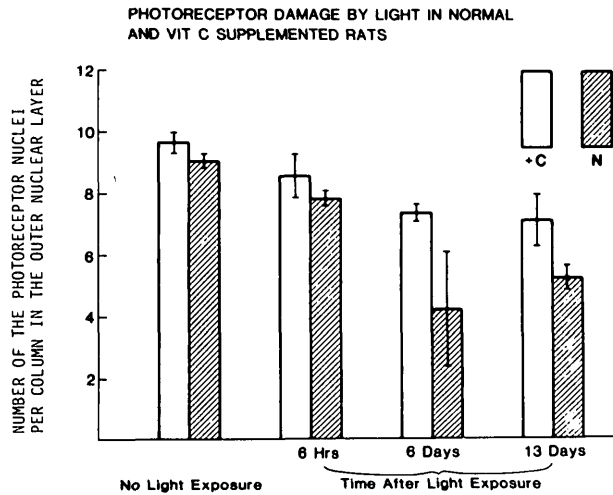


Fig. 9. Loss of photoreceptor cells in different periods after light exposure. There is a greater reduction in the number of nuclei in the outer nuclear layer in rats fed on a normal diet than in the rats treated with vitamin C supplement. The most severe loss of photoreceptor nuclei occurred in 6 to 13 days. The measurements were average of four quadrants of two retinas. The variability is indicated by standard deviation. N = rats fed on normal diet; +C = rats treated with vitamin C supplement.

quadrants of the retina in rats fed on a normal diet, findings which are comparable with the reports of Noell,¹⁵ Williams,¹⁶ and Rapp.⁹

In contrast to humans, who require exogenous vitamin C, rats produce endogenous vitamin C. However, the rat retina has been documented in the literature to show marked susceptibility to photic injury and, as such, may still provide a reasonable model for the study of photic injury and ascorbate supplement.

Key words: ascorbate, rat retina, retinal pigment epithelium, photic injury, lipid peroxidation

Acknowledgments

The authors are indebted to Irena Suvaizdis and Robert Kucera for their technical assistance and to Shirlee Kadlec for typing this manuscript.

References

1. Noell WK: Possible mechanisms of photoreceptor damage by light in mammalian eyes. *Vision Res* 20:1163, 1980.
2. Armstrong D, Hiramitsu T, Gutteridge J, and Nilsson SE: Studies on experimentally induced retina degeneration. I. Effect of lipid

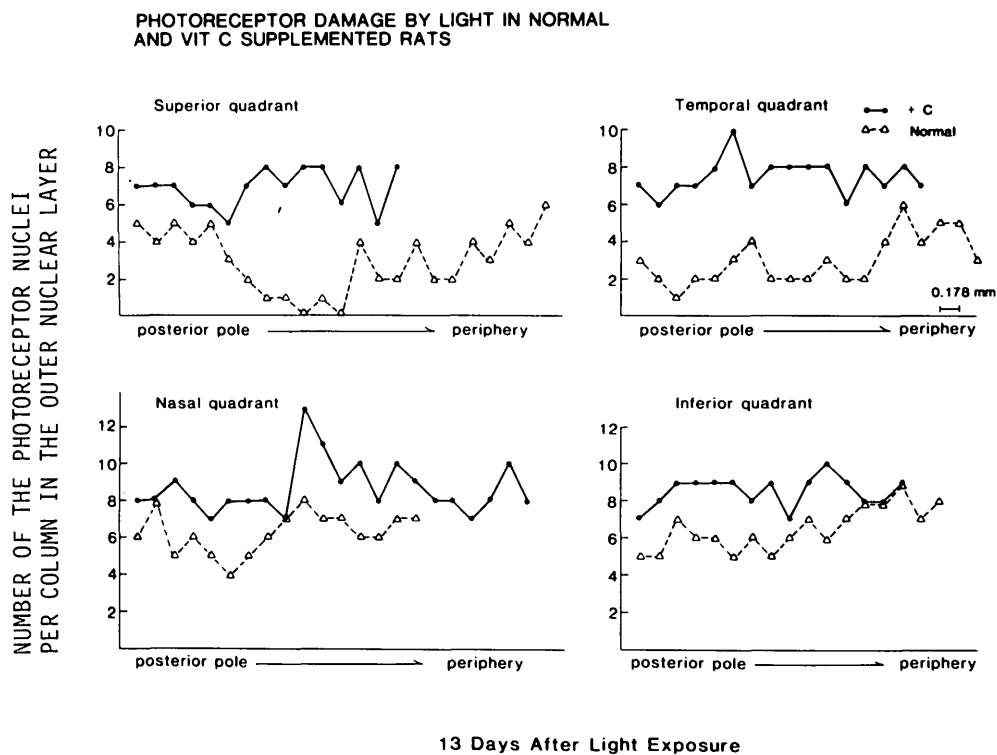


Fig. 10. Susceptibility of photoreceptor cells to photic damage varies among four regions of the retina. The most severe damage is in the superior and temporal quadrants. A rat on a normal diet was compared with another rat that received vitamin C supplement. Normal = rats fed on normal diet; +C = rats treated with vitamin C supplement.

- peroxides on electroretinographic activity in the albino rabbit. *Exp Eye Res* 35:157, 1982.
3. Woodford BJ, Tso MOM, and Lam KW: Reduced and oxidized ascorbates in guinea pig retina under normal and light-exposed conditions. *Invest Ophthalmol Vis Sci* 24:862, 1983.
 4. Tso MOM, Woodford BJ, and Lam KW: Distribution of ascorbate in normal primate retina and after photic injury: a biochemical, morphological correlated study. *Curr Eye Res* 3:181, 1984.
 5. Organisciak DT, Wang HM, and Kou AL: Ascorbate and glutathione levels in the developing normal and dystrophic rat retina: effect of intense light exposure. *Curr Eye Res* 3:257, 1984.
 6. Seregi A, Schaefer A, and Komlos M: Protective role of brain ascorbic acid content against lipid peroxidation. *Experientia* 34:1056, 1978.
 7. Varma SD, Kumar S, and Richards RD: Light-induced damage to ocular lens cation pump: prevention by Vit. C. *Proc Natl Acad Sci USA* 76:3504, 1979.
 8. Organisciak DT, Wang HM, Li ZY, and Tso MOM: The protective effect of ascorbate in retinal light damage of rats. *Invest Ophthalmol Vis Sci* 26:1580, 1985.
 9. Rapp LM and Williams TP: A parametric study of light damage in albino and pigmented rats. *In Effects of Constant Light on Visual Processes*. Williams TP and Baker BN, editors. New York, Plenum Press, 1980, pp. 135-59.
 10. Kleinbaum DG and Kupper LL: Fixed effects: ANOVA model for a randomized blocks experiment. *In Applied Regression Analysis and Other Multivariable Methods*. Kleinbaum DG and Kupper LL, editors. Boston, MA, Duxbury Press, 1984, pp. 308-14.
 11. Heath H, Beck TC, and Rutter AC: Biochemical changes in aphakia. *Vision Res* 1:274, 1961.
 12. Fox RR, Lam KW, Lowen R, and Lee PF: Ascorbate concentration in tissues from normal and buphthalmic rabbits. *J Hered* 73:109, 1982.
 13. Heath H, Rutter AC, and Beck TC: Changes in the ascorbic acid and glutathione content of the retinae and adrenals from alloxan-diabetic rats. *Vision Res* 2:431, 1962.
 14. Kuwabara T: Retinal recovery from exposure to light. *Am J Ophthalmol* 70:187, 1970.
 15. Noell WK: There are different kinds of retinal light damage in the rat. *In Effects of Constant Light on Visual Processes*, Williams TP and Baker BN, editors. New York, Plenum Press, 1980, pp. 3-28.
 16. Williams TP and Howell WL: Action spectrum of retinal light damage in albino rats. *Invest Ophthalmol Vis Sci* 24:285, 1983.