

# Regional Differences in the Subacute Response of Rabbit Orbicularis Oculi to Bupivacaine-Induced Myotoxicity as Quantified With a Neural Cell Adhesion Molecule Immunohistochemical Marker

Linda Kirschen McLoon and Jonathan Wirtschafter

**Purpose.** This study examined the subacute myotoxic effects of injection of the local anesthetic bupivacaine on the orbicularis oculi muscle in the rabbit eyelid. In contrast to other muscles, the orbicularis oculi was resistant to injury by the usual anesthetic doses of bupivacaine when local infiltration is used. An attempt was made to assess the sensitivity of orbicularis oculi muscle to bupivacaine using a variety of increased bupivacaine concentrations and in combination with hyaluronidase.

**Methods.** Bupivacaine was injected into rabbit lower eyelids at a variety of doses with and without the injection of hyaluronidase before bupivacaine treatment. Muscle injury was assessed immunohistochemically using an antibody to an isoform of neural cell adhesion molecule, anti-leu-19, a molecule shown to localize on the surface of regenerating muscle fibers. The number of neural cell adhesion molecule-positive muscle fibers was assessed 4 and 7 days after bupivacaine injection to determine the number of fibers that were injured.

**Results.** When bupivacaine was injected into the lower eyelid at a dose of 1.5 mg, only 10% of the orbicularis oculi muscle was injured. The most effective injury involved either multiple injections of 3 mg bupivacaine or of hyaluronidase 20 minutes before the injection of 3 mg bupivacaine, resulting in injury of up to 58% of the muscle fibers. In all cases, the preseptal region of the orbicularis oculi showed a greater percentage of injury than the pretarsal portions of the muscle.

**Conclusions.** Although multiple injections of bupivacaine and bupivacaine combined with hyaluronidase significantly increased the percentage of muscle cells injured, total destruction of the orbicularis oculi muscle was never seen. Neural cell adhesion molecule was a good marker for the quantification of the regenerating muscle fibers. It is proposed that the tight fasciculation of the orbicularis oculi muscle may play a role in preventing access of the local anesthetic to the individual muscle fibers. This demonstrates the relative clinical safety of local anesthetic injection into the eyelid. *Invest Ophthalmol Vis Sci.* 1993;34:3450–3458.

Skeletal muscle is susceptible to injury by a number of agents and methods that result in rapid degeneration of the muscle fibers. Some muscle toxic agents cause permanent muscle loss. These include x-ray irradiation<sup>1</sup> and doxorubicin.<sup>2–4</sup> Other agents cause muscle injury followed by regeneration. These include physi-

cal injuries, such as crush injury,<sup>5</sup> ischemic injuries, such as those resulting from autotransplantation,<sup>6</sup> and chemical-induced injuries, such as after the injection of local anesthetics.<sup>7</sup> A variety of local anesthetics have been shown to induce muscle degeneration and subsequent regeneration. These include lidocaine,<sup>8–10</sup> mepivacaine,<sup>11,12</sup> and bupivacaine.<sup>7,13</sup> Injection of these agents typically causes rapid loss of the muscle fibers, with the earliest effects of the injected drugs seen as soon as 15 minutes after application.<sup>7</sup>

Injection of bupivacaine into skeletal muscle can result in the almost total destruction of a given muscle,<sup>14–17</sup> followed by complete regeneration within 1 month. We investigated the effects of injection of bupivacaine into the lower eyelids of rabbits to assess the

From the Department of Ophthalmology, University of Minnesota, Minneapolis, Minnesota.

Supported by NEI grant EY07935, Minnesota Lions and Lionesses, Minnesota Medical Foundation, the Frank E. Burch Chair in Neuro-ophthalmology (JDW) and an unrestricted grant to the Department of Ophthalmology from Research to Prevent Blindness, Inc.

Submitted for publication January 22, 1993; accepted May 7, 1993.

Proprietary interest category: N.

Reprint requests: Linda Kirschen McLoon, Department of Ophthalmology, University of Minnesota, Box 493 UMHC, Minneapolis, Minnesota 55455.

susceptibility of the orbicularis oculi muscle to bupivacaine myotoxicity.

Neural cell adhesion molecule (N-CAM), is known to be expressed on developing muscle cells,<sup>18</sup> recently denervated muscle cells,<sup>19</sup> and regenerating muscle cells, including satellite cells, myoblasts, and myotubes.<sup>20,21</sup> N-CAM is not expressed on degenerating or necrotic skeletal muscle fibers,<sup>22</sup> or on normal, adult skeletal muscle except at neuromuscular junctions and on satellite cells. The presence of N-CAM was used as a quantitative marker for the reaction of orbicularis oculi muscle to bupivacaine induced injury. N-CAM was localized immunohistochemically on the bupivacaine-treated muscles in the rabbit eyelid, and the number of N-CAM-positive cells was determined. This number was compared to the total number of orbicularis oculi muscle fibers in the normal rabbit eyelid.<sup>23</sup>

## MATERIAL AND METHODS

Thirty New Zealand white rabbits were obtained from Birchwood Valley Farm (Red Wing, MN). All research conformed to the guidelines of the ARVO Resolution on the Use of Animals in Research.

Before injecting anesthetic solution into their eyelids, the rabbits were anesthetized with an intramuscular injection of a 1:1 mixture of ketamine HCl (Ketalar HCl, Parke Davis, Morris Plains, NJ) at a dose of 10 mg/kg and xylazine (Tranquid, St. Joseph, MN) at a dose of 2 mg/kg. Each treated eyelid received the local anesthetic injections in two elongated and separate boluses at two injection sites to include exposure of the entire mediolateral extent of the lower eyelid to the injected bupivacaine. Rabbits received injections of varying combinations of bupivacaine HCl alone (Sensorcaine, 0.75% solution in isotonic saline containing epinephrine 1:200,000; Astra Pharmaceutical Products, Inc., Westborough, MA) or bupivacaine and hyaluronidase (Wydase, 150 units/ml, in sterile isotonic saline; Wyeth, Philadelphia, PA) into each lower eyelid. If given, hyaluronidase was always administered as a separate injection 20 minutes before bupivacaine. The dosage and injection parameters for bupivacaine treatment of the eyelids are listed in Table 1. An additional five eyelids were injected with the dose determined to injure the maximal number of muscle fibers, two injections of hyaluronidase and 1.5 or 3 mg bupivacaine were given 18 hours apart, and the rabbits were killed after 7 days. Common dosages of bupivacaine in humans vary according to the area being anesthetized, and the amount and duration of anesthesia required. However, common doses for local infiltration anesthesia are between 0.75 and 3 mg. The recommended dosages for retrobulbar injections, conversely, range between 15 and 30 mg. Another four

TABLE 1. Number of Rabbit Eyelids Injected at Each Dose of Bupivacaine

	One Injection	Series of 2 Injections, 18 hr Apart
Saline	2§	—
15 units hyaluronidase*	2	—
1.5 mg bp†	5	5
3 mg bp	5	5
hyal/1.5 mg bp‡	6	5
hyal/3 mg bp‡	8	5

All animals were killed 4 days after the initial injections.

\* 150 units hyaluronidase (hyal) reconstituted in 1 ml isotonic saline.

† 0.75% bupivacaine (bp) HCl in saline with 1:200,000 epinephrine.

‡ Hyaluronidase injected 20 minutes prior to injection of bupivacaine.

§ Values are number of eyelids at each parameter.

eyelids were injected 18 hours apart with two sets of injections of hyaluronidase and 3 mg bupivacaine but without epinephrine, and the rabbits were killed 4 days later.

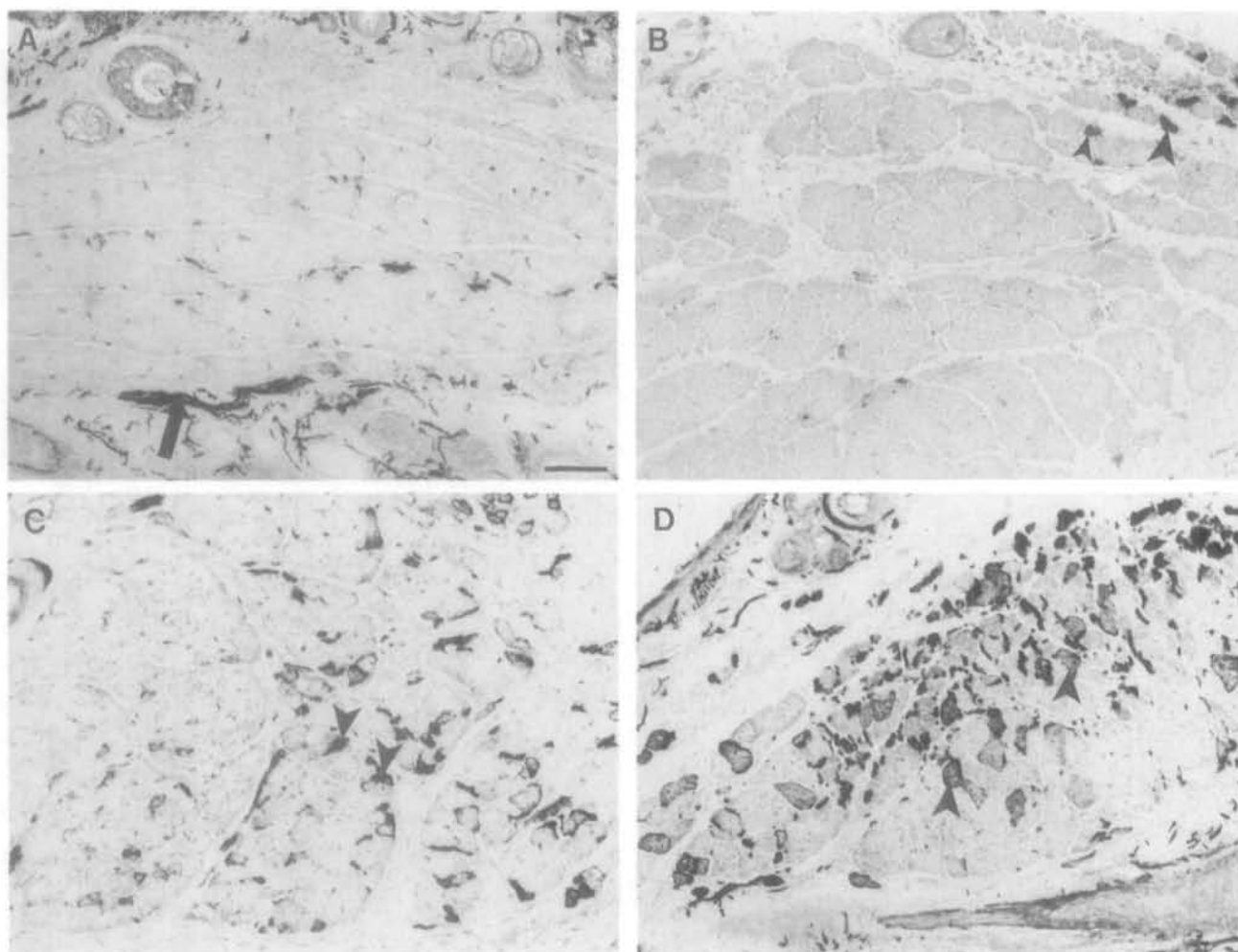
At the time of death the rabbits were deeply anesthetized as described earlier. Proparacaine HCl drops were applied to the conjunctival cul-de-sac. Samples of the medial, central, and lateral portions of the lower eyelids were removed and immediately frozen by immersion in 2-methylbutane that had been chilled on liquid nitrogen. The tissue was immediately sectioned at 12  $\mu$ m in a cryostat and processed for alkaline adenosine triphosphatase histochemistry at pH 10.5, which allows for the differentiation of types 1 and 2 muscle fiber.<sup>24</sup> Serial sections were processed with standard hematoxylin/eosin and Gomori trichrome stains. A third section in serial order was stained immunohistochemically with anti-leu-19, which binds to an isoform of N-CAM and allows for the visualization of regenerating or newly denervated muscle fibers.<sup>21</sup> Frozen sections were fixed in 95% ethanol, rinsed in phosphate-buffered saline (pH 7.4) and quenched for endogenous peroxidase by incubation in 0.3% H<sub>2</sub>O<sub>2</sub> in methanol. After incubation in blocking serum, the sections were incubated with the primary mouse monoclonal antibody anti-leu-19 (Becton Dickinson, Mountain View, CA) in a 1:80 dilution. After a rinse in phosphate-buffered saline, the sections were incubated with biotinylated horse anti-mouse IgG, followed by incubation with the Vectastain Elite ABC reagent containing the avidin-biotin-peroxidase complex (Vector Laboratories, Burlingame, CA). The reacted tissue sections were incubated using the intensified diaminobenzidine procedure.<sup>25</sup>

The eyelid sections were examined using light microscopy. The sections were analyzed to determine the extent of muscle injury as a result of the various injec-

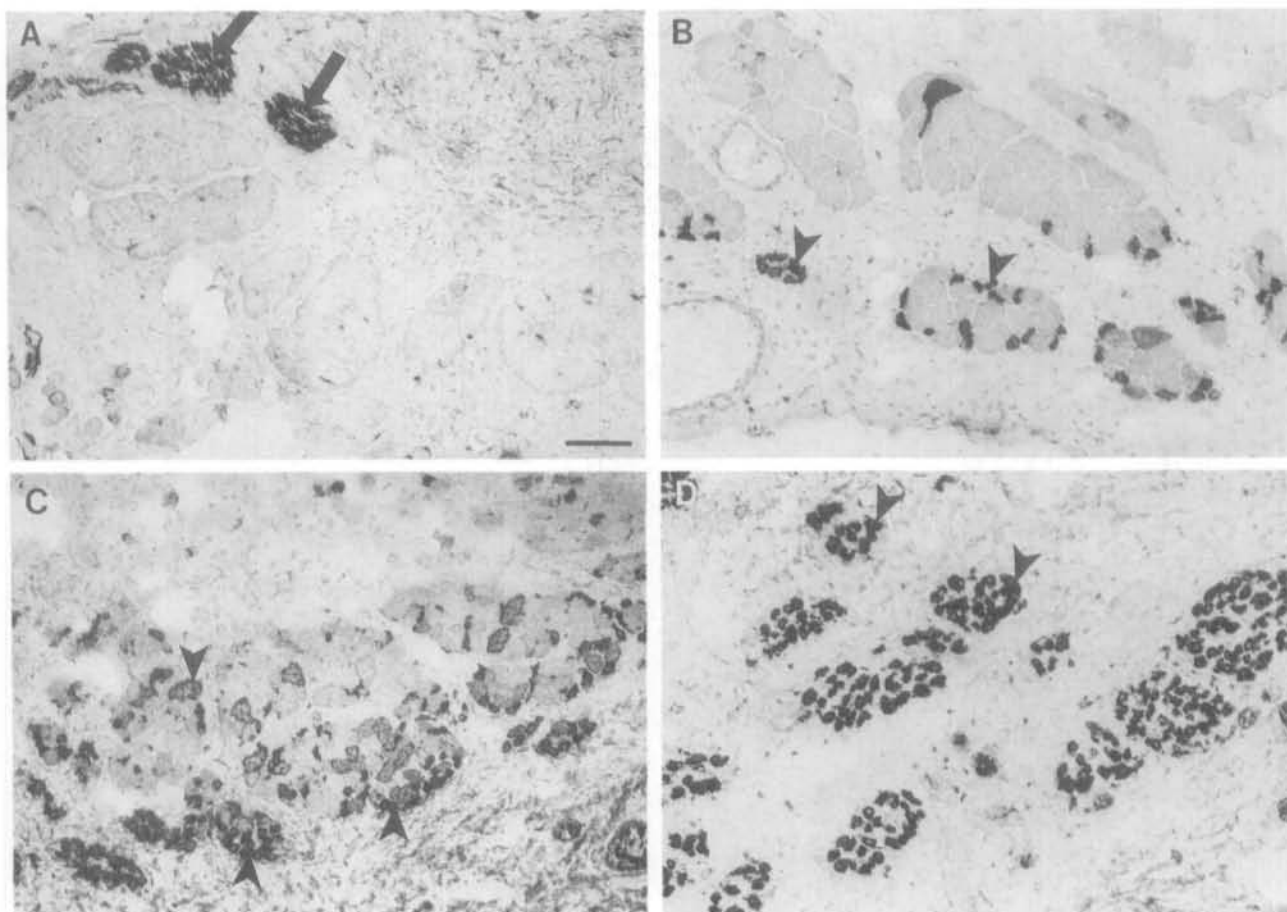
tion protocols, particularly with regard to the inclusion of both pretarsal and preseptal portions of the orbicularis oculi muscle.<sup>23</sup> These divisions are found in both upper and lower eyelids.<sup>23</sup> The pretarsal region of the orbicularis oculi is defined as the region from the eyelid margin to the end of the tarsal glands. The preseptal region of the orbicularis oculi is defined as the region from the end of the tarsal glands to the end of the conjunctival surface. Counts of muscle fibers positive for anti-leu-19 after each of the various injection protocols were made using the Bioquant Image Analysis system (R and M Biometrics, Nashville, TN). The total number of orbicularis oculi muscle fibers per eyelid cross section was also determined. Results were compared statistically using the Mann-Whitney test and a two-tailed *P* value. Results were considered significantly different at *P* < 0.001. All statistics were performed using the Instat biostatistics software (Graphpad, San Diego, CA).

## RESULTS

In the normal control orbicularis oculi muscle some N-CAM-positive staining could be seen, but only at what is either satellite cells or neuromuscular junctions as reported in the literature (Figs. 1A, 2A). A single injection of 1.5 mg bupivacaine containing epinephrine was not sufficient to significantly injure the orbicularis oculi in either the pretarsal (Fig. 1B) or preseptal (Fig. 2B) areas of the muscle. A single injection of 3 mg bupivacaine and two injections of 1.5 mg bupivacaine resulted in slightly greater numbers of injured fibers in both the pretarsal (Fig. 1C) and preseptal (Fig. 2C) portions of the muscle. The nerves in these sections retained a normal histologic appearance. When hyaluronidase was injected 20 minutes before injection of either 1.5 mg or 3 mg bupivacaine or when 3 mg bupivacaine was injected twice within 18 hours, there was a significant increase in the number



**FIGURE 1.** Photomicrographs of the pretarsal portion of the orbicularis oculi muscle from rabbit eyelids stained with a monoclonal antibody to leu-19, an isoform of N-CAM. (A) Uninjected control muscle. Four days after an injection of (B) 1.5 mg bupivacaine, (C) 3 mg bupivacaine, and (D) hyaluronidase followed 20 minutes later with 3 mg bupivacaine. Arrowheads indicate N-CAM-positive muscle fibers. Arrows indicate nerve. Note that normal peripheral nerve is positive for N-CAM staining. Bar is 100  $\mu$ m.



**FIGURE 2.** Photomicrographs of the preseptal portion of the orbicularis oculi muscle from rabbit eyelids stained with a monoclonal antibody to leu-19, an isoform of N-CAM. (A) Uninjected control muscle. Four days after the injection of (B) 1.5 mg bupivacaine, (C) 3 mg bupivacaine and (D) two injections of 3 mg bupivacaine within 18 hours. Arrowheads indicate N-CAM-positive muscle fibers. Arrows indicate normal nerve in cross-section. Bar is 100  $\mu$ m.

of muscle fibers injured compared with single injections of bupivacaine alone in both the pretarsal (Fig. 1D) and preseptal (Fig. 2D) regions of the orbicularis oculi muscle. Two injection series of hyaluronidase and either 1.5 or 3 mg bupivacaine, 18 hours apart, also resulted in a large number of injured muscle fibers (Fig. 1D).

The number of N-CAM-positive muscle cells 4 days after the various types of bupivacaine treatment was determined (Figs. 3, 4). Bupivacaine alone resulted in few labeled muscle fibers in either the pretarsal or preseptal region of the muscle. Increasing doses and number of treatments with bupivacaine, even without the addition of hyaluronidase, resulted in increased numbers of N-CAM-positive muscle fibers in both the pretarsal and preseptal regions of the muscle (Figs. 3, 4). In the pretarsal portion of the muscle, all of the injection protocols that included hyaluronidase injections before bupivacaine injection resulted in a significantly increased number of N-CAM-positive fibers over single injections of bupivacaine alone (Fig.

3). The maximal injury in the pretarsal muscle was seen after two injections of 3 mg bupivacaine, 18 hours apart, when 26% of the fibers were injured. In the preseptal region, there was a steady increase in the number of N-CAM-positive muscle fibers with increasing dosages of bupivacaine, and an even further increase when hyaluronidase was injected before bupivacaine treatment (Fig. 4). There was no significant difference between the numbers of muscle fibers injured after any treatment that included hyaluronidase, but these were all significantly elevated over bupivacaine alone.

When the number of N-CAM-positive muscle fibers is examined as a percentage of the total number of muscle fibers in either the pretarsal or preseptal regions of the muscle, there was never injury to all of the orbicularis oculi muscle fibers. After a single 1.5 mg bupivacaine injection, only 3% of the muscle fibers were injured in the pretarsal regions as a result of injection of this local anesthetic, and only 13% were injured in the preseptal regions (Fig. 5). The injured

### Anti-leu-19 Positive Pretarsal Muscle Fibers

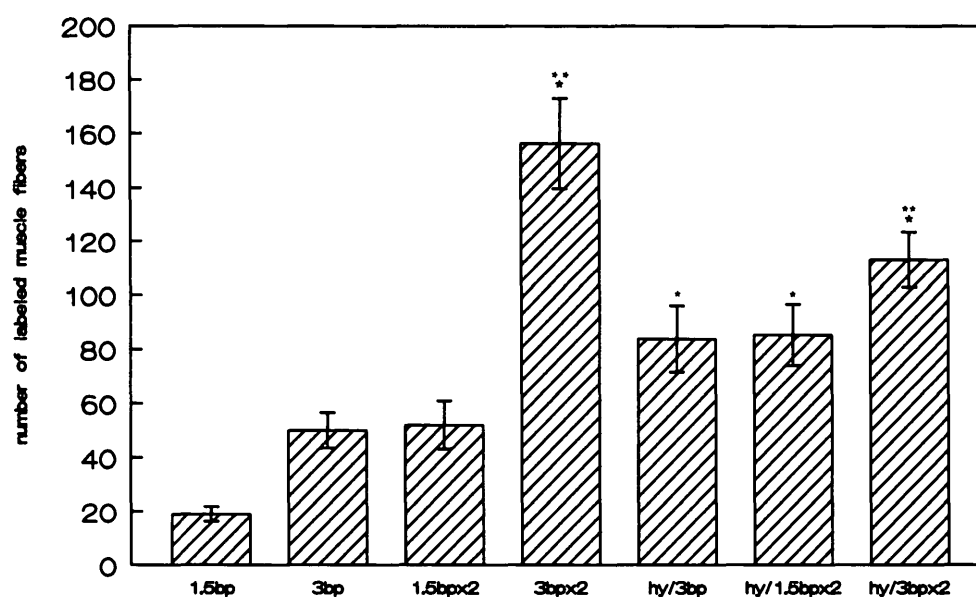


FIGURE 3. Bar graph depicting the number of anti-leu-19 positive muscle fibers in the pretarsal portion of the orbicularis oculi muscle after injection with different doses of bupivacaine (bp) or bupivacaine and hyaluronidase (hy). \*Indicates that the data are significantly different from the number of fibers labeled after a single injection of 1.5 mg bupivacaine. \*\*Indicates that the data are significantly different from the number of fibers labeled after either a single injection of 3 mg bupivacaine or after two injections of 1.5 mg bupivacaine.  $P < 0.0001$ .

### Anti-leu-19 Positive Preseptal Muscle Fibers

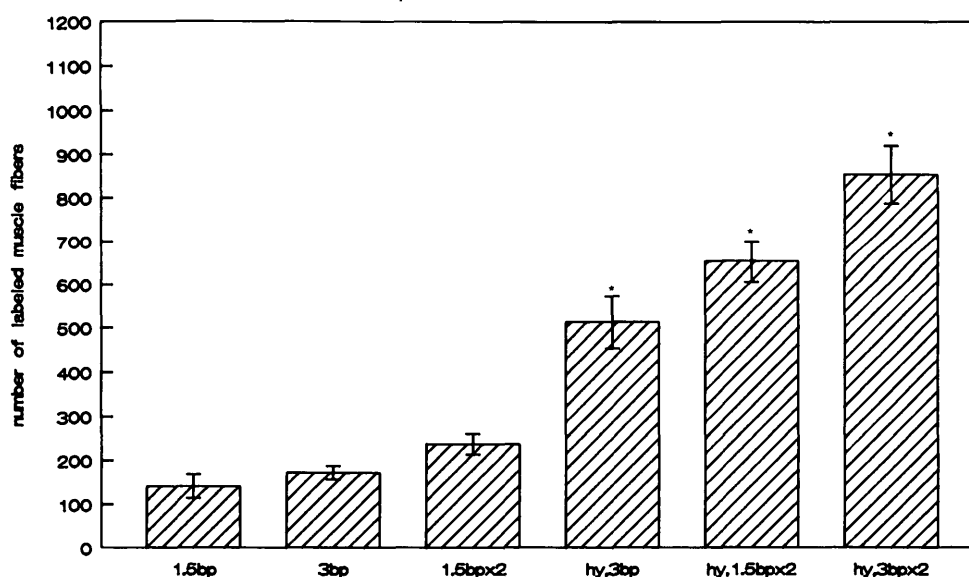
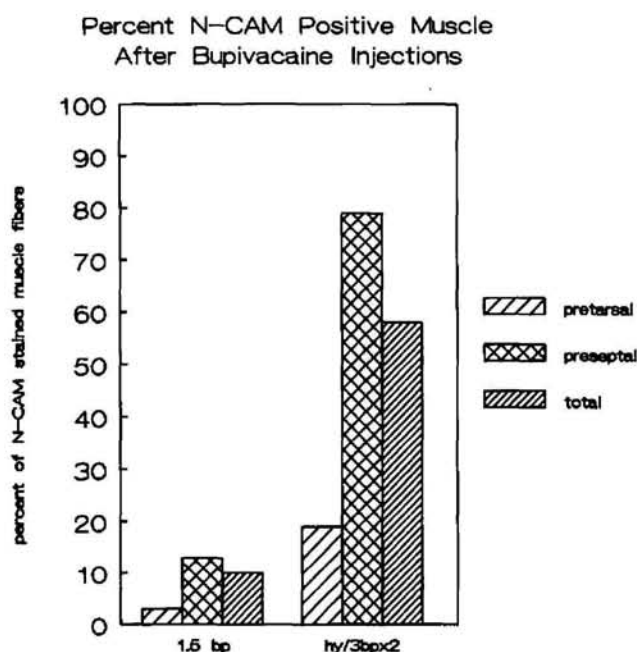


FIGURE 4. Bar graph depicting the number of anti-leu-19 positive muscle fibers in the preseptal portion of the orbicularis oculi muscle after injection with different doses of bupivacaine (bp) or bupivacaine and hyaluronidase (hy). \*Indicates data are significantly different from the number of fibers labeled after a single injection of either 1.5 or 3 mg bupivacaine or two injections of 1.5 mg bupivacaine.  $P < 0.0001$ .





**FIGURE 5.** Bar graph depicting the percentage of pretarsal, preseptal, and the total number of muscle fibers stained with anti-leu-19 as a marker of injury after injection of either 1.5 mg bupivacaine (bp) or two sets of injections of hyaluronidase followed by injection of 3 mg bupivacaine administered 18 hours apart compared with the number of muscle fibers in these regions in uninjured control eyelids.

muscle fibers were diffusely located throughout the muscle cross-section. This represents an injury to only 10% of the total number of palpebral orbicularis oculi fibers. After 2 injections, 18 hours apart, of hyaluronidase, followed by 3 mg bupivacaine each, only 19% of

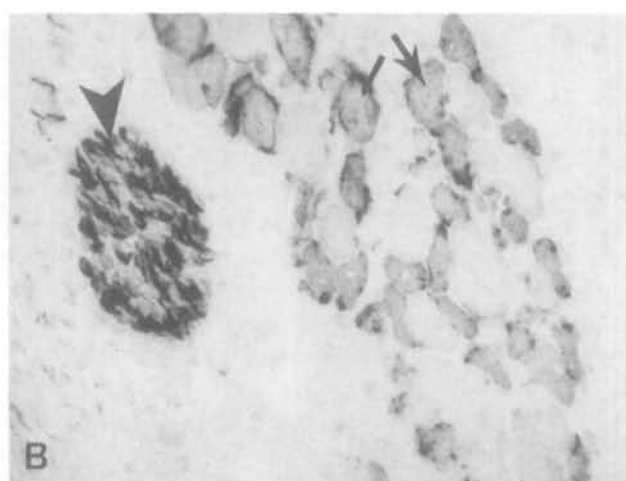
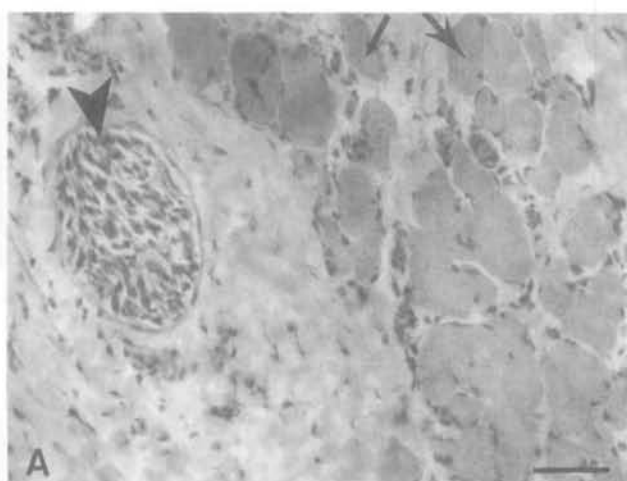
the muscle fibers were injured in the pretarsal region of the muscle, while 79% were injured in the preseptal region. This represents an injury to only 58% of the total number of fibers in the palpebral orbicularis oculi muscle (Fig. 5).

N-CAM appears to be a good marker for denervated or regenerating muscle fibers and a measure of the reaction to injury. When serial sections were prepared using standard hematoxylin/eosin histologic methods and compared with sections stained for N-CAM expression, there was a good correlation between the histologic appearance of regenerating fibers and N-CAM expression (Fig. 6). However, there were always fibers with a normal histologic appearance in the hematoxylin/eosin stain that expressed N-CAM circumferentially on their sarcolemmal surfaces. Thus, N-CAM expression is an excellent marker for the quantitative analysis of muscle fiber injury and regeneration after myotoxin treatment. The injured fibers are more readily identified with N-CAM staining than they are by using hematoxylin/eosin or trichrome methods.

Injection of bupivacaine without epinephrine always resulted in fewer muscle fibers injured than the same dose of bupivacaine that contained epinephrine (data not shown). Injections of either hyaluronidase alone or saline into the eyelid did not result in detectable muscle injury.

## DISCUSSION

When compared with other skeletal muscles treated with similar doses of bupivacaine as described in the



**FIGURE 6.** Photomicrographs of serial sections through the preseptal portion of the orbicularis oculi muscle 7 days after the injection, 18 hours apart, of hyaluronidase followed by 3 mg bupivacaine. (A) Muscle stained with hematoxylin/eosin. (B) Muscle stained with the monoclonal antibody to leu-19, an isoform of N-CAM. Arrowheads indicate a labeled nerve bundle. Arrows indicate fibers that appeared normal in the hematoxylin/eosin stain, but are positive for N-CAM expression. Bar is 50  $\mu$ m.

literature, the orbicularis oculi muscle was resistant to bupivacaine-induced myotoxicity. Injury to the orbicularis oculi muscle fibers could be increased when the dose of bupivacaine was increased or after pretreatment of the eyelid with hyaluronidase before injection with bupivacaine to a maximal injury of 58% of the muscle fibers. However, none of the injection protocols examined in this study resulted in total injury to the muscle fibers in the orbicularis oculi.

The small amount of injury of the orbicularis oculi muscle after an injection of either 1.5 mg or 3 mg bupivacaine, from 10 to 13%, is in contrast to the rather extensive injury that has been described after bupivacaine injection at the same dose in a number of other skeletal muscles. Comparable doses have been injected into or in the connective tissue around rat sternocleidomastoid muscles,<sup>26</sup> rat tibialis anterior,<sup>16</sup> mouse extensor digitorum longus,<sup>17</sup> and monkey extraocular muscles.<sup>14</sup> In all of these cases, more than 90% of the treated muscle was injured. However, the mode of administration and species treated seem to play a role in the amount of muscle damaged as a result of bupivacaine treatment. Retrobulbar injections of a number of local anesthetics in the rat resulted in extensive injury to the extraocular muscles, as did direct injection into primate extraocular muscles.<sup>14</sup> In contrast, injections of between 7.5 and 15 mg bupivacaine into the retrobulbar tissues but not directly into the muscles in the primate orbit have been shown to result in very mild muscle injury<sup>27</sup> with myopathic changes in only a single muscle fiber type in the extraocular muscles. Direct injection of local anesthetic into a muscle fascicle is the most effective method to induce muscle injury. The current study of rabbit orbicularis oculi muscle and that of Porter<sup>27</sup> examining monkey extraocular muscles both demonstrate the resistance of these particular muscles to local anesthetic treatment.

The reduced myotoxicity of bupivacaine compared to bupivacaine containing epinephrine has been described previously for a number of other local anesthetics.<sup>8,16</sup> This is most likely because of two factors. First, epinephrine has been shown to be slightly myotoxic when it is injected directly into muscle.<sup>8</sup> Second, epinephrine is a known vasoconstrictor, so the net result of its presence at the time of injection would be to cause the local anesthetic to remain at the site of injection for a longer time.

The orbicularis oculi muscle is very tightly fasciculated, with little connective tissue between the muscle fibers in any given fascicle. It may be that part of the reason for the limited myotoxicity of bupivacaine in the orbicularis oculi muscle is due to limited access of the drug to the individual muscle fibers. Hyaluronidase is an enzyme that breaks down hyaluronic acid in connective tissue. It is often used as an agent to in-

crease the spread of a drug at its injection site. It has been used previously in tandem with local anesthetic application with the same result shown in the current study, increasing the amount of muscle injury to rat tibialis anterior muscle compared with that seen after injection of bupivacaine alone.<sup>13</sup> We have demonstrated that hyaluronidase is effective in increasing the myotoxicity of doxorubicin when both drugs are injected into the eyelids of rabbits.<sup>3,28</sup> This is substantiated in part by the gradient of muscle injury in the eyelid that results from the injections of hyaluronidase with these myotoxic drugs (Fig. 1). Other agents known to increase the spread of drugs at their injection site, like dimethyl sulfoxide and collagenase, have been effective in increasing the myotoxic effects of doxorubicin, presumably by the same mechanism.<sup>3,28</sup> It may be that these would be more effective than hyaluronidase in producing bupivacaine-induced muscle injury.

The immunohistochemical localization of N-CAM on regenerating muscle cells allowed the quantification of the amount of muscle injury after bupivacaine injections in a more objective manner than has been possible with traditional histologic stains. N-CAM has been shown to be present only on satellite cells and neuromuscular junctions in adult skeletal muscle,<sup>20</sup> and on both denervated muscle cells<sup>19</sup> and regenerating myoblasts and myotubes.<sup>20-22</sup> It is not present on normal adult skeletal muscle sarcolemma or on degenerating or necrotic fibers.<sup>22</sup> In various myopathic diseases a good correlation has been shown between the histologic appearance of denervated fibers or regenerating fibers and the expression of N-CAM on the surfaces of those fibers.<sup>20,21,29</sup>

The N-CAM-positive muscle cells seen in this study are most likely regenerating fibers. Based on the timetable of injury seen after injection of other local anesthetics,<sup>7,11-14</sup> fatally injured muscle would have already become necrotic and degenerated 4 days after bupivacaine injection. Both in our histologic examination and in the work of others, the nerves appeared to be intact and undamaged as a result of bupivacaine injections (Figs. 2, 6).<sup>11,26,27</sup> The N-CAM-positive muscle fibers did not resemble the atrophic type fibers seen in denervated muscle, which are small and angulated in appearance.<sup>20,21</sup> Rather, in hematoxylin and eosin stained sections, they had the appearance of myoblasts and myotubes, with small cross-sectional areas, slightly basophilic cytoplasm and enlarged, centrally placed nuclei.<sup>30</sup> Recently, Figarella-Branger et al<sup>29</sup> have shown that satellite cells and denervated muscles express the nonsialylated form of N-CAM, whereas the regenerative fibers express the sialylated isoforms similar to those seen on skeletal muscles cells in developing embryos. In future studies, by using anti-

bodies to these various isoforms of N-CAM, we may be able to identify more definitively that the N-CAM-labeled fibers are regenerating after bupivacaine-induced muscle injury.

The orbicularis oculi appears to be somewhat resistant to injury by local bupivacaine injection. Despite multiple injections of bupivacaine, the maximal number of fibers injured was only 58%. This contrasts to that seen in other skeletal muscles at similar dosages of bupivacaine,<sup>13,14,26</sup> where 100% of the muscle was injured after a single injection of bupivacaine. Injection of hyaluronidase before injection of bupivacaine significantly increased the number of muscle fibers injured in the orbicularis oculi muscle, but again complete destruction of the muscle was never seen. The tight fasciculation of the muscle fibers in the eyelid would seem to protect the orbicularis oculi muscle from injury after injection of bupivacaine. Many ophthalmologic procedures require the injection of local anesthetic into the eyelid. These results indicate that the orbicularis oculi muscle is relatively safe from local anesthetic toxicity in its clinical use.

### Key Words

myotoxin, facial muscles, local anesthetics, skeletal muscle, muscle regeneration, N-CAM

### Acknowledgments

The authors thank Terry Doerr for her expert technical assistance.

### References

1. Alameddine HS, Dehaupas M, Fardeau M. Regeneration of skeletal muscle fibers from autologous satellite cells multiplied in vitro. An experimental model for testing cultured cell myogenicity. *Muscle Nerve*. 1989;12:544–555.
2. McLoon LK, Bauer G, Wirtschafter J. Quantification of muscle loss in the doxorubicin treated orbicularis oculi muscle of the monkey. *Invest Ophthalmol Vis Sci*. 1991;32:1667–1673.
3. McLoon LK, Ekern M, Wirtschafter J. Verapamil substantially increases the chemomyectomy effect of doxorubicin injected into rabbit or monkey eyelid. *Invest Ophthalmol Vis Sci*. 1992;33:3228–3234.
4. McLoon LK, Wirtschafter J. Doxorubicin chemomyectomy: injection of monkey orbicularis oculi results in selective muscle loss. *Invest Ophthalmol Vis Sci*. 1988;29:1854–1859.
5. McGeachie JK, Grounds MD. Initiation and duration of muscle precursor replication after mild and severe injury to skeletal muscle. *Cell Tissue Res*. 1987;248:125–130.
6. Morlet K, Grounds MD, McGeachie JK. Muscle precursor replication after repeated regeneration of skeletal muscle in mice. *Anat Embryol*. 1989;180:471–478.
7. Benoit PW, Belt WD. Destruction and regeneration of skeletal muscle after treatment with a local anesthetic, bupivacaine. *J Anat*. 1970;107:547–556.
8. Benoit PW. Reversible skeletal muscle damage after administration of local anesthetics with and without epinephrine. *J Oral Surg*. 1978;36:198–201.
9. Dolwick MF, Bush FM, Saibel HR, Burke GW. Degenerative changes in masseter muscle following injection of lidocaine: a histochemical study. *J Dent Res*. 1977;56:1395–1402.
10. Yagiela JA, Benoit PW, Buoncristiani RD, Peters MP, Fort NF. Comparison of myotoxic effects of lidocaine with epinephrine in rats and humans. *Anesth Analg*. 1981;60:471–480.
11. Basson MD, Carlson BM. Myotoxicity of single and repeated injections of mepivacaine (carbocaine) in the rat. *Anesth Analg*. 1980;59:275–282.
12. Oklund S, Komorowski TE, Carlson BM. Ultrastructure of Mepivacaine-induced damage and regeneration in rat extraocular muscle. *Invest Ophthalmol Vis Sci*. 1989;30:1643–1651.
13. Hall-Craggs ECB. Rapid degeneration and regeneration of a whole skeletal muscle following treatment with bupivacaine (Marcain). *Exp Neurol*. 1975;43:349–358.
14. Carlson BM, Emerick S, Komorowski TE, Rainin EA, Shepard BM. Extraocular muscle regeneration in primates. Local anesthetic-induced lesions. *Ophthalmol*. 1992;99:582–589.
15. Carlson BM, Rainin EA. Rat extraocular muscle regeneration. Repair of local anesthetic-induced damage. *Arch Ophthalmol*. 1985;103:1373–1377.
16. Foster AH, Carlson BM. Myotoxicity of local anesthetics and regeneration of the damaged muscle fibers. *Anesth Analg*. 1980;59:727–736.
17. Martin H, Ontell M. Regeneration of dystrophic muscle following multiple injections of bupivacaine. *Muscle Nerve*. 1988;11:588–596.
18. Grumet M, Rutishauser U, Edelman GM. Neural cell adhesion molecule is on embryonic muscle cells and mediates adhesion to nerve cells in vitro. *Nature*. 1982;295:693–695.
19. Covault J, Sanes JR. Neural cell adhesion molecule (N-CAM) accumulates in denervated and paralyzed skeletal muscles. *Proc Nat Acad Sci U S A*. 1985;82:4544–4548.
20. Cashman NR, Covault J, Wollman RL, Sanes JR. Neural cell adhesion molecule in normal, denervated and myopathic human muscle. *Ann Neurol*. 1987;21:481–489.
21. Illa I, Leon-Monzon M, Dalakas MC. Regenerating and denervated human muscle fibers and satellite cells express neural cell adhesion molecule recognized by monoclonal antibodies to natural killer cells. *Ann Neurol*. 1992;31:46–52.
22. Walsh FS, Moore SE. Expression of cell adhesion mol-



- ecule, N-CAM, in diseases of adult human skeletal muscle. *Neurosci Lett*. 1985;59:73–78.
23. McLoon LK, Wirtschafter JD. Regional differences in the orbicularis oculi muscle: conservation between species. *J Neurol Sci*. 1991;104:197–202.
24. Brooke MH, Kaiser KK. Muscle fiber types. How many and what kind? *Arch Neurol*. 1970;23:369–379.
25. Adams JC. Heavy metal intensification of DAB-based HRP reaction product. *J Histochem Cytochem*. 1981;29:775.
26. Tomas I Ferre J, Fenoll I Brunet J, Santage M, Mayayo E. Changes in motor nerve terminals during bupivacaine-induced postsynaptic deprivation. *J Anat*. 1989;162:225–234.
27. Porter JD, Edney DP, McMahon EJ, Burns LA. Extraocular myotoxicity of the retrobulbar anesthetic bupivacaine hydrochloride. *Invest Ophthalmol Vis Sci*. 1988;29:163–174.
28. McLoon LK, Bauer G, Wirtschafter JD. Increased tissue infiltration increases doxorubicin chemomyectomy in orbicularis oculi. *Invest Ophthalmol Vis Sci*. 1990;31:43.
29. Figarella-Branger D, Nedelec J, Pellissier JF, Boucraut J, Bianco N, Rougon G. Expression of various isoforms of neural cell adhesive molecules and their highly polysialylated counterparts in diseased human muscle. *J Neurol Sci*. 1990;98:21–36.
30. Mastaglia FL, Detchant LW. *Skeletal Muscle Pathology*. New York: Churchill Livingstone; 1992.