

Surgical interventions in chronic osteomyelitis

Shrestha BK¹, Rajbhandary T², Bijukachhe B², Banskota AK³

¹Associate Professor, ²Senior Registrar, ³Professor & Perceptor, Kathmandu University Medical School

Abstract

Chronic osteomyelitis is a leading cause of morbidity in orthopaedic practice in Nepal. Various factors like health service inaccessibility, inadequate treatment, malnutrition, poverty, and to some extent antibiotic resistance contribute to disease progression from acute osteomyelitis to chronic osteomyelitis in this region of the world. This paper presents our experience of managing ninety patients with chronic osteomyelitis over a period of four years, from February 1998 to November 2001.

Key Words: Osteomyelitis, Morbidity

A significant number of children continue to suffer from chronic osteomyelitis making it one of the most commonly presenting orthopaedic problems in Nepal^{1,2}. Chronic osteomyelitis of the extremities is also one of the commonest causes of disability in Nepal³. In the Hospital and Rehabilitation Centre for Disabled Children (HRDC), which is a tertiary level referral centre for reconstructive surgery and rehabilitation, about 6-10% of all the cases are children suffering from chronic osteomyelitis⁴. Pathological fracture and its sequelae, pain, joint contracture, and limb shortening are the commonest consequences after chronic osteomyelitis leading to physical disability⁵. This outcome study explored various aspects of chronic osteomyelitis in children to identify major problems in its management by surgical intervention. This study was carried out at HRDC.

Patients and Methods

This study was carried out between February 1998 to November 2001. Patients presenting with chronic osteomyelitis in the study period were included. Those fulfilling the following inclusion criteria were selected for the study:

- Osteomyelitis, diagnosed as chronic osteomyelitis
- age of the patient > 1 year
- requiring admission

The following patients were excluded from the study:

- Patients with infected joints
- Patients treated conservatively

Patients were regarded as having a functional loss if one of the following conditions existed: persistent pain, inability to weight bear, significantly deviated

gait, and loss of range of motion across the adjacent joint.

Following information and outcome measures were taken: Demographic details, site of infection and sequelae, type of intervention, result of treatment, and complication. The information was subsequently recorded in the computer using Microsoft Excel version 10, and presented in a tabulated format using Microsoft Word version 10.

Results

Ninety children (60 boys, 30 girls) were included in this study. Mean age at first surgical intervention was 2 years (range: 1 year – 16 years). 83% (75) of the patients with chronic osteomyelitis came from the rural community, while 17% (15) came from urban or semi-urban area. Regarding the site of infection, femur was the commonest site involved (50%) followed by tibia (45%). Other bones involved were radius, humerus, and scapula, in the upper extremity and fibula and tarsal bones in the lower extremity.

A total of 112 surgical procedures were carried out in 90 patients. There were 8 modalities of surgical intervention as shown in Table 1. The commonest intervention was Sequestrectomy (59.8%) followed by Ilizarov external fixator application (13.4%) and saucerization (10.7%).

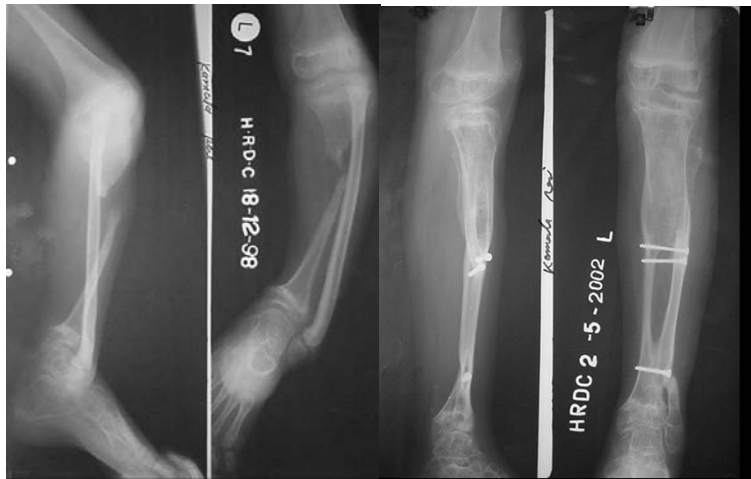As can be seen in Table 1, decompression procedures (Sequestrectomy and saucerization) were necessary for most of the cases. In 28 patients (31%) some other procedure, (combined with a decompression procedure or without it) was necessary to achieve union or leg length symmetry or both. In 62 cases, decompression procedure (79 procedures) was the only surgical intervention necessary.

Correspondence

Dr Binod Bijukachhe,
HRDC, P.O. Box 6757, Kathmandu, Nepal.
Email: orthobb@yahoo.com

Table 1: Surgical Modalities

Surgery	Number (percent)
Sequestrectomy	67 (59.8%)
Saucerization	12 (10.7%)
Internal fixation	6 (5.3%)
External fixation	3 (2.7%)
Huntington's transfer	4 (3.6%)
Fibular grafting	4 (3.6%)
Ilizarov fixator	15 (13.4%)
Symes amputation	1 (0.9%)
Total Number of Surgical Intervention	112



12 years old girl with gap non union of tibia

Huntington's transfer
1st and 2nd stage

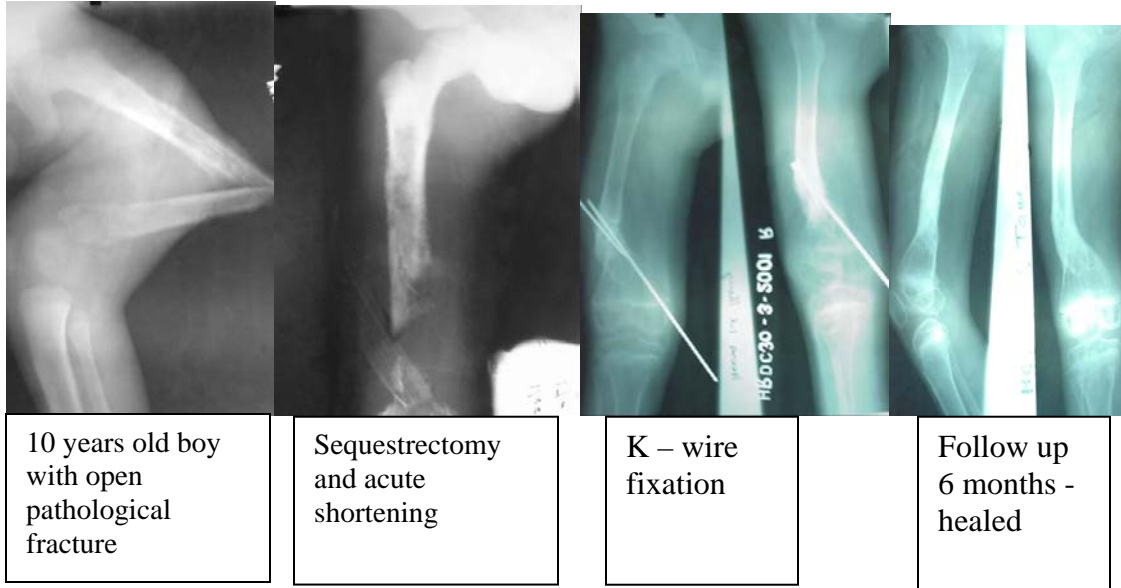
Results of procedures other than that related to decompression and amputation are shown in Table 2.

Table 2

Procedure (Number)	Site	Details	Results/ Complications	Remarks
Internal Fixation (6)	Femur: 5 Tibia: 1	<ul style="list-style-type: none"> • K – wire: 2 • DCP: 2 • Steinmann Pin: 2 	<ul style="list-style-type: none"> • Union: 4 • Nonunion: 2 • LLD>5cm: 3 	Ilizarov for nonunited cases
Fibular grafting (4)	Femur: 1 Tibia: 2 Radius: 1	<ul style="list-style-type: none"> • Strut: 3 • Marsupialized: 1 	<ul style="list-style-type: none"> • Union: 1 • Nonunion: 2 • Displaced graft: 1 	Nonunion: converted to Ilizarov
Huntington Transfer (4)	All tibia		<ul style="list-style-type: none"> • Successful: 2 • Failure: 2 	Ilizarov for failed cases
External Fixator (3)	Femur: 1 Radius: 2		<ul style="list-style-type: none"> • Union: 2 • Nonunion: 1 	Nonunion case lost from follow up
Ilizarov Method (15)	Tibia: 10 Femur: 5	<ul style="list-style-type: none"> • Bone transport: 5 • Limb lengthening: 8 • Stabilization only: 2 	<ul style="list-style-type: none"> • Union: all cases • LLD>5cm: 1 • LLD <2 cm: 14 	

All the procedures mentioned in Table 2 were carried out only after the infection was controlled as

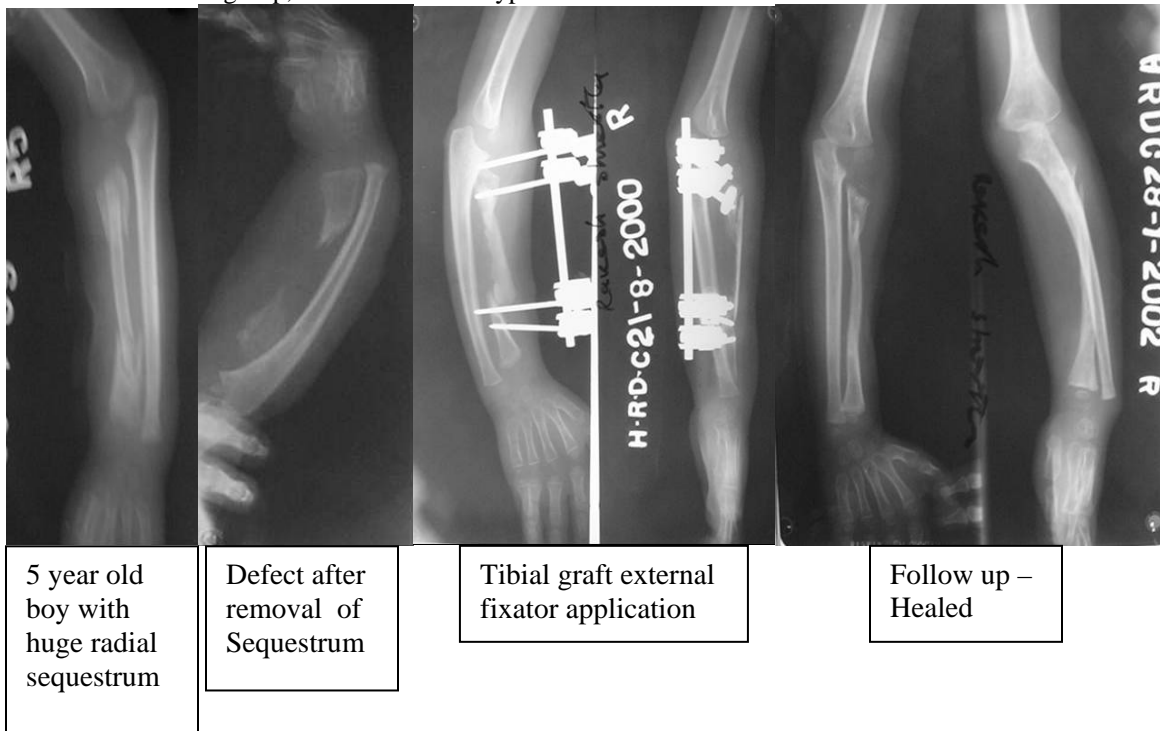
indicated by blood tests (Normal Total Count and ESR) and clinical examination.



In the cases where internal fixation was used, both the ununited fractures had been fixed by K-wires. Remaining four cases united, three of them with a significant limb shortening. In the cases requiring fibular grafting, union was achieved only in one case (post-infective radial club hand). Huntington's

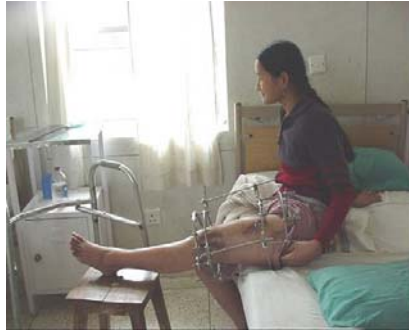transference was performed in 4 cases with gap nonunion of tibia, and it was successful in two cases. Of the two failed cases, first stage had been successfully carried out in one case. Both of these failed cases were converted into Ilizarov method later on.

In external fixation group, Orthofix and AO type of external fixator were used.

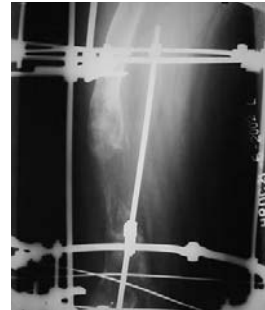


As can be seen in Table 2, six cases of Ilizarov were the ones in whom prior management with other methods failed. All cases with this system of treatment had union, and 14 out of 15 patients had leg

length discrepancy of less than 2 cm. Other minor complications included stiff knee and pin tract infection, which were successfully treated with physiotherapy and local pin care respectively.



16 years old girl in Ilizarov frame for infection of femur



X-ray picture of Ilizarov in femur

Discussion

Chronic pyogenic osteomyelitis continues to be a major challenge in orthopaedic practice. Surgical management varies from simple drainage and debridement to ablation of a part or the entire limb. The present study supports previously published studies⁶ that proper decompression procedures such as sequestrectomy and saucerization may be an adequate and definitive surgical management in chronic osteomyelitis as the majority of the cases were successfully treated with these procedures. However, it should be noted that repeated procedures were necessary in several cases.

A significant percent (31%) of the children with chronic osteomyelitis requiring surgical intervention had some complication that required additional procedures. Pathological fracture leading to nonunion and limb shortening were the two commonest consequences of such complication.

Internal fixation in osteomyelitis has been mentioned as an option for stabilizing the nonunion^{7,8}. The prerequisite for internal fixation is proper control of infection prior to the intervention. The nonunion rate was high in the present study, and limb shortening could not be addressed from this method. Ribault⁹ reported three cases of successful free fibular graft in chronic tibial osteomyelitis with total diaphyseal resection. However, in the present study, this method did not have good results in treating gap defect in tibia. Huntington's transfer has been advocated as a suitable method especially for young patients¹⁰. In our study, however, two out of four cases failed to unite which subsequently were successfully treated by Ilizarov method. External fixator used in the

forearm was mainly to hold the tibial cortical and fibular graft until union in the cases of post infective radial club hand. The result of tibial cortical graft (1 case) was excellent, while that of fibular graft (2 cases) did not yield good result.

Syme's amputation was performed in a child with spina bifida and insensate foot with osteomyelitic involvement of all tarsal bone.

The best result in our series, with complication requiring additional procedures other than decompression, was obtained with Ilizarov circular fixator method. This method is an increasingly popular method for the treatment of various deformities and complications including that resulting from chronic osteomyelitis. Recently published studies accept this method as the best alternative for managing bone defects caused by chronic hematogenous osteomyelitis in children¹¹. In the present study, both the aims of treatment – that is union and limb length equalization – were achieved in 14 out of 15 cases. The remaining one case in which there was more than 5 cm of limb shortening is still under our follow-up, and will undergo a limb lengthening procedure. Ilizarov fixator was also adopted with success in six cases in which other methods had failed. The present study is in accordance with published studies^{11,12} that, if surgical expertise and logistic facilities exist, Ilizarov method is the most suitable method for treating either nonunion or limb shortening due to bone loss following chronic osteomyelitis. As Ilizarov method can provide excellent stability and also address the limb length discrepancy, this is a treatment with

better functional outcome, especially in the age group studied.

Conclusion

Chronic osteomyelitis is still a very common problem in Nepal posing serious challenges to the orthopaedic surgeon. Repeated debridements may be necessary to eradicate or control infection. When complications such as pathological fracture, diaphyseal bone gaps, nonunions and stiffness and deformity have set in, the treatment becomes more complex. The ring fixator has been shown to be a useful tool to address such complications.

References

1. Banskota, A.K. - Chronic Pyogenic Osteomyelitis: Towards more effective treatment. *Journal of the Institute of Medicine*. Vol 5 (1), March 1983:93-96.
2. Lindberg, H.M. - Treatment of chronic osteomyelitis with gentamicin-PMMA beads: A prospective study in Nepal. *Tropical Doctor*. 1987 Oct; 17(4):157-63.
3. Boyce W, Malakar S, Millman R, Bhattarai K. - Physically disabled children in Nepal: A follow-up study. *Asia Pacific Disability Rehabilitation Journal* 2000. Vol. 10(1).
4. Annual Report 2002. Hospital and Rehabilitation centre for Disabled Children.
5. Warner WC. Osteomyelitis. In Crenshaw AH: *Campbell's Operative Orthopaedics*. Missouri, 1992, Mosby Year Book.
6. Walenkamp GH, van Roermund PM, van Horn JR - One hundred years of orthopedics in the Netherlands. The treatment of chronic osteomyelitis. *Ned Tijdschr Geneesk*, 1998 May; 142(20):1124-30.
7. Blachut PA, Meek RN, O'Brien PJ - External fixation and delayed intramedullary nailing of open fractures of the tibial shaft. A sequential protocol. *Journal of Bone and Joint Surgery (Am)* 1990 Jun; 72(5):729-35.
8. Klemm KW. - Treatment of infected pseudarthrosis of the femur and tibia with an interlocking nail. *Clin Orthop* 1986 Nov ;(212):174-81.
9. Ribault L - Treatment of chronic tibial osteomyelitis with total diaphyseal resection and non vascularized secondary fibular graft. *J Chir (Paris)* 1991 Jan; 128(1):22-5.
10. Agiza AR - Treatment of tibial osteomyelitic defects and infected pseudarthroses by the Huntington fibular transference operation. *Journal of Bone and Joint Surgery (Am)* 1981 Jun; 63(5):814-9.
11. Kucukkaya M, Kabukcuoglu Y, Tezer M, Kuzgun U. - Management of childhood chronic tibial osteomyelitis with the Ilizarov method. *Journal of Pediatric Orthopaedics* 2002 Sep-Oct; 22(5):632-7.
12. Marsh JL, Prokuski L, Biermann JS. - Chronic infected tibial nonunions with bone loss: Conventional techniques versus bone transport. *Clinical Orthopaedics* 1994 Apr ;(301):139-46.