

Case Report

Medical Journal of the Islamic Republic of Iran, Vol. 23, No. 4, February 2010, pp. 233-237

Idiopathic granulomatous mastitis: report of 3 cases and a review of the literature

Farzaneh Ebrahimi-Fard, MD¹, Arash Najaf beygi, MD², Ali Kavyani, MD³,
233 Amir Hosein Jalali, MD⁴

Shahid Modarres Hospital, Shahid Beheshti University of Medical Sciences, Tehran, Iran.

Abstract

Idiopathic granulomatous mastitis is a rare, inflammatory, and benign breast disease characterized by non-caseating granulomata and microabscesses limited to breast lobules. This condition presents as a firm breast mass that is clinically and radiologically indistinguishable from breast cancer, or as multiple or recurrent abscesses, or mastitis in a young non-lactating woman. Almost always, the diagnosis is made after surgical interventions to rule out other pathologies as differential diagnoses especially tuberculosis which is endemic in our country.

We are going to report 3 cases of granulomatous mastitis besides a brief review of the literature. We emphatically recommend that although this entity should be kept in mind as a rare differential diagnosis, it should not be considered as the first one.

Keywords: Chronic mastitis, Breast mass, Breast abscess, Granuloma, Idiopathic granulomatous mastitis

Introduction

Idiopathic granulomatous mastitis (IGM), first described by Kessler and Wolloch in 1972, is a rare benign inflammatory disease of the breast in young women. Clinically and histologically, it is a mimicker of acute infection or carcinoma of the breast.

Its etiology is unknown, and autoimmune pathogenesis has been advocated. Histologically, the disease is characterized by the occurrence of numerous granulomatous lesions with multinucleated cells of the Langhans type and focal central necrosis [1].

All specific infectious, granulomatous and neoplastic diseases must be excluded for a correct therapeutical approach [2]. Idiopathic granulomatous mastitis (IGM) characterized by non-caseating granulomata and microab-

sscesses limited to breast lobules. The disease is presented mostly by multiple and recurrent breast abscesses or a firm mass that is clinically and radiologically not distinguished from breast cancer. Frequently, patients are young and multiparous women, some, complain of mastalgia [1-4].

Almost always, the condition is diagnosed after surgical interventions (excisional or incisional biopsy). Two cases referred to the surgical ward and were candidates for mastectomy due to the high suspicion of breast cancer or inflammatory carcinoma. They were treated post-operatively as having tuberculosis (TB) and developed chronic sinus after antituberculous empiric chemotherapy. For this reason, this disease is explored and reviewed in the literature.

Although some organisms may be found in the lesions of granulomatous mastitis, they are

1. Assistant Professor of General Surgery, Shahid Beheshti University of Medical Sciences and Health Services.

2. **Corresponding author**, General Surgery Resident; Shahid Beheshti University of Medical Sciences; Tehran, Iran. Tel: +98 9124849963; Email: a.najafbeygi@yahoo.com

3&4. General Surgery Resident; Shahid Beheshti University of Medical Sciences, Tehran, Iran.

not supposed to be the causative agents and as a matter of fact, the disease is idiopathic [4]. This condition must be differentiated from the other granulomatous diseases such as tuberculosis. Granulomatous mastitis has a great tendency to recur but usually resolves spontaneously even without treatment [2-4].

There is no consensus about the best treatment for this disease but it is believed that proper management and close follow-ups are the preferred choices. Steroids have been used in the treatment course and considered effective in some recurrent or intractable ones but, drug side effects or relapse may be inevitable. In a study conducted in Australia, methotrexate was trialed in refractory cases after surgery or a course of steroid therapy and associated with successful results [5]. It is obvious that surgical intervention per se, can not prevent recurrence of the disease and actually can lead to wound infection persistent wound discharge, suppurative sinus formation or even wound nonhealing [6,7]. On the other hand, it is necessary to have histologic confirmation and also surgical sampling is inevitable [8].

For abscesses, simple drainage accompanied by incisional biopsy of the abscess wall is adequate and constitutes the standard treatment [8]; but for a breast mass that mimics cancer, it is preferred to obtain a tissue sample by fine-needle aspiration (FNA) or core needle biopsy [5,9]. Needle aspiration or a small incision to drain abscesses is preferred if feasible.

Both the aforementioned procedures were performed by the author and then reported on this paper.

Case reports

Case 1:

A 41-year-old multiparous woman was referred to the surgical ward because of pain in the right breast in addition to a palpable mass with surrounding erythema. She also complained of nipple purulent discharge. The symptoms were initiated one month prior to admis-

sion and she was febrile when referred. She had a history of the same breast abscess drainage last year, accompanying psychologic disorder necessitating antipsychotics and biperiden. She was not lactating. Ultrasonography revealed a large retroareolar abscess measuring 8 centimeters in diameter. Abscess drainage with abscess wall biopsy was performed under general anesthesia. It resembled malignant but on pathologic examination, granulomatous perilobular mastitis was reported. The patient suffered a delayed infection and recurrent contralateral breast abscess formation which was treated by recurrent aspirations. Abscess discharge culture was negative for acid fast bacilli (AFB) and polymerase chain reaction (PCR) confirmatory test was also negative. Discharge culture however, revealed nonspecific bacterial growth.

Case 2:

A 34-year-old woman with a history of normal vaginal delivery at the age of 29, was referred because of a tender mass accompanying a sense of heaviness in her right breast. She was not lactating and there was no history of oral contraceptive (OCP) consumption. She had a history of taking levothyroxine for 15 years before admission because of a benign goiter besides taking antipsychotic agents. On ultrasonography, the mass was detected as solid and heterogenous in echo pattern and on mammography, a hyperdense mass with irregular borders suspected of infiltrative malignancy. On pathologic tissue evaluation, chronic mastitis with granulomatous changes was reported. Afterwards, the patient developed wound infection with significant suppurative discharge and finally a chronic sinus was formed that lasted nearly 2 months to resolve. Direct smear was negative for AFB and PCR did not confirm tuberculosis. Considering our area as endemic for tuberculosis and presence of granulomata on microscopic evaluation, empiric antituberculous treatment was accomplished but no clinical improvement evidenced. During medical

therapy, breast masses with sonographic features suspected of malignancy were detected but pathologic evaluation resulted in the same diagnosis. Afterwards, the patient was followed-up, for her condition.

Case 3:

A 24-year-old girl was referred with left peri-areolar breast abscess. On examination, the whole breast was indurated and inflamed. Sonographically, the abscess was confirmed. Hence, surgical drainage was done and a biopsy was taken from the inflamed abscess wall but revealed granulomatous mastitis. Tissue smear and culture for AFB was negative. There was a history of convulsive disorder and antiepileptic agent (eg. phenytoin & valproate sodium) consumption since childhood. Following abscess drainage, a suppurative sinus complicated the surgical site and it took a long time to be healed. In less than 6 months, the breast abscess recurred and was managed by needle aspiration.

Discussion

Granulomatous mastitis was first described by Kessler & Wolloch in 1972.

They reported 5 cases with the initial diagnosis of malignant breast mass who developed recurrent abscess formation containing granulomata subsequently. They emphasized that this rare disorder had a tendency to recur chronically [5].

Other systemic granulomatous disorders like Wegener's granulomatosis or sarcoidosis must be ruled out to establish the final diagnosis of granulomatous mastitis[3,4]. In primary granulomatous mastitis, the inflammatory process is confined to breast lobules and microabscesses may occupy the whole lobule. Areas of necrosis may also develop. Giant cells and non-caseous epithelioid cells constitute the nonspecific granulation tissue in granulomatous mastitis and those composed of foreign body cells and the Langhans' cells. In the center of the granulomata, polymorphonuclear cells (PMNs) are

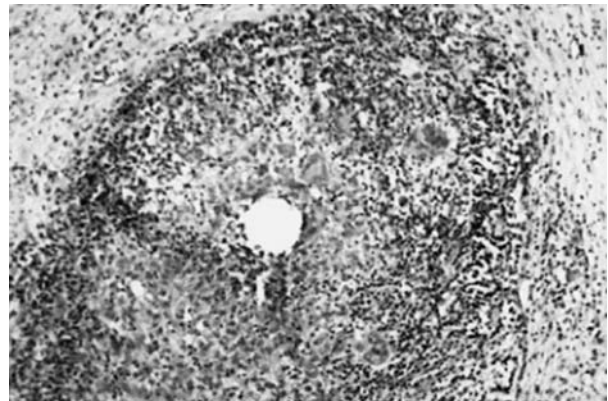


Fig. 1. Photomicrograph shows completely affected breast lobules by chronic inflammation and granulomatous formation. (Hematoxylin and eosin; magnification $\times 100$.)

more frequent than other cells and duct ectasia may be absent [1,3].

The most important granulomatous disorder which must be differentiated is tuberculosis (that is especially endemic in our country). In all 3 of the aforementioned cases, tissue acid fast staining and the PCR test were negative for tuberculosis. It is noteworthy that we did not find any caseating necrosis (the key point to de-

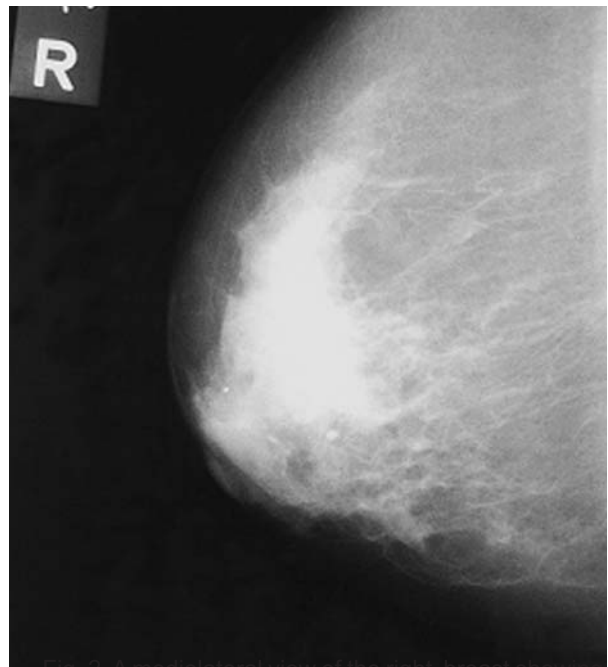


Fig. 2. A mediolateral view of the right breast showing a large asymmetrical increased density in the upper outer quadrant extending to the retroareolar region. Excisional biopsy showed idiopathic granulomatous mastitis.

termine tuberculosis) in our tissue specimens. In all suspected cases, inflammatory carcinoma must be ruled out; especially because it affects nonlactating women. Hence, pathologic evaluation of the lesion is strongly suggested.

The Granulomatous mastitis etiology is unknown, and more common in young women. No correlation between breast feeding or OCP consumption and the mentioned disorder has been found so far. Kessler & Wolloch have supported the autoimmune etiology mostly because microscopic features are similar to other granulomatous disorders (like granulomatous thyroiditis or orchitis).

Treatment of the granulomatous mastitis is controversial [12]. Surgery is not abruptly beneficial and in most of cases, simple drainage and incisional biopsy are adequate [8]. De-Hertogh and colleagues showed that short courses of high dose prednisolone was efficient although the follow-up period was shorter to precisely evaluate recurrence rate [12].

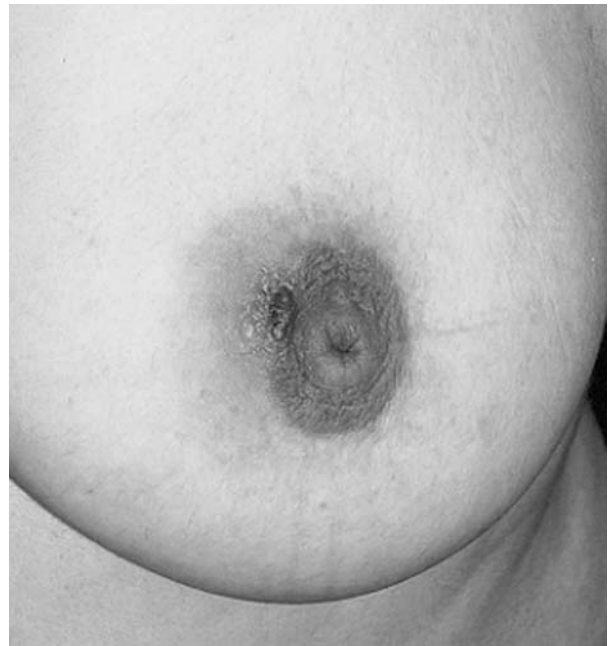

Fig.3. View of the left breast in a GM patient.

In several studies, the diagnostic accuracy of FNA has been reported as 87-90%.

The aforementioned cases of granulomatous

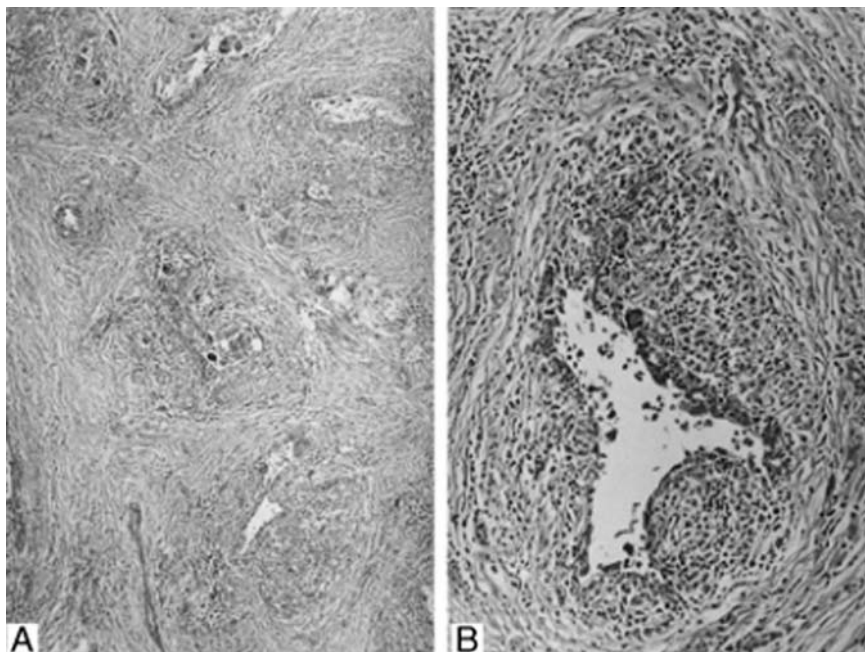


Fig. 4. (A) A case of idiopathic granulomatous mastitis showing chronic inflammation and noncaseating granulomas, centered on breast lobules, which have been diffusely obliterated (hematoxylin-eosin; magnification $\times 100$). (B) Note the presence of epithelioid histiocytes, lymphocytes, plasma cells, polymorph nuclear leukocytes, and multinucleated Langhans-type giant cells (hematoxylin-eosin; magnification $\times 250$).

mastitis who all presented with distinct clinical features of the disease, are characteristic examples of clinical diagnostic pitfalls and the necessity of histologic diagnosis to rule out other benign and malignant pathologies of the breast.

Granulomatous mastitis predominantly occurs in nonlactating women [3,4], so, it is more probable to assume the clinical feature as a malignant process [1,2,3], rather than an inflammatory disorder like mastitis or breast abscess. It must be considered as a rare differential diagnosis (but not the first one) in breast specialists approach.

Conservative and symptomatic treatment should follow the surgical one at least to definitively diagnose the disorder and rule out the differential ones. Medical treatments such as steroids or methotrexate, are under survey [1,8,12]. The probability of drug resistance, recurrence of the disease after drug discontinuation and the risk of drug side effects should be considered when medical therapy is selected [8,11].

By reviewing the literature, granulomatous mastitis is more common in Eastern countries like China and Turkey where it can be epidemiologically significant. Performing similar studies in Iran can also be helpful.

In addition, in all 3 cases of this paper, there was a history of psychoactive drug consumption that can be noteworthy but further studies with a larger sample-size are required to determine the probable correlation. As a whole, more clear evidence is needed to reveal its pathogenesis.

Conclusion

It is necessary to consider granulomatous mastitis as a rare differential diagnosis from other pathologies and not the first one. More common benign and especially malignant disorders of the breast should be ruled out prior to making a definite diagnosis.

References

1. Dixon JM, Breast Infection. ABC of breast diseases BMJ 1994;309-946.
2. Going JJ, Anderson TJ, Wilkinson S, Chetty U. Granulomatous lobular mastitis. J Clin Pathol 1987;40:535.
3. Howell JD, Barker F, Gazet J-C .Granulomatous lobular mastitis: report of a further two cases and a comprehensive literature review. Breast 1994;3:119.
4. Disease of Breast, 2nd ed. Edited by Jay R.Harris Lippincott Williams & Wilkins, Philadelphia. 2000; 4:54.
5. Kessler E,Wolloch Y. Granulomatous mastitis: a lesion clinically simulating carcinoma, Am J Clin Pathol 1972;58:642-46.
6. Cohen C. Granulomatous mastitis. A review of 5 cases. S Afr Med 1997;52:14-16.
7. Kamal E, Bani-Hani. Idiopathic granulomatous mastitis: time to avoid unnecessary mastectomies. The Breast Journal 2004;318-322.
8. Oktar Asoglu, Vahit Ozmen . Feasibility of surgical management in patients with granulomatous mastitis. The Breast Journal 2005 ;108-114.
9. B, Cakir. N, Tuncbilek. Granulomatous mastitis mimicking breast carcinoma. The Breast Journal 2002;251-252.
10. Siu-King Mak, Pik-Kei Wong. Granulomatous mastitis. Ann Coll Surg HK 2001. 5;129-131.
11. Joon Kim, Kathleen E. Methotrexate in the management of granulomatous mastitis. ANZ J. Surg.2003;73:247-249.
12. Eric C.H.Lai, MRCSEd, Wing Cheong Chan, FRCSEd, The role of conservative treatment in idiopathic granulomatous mastitis. The Breast Journal 2005.11-6;454-456.
13. Maffini F, Baldini Bassi F, F, Luini A, Viale G. Systemic therapy as a first choice treatment for idiopathic granulomatous mastitis. J Cutan Pathol 2009 Jun; 36(6):689- 91. Epub 2009 Feb 4. PMID: 19222698.