

# Improvement of Autism Symptoms with Antiepileptic Treatment in a Child with Landau-Kleffner Syndrome

ARTICLE IN PRESS



Çağatay UĞUR<sup>1</sup>, Nagihan SADAY DUMAN<sup>2</sup>, Ömer BEKTAŞ<sup>3</sup>, Cihat Kağan GÜRKAN<sup>4</sup>

## SUMMARY

**Introduction:** Landau-Kleffner Syndrome is a rare childhood disorder characterized by acquired aphasia and epileptiform EEG abnormalities. Hyperactivity and attention problems are common in LKS, and symptoms of Autism Spectrum Disorders (ASDs) may also coexist. Many different treatments have been used for LKS, with varying rates of success. In particular, the effects of antiepileptic drug treatment on acquisition of language have been inconsistent. To the best of our knowledge the literature does not include any reports on the effect of antiepileptic drug treatment on ASD symptoms in patients with LKS. Herein we report a boy with LKS whose ASD symptoms markedly improved in response to antiepileptic treatment.

**Case:** A boy aged 3 years 10 months presented to the department of child and adolescent psychiatry due to lack of social interaction, decreased eye contact, stereotypic hand movements, and language regression. The patient was diagnosed as LKS and valproic acid (VAL) treatment was started. The patient was followed-up regularly and after 3 months of treatment with VAL substantial improvement was observed in problematic behaviors, and language and social skills.

**Discussion:** In the presented LKS case rapid improvement in autism symptoms was observed in response to antiepileptic drug treatment. The patient's reacquisition of speech and rapid improvement in social skills with antiepileptic treatment are important findings. It may be possible to effectively treat ASD symptoms in patients with LKS with early diagnosis and appropriate antiepileptic treatment.

**Keywords:** Autism spectrum disorders, Landau-Kleffner syndrome, antiepileptic treatment

## INTRODUCTION

Autism spectrum disorders (ASDs) is a group of neurodevelopmental disorders characterized by complex features, including impaired reciprocal communication and social interaction, and restrictive and repetitive behaviors (American Psychiatric Association 2000). Landau-Kleffner syndrome (LKS) is a very rare childhood disorder characterized by acquired aphasia and abnormal epileptiform EEG findings (Office of Rare Diseases 2008). Since 2011, years there have been only 350 LSK cases described in the literature (Cockerell et al. 2011). Most children with LKS experience language loss resembling autism prior to the age of 36 months (McVicar et al. 2005). Language loss is often characterized by severe disturbance in auditory language comprehension combined with substantial reduction

in expressive language. It is known that LKS may sometimes involve ASD symptoms in addition to the commonly observed hyperactivity and attention problems (Stefanatos 2011). Herein we report a patient that presented with ASD symptoms that was diagnosed as LKS based on neurological assessments and showed marked improvement in ADS symptoms following antiepileptic drug treatment.

## CASE

A boy aged 3 years 10 months old boy was brought to our clinic by his mother and father due to social withdrawal, not playing with peers, lack of social interaction, reduced eye contact, stereotypic hand movements, and language regression. It

Received: 07.01.2013 - Accepted: 25.04.2013

<sup>1,2</sup>MD, Department of Child and Adolescent Psychiatry, <sup>3</sup>MD, Department of Pediatric Neurology, <sup>4</sup>Assoc. Prof., Department of Child and Adolescent Psychiatry, Ankara University Medical School, Ankara, Turkey.

E-mail: bektasomer@gmail.com

was reported that the boy's father had an accident 10 months earlier and was away from home for a short period of time, during which the child was accidentally burned by hot water. One month after that event he began to exhibit social withdrawal, language regression, reduced eye contact, and aimless hand movements. It was also reported that the reported symptoms gradually increased during the 3 months prior to presentation; the child became unresponsive to his environment, behaved as if he were deaf, stopped responding to his father when he returned home, stopped playing with his peers, spun in circles, ran aimlessly around the home, and began murmuring to himself—especially while looking at his hands. The parents reported that the patient was not communicating with his peers and did not play with other children, preferring to be alone. The boy exhibited repetitive behaviors and insisted on sameness. Moreover, he would stare vacantly at the television or into space, would daydream for more than 5-10 s at a time, and talked during sleep and woke up screaming.

The patient was the parents' second male child and was born when his mother was 26 years old. The mother was diagnosed with hyperemesis gravidarum during her pregnancy and was recommended 4 months of bed rest to prevent preterm labor; the patient was born full term via normal vaginal delivery without any post-delivery complications. The patient was breastfed for 24 months, began to speak single meaningful words at age 1 year and was walking at age 1.5 years. It was reported that the patient had been cheerful, made regular eye contact, responded to his name, played with his peers, spontaneously talked to his family and relatives, made complete sentences, imitated animal sounds, and asked questions about issues of interest before the onset of the presenting symptoms.

During the patient's psychiatric evaluation he did not speak, but made some meaningless sounds, did not respond to his name, appeared socially impaired, and could not follow simple commands. It was also noted that he made limited eye contact, and he did not point at objects or look in the direction that others pointed to. The patient did not initiate any communication spontaneously, and could only perform simple and repeated commands. He spun around in a circle and made some stereotyped movements such as flapping.

Following the initial interview, the Autism Interview Form (Akçakın 193) was administered and his parents were asked to complete the Autism Behavior Checklist (ABC) (Yılmaz-Irmak et al. 2007). According to the father's and mother's ABC scores (82 and 71, respectively), the patient had many autism symptoms. As a result of the evaluations carried out, the patient was diagnosed as pervasive developmental disorder not otherwise specified (PPD-NOS). The Ankara Developmental Screening Inventory (ADSI) score showed that the patient also had mild developmental delay.

Based on the symptoms reported by the patient's parents, epileptic seizure was suspected and the patient underwent pediatric neurological consultation. Brainstem auditory evoked response (BAER) test and cranial MRG findings were normal. EEG showed a generalized epileptic abnormality, which together with the clinical findings led to a diagnosis of LKS, according to ICD-10 criteria. Valproic acid (VAL) treatment was then initiated by the pediatric neurology department.

The patient was enrolled in a special education program and recommended to start a kindergarten. Moreover, the family and the child were followed-up and treated regularly via interaction guidance sessions at the child and adolescent psychiatry clinic. After initiating VAL treatment (20 mg·kg<sup>-1</sup>·d<sup>-1</sup>) the patient's clinical findings improved markedly. Along with an increase in eye contact, the patient began again to speak and ask questions spontaneously. The frequency and duration of stereotypic hand movements decreased. He started to understand and follow commands consistently. He began to speak more frequently and the frequency of meaningless and repetitive utterances decreased.

EEG findings 3 months after the start of VAL treatment were normal, which was regarded as a positive response to the treatment. The patient was still on VAL treatment at the time of the final psychiatric interview conducted 2 months after presenting, all the presenting symptoms were greatly improved, and the ABC scale score decreased to 44.

## DISCUSSION

To the best of our knowledge the present report is the first to describe rapid improvement in autism symptoms in a patient with LKS following antiepileptic treatment. There are studies that suggest language skills, cognitive functions, seizures, and EEG abnormalities in LKS can be improved by various medications; however, there are no data concerning their effectiveness in the treatment of the symptoms of autism. The literature does include reports that ASD symptoms can occur in LKS (Lesca et al. 2012; Alyanak and Motavalli 2002). Children with LKS have been reported to exhibit normal language and social development, only to lose those abilities during the first 2 years of life, receiving the diagnosis of autism (Lord et al. 2004).

Periods of regression in some cases with autism, along with the fact that autism is causatively related to epileptic disorder has led to the notion that treating EEG abnormalities might improve the symptoms of autism too, and that LKS could be a good starting point in this regard (Deonna and Roulet-Perez 2010). As such, many centers have collected EEG data on newly diagnosed autism patients and have treated with antiepileptic drugs or corticosteroids (Chez et al. 2006); however, it remains unclear if children with regressive autism are

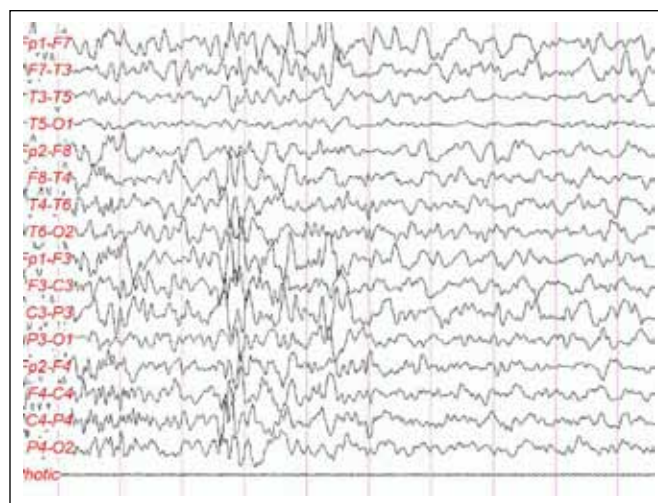
different than others or if improving EEG abnormalities via antiepileptic drugs improves autism symptoms (Deonna and Roulet-Perez 2010).

Although the etiology of LKS has been well studied, data on its physiopathology, prognosis, and treatment are limited. As LKS is a rare syndrome, studies on its treatment are limited in number and there haven't been any randomized controlled studies. It has been reported that epileptic seizures are usually controlled easily with ordinary antiepileptic treatment, whereas the optimal treatments for language disorders and EEG abnormalities are unclear (McVicar and Shinnar 2004). While drugs such as valproate, ethosuximide, clonazepam, and clobazam have been reported to be effective for partial or transient epileptic seizures, for regaining the ability to speak (Gordon 2004; Smith and Spitz 2002), and for decreasing the frequency of seizures without improving the ability to speak (Hughes 2011), some studies reported that antiepileptic treatment has no benefit (Bogaert et al. 2012; Tsuru et al. 2000). Corticosteroids, however, have been reported to significantly improve language and cognitive skills in children with LKS (Bogaert et al. 2012; Hughes 2011; Gordon 2004; Smith and Spitz 2002). These findings suggest that antiepileptic drugs varying in their effectiveness in treating LKS, making it difficult to decide on an optimal treatment. In addition, no studies have investigated the impact of drugs on comorbid autism symptoms.

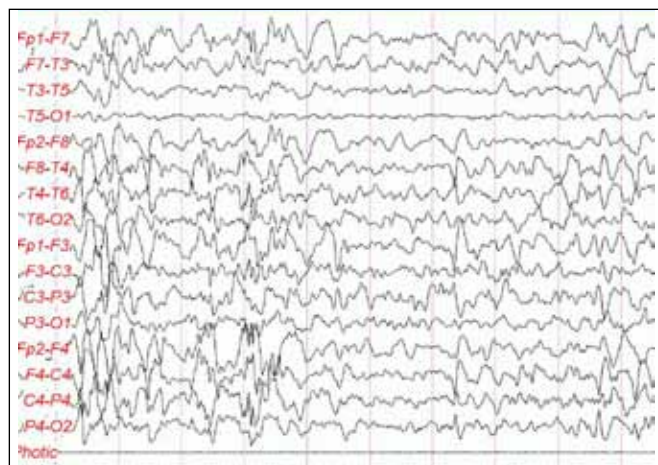
In the present case rapid and significant improvement was noted in language and symptoms of autism following antiepileptic drug treatment. It is a limitation that the patient's condition prior to presentation is based only a parental reports. His parents reported that premorbid development was normal. In this regard, 2 options were considered: the case had ASD before seizures and that the seizures caused regression in language and social skills, or ASD symptoms started due to EEG abnormality/seizures. Nonetheless, the improvement in autism symptoms following antiepileptic treatment was much faster than that expected in ordinary autism cases.

ASDs are a group of disorders classified under a single heading due to their clinical similarities. Although LKS is within that spectrum, it is difficult to classify cases with typical EEG abnormalities and a positive response to treatment in this spectrum. In the future, the heterogeneity of LKS and its derivatives should be addressed, appropriate diagnostic criteria regarding regression should be defined (Stefanatos 2011), and more effective treatments should be developed (O'Hare 2008) based on the findings of longitudinal, multidisciplinary multicenter studies. Thus, a psychiatric classification system that considers the role of multi-etiological factors rather than being only descriptive, may include a pervasive developmental disorder variant of LKS.

To the best of our knowledge the present case report is the first to describe rapid improvement in autism symptoms in LKS with antiepileptic drugs. Earlier studies that focused on improvements in language and cognitive symptoms in patients that differed from the presented case in terms of clinical presentation and age of onset emphasized that LKS might be associated with regressive autism (McVicar and Shinnar 2004); however, based of the latest data LKS may have as early an onset as autism and those with LKS may have symptoms of autism (Deonna and Perez 2010). In the presented case the rapid improvement in ASD symptoms, including repetitive behaviors, and language and social skills regression following normal development, is noteworthy. Accordingly, we think that controlled studies that evaluate the impact of antiepileptic drugs on autism symptoms in LKS are necessary.



**Figure 1.** 3 years and 10 months-old male patient is diagnosed with Landau-Kleffner Syndrome: Multi focal spike and slow wave discharges in the interictal Sleep EEG's (Amplitude 200  $\mu$ v, low filter: 1Hz, high filter:35 Hz).



**Figure 2.** 3 years and 10 months-old male patient is diagnosed with Landau-Kleffner Syndrome: Multi focal spike and slow wave discharges in the interictal Sleep EEG's (Amplitude 200  $\mu$ v, low filter: 1Hz, high filter:35 Hz).

In conclusion, children presenting with ASD symptoms, such as restricted interests, repetitive behaviors, and regression in social interaction and language, should be carefully assessed via neurological, audiological, and psychiatric examinations, and LKS and similar epileptic syndromes should be considered in the differential diagnosis. As in the presented case, early diagnosis followed by treatment with antiepileptic drugs can improve seizures and EEG abnormalities.

---

## REFERENCES

- American Psychiatric Association. Diagnostic and statistical manual for mental disorders (DSM-IV-TR). 4th ed, text revision. Washington, DC, USA: American Psychiatric Association, 2000.
- Akçakın M, Kerimoğlu E (1993) Otizmde Prognoz ve Ayırıcı Tanı, Otizm.1st ed, Ankara Üniversitesi Tıp Fakültesi Basımevi, Ankara, Turkey.
- Alyanak B, Motavallı Mukaddes N (2002) Yaygın Gelişimsel Bozukluklar ve Landau Kleffner Sendromu'nun Örtüştüğü Olgular (5 Olgu Sunumu) *Düşünen Adam*, 15:113-6.
- O'Hare A (2009) Autism spectrum disorder: diagnosis and management *Arch Dis Child Educ Pract Ed*, 94:161-8.
- Bharani S, Trivedi C, Shendurnikar N et al (2001) Landau Kleffner syndrome. *Indian J Pediatr*, 68:567-9
- Bogaert VB, King MD, Paquier et al (2013) Acquired auditory agnosia in childhood and normal sleep electroencephalography subsequently diagnosed as Landau-Kleffner syndrome: report of three cases. *Dev Med Child Neurol*, 55:575-9.
- Chez MG, Chang M, Krasne V et al (2006) Frequency of epileptiform EEG abnormalities in a sequential screening of autistic patients with no known clinical epilepsy from 1996 to 2005. *Epilepsy Behav*, 8:267-71.
- Cockerell I, Bølling G, Nakken KO (2011) Landau-Kleffner syndrome in Norway: Long-term prognosis and experiences with the health services and educational systems. *Epilepsy & Behavior*, 21:153-9.
- Deonna T, Roulet-Perez E (2010) Early-onset acquired epileptic aphasia (Landau-Kleffner syndrome, LKS) and regressive autistic disorders with epileptic EEG abnormalities: The continuing debate. *Brain Dev*, 32:746-52.
- Duran MH, Guimarães CA, Medeiros LL et al (2009) Landau-Kleffner syndrome: long-term follow-up. *Brain Dev*, 31:58-63.
- Gordon N (2004) The neurology of sign language. Review. *Brain Dev*; 26:146-50.
- Hughes JR (2011) A review of the relationships between Landau-Kleffner syndrome, electrical status epilepticus during sleep, and continuous spike-waves during sleep. *Epilepsy Behav*, 20:247-53.
- Inutsuka M, Kobayashi K, Oka M et al (2006) Treatment of epilepsy with electrical status epilepticus during slow sleep and its related disorders. *Brain Dev*, 28:281-6.
- Lesca G, Rudolf G, Labalme A et al (2012) Epileptic encephalopathies of the Landau-Kleffner and continuous spike and waves during slow-wave sleep types: Genomic dissection makes the link with autism. *Epilepsia*, 53:1526-38.
- Lord C, Shulman C, DiLavore P (2004) Regression and word loss in autistic spectrum disorders. *J Child Psychol Psychiatry*, 45:936-55.
- McVicar KA, Shinnar S (2004) Landau-Kleffner syndrome, electrical status epilepticus in slow wave sleep, and language regression in children. *Ment Retard Dev Disabil Res Rev*, 10:144-9.
- McVicar KA, Ballaban-Gil K, Rapin I et al (2005) Epileptiform EEG abnormalities in children with language regression. *Neurology*, 65:129-31.
- Office of Rare Diseases Research. Washington, DC: National Institutes of Health; 2008. <http://rarediseases.info.nih.gov/gard/6855/Landau-Kleffner-syndrome/Resources/1>
- Paquier PF, Van Dongen HR, Loonen CB (1992) The Landau-Kleffner syndrome or 'acquired aphasia with convulsive disorder': long-term follow-up of six children and a review of the recent literature. *Arch Neurol*, 49:354-9.
- Smith MC, Spitz MC (2002) Treatment strategies in Landau-Kleffner syndrome and paraictal psychiatric and cognitive disturbances. *Epilepsy Behav*, 3:24-9.
- Stefanatos G (2011) Changing perspectives on Landau-Kleffner Syndrome. *The Clinical Neuropsychologist*, 25:963-88.
- Tsuru T, Mori M, Mizuguchi M et al (2000) Case reports. Effects of high-dose intravenous corticosteroid therapy in Landau-Kleffner syndrome. *Pediatr Neurol*, 22:145-7.
- Yılmaz-Irmak T, Tekinsav-Sütçü S, Aydın A et al (2007) Otizm Davranış Kontrol Listesinin (SDKL) Geçerlik ve Güvenirliğinin İncelenmesi. *Çocuk ve Gençlik Ruh Sağlığı Derg*, 1:13-23.